

Microfracture Technique in Combination with Intraarticular Hyaluronic Acid Injection in Articular Cartilage Defect Regeneration in Rabbit Model

Legović, Dalen; Zoričić, Sanja; Gulan, Gordan; Tudor, Anton; Prpić, Tomislav; Šantić, Veljko; Bobinac, Dragica; Šestan, Branko; Mihelić, Radovan; Jurdana, Hari

Source / Izvornik: **Collegium antropologicum, 2009, 33, 619 - 623**

Journal article, Published version

Rad u časopisu, Objavljena verzija rada (izdavačev PDF)

Permanent link / Trajna poveznica: <https://um.nsk.hr/um:nbn:hr:184:050339>

Rights / Prava: [In copyright](#)/[Zaštićeno autorskim pravom.](#)

Download date / Datum preuzimanja: **2024-10-07**



Repository / Repozitorij:

[Repository of the University of Rijeka, Faculty of Medicine - FMRI Repository](#)



Microfracture Technique in Combination with Intraarticular Hyaluronic Acid Injection in Articular Cartilage Defect Regeneration in Rabbit Model

Dalen Legović¹, Sanja Zoričić², Gordan Gulan¹, Anton Tudor¹, Tomislav Prpić¹, Veljko Šantić¹, Dragica Bobinac², Branko Šestan¹, Radovan Mihelić¹ and Hari Jurdana¹

¹ Orthopaedic University Hospital Lovran, Lovran, Croatia

² Department of Anatomy, School of Medicine, University of Rijeka, Rijeka, Croatia

ABSTRACT

Although articular hyaline cartilage typically has low potential for regeneration, numerous methods and techniques have been proposed to induce the reparation process. In our work, we used microfracture techniques in combination with intraarticular application of hyaluronic acid in rabbit knee articular cartilage defect. In comparison with the control group, after 6 and 10 weeks we observed a higher potential of healing in the experimental group, with thicker and more organized repair tissue filling the defect. In conclusion, a combination of the microfracture technique and application of hyaluronic acid might be potentially beneficial in inducing articular cartilage defect reparation.

Key words: *hyaluronic acid, microfracture technique, cartilage reparation*

Introduction

Articular cartilage injuries in the knee have been frequently observed and recognized as a cause of significant morbidity and disability. It is generally accepted that focal chondral lesions often progress towards osteoarthritis¹.

Curl et al.² reported 63 % of cartilage lesions in 19,827 knees. Aroen et al.³ described various articular cartilage abnormalities in 66% of 993 knee arthroscopies.

Chondral defects of the articular surface present a challenging problem to the orthopedic surgeon because of the low healing potential of the cartilage⁴. The goal of surgery is to alleviate pain, maximize function and prevent further degenerative changes. A number of techniques have been described to treat these lesions^{5–8}. When considering the options for treating chondral defects, the surgeon must take into account the size, depth, location and chronicity of the lesion.

In 1994, Rodrigo and Steadman introduced some new techniques for treating the articular cartilage defect, the so-called microfracture techniques⁹. After debriding the articular defect, the subchondral bone was penetrated

with specially constructed awls to provoke bleeding. The holes thus formed filled with clots rich in pluripotential cells and various growth factors which differentiated into a fibrocartilaginous tissue. Formation of new tissue can be expected in 6–12 weeks according to Gill et al.¹⁰.

Another method used in treating a knee with cartilage breakdown, especially a knee with osteoarthritic change, is the intraarticular application of hyaluronic acid^{11–14}.

The purpose of this study was to investigate the therapeutic effect of a combined therapeutic method in treating the full-thickness articular cartilage defect *in vivo*, i.e., a combination of microfracture method and hyaluronic acid application.

Materials and Methods

Twenty-four fully grown male New Zealand rabbits, weighing 4 kg, were used in this study. Following intravenously administered anesthesia (Ketalar via ear marginal vein), a medial parapatellar skin incision was made

and extended through the joint capsule. The patella was removed laterally and joint surfaces were exposed. A 4 × 3 mm defect of the articular cartilage (depth 1–2 mm) was made on the upper quadrant of a medial femoral condyle using a mini chisel. The base of the articular cartilage defect was perforated at 4 consistently distant points using fine Kirshner wire and creating microfractures of the subchondral bone (Figure 1). This resulted in bleeding of the subchondral blood vessels. After this treatment, the wound was sutured in two layers with absorbable sutures and the animals were given an antibiotic. After the surgery, the animals were not immobilized and were allowed free movement and activity in their cages of standard dimensions. The animals were divided into two groups according to the postoperative treatment as follows:

1. The experimental group of animals that received an intraarticular injection of hyaluronic acid (0.5 mL sodium-hyaluronat, commercial product Hyalgan, 2 mL, concentration of 1% hyaluronic acid, Fidia S.p.A., Abano Terme, Italy) once weekly for 5 weeks.

2. The control group of animals received an intraarticular injection 0.5 mL bufferet saline without the active substance – hyaluronic acid, once weekly for 5 weeks.

The animals were euthanized with an overdose of pentobarbiton until cardiac arrest was achieved. The tissues were then harvested for microscopic analysis.

From each animal group, 6 animals were sacrificed at each time point (6 and 10 weeks after surgery).

Tissue processing and histology

The knee joint of each sacrificed animal was opened and the femur dislocated from the tibia. The distal part of the femur was excised and rinsed with saline, fixed in

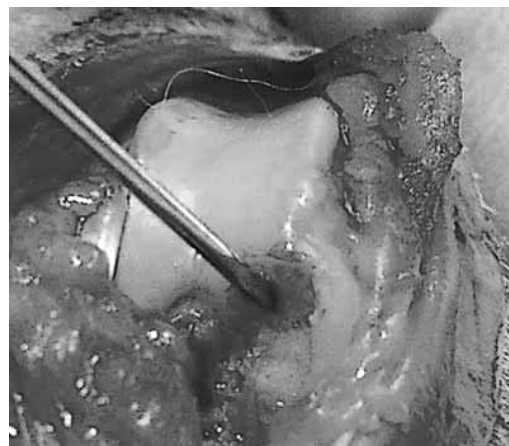


Fig. 1. Articular defect formed by chisel was drilled with K-wire till the subchondral bone.

4% paraformaldehyde, dehydrated in ethanol, cleared in xylene and embedded undecalcified in methyl metacrylate. Serial slices of the tissue samples were cut to a thickness of 7 μ m using a microtome (Leica RM 2155) equipped with a tungsten carbide knife. They were then mounted on silinated glass slides (Silane-Prep slides, Sigma S 4651), dried at 37 °C and stained with toluidin blue.

The articular cartilage obtained from both groups of animals was graded using the International Cartilage Repair Society (ICRS) Visual Histological Assessment Scale by one blinded observer¹⁵ (Table 1).

The analysis of the presence of specific features scored by ICRS scale was performed using Pearson, χ^2 test or Fischers' exact test. All statistical values were considered significant at the P level of <0.05.

TABLE 1
THE ICRS VISUAL HISTOLOGICAL ASSESSMENT SCALE

Histological criteria		Score
Articular surface	smooth/continuous	3
	irregularities/discontinuous	0
Matrix	hyaline	3
	mixture (hyaline / fibrocartilage)	2
	fibrocartilage	1
	fibrous tissue	0
Cell distribution	columnar	3
	mixed (columnar / clusters)	2
	clusters	1
	individual cells / disorganized	0
Cell population viability	predominantly viable	3
	partially viable	1
	< 10% viable	0
Subchondral bone	normal	3
	increased remodeling	2
	bone necrosis / granulation tissue	1
	detached / fracture / callus at base	0
Cartilage mineralization	normal	3
	abnormal / inappropriate location	0

All the surgical procedures performed on the experimental animals were approved by the ethics committee of the University of Rijeka School of Medicine.

Results

Histological sample analysis of the control group at 6th and 10th week revealed that articular cartilage defects were filled with repair tissue which varied widely from a disorganized fibrous tissue with incorporated bone fragments undergoing reabsorption to fibrous cartilage or islands of hyaline cartilage. The edges of the original articular cartilage could be recognized as a sharp demarcation line. The bottom of the defect showed changes in the bone architecture with regard to the adjacent subchondral bone, the bone trabeculas being smaller but more numerous and showing necroses and detachment. The appearance of the healing process was not uniform in all tissue samples and no common morphological pattern could be recognized.

In the experimental group, the histological samples showed that the articular cartilage defects were filled with fibrous cartilage with numerous chondrocyte clusters (Figure 2). Reparative tissue reached the level of normal cartilage. The edges of the defects showed the sites of bone reabsorption but the adjacent articular cartilage seemed unchanged and continuously bonded to the

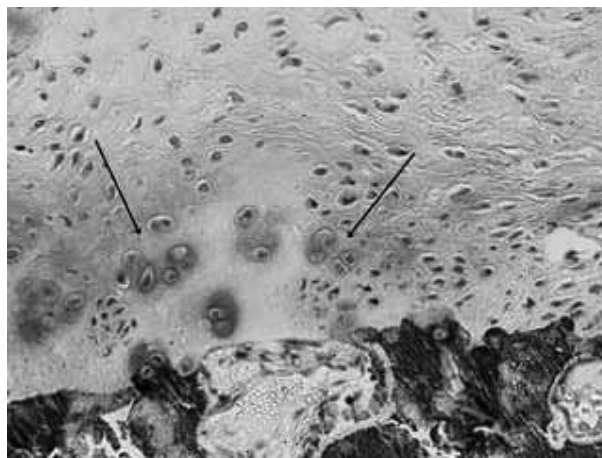


Fig. 2. Chondrocytic clusters (toluidin blue, magnification 400 X).

ters (Figure 2). Reparative tissue reached the level of normal cartilage. The edges of the defects showed the sites of bone reabsorption but the adjacent articular cartilage seemed unchanged and continuously bonded to the

TABLE 2
RESULTS IN BOTH GROUPS ACCORDING TO THE ICRS FEATURES WITH STATISTICAL ANALYSIS

ICRS score	After 6 weeks			After 10 weeks		
	Control Group	Experimental group	Statistics	Control Group	Experimental group	Statistics
Art. Surface	Number	Number	<i>P</i>	Number	Number	<i>P</i>
0	12	4	0.001*	6	3	0.581
3	0	8		7	9	
Matrix						
0	8	4	0.085	4	0	<0.001*
1	4	8		6	0	
2	0	0		2	12	
3	0	0		0	0	
Cell distr.						
0	12	3	<0.001*	8	0	0.039*
1	0	9		3	10	
2	0	0		1	2	
3	0	0		0	0	
Cell pop. Viabil.						
0	2	3	0.162	7	0	0.005*
1	10	7		5	11	
3	0	2		0	1	
Subcho. Bone						
0	4	1	0.256	3	0	<0.001*
1	8	11		9	0	
2	0	0		0	12	
3	0	0		0	0	
Cartil mineral.						
0	6	8	0.581	9	8	0.276
3	6	4		3	6	

* statistically, Pearson, χ^2 test or Fischers' exact test

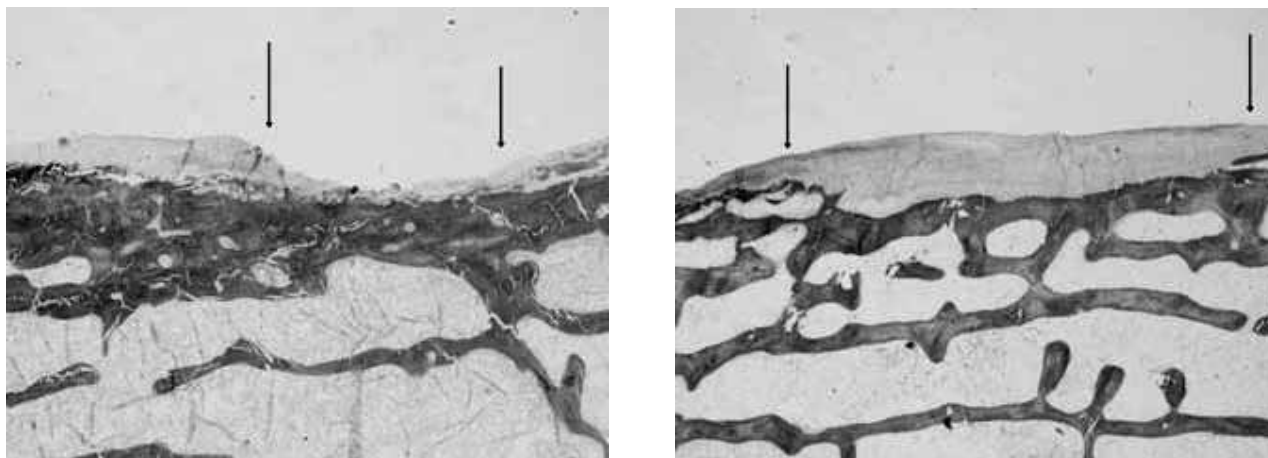


Fig. 3.a) Microphotograph of the histological section of articular cartilage defect reparative tissue in animal from the control group treated with microfracture only and b) animals from the experimental group treated with microfracture and hyaluronic acid, 10 weeks after injury (toluidin blue, magnification 100 X). The arrows indicate edges of the defect.

repair tissue that filled the defect. The bottom of the defect showed no clear demarcation line between the repair tissue and the underlying subchondral bone. The subchondral bones showed signs of increased remodeling (Figure 3a-b). Table 2 shows the number of joints for each histological feature for the control and the experimental groups scored by ICRS visual histological assessment with statistical analysis.

Analyzing Table 2, it is interesting to note that after the 6th week all joints in the control group had an irregular and discontinuous articular surface, while in the experimental group 8 joints had score 3, which means that surface of the articular cartilage was in continuity. Similar results were observed analyzing the cell distribution. The result was statistically significant. After the 6th week, there was no significant difference in any other feature of the ICRS scale between the two groups. Analyzing the joints after the 10th week, the difference was statistically significant in four of six features of the ICRS scale. It is important to observe that at this moment there was no difference between the control and the experimental group as regards the articular surface. The other feature which did not show any significant difference was cartilage mineralization.

Discussion and Conclusion

When an articular cartilage defect is treated with microfracture techniques as described by Steadman^{16,17} repair tissue is formed. Mechanical and biological micro-environmental factors in the joint contribute towards differentiating mesenchymal cell into cartilage tissue^{18–21}. The repair tissue formed by microfracture techniques consists predominantly of collagen type I, which resembles fibrocartilage and does not resist shear and compression loads as does normal hyaline cartilage. The method proved to be effective, showing a significant improvement in ability and symptom regression.

Another method used in treating the knee with cartilage breakdown, as in osteoarthritis, is the application of the hyaluronic acid²². Hyaluronic acid is a critical component of normal synovial fluid and an important contributor to joint homeostasis²³. The clinical benefits of intra-articular hyaluronic acid injections are supposed to occur through improved joint lubrication. While the physical properties of hyaluronic acid are important, there is evidence to suggest that hyaluronic acid may provide physiological, pharmacological and anabolic activity^{24–26}. Moreover it may have a great influence on chondrocyte activity and the ability to synthesize essential components of the articular cartilage extracellular matrix²⁷.

Analyzing the literature, we could find that only Kang et al. combined the microfracture techniques in with hyaluronan²⁸. The other parts of the protocol, which in our opinion can significantly influence the final results, were completely different. While Kang et al. used one-time application of hyaluronic acid stabilized with gel, our method of application was identical to the one used for patients in hospital and consisted of 5 intraarticular injections given once a week. It is well known that molecular mass can influence the result. We used the low molecular hyaluronan with of 500–730 kD, while others used the high molecular weight of 3000 kD. For evaluating the results we used the ICRS scale which can numerically describe the possible difference between the experimental and the control group.

Our study confirmed some benefits other than the physical properties of the hyaluronic acid itself. When, in our experimental group, pluripotent cells from a blood clot were exposed to hyaluronic acid, some biological activity was also observed.

Six weeks after the surgery only a minor difference between the two groups was observed: the experimental group had a smoother surface and the cells were more organized.

Ten weeks after the surgery, a significant improvement in almost all other features of the ICRS scale was observed in the experimental group (Table 2). This improvement consisted in the following: the reparative tissue reached the level of normal cartilage, while the tissue in the control group filled only the bottom of the defect; the reparative tissue was more organized and had a higher cellularity; the cells were organized in numerous clusters, indicating a better mitotic activity in the area of regeneration; and the subchondral bone in the experimental group showed increasing remodeling and tight

continuity with the repair tissue that fills the articular defect.

Hyaluronic acid is known to have a biological effect on chondrocytes and synoviocytes, but it appears to have the same effect on mesenchymal cells as well, as was shown in our experiment.

In conclusion, we can say that the combination of the two techniques used showed a significant improvement in healing cartilage defects.

REFERENCES

1. FASSBENDER, HG, Osteoarthritis – Diagnosis and Therapy (Springer Verlag, Heidelberg, 1988). — 2. CURLE, WW, KROME J, GORDAN ES, RUSHIGN J, SMITH BP, POEHLING GG, Arthroscopy, 13 (1997) 456. — 3. AROEN, A, LOKEN S, HEIR S, ALVIK E, EKELAND A, GRANLUND OG, ENGBRETTSEN L, Am J Sports Med, 32 (2004) 211. — 4. SIMON TM, JACKSON DW, Sport Med Arthrosc, 14 (2006) 146. — 5. BLEVINS FT, STEADMAN JR, RODRIGO JJ, SILLMAN JF, Orthopedics, 21 (1998) 761. — 6. HOIKKA VE, JAROMA HJ, RITSILA VA, Acta Orthop Scand, 61 (1990) 36. — 7. HANGODY L, KARPATI Z, Ortop Kezseb Plasztikai, 37 (1994) 237. — 8. BRITTEBERG M, LINDAHL A, NILSSON A, OHLSSON C, ISAKSSON O, PETERSON L, N Engl J Med, 331 (1994) 889. — 9. RODRIGO JJ, STEADMAN JR, SILLMAN JF, Am J Knee Surg, 7 (1994) 116. — 10. GILL TJ, ASNIS PD, BERKSON EM, J Orthop Sports Phys Ther, 36 (2006) 728. — 11. WANG CT, LIN J, CHANG CT, LIN YT, HOU SM, J Bone Joint Surg Am, 86 (2004) 538. — 12. PETRELLA RJ, PETRELLA M, J Rheumatol, 33 (2006) 951. — 13. BELLAMY N, CAMBELL J, ROBINSON V, GEE T, BOURNE R, WELLS G, Cochrane Database Syst Rev, 19 (2006) 5321. — 14. BRZUSEK D, PETRON D, Curr Med Res Opin, 24 (2008) 3322. — 15. MAINIL-VARLET P, AIGER T, BRITTEBERG M, J Bone and Joint Surg, 85 (2003) 45. — 16. STEADMAN JR, RODKEY WG, RODRIGO JJ, Clin Orthop Relat Res, 10 (2001) 362. — 17. GILL TJ, Am J Knee Surg, 13 (2000) 33. — 18. MILLWARD-SADLER SJ, SALTER DM, Ann Biomed Eng, 32 (2004) 446. — 19. O DRISCOLL SW, SALTER RB, Clin Orthop Relat Res, 208 (1986) 140. — 20. SETTON LA, MOW VC, MULLER FJ, PITA JC, HOWELL DS, Osteoarthritis Cartilage, 5 (1997) 16. — 21. FRIEDL G, SCHMIDT H, REHAK I, KOSTNER G, SCHAUENSTEIN K, WINDHAGER R, Osteoarthritis Cartilage, 15 (2007) 1300. — 22. FRIZZIERO L, GOVONI E, BACCHINI P, Clin Exp Rheum, 16 (1998) 441. — 23. WILLIAMS JM, RAYAN V, SUMMER DR, THONAR EJ, Journal of Orthopaedic Research, 21 (2003) 305. — 24. CHOW G, KNUDSON GB, HOMANDBERG G, KNUDSON W, J Biol Chem, 270 (1995) 27734. — 25. KNUDSON W, CASEY B, NIXHIDA Y, Arthritis Rheum, 43 (2000) 1165. — 26. MIGLIORE A, GRANATA M, Clin Interv Aging, 3 (2008) 369. — 27. AKMAL M, SINGH A, ANAND A, KESANI A, ASLAM N, GOODSHIP A, BENZLY G, Arthritis Rheum, 8 (2005) 1143. — 28. KANG SW, BADA LP, KANG CS, LEE JS, KIM CH, PARK JH, KIM BS, Biotechnol Lett 30 (2008) 439.

D. Legović

Orthopaedic University Hospital Louvan, M. Tita 1b, HR-51415 Louvan, Croatia
e-mail: dalen.legovic@inet.hr

LIJEČENJE OŠTEĆENJA HRSKAVICE KOLJENOG ZGLOBA TEHNIKOM MIKROFRAKTURA UZ INTRAARTIKULARNU PRIMJENU HIJALURONANA (NATRIJEVE SOLI HIJALURONSKE KISELINE) U KUNIĆA

SAŽETAK

Hrskavično tkivo ima slab potencijal cijeljenja. Predložene su brojne tehnike s ciljem ubrzanja poboljšanja kvalitete cijeljenja. U našem radu na zečijem modelu korištena je kombinacija kirurške tehnike mikrofraktura uz dodatak intraartikularne aplikacije soli hijaluronske kiseline. Nakon 6 odnosno 10 tjedana od kirurškog zahvata uočen je veći potencijal cijeljenja u eksperimentalnoj grupi uz stvaranje obilnijeg, celularnijeg i bolje organiziranog reparacijskog tkiva u hrskavičnom defektu. Zaključno možemo reći da kombinacija navedenih tehnika značajno unaprijeđuje cijeljenje lokaliziranih defekata zglobne hrskavice u koljenu zeca.