

# Spontaneous Regression of Intervertebral Disc Herniation - Case Reports

---

Rapan, Saša; Gulan, Gordan; Lovrić, Ivan; Jovanović, Savo

Source / Izvornik: **Collegium antropologicum, 2011, 35, 211 - 215**

Journal article, Published version

Rad u časopisu, Objavljena verzija rada (izdavačev PDF)

Permanent link / Trajna poveznica: <https://um.nsk.hr/um:nbn:hr:184:045091>

Rights / Prava: [In copyright](#)/[Zaštićeno autorskim pravom.](#)

Download date / Datum preuzimanja: **2025-02-05**



Repository / Repozitorij:

[Repository of the University of Rijeka, Faculty of Medicine - FMRI Repository](#)



# Spontaneous Regression of Intervertebral Disc Herniation – Case Reports

Saša Rapan<sup>1</sup>, Gordan Gulan<sup>2</sup>, Ivan Lovrić<sup>3</sup> and Savo Jovanović<sup>1</sup>

<sup>1</sup> »J. J. Strossmayer« University, Osijek University Hospital Center, Department of Orthopaedic Surgery, Osijek, Croatia

<sup>2</sup> University of Rijeka, School of medicine »Lovran« Clinic for Orthopaedic Surgery, Rijeka, Croatia

<sup>3</sup> »J. J. Strossmayer« University, Osijek University Hospital Center, Department of Traumatology, Osijek, Croatia

## ABSTRACT

*Lumbar disc hernia (LDH) is a common cause of low back pain and radicular leg pain. It is well known that the majority of LDH patients recover spontaneously. Since the advent of MRI, a spontaneous regression of fragment size of disc hernia occurs, as well as mitigation of subjective difficulties and neurological disorders. Therefore, surgical treatment is not always method of choice in this disease. Two cases of conservatively treated large disc extrusion which result in significant reduction of difficulties, with simultaneous reduction in fragment size of hernia which is documented by MR.*

**Key words:** disc herniation, spontaneous regression

## Introduction

Lumbar disc hernia (LDH) is a common cause of low back pain and radicular leg pain. It is well known that the majority of LDH patients recover spontaneously. Since the advent of MRI, a spontaneous regression of fragment size of disc hernia occurs, as well as mitigation of subjective difficulties and neurological disorders. Therefore, surgical treatment is not always method of choice in this disease. There are many cases in literature that describe such spontaneous regression of herniation occurring after non-surgical treatment. Two cases of conservatively treated large disc extrusion which result in significant reduction of difficulties, with simultaneous reduction in fragment size of hernia which is documented by MR.

## Case Report 1

A 27-year old lady, with lumbar pain lasting 3 months came to Department of Orthopaedics of Osijek University Hospital Center in 2006. At physical examination performed upon her arrival Lasegue test (straight leg rise) of n. ischiadicus was positive bilaterally but there was no symptoms motility disturbances on lower limbs. Her walking was normal, but the patient was continuously taking analgesics and anti-inflammatory drugs perorally and sometimes parenterally as well. Lower back MR, re-

vealed large dorsomedial protrusion of disc fragment at the L4-L5 level, with compression of dural sac (Figure 1).

As there was no neurological deficit, conservative treatment was recommended, with observation of neurological status, resting, analgesics and physical therapy. During next few months subjective difficulties reduced and the patients has taken analgesics only occasionally.

Control MR of lumbar spine in 2008, 12 months after difficulties occurred, showed total regression of the herniated disc fragment, without any signs of pressure on dural sac but with significant reduction in intervertebral L4-L5 area (Figure 2) which was seen in MR also in April 2010 (Figure 3).

## Case Report 2

A 32-year old male, with 6 months long difficulties in lower back and along the left leg was examined at Department of Orthopaedics of Osijek University Hospital Center in December 2008. Pains spread along the lower leg all the way to the foot with tingling in the first toe of the same foot.

The lumbar spine MR showed extruded disc fragment, L5-S1, dorsolaterally left, which compressed the S1 root, left (Figure 4).

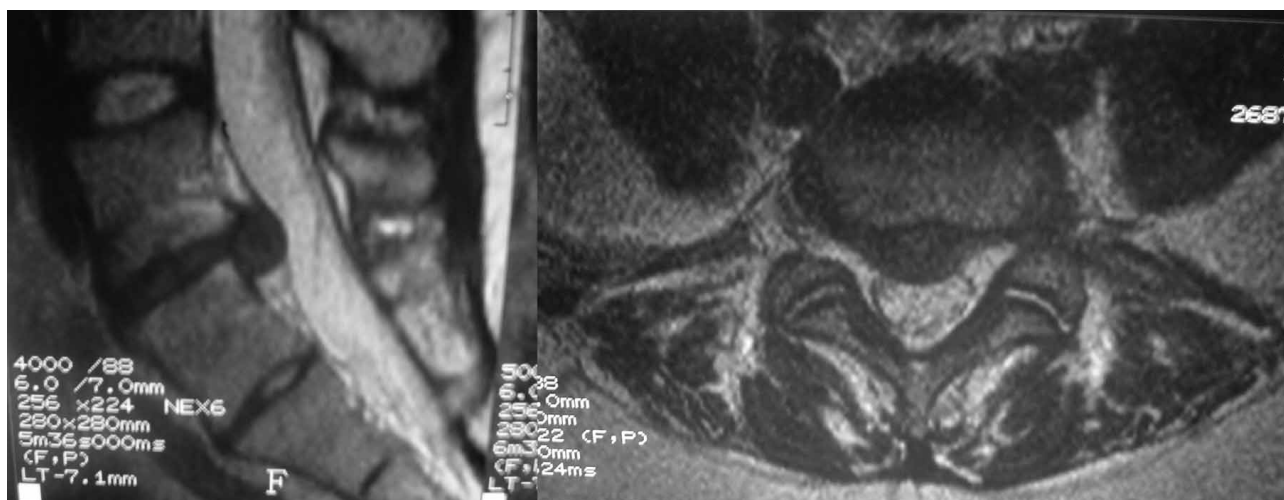


Fig 1. MRI shows disc hernia with intact posterior longitudinal ligament.

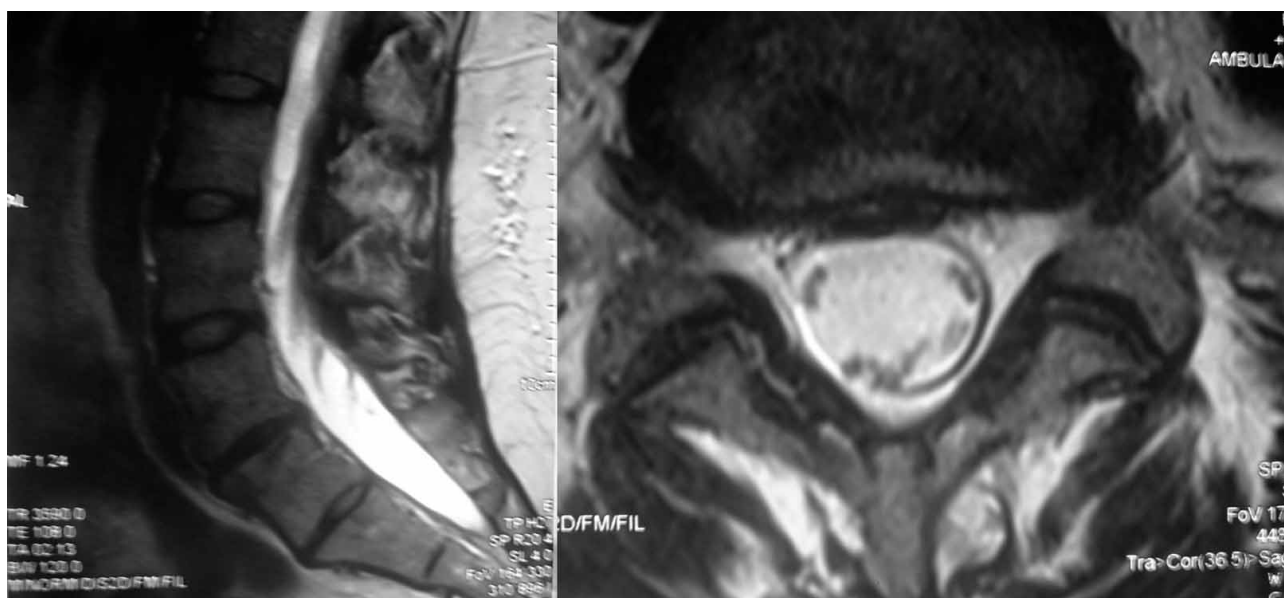


Fig. 2. MRI taken after 12 months shows spontaneous regression, with development of degenerative changes of intervertebral segment.

The patient postponed proposed surgical treatment for private reasons and meanwhile, he commenced conservative treatment.

One year later, i.e. in 2009 the patient came to control examination, almost without any difficulties, with control MR report showing regression of the extruded disc part, without any significant loss of intervertebral L5-S1 area (Figure 5).

## Discussion

So far there are 3 current theories of possible regression mechanism or reduction in i.v. disc herniation.

Dehydration theory starts from the assumption that detached fragment gradually loses water and shrinks.

Resorption theory argues the idea of tissue dissolving by enzymes and phagocytosis due to inflammatory reaction and neovascularization as autoimmune response to the fragment in spinal canal which is registered by immune system as a foreign body.

This theory is supported by numerous studies which reported neovascularization at fragment periphery, presence of macrophages and T cells. Cell infiltration is more pronounced in the nucleus pulposus area than in the annulus fibrosus area.

Retraction theory explains possible repositioning of the fragment to intervertebral space. This theory is applicable only if disc protruded the annulus but is not detached from it.

Besides, larger fragments become smaller faster than smaller ones, probably due to water contained, which is simultaneously reflected in mitigated difficulties. This is explained by reduced fragment pressure on the nerve and reduced inflammatory reaction. Although maximum improvement of clinical manifestation is observed after a year, radiological changes take place beyond that period as well. Ahn SH has defined herniation ratio when analysing MR images for efficiency of conservative treatment. He concluded that the ratio shall be reduced by 20% and more to achieve more significant clinical improvement.

Splendiani point out that it takes 6 months for the fragment reduction of approx. 34.72%. Saal mentions level of success of non-operative therapy of disc herniation in about 90% of patients. Although most patients opt for non-operative treatment in the beginning, some of them still finally undergo surgical treatment due to progression of neurological injury or unbearable pains.

According to Weber, some 25% of patients undergo surgical treatment within one year from the beginning of conservative treatment, while other study showed the percentage of 15% within 3 months from beginning of treatment.

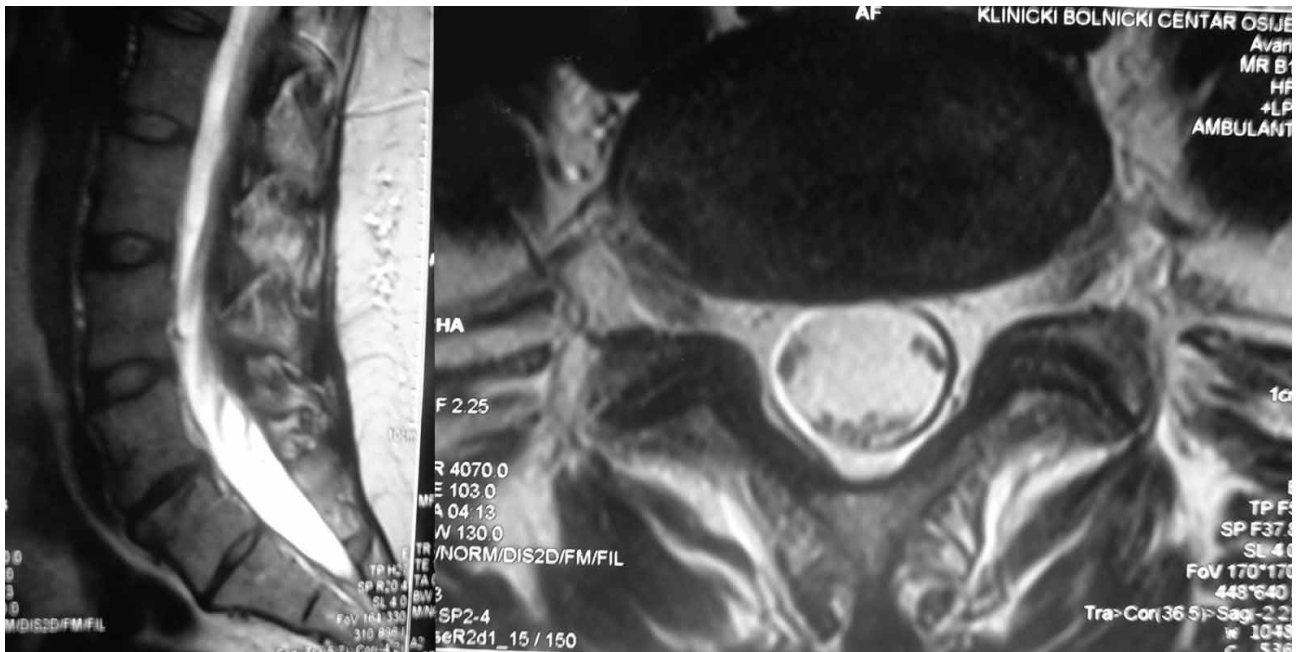


Fig. 3. No changes in MRI taken after 24 months compared to the one taken after 12 months.

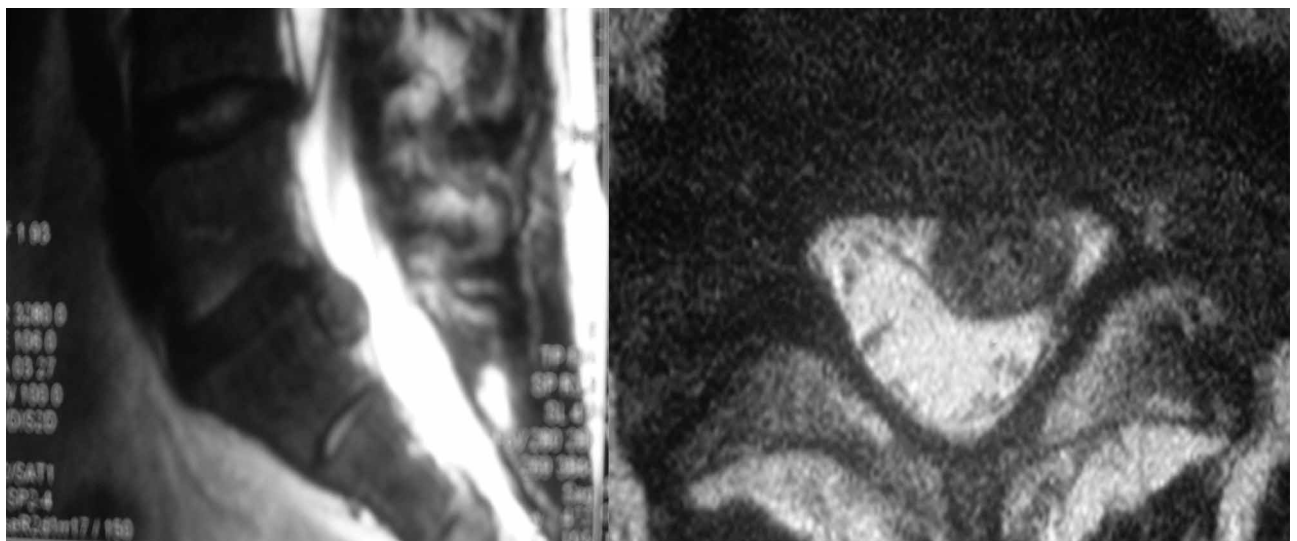


Fig. 4. MRI shows disc extrusion.



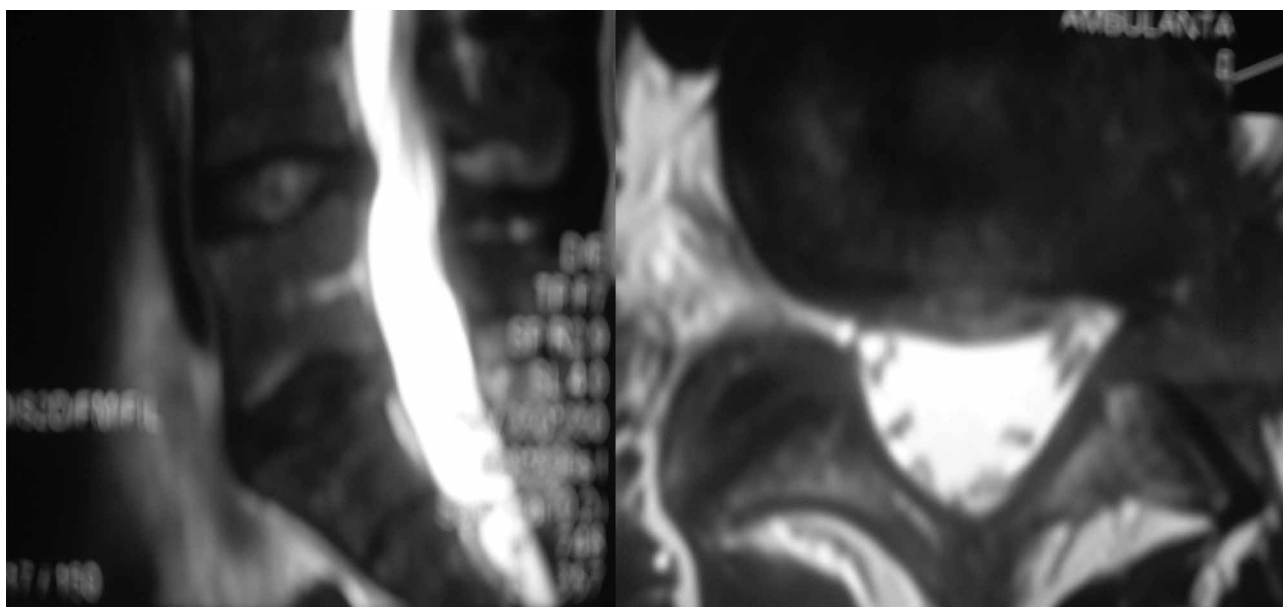


Fig. 5. MRI shows spontaneous regression, with intact intervertebral segment.

## Conclusion

In our 2 cases, spontaneous regression of disc fragment developed by dehydration or its resorption, and in the first case it is possible that it happened through retraction mechanism because it involved a protruded disc.

These cases show and confirm importance of earlier opinions that non-operative treatment can be sometimes applied successfully to large herniations.

Such treatment represents good initial option unless there are symptoms of neurological deficit, cauda equinae syndrome in the first place, provided a patient is able to tolerate pain and provided such treatment could be

harmonised with his/her social, work obligations in the first place.

I deem that the best treatment establishing good relationship between patient and physician, and which includes balance between conservative and surgical treatment. Surgical treatment should not be taken into account too early, except in cases of absolute indications and, but on the other side, conservative treatment should not cross the line beyond which it could have unrecoverable bad impact on surgical treatment.

In spite of successfulness of surgical and conservative treatment of disc herniation, there are still many unidentified factors that influence development, prognosis and treatment.

## REFERENCES

1. BOZZAO A, GALLUCCI M, MASCIOCCHI C, APRILE I, BARILE A, PASSARIELLO R, Radiology, 185 (1992) 135. — 2. BOROTA L, JONASSON P, AGOLLI A, Spine J, 8 (2009) 397. — 3. BUSH K, COWAN N, KATZ DE, GISHEN P, Spine, 17 (1992) 1205. — 4. FAGER CA, Surg Neurol, 42 (1994) 282. — 5. KOMORI H, SHINOMIYA K, NAKAI O, YAMURA I, TAKEDA S, FURUYA K, Spine, 15 (1996) 225. — 6. MAIGNE JY, DELIGNE L, Spine, 19 (1994) 189. — 7. REYENTOVICH A, ABDU WA, Spine, 27 (2002) 549. — 8. SAAL JA, SAAL JS, HERZOG RJ, Spine, 15 (1990) 668. — 9. SLAVIN KV, RAJA A, THORNTON J J, WAGNER FC JR, Surg Neurol, 56 (2001) 333. — 10. SEI A, NAKAMURA T, FUKUYAMA S, Rev Chir Orthop Reparatrice Appar Mot, 80 (1994) 144. — 11. HARO H, SHINOMIYA K, KOMORI H, OKAWA A, SAITO I, MIYASAKA N, FURUYA K, Spine, 14 (1996) 1647. — 12. KOMORI H, OKAWA A, HARO H, MUNETA T, YAMAMOTO H, SHINOMIYA K, Spine, 23 (1998) 67. — 13. SAKAI T T, TSUJI T, ASAZUMA T, YATO Y, MATSUBARA O, NEMOTO K, J Neurosurg Spine, 6 (2007) 574. — 14. YAMASHITA K,

HIROSHIMA K, KURATA A, Spine, 19 (1994) 479. — 15. MORANDI X, CROVETTO N, CARSIN-NICOL B, CARSIN M, BRASSIER G, Neurochirurgie, 45 (1999) 155. — 16. MARTINEZ-QUINONES JV, ASO-ESCARIO J, CONSOLINI F, ARREGUI-CALVO R, Neurocirugia, 21 (2010) 108. — 17. GEZICI AR, ERGUN R, Acta Neurochir, 151 (2009) 1299. — 18. AHN SH, AHN MW, BVU WM, Spina, 25 (2000) 475. — 19. LUTMAN M, GIRELLI G, Radiol Med, 81 (1991) 225. — 20. ITO T, YAMADA M, IKUTA F, Spine, 21 (1996) 230. — 21. DOITA M, KANATANI T, HARADA T, MIZUNO K, Spine, 21 (1996) 21. — 22. WOERNITGEN C, ROTHOERL RD, BRAWANSKI A, Spine, 25 (2000) 871. — 23. ARAI Y, YASUMA T, SHITOTO K, J Orthop Sci, 25 (2000) 229. — 24. TEPLICK JG, HASKIN ME, AJR, 145 (1985) 371. — 25. BUTTERMANN GR, J Spinal Disord Tech, 15 (2002) 469. — 26. SPLENDIANI A, PUGLIELLI E, DE AMICIS R, BARILE A, MASCIOCCHI C, GALLUCCI M, Neuroradiology, 46 (2004) 916. — 27. WEBER H, Spine, 8 (1983) 131. — 28. ATLAS SJ, KELLER RB, CHANG Y, DEYO RA, SINGER DE, Spine, 26 (2001) 1179.

*S. Rapan*

*»J. J. Strossmayer« University, Osijek University Hospital Center, Department of Orthopaedic Surgery, J. Huttlera 4,  
31000 Osijek, Croatia  
e-mail: sasa.rapan@gmail.com*

## **SPONTANA REGRESIJA HERNIJACIJE INTERVERTEBRALNOG DISKA – PRIKAZ SLUČAJA**

### **S A Ž E T A K**

Hernija intervertebralnog diska u lumbalnoj regiji čest je uzrok križobolje i bolova duž nogu. Zamijećeno je da i bez kirurškog tretmana, kroz neko vrijeme dolazi do spontane regresije veličine fragmenta hernije diska, a tako i do smanjenja subjektivnih tegoba i neuroloških poremećaja. Iz istog razloga, operacijsko liječenje nije uvijek metoda izbora ove bolesti. U ovom radu prikazat ćemo 2 slučaja velike ekstruzije diska koje su liječene konzervativno i kod kojih je došlo do značajnog smanjenja tegoba, uz istovremenu redukciju veličine fragmenta hernije, što je dokumentirano MR-om.