

# Keller's Arthroplasty with Proximal Metatarsal Opening Wedge Osteotomy in Treating Severe Hallux Valgus Deformity - Surgical Techniques and Case Report

---

Jurdana, Hari; Gulan, Gordan; Šestan, Branko; Legović, Dalen; Šantić, Veljko; Ravlić-Gulan, Jagoda; Roth, Sandor

Source / Izvornik: *Collegium antropologicum*, 2009, 33, 955 - 959

Journal article, Published version

Rad u časopisu, Objavljena verzija rada (izdavačev PDF)

Permanent link / Trajna poveznica: <https://um.nsk.hr/um:nbn:hr:184:607155>

Rights / Prava: [In copyright](#) / [Zaštićeno autorskim pravom](#).

Download date / Datum preuzimanja: **2024-12-30**



Repository / Repozitorij:

[Repository of the University of Rijeka, Faculty of Medicine - FMRI Repository](#)



# Keller's Arthroplasty with Proximal Metatarsal Opening Wedge Osteotomy in Treating Severe *Hallux Valgus* Deformity – Surgical Techniques and Case Report

Hari Jurdana<sup>1</sup>, Gordan Gulan<sup>1</sup>, Branko Šestan<sup>1</sup>, Dalen Legović<sup>1</sup>, Veljko Šantić<sup>1</sup>, Jagoda Ravlić-Gulan<sup>2</sup> and Sandor Roth<sup>3</sup>

<sup>1</sup> Clinic for Orthopaedic Surgery »Lovran«, School of Medicine, University of Rijeka, Rijeka, Croatia

<sup>2</sup> Department for Physiology and Pathophysiology, School of Medicine, University of Rijeka, Rijeka, Croatia

<sup>3</sup> Department of Children's Orthopaedics, University Hospital Center »Rijeka«, Rijeka, Croatia

## ABSTRACT

*The paper presents an operative technique proposed for treating severe Hallux Valgus deformity with arthrosis of the first metatarsal joint in elderly people. The procedure consists of the Keller's arthroplasty in combination with basal osteotomy of the first metatarsal bone, whereby the head of the metatarsal is displaced laterally and plantarward. The osteotomy is fixed with a reconstructive plate. The results show a significant improvement in the hallux valgus angle, the first metatarsal angle, as well as in the plantar pressure distribution.*

**Key words:** Hallux Valgus, Keller's arthroplasty, osteotomy

## Introduction

Severe *Hallux Valgus* deformity with concomitant arthrosis of the first metatarsophalangeal joint is a disabling condition which affects mostly individuals in the older age group. Because of the deformity, the patients suffer pain in the forefoot caused by transfer metatarsalgia and compression over the base of the *Hallux*. They often have footwear problems as well.

In 1904, Keller recommended a procedure for treating *Hallux Valgus* which consists of a partial resection of the proximal phalanx<sup>1</sup>. In 1929 Brandes included to it resection of the pseudoexostosis on the medial side of the first metatarsal head<sup>2</sup>. However, as the first metatarsophalangeal joint is sacrificed in it, this operation should be reserved for individuals with degenerative arthritis of the joint and a less demanding activity.

The Keller procedure offers a number of advantages, including technical simplicity, satisfactory pain relief and easy postoperative care<sup>3</sup>, but various complications can also be associated with it<sup>4,5</sup>. In our experience, complications associated with this operation included persistent transfer metatarsalgia and shoe-wear limitation, which are most pronounced in this group of patients.

These complications are due to a high first intermetatarsal angle with metatarsus primus varus which could not be corrected by the Keller's procedure alone.

Osteotomy performed at almost every level of the first metatarsal bone, aimed at diminishing and correcting the high first intermetatarsal angle, has already been described. Proximal opening wedge osteotomy of the metatarsal bone was first described by Trethowan in 1923<sup>6</sup>.

In 1957 Stamm et al. described an operation which involved a combination of Keller's arthroplasty, McBride procedure and opening wedge osteotomy at the base of the first metatarsal bone for all age groups<sup>7</sup>. The foot was immobilised in plaster with a long postoperative period.

In this paper, we present a surgical technique which consists of the Keller's arthroplasty in combination with two plane basal osteotomy of the first metatarsal for moderate to severe *Hallux Valgus* deformity with concomitant arthrosis of the first metatarsophalangeal joint. The osteotomy was fixed with rigid fixation, which offers faster recovery with fewer complications.

## Indications and Contraindications

This type of surgical procedure is indicated in the elderly with a severe *Hallux Valgus* deformity (HV angle  $>35^\circ$ , first IM angle  $>15^\circ$ ), callosities under metatarsal heads and advanced osteoarthritic changes of the first metatarsophalangeal joint. Contraindications include young patients, physically active patients, and patients with an active infection, extensive peripheral vascular disease and neuropathies.

## Operative Procedure

### Patients preparation

The operation is performed using regional anaesthesia. The patient is positioned supine on the operating table and the leg is prepared by draping in the standard fashion. The surgeon stands on the opposite side of the operated leg. A tourniquet is applied to the thigh, the leg is exsanguinated and the tourniquet inflated to 350 mmHg.

### Medial approach

A longitudinal incision is centred over the medial eminence and extended from the midportion of the proximal phalanx to a point 2 cm proximal to the medial eminence (Figure 1). The incision is deepened along this line through the subcutaneous tissue to the capsule and then carefully extended in dorsal and plantar directions.

Care is taken to identify and protect the medial dorsal cutaneous nerve. An elliptical capsular incision is performed to expose the eminence. The incision is extended in proximal and distal directions of the remaining capsule for a better exposition of the bones (Figure 2).

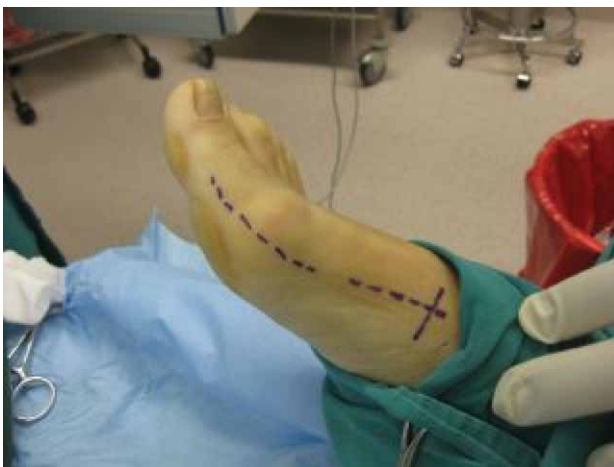


Fig. 1. A longitudinal incision is centered over the medial eminence and extended from the midportion of the proximal phalanx to a point 2 cm proximal to the medial eminence. A second incision, about 4 cm in length, is centered over the medial aspect of the first metatarsal starting from the first cuneiform-metatarsal joint.

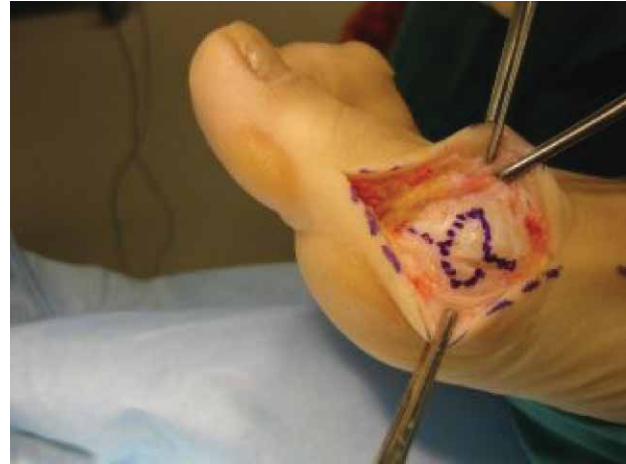

Fig. 2. Elliptical shaped capsular incision over metatarsophalangeal joint with proximal and distal extension.

The base of the proximal phalanx is freed of the soft tissue with a knife and a rasp and mobilised (Figure 3). Care is taken not to damage the flexor tendon of the *Hallux*. The base of the proximal phalanx is resected by saw, mostly removing about one-third of the phalanx only.

The sagittal sulcus on the metatarsal head is identified. It alone is an unreliable reference point for resection of the medial eminence. With a small medial eminence, the sulcus may represent the actual site of the osteotomy; with a more severe deformity, however, the sulcus may have migrated too far laterally to be used as a reference point and bone resection at this point would be excessive. The medial eminence is resected with the sagittal saw starting

in line with the medial cortex of the first metatarsal shaft. Excessive resection should be avoided as it may lead to *Hallux Varus* deformity. Sharp edges are removed with a rongeur (Figure 4).

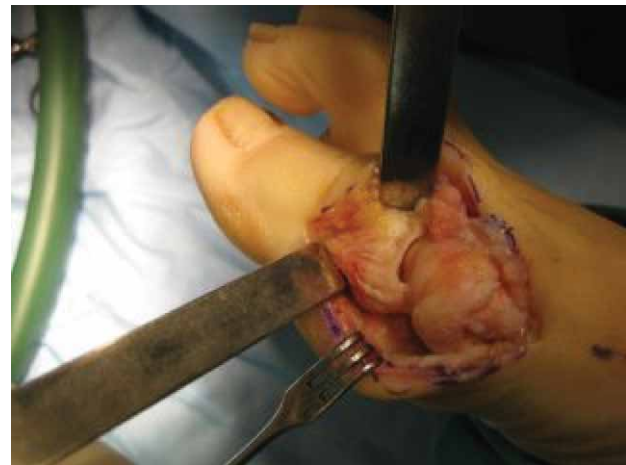

Fig. 3. Exposed metatarsophalangeal joint.

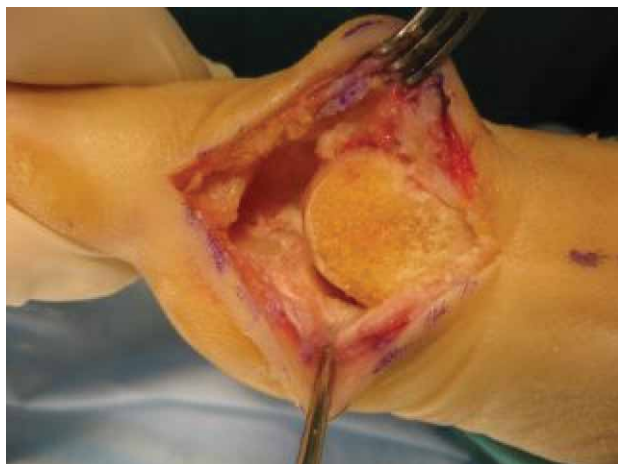

Fig. 4. Medial part of the metatarsal head after resection of pseudoexostosis.

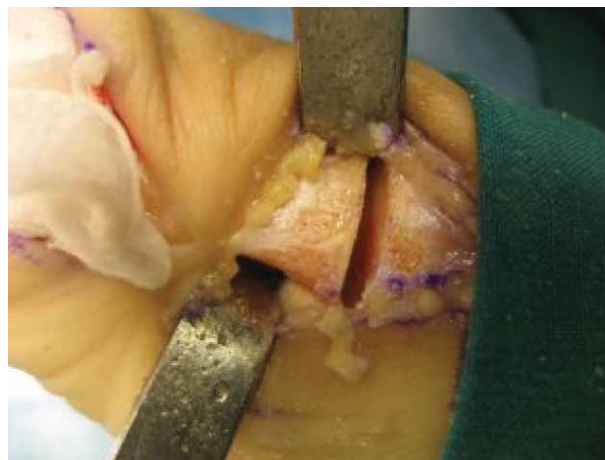


Fig. 6. Opened gap after performed osteotomy with remaining part of the cortical bone in plantar and lateral part which serve as a hinge.

### Proximal Osteotomy of the First Metatarsal

A second incision, about 4 cm in length, is centred over the medial aspect of the first metatarsal starting from the first cuneiform-metatarsal joint, which is located by moving the first metatarsal (Figure 1). After identification of the joint, the needle is placed as orientation marker. Account must be taken of the joint direction, which runs obliquely from proximal and medial to distal and lateral. The incision is deepened to the metatarsal shaft and the periosteum is reflected with an elevator. The Hohmann retractor is placed subperiosteally around the base of the first metatarsal. The site of the osteotomy is signed at about 1–1.5 cm from the medial joint line, in the region of metaphysis (Figures 5 and 6).

Distal to the signed line, K-wire is introduced between the sagittal and coronal planes (in an oblique direction). It is advisable to pass both cortices. Osteotomy is initi-

ated with the sagittal saw in a direction parallel to the K-wire and carefully advanced to the plantar and lateral cortex, which must remain intact to serve as a hinge when a gap opens after osteotomy. By manipulating the K-wire, which serves as a joystick, the gap is opened by pushing the distal part in the lateral and plantarward direction. By this manoeuvre and with a hinge on the plantar and lateral part of the first metatarsal, correction can be made in two planes: frontal and sagittal. The bone which has been removed from the metatarsal head is modulated in a triangular shape and introduced into the metatarsal gap (Figures 7 and 8).

The osteotomy site is stabilized with a small L or T shaped plate with 5 holes (Figure 9).

### Closure

Following osteotomy, the medial capsule is imbricated with vicryl No. 2 over the resected metatarsophalangeal

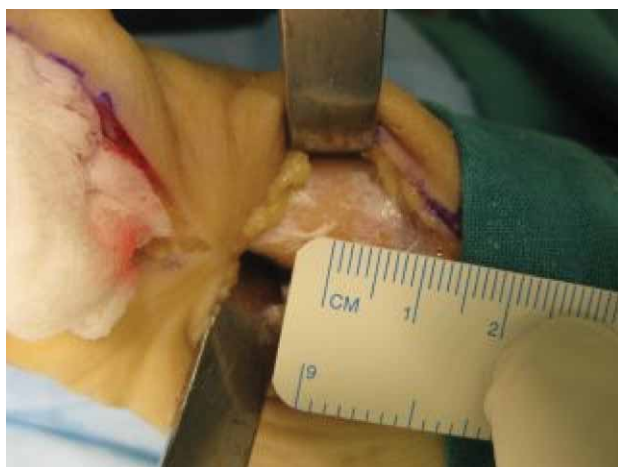


Fig. 5. The osteotomy is situated about 1–1.5 cm proximal to metatarsal-cuneiform joint.

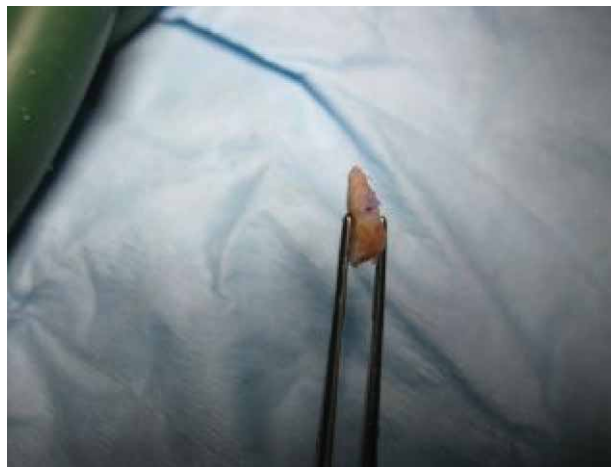

Fig. 7. Bone removed from pseudoexostosis modulated in a triangular shape.



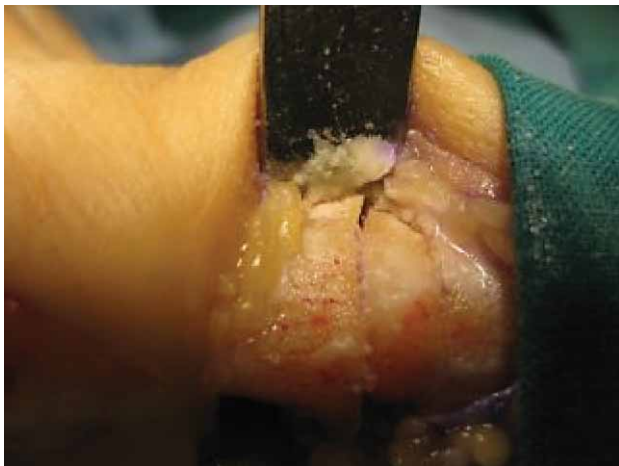

Fig. 8. Introduced bone in osteotomy gap.

joint and, by proper tensioning, the proximal phalanx is placed in the proper position. The skin is closed with ethilone No. 3 or with resorptive fibre.

### Postoperative Period

After closure of the wound of the above procedure, a dry dressing is applied at the conclusion of the operation to hold the *Hallux* and the metatarsal in proper alignment. The patient wears a postoperative rigid-soled shoe and is allowed to walk with crutches, bearing weight on the heel and the lateral aspect of the foot. One or two days following the surgery, the compression dressing is changed. Radiographs are made immediately and six weeks after the surgery, if adequate healing of the osteotomy site is noted radiographically, the patients is allowed to full weight bearing in hard sole shoe.

Passive and active range of motion exercises are commenced ten days following the surgery. The length in

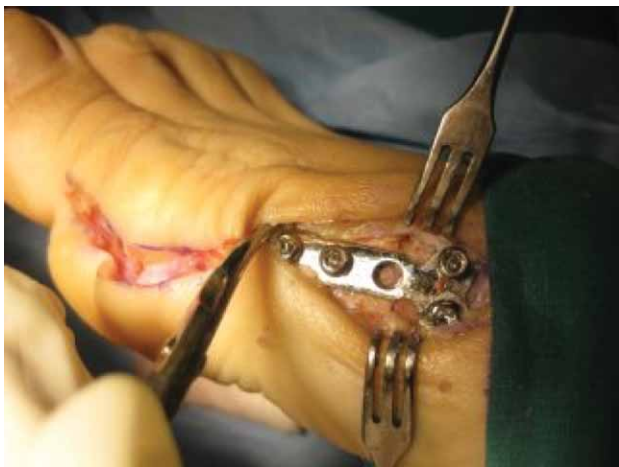


Fig. 9. Osteotomy is stabilised with T or L shape plate with 5 holes.

hospital ranges from 2-4 days. Sutures are removed 14 days after surgery.

### Case Report

A 68-year-old woman presented with symptomatic *Hallux Valgus* deformity of her right foot. She had a pronounced »bump« on the medial side of the metatarsal head with skin redness over it. She suffered great pain in the forefoot and had a pronounced shoe wear problem. Callosities over the plantar side of the metatarsal head were also present.

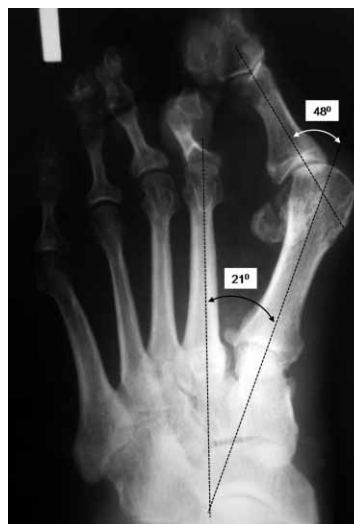

Fig. 10. Preoperatively plain radiograp in full weight bearing position showed intermetatarsal angle of 21° and Hallux Valgus angle of 48°. The subluxation with arthritic changes in metatarsophalangeal joint are also noted.

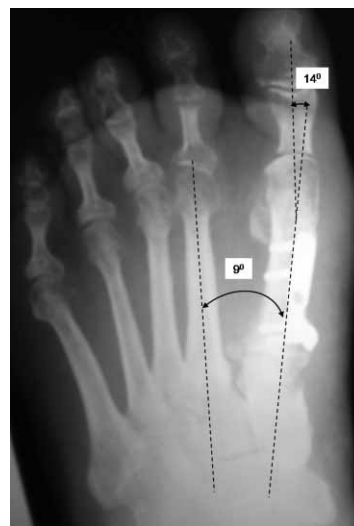

Fig. 11. Plain radiography in full weight bearing position eight weeks after operation, show intermetatarsal angle of 9° and Hallux Valgus angle of 14° with bony union.

At clinical examination, the motion in the metatarsophalangeal joint of the Hallux was reduced and painful with crepitation.

Plain radiography in full weight bearing position showed a *Hallux Valgus* angle of 48° and the first intermetatarsal angle of 21°. Osteoarthritic changes of the first metatarsophalangeal joint were also present with subluxation in the joint (Figure 10).

We performed Keller's excisional arthroplasty with a proximal opening wedge osteotomy of the first metatarsal, using the technique and postoperative management as described above.

After 8 weeks we observed clinical and radiographic union and the patient was walking in a normal shoe.

Plain radiography taken at this moment showed an excellent reduction of deformity, with the first intermetatarsal angle of 9° and the *Hallux Valgus* angle of 14°, which represent normal values (Figure 11). We did not observe any complications. The patient was extremely happy with the result.

## Conclusion

The Keller' arthroplasty with opening wedge osteotomy, which we presented here, is a technically easier and reproducible procedure, and a useful surgical method in treating severe *Hallux Valgus* deformity in the elderly.

## REFERENCES

1. KELLER WL, New York Med J, 80 (1904) 741. — 2. BRANDES M, Zbl Chir, 56 (1929) 2434. — 3. MACHACEK F, EASLEY ME, GRUBER F, RITSCHL P, TRNKA HJ, J Bone Joint Surg, 86 (2004) 1131. — 4. ANDERL W, KNAHR K, STEINBOCK G, Z Orthop Ihre Grenzgeb, 129 (1991) 129. — 5. AXT M, WILDNER M, REICHEL T A, Arch Orthop Traumatol Surg, 112 (1993) 266. — 6. TRETOWAN J, Hallux valgus. In: CHOYCE CC (Eds) A system of surgery (New York, 1923). — 7. STAMM TT, Guys Hosp Rep, 106 (1957) 273.

G. Gulan

Clinic for Orthopaedic Surgery »Lovran«, M. Tita, 51415 Lovran, Croatia  
e-mail: gordang@medri.hr

## EKSCIZIJSKA ARTROPLASTIKA PO KELLERU UZ OSTEOTOMIJU OTVARANJA BAZE PRVE METATARZALNE KOSTI U LIJEČENJU UZNAPREDOVALOG *HALLUX VALGUSA* – KIRURŠKA TEHNIKA I PRIKAZ SLUČAJA

### SAŽETAK

U ovom radu prikazana je operacijska tehnika namjenjena liječenju *Hallux Valgus* deformiteta s uznapredovalim artrotskim promjenama prvog metatarzofalangealnog zgloba. Operacija se sastoji u kombinaciji ekscizijske artroplastike po Kelleru u kombinaciji s osteotomijom otvaranja u području baze prve metatarzalne kosti pri čemu se glavica metatarzalne kosti pomiče prema lateralno i plantarno. Mjesto osteotomije se fiksira pločicom L ili T oblika s 5 otvora. Rezultati ove operacijske tehnike pokazuju značajno smanjenje prvog intermetatarzalnog kuka i kuta *Hallux Valgusa* kao i preraspodjelu plantarnog opterećenja stopala.