

Osteochondritis Dissecans of the Medial and Lateral Femoral Condyles affecting Adult Knee

Gulan, Gordan; Mokrović, Hrvoje; Ravlić-Gulan, Jagoda; Cicvarić, Tedi; Marinović, Marin; Bakota, Bore; Bandalović, Ante

Source / Izvornik: **Collegium antropologicum, 2014, 38 Supplement 1, 249 - 252**

Journal article, Published version

Rad u časopisu, Objavljena verzija rada (izdavačev PDF)

Permanent link / Trajna poveznica: <https://um.nsk.hr/um:nbn:hr:184:027130>

Rights / Prava: [In copyright](#)/[Zaštićeno autorskim pravom.](#)

Download date / Datum preuzimanja: **2025-03-29**



Repository / Repozitorij:

[Repository of the University of Rijeka, Faculty of Medicine - FMRI Repository](#)



Osteochondritis Dissecans of the Medial and Lateral Femoral Condyles affecting Adult Knee

Gordan Gulan¹, Hrvoje Mokrović¹, Jagoda Ravlić-Gulan², Tedi Cicvarić³, Marin Marinović³, Bore Bakota⁴ and Ante Bandalović⁵

¹ University of Rijeka, School of Medicine, Clinic for Orthopaedic Surgery Lovran, Lovran, Croatia

² University of Rijeka, School of Medicine, University Hospital Rijeka, Department of Physiology, Immunology and Pathophysiology, Rijeka, Croatia

³ University of Rijeka, School of Medicine, University Hospital Rijeka, Department of Traumatology, Rijeka, Croatia

⁴ General Hospital Karlovac, Department of Traumatology, Karlovac, Croatia

⁵ University of Split, University Hospital Centre Split, Department of Traumatology, Split, Croatia

ABSTRACT

We report the first case of osteochondritis dissecans (OCD) affecting a large area of lateral and medial femoral condyles with adult-onset in the same knee of the 22-year old professional athlete with respect to result of applied therapeutic procedure. After a clinical examination, radiograph and magnetic resonance imaging showed a huge bicondylar OCD. Through arthrotomy, the osteochondral fragment was fixed with biodegradable pins combined with two threaded 4 mm cobalt-chrome cancellous screws. By using this surgical fixation procedure, osteochondral fragments healed completely, which is evidenced arthroscopically one year after a new trauma episode which resulted in the lateral meniscus reinjury. According to our knowledge this is the first reported case of bicondylar OCD affecting adult knee. In the rare case of such a large osteochondral defect, when fixation with biodegradable pins could be insufficient, a combination with cancellous screws can bring good results, even in professional athletes.

Key words: osteochondritis dissecans, bicondylar osteochondral defects, adult onset, therapy

Introduction

Osteochondritis dissecans (OCD) is a condition characterised by a localised lesion of the articular cartilage and underlying subchondral bone with partial or complete separation of the fragment. In 80% of cases it occurs in the knee, and is usually unilateral (74%). The most common localisation is the posterolateral section of the medial femoral condyle (80%). Other sites include the ankle, elbow and wrist^{1,2}. Various theories have been proposed regarding the etiology of the OCD including trauma³, subchondral ischemia⁴, ossification defects⁵ and genetic causes⁶.

There are two forms of OCD – the juvenile and the adult form. Usually, OCD occurs before the age of 18 and is twice as common in males as it is in females.

Patients with focal cartilage lesions have major problems with pain and functional impairment. Their complaints are worse than those of patients with anterior

cruciate ligament-deficient knees, and quality of life is affected to the same extent as in patients scheduled for knee replacement. If not diagnosed in time, it can progress to degenerative joint disease⁷.

Herewith we describe the case of the adult form of OCD affecting both condyles of the same knee, and the results of applied method of treatment. As far as we know, bicondylar OCD in the same knee has already been described only in one paper⁸, but it refers to two cases of a juvenile form. Our paper is, to the best of our knowledge, the first to describe an adult form of bicondylar OCD in the same knee.

Case reports

A 22-year old male presented to the orthopaedic surgeon with a history of recurring episodes of pain and

swelling of the right knee. The symptoms started three years earlier with no history of direct trauma to the knee. Episodes of lock-in occurred in the right knee followed by more intense episodes of pain and swelling. At this stage the patient came to our clinic. Upon clinical examination, the knee showed pain and tenderness on both sides, with a positive balottement test. The range of motion was reduced. Radiograph and magnetic resonance imaging (MRI) of the right knee were carried out. The radiograph showed OCD lesion affecting both femoral condyles (Figure 1).

The MRI showed a larger defect in the lateral femoral condyle occupying zones 4th and 5th according to Cahill⁹ on the antero-posterior view, and zone C in the lateral view. The defect of the medial femoral condyle was smaller (Cahill's 2nd zone on the antero-posterior view and zone B in the lateral view) comparing to lateral femoral condyle lesion. Arthroscopy of the right knee was performed and a deep unstable osteochondral fragment involving almost the entire weight-bearing surface of the lateral femoral condyle was revealed. Lesion of the lateral meniscus was also present. Arthroscopic partial lateral meniscectomy was performed.

Because the osteochondral defect was very large, arthrotomy was done (Figure 2). After debriding the base of the defects, we fixed the lateral osteochondral frag-

ment with two cancellous screws and one biodegradable pin, while fixation of the medial osteochondral fragment was done with one screw (Figure 3).

After surgical treatment the patient started with early rehabilitation. Rehabilitation exercises with emphasis on limb function and muscle recruitment were initiated after 48 hours and continued for 8 weeks. Weight bearing was gradually introduced into the patient's rehabilitation schedule, and the patient progressed to full weight bearing after 8 weeks.

Three months after arthroscopy, radiographs showed satisfactory healing on the site of the osteochondral fragments and the screws were removed.

One year after the operation the patient had full-range motion in the right knee with no effusion or discomfort. But, during a sports activity he twisted his right knee which started to lock again limiting the range of movement. He was again referred to our clinic. The radiograph was unremarkable (Figure 4). Arthroscopy was performed. The operation revealed the lesion of the lateral meniscus which had been partially removed during the first arthroscopy; this time subtotal meniscectomy of lateral meniscus was performed. The osteochondral fragments on both condyles were healed and there were no signs of new cartilage defect. After 2 years, neither knee pain nor arthrosis has occurred.

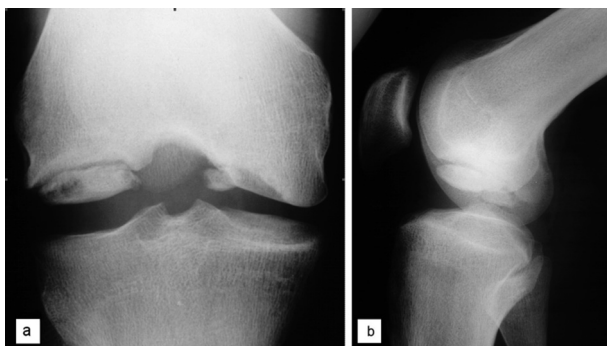


Fig. 1. Antero-posterior (a) and lateral (b) plain radiographs of the right knee that showed existence of huge osteochondritis dissecans defects in both femoral condyles.

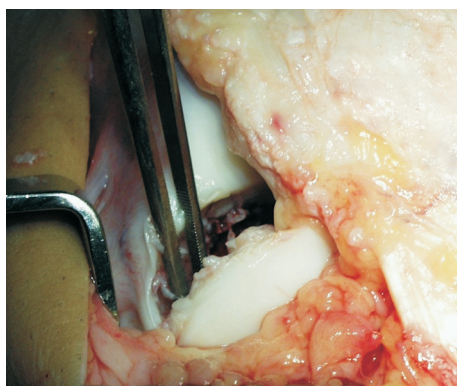


Fig. 2. A view on osteochondral fragment that occupied almost entire lateral femoral condyle of the right knee before fixation.

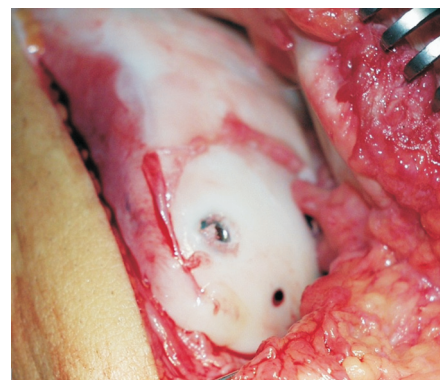


Fig. 3. A view on lateral femoral condyle after the fixation of the osteochondral fragment was done by two cancellous screws and one resorbable pin.

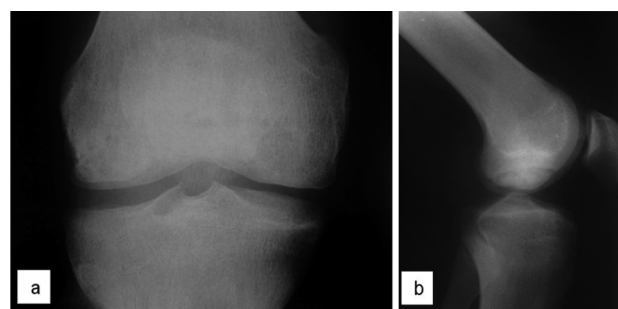


Fig. 4. Antero-posterior (a) and lateral (b) plain radiographs of the right knee one year after fixation of osteochondral fragments demonstrating good results of healing process in both femoral condyles.

Discussion

The exact etiology of OCD is presently unknown. Reported incidence of OCD is between 0.02–0.03% on a survey of knee radiographs^{1,10}. The highest rates appear among patients aged between 10–15 years, affecting male twice common than female. In 15% of the cases both knees are involved, but typically in different phases of development¹¹.

The separation of OCD of the knee into juvenile and adult form is clinically relevant as the two pathologic conditions have distinctly different clinical courses. Juvenile OCD has a much better prognosis than does adult OCD, with higher rates of spontaneous healing after conservative therapy^{11–14}.

As far as we know, until now there was no published paper describing adult form of OCD of both condyles in the same knee. Hanna SA et al⁸ reported two cases describing bicondylar OCD in the same knee affecting young boys with opened physis.

In our case, there is one more feature yet undescribed. The localization of OCD in medial femoral condyle in our patient corresponds with most frequently reported location in the knee. On the other hand, the OCD of lateral femoral condyle was huge affecting almost all weight-bearing surface and was loose. Until now, all reported OCD of lateral femoral condyle were juvenile form, and in combination with lateral discoid meniscus. Mizuta H. et al¹⁵ reported the development of OCD after lateral meniscectomy in all patients that underwent meniscectomy of lateral discoid meniscus. Mitsuoka T. et al.¹⁶ studied the features of the OCD affecting lateral and medial femoral condyles and observed that all patients with lateral OCD were in growing period, average younger than group with medial OCD, and all had damaged lateral discoid meniscus. Three of them were ruptured, while in other three the lesion were intrasubstantially. The other studies also observed the development of OCD after lateral discoid meniscectomy^{17,18}. In our patient, adult form of OCD in the lateral femoral condyle was combined with the damage of previously normal-shaped

meniscus. It could be only speculative discussion what first developed, but the damage of lateral meniscus was not extensive. Only middle part of lateral meniscus was damaged.

Exact factors causing lateral OCD are unknown and remain speculative. Various etiology were proposed. Some authors suggested that damaged discoid meniscus could cause repetitive stress on weaker osteochondral structure¹⁵, but Oni DB et al¹⁹ studied the characteristics of lateral femoral condyle in the presence of discoid meniscus and found no difference in articular cartilage thickness comparing to the medial condyle and concluded that mechanical disturbances wrought by the discoid shape do not have a »Wolff law« effect.

There are various proposed treatment methods of the osteochondral defect, which include fixation of the fragment with Herbert screws or cancellous screws²⁰ and biodegradable pins²¹, mosaicplasty²², autologous chondrocyte implantation^{23,24}, anterograde and retrograde drilling²⁵ and osteochondral allograft transplantation^{26–29}. If the fragment is unstable and large, restoration of the articular surface should be attempted by fixation, as in our case. We used fixation with compression by cancellous screws and biodegradable pins which showed good results, and the osteochondral fragments healed completely. After a further trauma episode arthroscopically confirmed by the lateral meniscus injury, the fixed osteochondral fragment showed no lesion.

Conclusion

We can conclude that in the rare case of such a large osteochondral defect, when fixation with biodegradable pins could be insufficient, a combination with cancellous screws can bring good results, even in professional athletes. We hope that some of unique features that we observed in our patient could possibly help in understanding and explaining the etiology of OCD in future as well as for future treatment.

REFERENCES

- LINDON B, *Acta Orthop Scand*, 47 (1976) 664. — 2. SCHENCK RC, Jr, GOODNIGHT JM. *J Bone Joint Surg Am*, 78 (1996) 439. — 3. SMILLIE IS, *Osteochondritis dissecans: Loose bodies in joints: Etiology, pathology, treatment.* (E and S Livingstone, Edinburgh, 1960) — 4. REDDY AS, FREDERICK RW, *Am J Sports Med*, 26 (1998) 415. — 5. RIBBING S. *Acta Orthop Scand*, 24 (1955) 286. — 6. CRAWFORD DC, SAFRAN MR, *J Am Acad Orthop Surg*, 14 (2006) 90. — 7. HEIR S, NERHUS TK, RØTTERUD JH, LØKEN S, EKELAND A, ENGBRETTSEN L. *Am J Sports Med*, 38 (2010) 231. — 8. HANNA SA, ASTON WJ, GIKAS PD, BRIGGS TW, *J Bone Joint Surg*, 90 (2008) 232. — 9. CAHILL BR. *J Am Acad Orthop Surg*, 3 (1995) 237. — 10. BRADLEY J, DANDY DJ, *J Bone Joint Surg Br*, 71 (1989) 518. — 11. HEFTI F, BEGUIRISTAIN J, KRAUSPE R, MOLLER-MADSEN B, RICCIO V, TSCHAUNER C, *J Pediatr Orthop B*, 8 (1999) 231. — 12. CAHILL BR, PHILLIPS MR, NAVARRO R, *Am J Sports Med*, 17 (1989) 601. — 13. CLANTON TO, DELEE JC, *Clin Orthop Relat Res*, 167 (1982) 50. — 14. TWYMAN RS, DESAI K, AICHROTH PM, *J Bone Joint Surg Br*, 73 (1991) 461. — 15. MIZUTA H, NAKAMURA E, OTSUKA Y, KUDO S, TAKAGI K, *Arthroscopy*, 17 (2001) 608. — 16. MITSUOKA T, SHINO K, HAMADA M, HORIBE S, *Arthroscopy*, 15 (1999) 20. — 17. LIM HC, BAE JH, *J Med Case Reports*, 5 (2011) 434. — 18. STANITSKI CL, BEE J, *Am J Sports Med*, 32 (2004) 797. — 19. ONI DB, JEYAPALAN K, ONI OO, *Knee*, 18 (2011) 202. — 20. CETIK O, TURKER M, USLU M, *Knee Surg Sports Traumatol Arthrosc*, 13 (2005) 468. — 21. DIN R, ANNEAR P, SCADDAN J, *J Bone Joint Surg Br*, 88 (2006) 900. — 22. MINIACI A, TYTHERLEIGH STRONG G, *Arthroscopy*, 23 (2007) 845. — 23. KRISHNAN SP, SKINNER JA, CARRINGTON RW, FLANAGAN AM, BRIGGS TW, BENTLEY G, *J Bone Joint Surg Br*, 88 (2006) 203. — 24. PETERSON L, MINAS T, BRITTBURG M, LINDHAL A, *J Bone Joint Surg Am*, 85-A (2003) 17. — 25. AGLIETTI P, BUZZI R, BASSI PB, FIORITI M, *Arthroscopy*, 10 (1994) 286. — 26. BEAVER RJ, MAHOMED M, BACKSTEIN D, DAVIS A, ZUKOR DJ, GROSS AE, *J Bone Joint Surg Br*, 74 (1992) 105. — 27. GHAZAVI MT, PRITZKER KP, DAVIS AM, GROSS AE, *J Bone Joint Surg Br*, 79 (1997) 1008. — 28. MAHOMED MN, BEAVER RJ, GROSS AE, *Orthopedics*, 15 (1992) 1191. — 29. MARCACCI M, KON E, ZAFFAGINI S, VISANI A, *Orthopedics*, 22 (1999) 595.

G. Gulan

Clinic for Orthopaedic Surgery Lovran, M. Tita 1, 51415 Lovran, Croatia

e-mail: gordang@medri.hr

DISECIRAJUĆI OSTEOHONDRITIS MEDIJALNOG I LATELARNOG KONDILA BEDRENE KOSTI U KOLJENU ODRASLE OSOBE

S A Ž E T A K

Prikazali smo prvi slučaj disecirajućeg osteohondritisa (OHD) koji je zahvatio veliku površinu lateralnog i medijalnog kondila bedrene kosti u odrasle osobe. Promjene su se dogodile u istostranom koljenu kod 22-godišnjeg profesionalnog sportaša. Nakon kliničkog pregleda, radiološka obrada i magnetska rezonancija pokazali su izražen bikondilarni DOH. Artroskopskim postupkom, osteohondralni fragment je fiksiran s biorazgradivim pinom u kombinaciji s dva 4 mm kobalt-krom spongiozna vijka. Korištenjem ovog kirurškog postupka fiksacije, osteohondralni fragmenti su u potpunosti zacijelili, što se potvrdilo artroskopski nakon godinu dana od prve ozljede. Tada je pacijent uslijed nove traumatske epizode zadobio leziju lateralnog meniska. Prema našim saznanjima ovo je prvi slučaj bikondilarnog OHD u odraslom koljenu. U rijetkim slučajevima velikog osteohondralnog defekta, kada fiksacija biorazgradivim pinom može biti nedovoljna, kombinacija sa spongioznim vijcima može donijeti dobre rezultate, čak i kod profesionalnih sportaša.