

Open Total Talar Dislocation with Extrusion (Missing Talus)

Gulan, Gordan; Šestan, Branko; Jotanović, Zdravko; Mađarević, Tomislav; Mikačević, Marijan; Ravlić-Gulan, Jagoda; Rapan, Saša; Jovanović, Savo

Source / Izvornik: **Collegium antropologicum, 2009, 33, 669 - 672**

Journal article, Published version

Rad u časopisu, Objavljena verzija rada (izdavačev PDF)

Permanent link / Trajna poveznica: <https://um.nsk.hr/um:nbn:hr:184:833487>

Rights / Prava: [In copyright](#)/[Zaštićeno autorskim pravom.](#)

Download date / Datum preuzimanja: **2024-08-30**



Repository / Repozitorij:

[Repository of the University of Rijeka, Faculty of Medicine - FMRI Repository](#)



Open Total Talar Dislocation with Extrusion (Missing Talus)

Gordan Gulan¹, Branko Šestan¹, Zdravko Jotanović¹, Tomislav Mađarević¹, Marijan Mikačević¹, Jagoda Ravlić-Gulan², Saša Rapan³ and Savo Jovanović³

¹ Clinic for Orthopaedic Surgery Lovran, School of Medicine, University of Rijeka, Rijeka, Croatia

² Department of Physiology and Pathophysiology, School of Medicine, University of Rijeka, Rijeka, Croatia

³ Department of Orthopaedic Surgery, School of Medicine, University of Osijek, Osijek, Croatia

ABSTRACT

Open total dislocation of a talus with extrusion (missing talus) is an extremely rare injury. We present a case of a 63-year-old male who sustained an open total lateral dislocation of the right talus with extrusion and without a concomitant fracture after a fall from a small height. Tibiocalcaneonavicular arthrodesis was performed. Arthrodesis failed, and due to painful and unstable ankle, rearthrodesis was performed two years later, successfully. Because of rarity of this kind of injury, here its importance for foot function, previously described various treatment options and absence of guidelines, herewith we propose, according to our experience and review of literature, the algorithm for the treatment of this rare injury.

Key words: talus, dislocations, arthrodesis

Introduction

A complete dislocation of the talus from the ankle mortise without a concomitant fracture is a very rare injury¹. Choice of treatment, because of the rarity of this kind of injury, has been controversial and various treatments have been used². We presented here a very rare case of an open total lateral dislocation of the talus with extrusion and without a concomitant fracture which was ultimately treated successfully with tibiocalcaneonavicular arthrodesis. This case report analyzes previous reports in the literature and gives a proposal of treatment recommendations in similar cases.

Case Report

A 63-year-old male with medical history of the right ankle dislocation presented to the emergency department of another hospital after sustaining the right ankle injury after a fall from a 1,5 m height onto the ground. He reported a fall on an inverted foot. He also noticed an open wound at the lateral aspect of his ankle with fully extruded talus in his sock. He denied losing consciousness or sustaining any other injuries. At admission, he

was in moderate distress due to pain and oriented to person, place and time. Vital signs were stable. Examination of the right foot and ankle revealed medial dislocation of the foot and ankle and an open wound at the lateral aspect of the ankle. There was no evidence of neurovascular imperiling. Computed tomography (CT) scans of the right ankle revealed a complete dislocation of the talus from tibiotalar, subtalar and talonavicular articulations without a concomitant fracture (Figure 1a and b). The patient was administered passive and active anti-tetanic prophylaxis and antimicrobial prophylaxis (crystal penicillin and gentamicin). After the preoperative preparation, the patient was taken to the operating room and surgery was performed on the same day as the injury occurred. All capsuloligamentar structures at the lateral aspect of the right ankle were ruptured. The talus was missing. The dorsal neurovascular bundle and tendons were intact. After debridement and antibiotic irrigation of the open wound, an immediate tibiocalcaneal arthrodesis using an external fixator and tibionavicular arthrodesis with a screw were performed. The wound was closed primarily. Postoperatively, the patient was mobili-

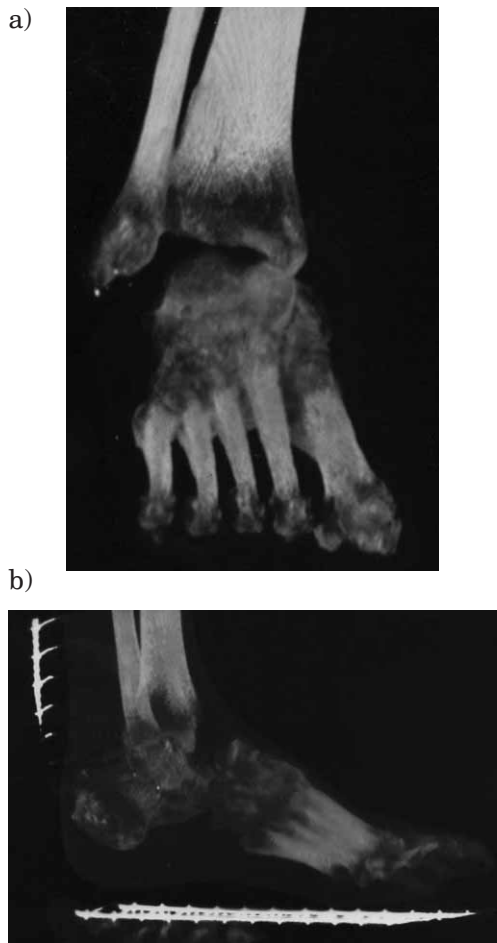


Fig. 1. a) and b) Frontal and lateral CT of the ankle, taken immediately after injury, showed total talar dislocation.

zed with two crutches and with recommendation on non-weight bearing on the right lower extremity. The wound healed primarily without any signs of infection.

Twenty six months after the operation, the patient was admitted to our hospital because of a painful, edematous and unstable ankle, vicious position of the foot and leg shortening. Roentgenograms revealed failed arthrodesis (Figure 2). After preoperative preparation, tibio-calcaneonavicular rearthrodesis with autogenous bone graft was performed by using an external fixator. During surgery, we noticed residual cartilage on the articular surface of the tibia and calcaneus which had not been removed properly during the first operation. After complete removal of the cartilage, previously mentioned operation was done. Postoperatively, the patient was mobilized with two crutches and with the recommendation on nonweight-bearing on the right lower extremity.

Ten months after the second operation, roentgenograms showed bone consolidation in the region of arthrodesis (Figure 3). The patient was without symptoms, unrestricted in any daily work. The patient achieved good results ten months after the reoperation.

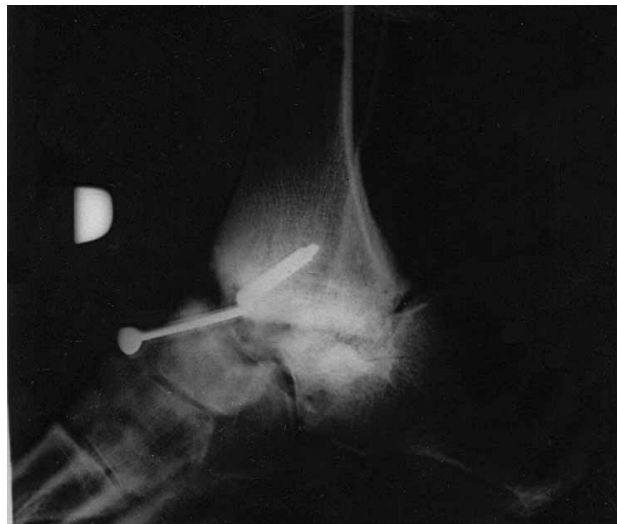

Fig. 2. Lateral radiographs of the ankle 26 months after first operation showed failed arthrodesis.

Discussion

Total dislocation of the talus (i.e. tibiotalar, talonavicular and talocalcaneal disruption) is an uncommon injury and has been reported in approximately 0.06% of all dislocations and 2% of all talar injuries^{3,4}. It is an extremely rare injury because of its deep position in the foot, the strong ligamentous support and the amount of force required for its dislocation^{5,6}. Total talar dislocation is usually an open injury⁵. The talus is predisposed to dislocation because of its anatomical characteristic: it is the only bone in the lower extremity without muscle attach-

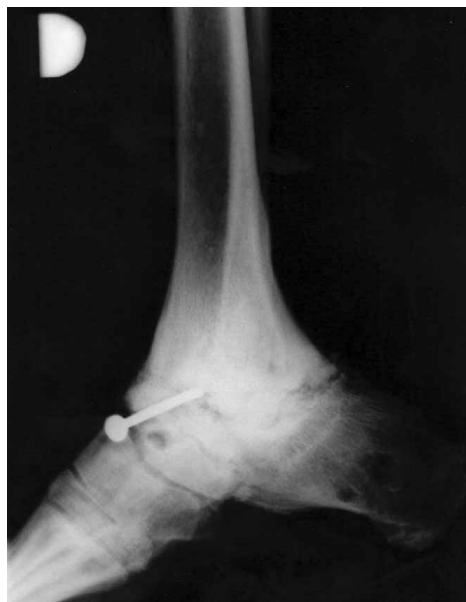

Fig. 3. Lateral radiographs of the ankle 10 months after second operation showed bone consolidation in the arthrodesis region.

ments and three-fifths of its surface is articular⁷. According to Leitner, subtalar dislocation is a preliminary stage in total talar dislocation. Severe supination or inversion forces lead to medial subtalar dislocation (first-degree supination injury) followed by talocrural subluxation (second-degree supination injury), which finally results in total lateral dislocation of the talus⁸.

In our case, the patient sustained several dislocations of the right ankle in his medical history. The finale cause of talar extrusion in the present case was a fall on the inverted and plantar flexed foot from a small height. It resulted in a rupture of the lateral capsule and lateral structures with a lateral dislocation of the talus from the ankle mortise. This injuries were probably results of a previously subtalar dislocations and talocrural subluxations (in combination or separate) that ultimately resulted in total talar dislocation.

Initial treatment recommendations in the case of total dislocation of the talus are different. Some authors recommend, because of possible infection, damage of talar vascularity and consequent avascular necrosis (AVN), primary talectomy with tibiocalcaneal arthrodesis, even in the case of a closed talar dislocation². However, primary talectomy affects hindfoot function and limits subsequent reconstructive options⁹.

Because of that, others advocate preservation of talus unless he is not extruded out of the wound or the wound is extremely contaminated. Than, consideration may be given to primary excision of the talus¹⁰. In a case of infection, secondary talectomy and tibiocalcaneal arthrodesis can give satisfactory results^{11,12}.

Recent papers suggest reimplantation of the talus whenever it is possible because it may restore joint mechanics, hindfoot height and bone stock for future reconstructive procedures⁹. Results of talar reimplantation are promisingly. Three separate case reports, two published 1997^{10,13} and a last one 2004 with five-year follow-up¹⁴, showed successful reimplantation of the talus. Talus survived reimplantation despite no soft-tissue connections and five years after showed subchondral sclerosis and joint-space narrowing anteriorly without evidence of osteonecrosis or talar body collapse¹⁴. Infection rates in the cases of talar reimplantation vary from 10–100%^{9,12,15}. Carefully soft-tissue handling, multiple debridements, use of external fixation either to temporize or stabilize the soft-tissue envelope and early soft-tissue closure may have contributed to the relatively low infection rate⁹. Another problem after talar reimplantation are collapse or osteonecrosis of the talus or osteoarthritis of the ankle or the subtalar joint⁹. Collapse or osteonecrosis of the talus require subsequent procedures after talar reimplantation. In that case, according to some authors, fusion between the sclerotic talus and the tibia or calcaneus is more difficult to achieve^{12,16}. However, opposite of them, Schulze et al. successfully performed an arthrodesis in three ankles, five combined ankle and subtalar joints, and one talonavicular joint despite osteonecrosis of the talus¹⁷.

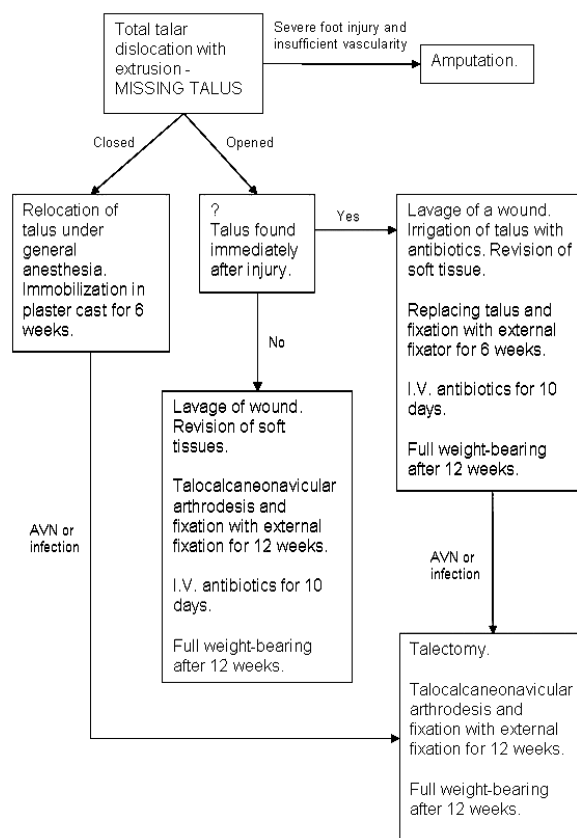


Fig. 4. Proposal of treatment algorithm for total talar dislocation with extrusion (missing talus).

Recently has been described an alternative approach for treatment of an extruded talus, in which a metal prosthesis is shaped according to the dimensions of the lost talus in combination with total ankle arthroplasty¹⁸. In this case, open talar dislocation was associated with loss of the medial malleolus and complete disruption of the deltoid ligament, which limited the treatment options^{2,19}. Twenty-eight months after, there was no evidence of loosening or migration of the implant with good medium-term functional results.

Because of rarity of this kind of injury, hers importance for foot function, previously described various treatment options and absence of guidelines, we propose, according to our experience and review of literature, treatment algorithm for total talar dislocation with extrusion (missing talus) (Figure 4).

The only treatment that can be done in this situation is primary tibiocalcaneonavicular arthrodesis of the compression type. We believe that the reason for failure of primary tibiocalcaneonavicular arthrodesis in our patient is incomplete removal of the cartilage from the articular surface of the tibia and calcaneus, what is basic postulate for intraarticular arthrodesis. Arthrodesis, as the procedure of choice in this case, produce a painless foot. Because of leg shortening, the patient always needs a shoe lift.

Conclusion

Open total dislocation of the talus with complete extrusion and without a concomitant fracture is an ex-

tremely rare injury that can be successfully treated, if there is no talar bone, with primary tibiocalcaneonavicular arthrodesis of the compression type.

REFERENCES

1. SEGAL D, WASILEWSKI S, *J Bone and Joint Surg*, 62 (1980) 1370.
- 2. DE'ETENBECK LC, KELLY PJ, *J Bone and Joint Surg*, 51 (1969) 283.
- 3. LEITNER B, *Ergebn Chir Orthop*, 38 (1952) 93.
- 4. SCHUIND F, ADRIANNE Y, BURNY F, DONKER-WOLCKE M, SARIC O, *Acta Orthop Belg*, 49 (1983) 652.
- 5. HIRAIZUMI Y, HARA T, TAKAHASHI M, MAYEHI S, *Foot Ankle*, 13 (1992) 473.
- 6. MAFFULLI N, FRANCOBANDIERA C, LEPORE L, CIFARELLI V, *J Foot Surg*, 28 (1989) 208.
- 7. BONNIN JG, *British J Surg*, 28 (1940) 88.
- 8. LEITNER B, *J Bone and Joint Surg*, 37 (1955) 89.
- 9. SMITH CS, NORK SE, SANGEORZAN BJ, *J Bone Joint Surg Am*, 88 (2006) 2418.
- 10. PALOMO-TRAVER JM, CRUZ-RENOVELL E, GRANELL-BELTRAN V, MONZONIS-GARCIA J, *J Orthop Trauma*, 11 (1997) 45.
- 11. KENWRIGHT J, TAYLOR RG, *J Bone Joint Surg Br*, 52 (1970) 36.
- 12. MARSH JL, SALTZMAN CL, IVERSON M, SHAPIRO DS, *J Orthop Trauma*, 9 (1995) 371.
- 13. BREWSTER NT, MAFFULLI N, *J OrthopTrauma*, 11 (1997) 42.
- 14. ASSAL M, STERN R, *J Bone Joint Surg Am*, 86 (2004) 2726.
- 15. JAFFE KA, CONLAN TK, SARDIS L, MEYER RD, *Foot Ankle Int*, 16 (1995) 583.
- 16. SANDERS DW, BUSAM M, HATTWICK E, EDWARDS JR, MCANDREW MP, JOHNSON KD, *J Orthop Trauma*, 18 (2004) 265.
- 17. SCHULZE W, RICHTER J, RUSSE O, INGELFINGER P, MUHR G, *Acta Orthop Scand*, 73 (2002) 344.
- 18. MAGNAN B, FACCI E, BARTOLOZZI P, *J Bone Joint Surg Am*, 86 (2004) 1778.
- 19. HECKMAN JD, *Fractures and dislocations of the foot*. In: ROCKWOOD CA, GREEN DP, BUCHOLZ RW (Eds) *Rockwood and Green's fractures in adults* (Lippincott, Philadelphia, 1991).

G. Gulan

Clinic for Orthopaedic Surgery Louvan, School of Medicine, University of Rijeka, M. Tita 1, 51415 Louvan, Croatia
e-mail: gordang@medri.hr

DISLOKACIJA TALUSA S EKSTRUZIJOM (ODSUTNOST TALUSA) UZ PRIKAZ SLUČAJA I PREGLED LITERATURE

SAŽETAK

Otvorena totalna dislokacija talusa s ekstruzijom je izrazito rijetka ozljeda. Prikazujemo slučaj šezdestogodišnjeg muškarca koji je zadobio otvorenu totalnu lateralnu dislokaciju desnog talusa s ekstruzijom, bez pratećeg prijeloma, nakon pada s male visine. Primarno je učinjena tibiokalkaneonavikularna artrodeza. Poradi neuspjele artrodeze, te bolnog i nestabilnog gležnja, dvije godine kasnije, uspješno je učinjena reartrodeza. Zbog rijetkosti ovakve vrste ozljede, njezine važnosti za funkciju stopala, prethodno opisanih različitih vrsta liječenja i odsutnosti smjernica liječenja, predlažemo, na osnovu našeg iskustva i pregleda literature, algoritam liječenja za ovu rijetku vrstu ozljede.