

# Multiple Recurrence of Hydatid Disease Lasted 19 Years

---

Miletić, Bojan; Matanić, Dubravka; Kurpis, Marina; Flego, Veljko

Source / Izvornik: **Collegium antropologicum, 2009, 33, 1397 - 1399**

Journal article, Published version

Rad u časopisu, Objavljena verzija rada (izdavačev PDF)

Permanent link / Trajna poveznica: <https://um.nsk.hr/um:nbn:hr:184:811202>

Rights / Prava: [In copyright](#)/[Zaštićeno autorskim pravom.](#)

Download date / Datum preuzimanja: **2025-01-27**



Repository / Repozitorij:

[Repository of the University of Rijeka, Faculty of Medicine - FMRI Repository](#)



# Multiple Recurrence of Hydatid Disease Lasted 19 Years

Bojan Miletić<sup>1</sup>, Dubravka Matanić<sup>2</sup>, Marina Kurpis<sup>2</sup> and Veljko Flego<sup>2</sup>

<sup>1</sup> »Thalassotherapia«, Opatija, Croatia

<sup>2</sup> Department of Pulmology, University Hospital Center Rijeka, Rijeka, Croatia

## ABSTRACT

*Hydatid disease (echinococcosis) is a potentially fatal parasitosis caused by tapeworm larvae of the genus Echinococcus which affects primarily the liver and the lungs. However, despite effective medical and surgical treatment, risk of recurrence remains the main problem in the treatment of the disease. We describe here a rare case of multiple recurrence of hydatid disease that lasted more than 19 years. The patient presented with multiple cysts of the liver and dissemination to the lung. The way of dissemination remained unclear and speculative. Despite surgical and intensive medical treatment the disease progressed and the patient died in septic shock.*

**Key words:** *hydatid disease, Echinococcus granulosus, treatment*

## Introduction

Hydatid disease (echinococcosis) is a zoonosis caused by tapeworm larvae of the genus *Echinococcus* in the Mediterranean countries mostly by species *Echinococcus granulosus*. It affects primarily the liver and the lungs. Although medical and surgical treatment can potentially cure the disease, risk of recurrence remains the main problem in the treatment of hydatid disease. We describe here a rare case of recurrent hydatid disease that lasted more than 19 years.

## Case Report

A 51-year-old-man presented with dry cough, fever and chest pain lasted more than one month was admitted to hospital. Prior to hospitalization he was unsuccessfully treated with different antimicrobial drugs. He worked in a warehouse. Nineteen years ago he was operated for cystic hydatid disease of the right liver lobus and then twice again during the following year because of new liver cysts which appeared at the same localisation. Two years later four cysts of the mediastinal pleura and one

cyst of the right lung were discovered and surgically removed. Four years later, thoracotomy and phrenotomy were performed and multiple cysts of the left lung and left lobus of the liver were removed. This operation was complicated by pleural empyema. The patient was regularly radiologically followed during the next three years. He was asymptomatic for over 12 years. Upon hospitalisation, initial chest radiography and CT scans showed bilateral multiple nodular infiltrates of the lung indicating again the hydatid disease recidiv (Figure 1 and 2). Abdominal CT scans showed the same changes in the left lobus of the liver (Figure 3). The presumptive diagnosis was supported by indirect haemagglutination test on *Echinococcus granulosus*. The laboratory analyses showed elevated sedimentation rate – 56 (normal range-NR-2–10 mm/h), alkaline phosphatase – 138 (NR 34–104 U/L) and gamaglutamyl transferase – 733 (NR 7–32 U/L); other laboratory findings were within normal limits. Blood cultures were negative. Fiberoptic bronchoscopy demonstrated extramural compression of the left inferior lobe and upper right lobe of the lung. Microbio-

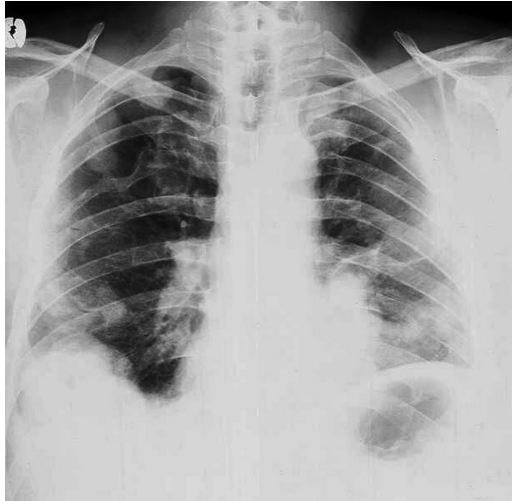


Fig. 1. Multiple nodular infiltrates of the lung on chest radiography.

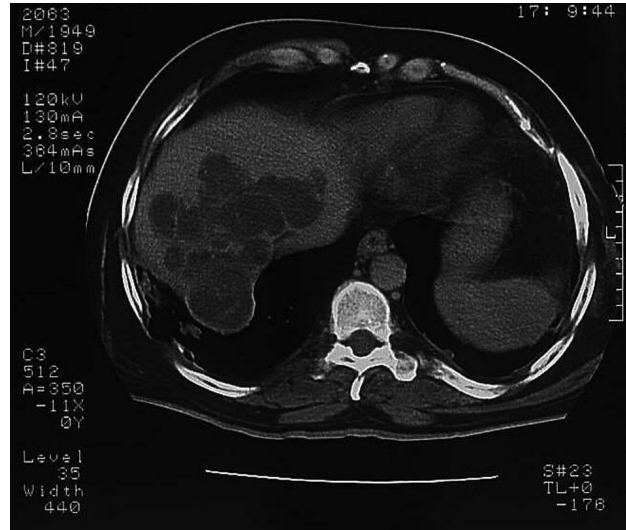

Fig. 3. Nodular infiltrates of the liver on computer tomography.

logical and cytological examinations of the specimens obtained by bronchial washing were negative. Because of the disease progression and high operative risk the patient received albendazol. One week later he became afebrile and the operation was planned. However, clinical worsening occurred during the next two weeks and the patient got again high fever with productive cough and haemoptysis and finally died with signs of respiratory failure and septic shock. The autopsy confirmed pulmonary and liver cystic hydatid disease with no sign of transdiaphragmatic rupture.

### Discussion

The patient presented lived during childhood in Dalmatia (Croatia), known as an endemic *Echinococcus gra-*

*nulosus* hydatidosis area<sup>1,2</sup>. In most cases the liver (75%) and lungs (15%) were primarily affected<sup>1,3-5</sup>. Our patient presented with non-specific respiratory symptoms-cough, fever, haemoptysis and chest pain. We followed standard diagnostic procedure that includes chest radiography, CT and serological testing<sup>6</sup>. Xanthakis DS et al reported that primary rupture of the liver hydatid cysts into the pleural cavity is rare<sup>7</sup>. In our case the haematogenous dissemination or transdiaphragmatic migration could be the most probable causes of dissemination of the disease<sup>8</sup>. However, the intravascular rupture and haematogenous spread of protoscolex via the hepatic veins into the lungs as a mechanism of diffuse intrapulmonary dissemination is still to be discussed.

Our patient underwent various surgical treatments several times during seven years of treatment, 12 years before present hospitalisation. Surgical treatment can potentially be curative and remains the treatment of choice. The type of surgical intervention depends on the form of disease<sup>9</sup>. The operative mortality rate is low (1-2%), as well as the recurrence rate (1-3%)<sup>6</sup>. Medical treatment before and after surgery additionally minimises the risk of recurrence<sup>10</sup>. Kir A et al. described a recurrence of a pulmonary cyst in only one patient of 23 who were operated because of simultaneous liver and pulmonary cysts<sup>11</sup>. On the other hand, Gollackner B et al. described a higher recurrence rate in 9 of 60 patients (15%) at an interval of 3 months to 20 years from the first operation<sup>12</sup>. The relapses may inevitably occur in hydatid surgery. However, we could not find any similar case of hydatid disease, recurring so many times over so long a period of more than 19 years despite repeated surgical and medical treatment. Our patient did not perform any radiological control for nine years. Regular and long-term follow-up, especially in endemic areas, timely diagnosed disease recurrence and aggressive treatment can be crucial for such patients.

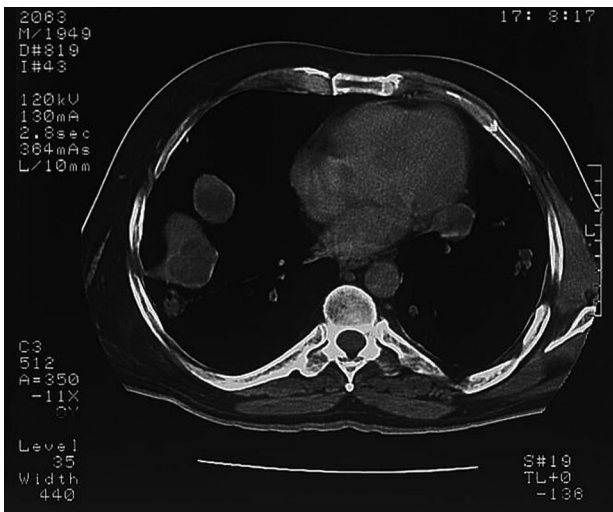


Fig. 2. Multiple nodular infiltrates of the lung on computer tomography.

## REFERENCES

1. CÖL C, CÖL M, LAFCI H, Acta Med Austriaca, 30 (2003) 61. — 2. MOROVIC M, Epidemiol Infect, 119 (1997) 271. — 3. SUMA S, POLAT P, GÖRGÜNER M, Eur Resp J, 18 (2001) 1069. — 4. ACAR T, GÖMCELI I, GÜZEL K, YAZGAN A, AYDIN R, Scott Med J, 48 (2003) 52. — 5. BUSIĆ Z, AMIĆ E, SERVIS D, PREDRIJEVAC M, STIPANČIĆ I, BUSIĆ D, Coll Antropol, 28 (2004) 325. — 6. MORAR R, FELDMAN C, Eur Resp J, 21 (2003) 1069. — 7. XANTHAKIS DS, KATSARAS E, EFTHIMIADIS M, PAPANAKIS G, VAROUCHAKIS G, ALIGIZAKIS C, Thorax, 36 (1981) 497. — 8. PEDROSA I, SAIZ A, ARRAZOLA J, FERREIROS J, PEDROSA CS, Radiographics, 20 (2000) 795. — 9. YORUK Y, YALCINKAYA S, COSKUN I, EKIM T, KOSE S, MEHMET R, Hepatogastroenterology, 45 (1998) 1831. — 10. AYED AK, ALSHAWAF E, Med Princ Pract, 12 (2003) 112. — 11. KIR A, BARAN E, Thoracic & Cardiovascular Surgeon, 43 (1995) 62. — 12. GOLLACKNER B, LANGLE F, AUER H, MAIER A, MITTLBOCK M, AGSTNER I, KARNER J, LANGER F, ASPOCK H, LOIDOLT H, ROCKENSCHAUB S, STEININGER R, World J Surg, 24 (2000) 717.

*B. Miletić*

»Thalassotherapia«, M. Tita 188/1, 51410 Opatija, Croatia  
e-mail: bojan.miletic@ri.t-com.hr

## 19-GODIŠNJA REKURENTNA HIDATIDNA BOLEST

### SAŽETAK

Hidatidna bolest (ehinokokoza) je potencijalno fatalna parazitoza, uzrokovana parazitom *Echinococcus* i zahvaća primarno jetru i pluća. Unatoč efikasnom medikamentoznom i kirurškom liječenju, rekurentne epizode bolesti ostaju osnovni problem u tretmanu. Opisujemo rijedak slučaj višestruko ponavljane ehinokokoze koja je trajala više od 19 godina. Prezentirala se multiplim cistama jetre s diseminacijom u pluća, no put diseminacije u ovom slučaju ostao je ipak nepotpuno razjašnjen i ostavlja mogućnost daljnjih rasprava. Unatoč kirurškoj i medikamentoznoj terapiji došlo je do značajne progresije bolesti i razvoja septičkog šoka s letalnim ishodom.