

Lower Lobe Pulmonary Tuberculosis in Immunocompetent Male

Flego, Veljko; Kurpis, Marina; Milevoj-Ribić, Flavija; Bulat-Kardum, Ljiljana; Matanić, Dubravka

Source / Izvornik: **Collegium antropologicum, 2010, 34, 1453 - 1455**

Journal article, Published version

Rad u časopisu, Objavljena verzija rada (izdavačev PDF)

Permanent link / Trajna poveznica: <https://um.nsk.hr/um:nbn:hr:184:089294>

Rights / Prava: [In copyright](#)/[Zaštićeno autorskim pravom.](#)

Download date / Datum preuzimanja: **2025-03-10**



Repository / Repozitorij:

[Repository of the University of Rijeka, Faculty of Medicine - FMRI Repository](#)



Lower Lobe Pulmonary Tuberculosis in Immunocompetent Male

Veljko Flego, Marina Kurpis, Flavija Milevoj-Ribić, Ljiljana Bulat-Kardum and Dubravka Matanić

University of Rijeka, Rijeka University Hospital Center, Department of Pulmology, Rijeka, Croatia

ABSTRACT

We present a case of 23 years old student misdiagnosed for two months. Radiological finding showed a pneumonial infiltrate of left lung lower lobe. Antibiotic therapy was not resulting in a radiological regression. Biopsy of the lung infiltrate by transthoracic computed tomography guided histology needle, showed granulomatous inflammation with necrosis. Bronchial aspirate received by bronchoscopy was positive in culture on *Mycobacterium tuberculosis*. After 6 months of antituberculous therapy advance the complete regression of lung infiltrate. Tuberculosis of lower lung lobe is difficult to diagnose, particularly in persons who are not immunocompromised or without associated diseases. Lower lobe localization of tuberculosis is between 0.6 to 10.5% in all cases. Early diagnosis and therapy of pulmonary tuberculosis depends on bronchoscopic samples. The biopsy of the lung infiltrate by transthoracic computed tomography guided histology needle in histopathological and bacteriological diagnosis of tuberculosis was also useful.

Key words: tuberculosis, lung infection, lower lobe, infiltrate, radiological findings

Introduction

Pulmonary tuberculosis (TB) is found predominantly in the upper lobes¹. Usually, more than one lobe or segment is involved. It is unusual to find isolated segments outside or without lesions in the typical areas².

A lower lung lobes tuberculosis is often confused by pneumonia and the correct diagnosis may not be established for a prolonged time. The radiographic findings in lung lower lobes tuberculosis differ significantly from those found in upper lobe. Disease often resembles bacterial or viral pneumonia more than tuberculosis. Tissue consolidation in lung lower lobes tends to be more confluent and extensive than that found in upper lobes tuberculosis.

Tuberculosis of lower lobes appears in immunocompromised persons, in patients with diabetes mellitus and in younger females. The incidence of this pulmonary TB localization is 0.6 to 10.5 percent³.

Case Report

A 23-year-old male, student, nonsmoker, was admitted to the Department of Pulmology after ten days high fever, chest pain on the left side, cough and purulent

cough out. At physical examination, the patient showed crackles on the base of the left lung.

His past medical history included community-acquired pneumonia (CAP) before ten years.

An antibiotic therapy at home was performed (amoxicillin+acid clavulanic and azithromycin), without clinical improvement.

The chest radiographs of patient on admittance to the hospital showed extensive confluent consolidation with air bronchogram in the left lower lobe (Figure 1).

Laboratory findings: WSE 84 mm/h, leucocytes $11.5 \times 10^9/L$, neutrophiles 75%, lymphocytes 16%, C-reactive protein (CRP) 128.3 mg/L. Other routine laboratory findings were normal. PPD skin test was 9 mm.

Microbiological diagnosis of sputum was: *Streptococcus* group F. Anti-HIV was negative. *Mycobacterium tuberculosis* was microscopically negative in sputum. An empiric therapy was performed (gentamycin + ciprofloxacin) for ten days and cephtriaxon (aimed) for the next ten days.

He was discharged from the hospital, without fever, CRP was 84.4 mg/L, leucocytes were $10.2 \times 10^9/L$.

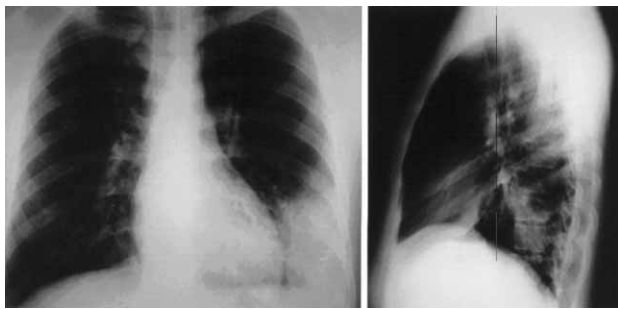


Fig. 1. Posteroanterior and lateral chest radiographs of a patient at arrival in the hospital.

The control chest radiographic finding was surprisingly without regression. Bronchoscopic examination was normal. In bronchial aspirate meticillin-resistant *Staphylococcus Aureus* (MRSA) was isolated. The patient was treated with 2 grams of vancomycin daily and hospitalized for 10 days. The next chest radiographic finding was also without regression. Laboratory findings: WSE 24 mm/h, leucocytes $14.0 \times 10^9/L$, neutrophyles 88%, lymphocytes 8%, CRP 18.5 mg/L.

Multi slice computed tomography (MSCT) finding: homogeneous consolidation of lung parenchyma in left lower lobe (posterior and lateral segments) with pneumobronchogram and the signs of perifocal hyperemia (Figure 2). This finding was predictive for pneumonial infiltrate. The biopsy of the consolidation by transthoracic CT-guided histology needle showed histopathological finding of granulomatous inflammation with necrosis. Seven weeks after bronchoscopy we received positive culture for *M. tuberculosis* in bronchial aspirate, while in sputum was negative. Moreover, *M. tuberculosis* was proved in bronchial aspirate by polymerase chain reaction by identification one insertion site of IS6110 region of *M. tuberculosis* genome. The test of *M. tuberculosis* drug resistance was negative.

We started medical treatment with antituberculosis chemotherapy two months after the first hospitalization. *M. tuberculosis* culture grows out negative after two months. The chest radiographic finding was normal, as all laboratory findings, after 6 months treatment with antituberculosics.

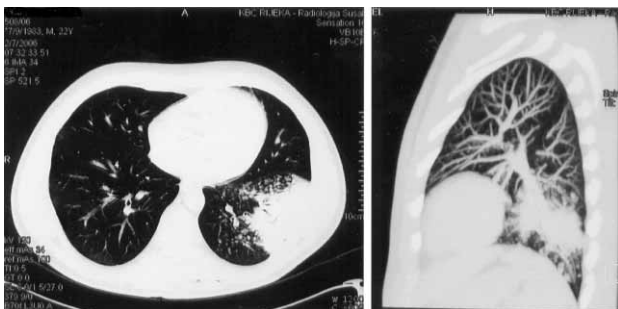


Fig. 2. MSCT (multi slice CT) of the chest in a patient 2 months after antibiotics treatment.

Discussion

We presented a rare case of lung lower lobe tuberculosis in previous healthy young male. Lower lung field TB is fairly rare in non-immunocompromised persons⁴. This entity should be commonly looked for in HIV infected persons, concomitant lung malignancy, diabetics and other underlying diseases³. Clinical presentation was similar to that of upper lung field TB and short course chemotherapy is equally effective as in classical upper zonal disease. Interestingly, the right lower lobe was the commonest localization of parenchymal opacities in pulmonary tuberculosis in children⁵. In our case pulmonary tuberculosis is presenting radiologically as community-acquired pneumonia. In the study of Malaysian population *M. tuberculosis* was isolated in 4.9% of 346 patients hospitalized for CAP⁶. Differential diagnosis of infiltrative TB and pneumonia located in the lower lobe is usually difficult. Radiologically TB is characterized by more frequent polysegmentary lesions and involvement of the VI segment. Pneumonia is characterized by involvement of the middle lobe, segments VIII and X⁷. Pulmonary TB is mainly bilateral, with the involvement of 2 lobes or more, with the presence of destructive changes and bronchogenic dissemination⁸. Errors in diagnosing pulmonary TB happens where TB is hidden under the mask of inflammatory pulmonary disease, or concomitant pathology, due to severe intoxication, or multiorgan insufficiency, or complications of TB and tuberculosis of other organs^{9,10}. Tuberculosis is relative often mistaken for CAP. Any CAP patient failing or relapsing after empiric or aimed therapy should be investigated for TB. At the beginning our patient could have lower lobe tuberculosis and co-existing pneumonia. A clinical and laboratory improvement was achieved after antibiotic treatment. On the other hand, the left lower lobe consolidation in radiological findings was remained for two months without changes. Suboptimal therapeutic response on antibiotics required further treatment¹¹.

The more important for the right diagnosis is bronchoscopic samples in our case. Moreover, biopsy of the lung infiltrate by transthoracic computed tomography guided histology needle is very usefully in histopathological and bacteriological diagnosis of tuberculosis^{12,13}.

An acquired lower lobe pulmonary tuberculosis in immunocompetent young man is rare. Bronchoscopy and transbronchial lung biopsy, taking brushing smear or bronchial aspirate are useful in evaluation. We detected *M. tuberculosis* in culture of bronchial aspirate. Transthoracic CT-guided histology needle biopsy showed histopathological finding of granulomatous inflammation with necrosis, which primarily suggest tuberculosis. In spite of clinical and laboratory improvement, the bronchoscopy is the key for the early diagnosis. Lower lobe TB should be considered at the first sign of non regression of the X-ray lung consolidation.

REFERENCES

1. AGIZEW T, BACHHUBER MA, NYIRENDA S, MAKWARUZI VZ, TEDLA Z, TALLAKSEN RJ, PARKER JE, MBOYA JJ, SAMANDARI T, Int J Tuberc Lung Dis, 14 (2010) 324. — 2. WONG KS, HUANG YC, LAI SH, CHIU CY, HUANG YH, LIN TY, Int J Tuberc Lung Dis, 14 (2010) 155. — 3. AHMAD Z, ZAHEER MS, JIACM, 4 (2003) 116. — 4. SESTER U, WILKENS H, VAN BENTUM K, SINGH M, SYBRECHT GW, SCHAFERS HJ, SESTER M, Eur Respir J, 34 (2009) 702. — 5. MILKOVIĆ Đ, RICHTER D, ZORIČIĆ-LETOJA I, RAOS M, KONCUL I, Coll Antropol, 29 (2005) 271. — 6. LIAM CK, PANG YK, POOSPARAJAH S, Respiriology, 11 (2006) 786. — 7. SCHLOSSBERG D, Infect Dis Clin North Am, 24 (2010) 139. — 8. DEIKINA ON, MISHIN V, DEMIKHOVA OV, Probl Tuberk Bolezn Legk, 1 (2007) 39. — 9. KUKULJ S, MEHULIĆ M, BARIŠIĆ B, KAMAUF-BALABANIĆ B, KRIŽANAC Š, Coll Antropol, 28 (2004) 931. — 10. LEVISON JH, BARBIERI RL, KATZ JT, LOSCALZO J, N Engl J Med, 363 (2010) 965. — 11. CRAIG SE, BETTINSON H, SABIN CA, GILLESPIE SH, LIPMAN MC, Int J Tuberc Lung Dis, 13 (2009) 208. — 12. METZGER F, PERNET D, MANZONI P, RANFAING E, DALPHIN JC, Rev Mal Respir, 27 (2010) 6. — 13. GARG S, HANDA U, MOHAN H, JANMEJA AK, Diagn Cytopathol, 35 (2007) 26.

V. Flego

University of Rijeka, Rijeka University Hospital Center, Department of Pulmology, Tome Strižića 3, 51000 Rijeka, Croatia
e-mail: veljko.flego2@ri.t-com.hr

TUBERKULOZA DONJEG REŽNJA PLUĆA U IMUNOKOMPETENTNOG MUŠKARCA

SAŽETAK

Prikazali smo slučaj 23 godišnjeg studenta bez dokazane dijagnoze u dva mjeseca. Radiološki nalaz pluća pokazivao je pneumonični infiltrat donjeg režnja lijevog pluća. Antibiotikom terapijom nije postignuta radiološka regresija. Kompjutorskom tomografijom vođena transtorakalna iglena biopsija infiltrata pluća utvrdila je histološki nalaz granulomatozne upale s nekrozom. Bronhoskopski dobiven aspirat bronha bio je u kulturi pozitivan na *Mycobacterium tuberculosis*. Nakon 6 mjeseci antituberkulozne terapije došlo je do potpune regresije infiltrata pluća. Tuberkuloza donjeg režnja predstavlja dijagnostičku poteškoću, naročito u osoba koje nisu imunokompromitirane ili koje ne boluju od neke pridružene bolesti. Incidencija tuberkuloze donjeg režnja je između 0.6 i 10.5% od svih bolesnika oboljelih od TB. Rana dijagnoza i liječenje plućne tuberkuloze ovisi o uzimanju uzoraka dobivenih bronhoskopskijom. Kompjutoriziranom tomografijom vođena transtorakalna iglena biopsija pluća je od velikog značaja u patohistološkoj i bakteriološkoj dijagnostici tuberkuloze.