

# Laringoskopija visoke rezolucije u dijagnozi poremećaja glasnica

---

Šepić, Tatjana; Starčević, Radan; Šoša, Ivan; Strenja-Linić, Ines; Grubešić, Aron

Source / Izvornik: **Medicina Fluminensis : Medicina Fluminensis, 2012, 48, 233 - 237**

Journal article, Published version

Rad u časopisu, Objavljena verzija rada (izdavačev PDF)

Permanent link / Trajna poveznica: <https://um.nsk.hr/um:nbn:hr:184:550590>

Rights / Prava: [In copyright](#)/[Zaštićeno autorskim pravom](#).

Download date / Datum preuzimanja: **2024-07-13**



Repository / Repozitorij:

[Repository of the University of Rijeka, Faculty of Medicine - FMRI Repository](#)



# High Resolution Close-up Laryngoscopy in Diagnosis of Vocal Folds Defects

## Laringoskopija visoke rezolucije u dijagnozi poremećaja glasnica

Tatjana Šepić<sup>1</sup>, Radan Starčević<sup>1</sup>, Ivan Šoša<sup>2</sup>, Ines Strenja-Linić<sup>3</sup>, Aron Grubešić<sup>4\*</sup>

**Abstract. Aim:** Our aim is to underline the superiority of Wolf endocam among other high resolution close-up laryngoscopy devices. We use a camera made by Richard Wolf GmbH (Knittlingen, Germany). High-Speed Endocam 5562 was constructed specifically for laryngoscopy, so it is equipped with an automatic focus. **Case report:** Patient whom we present is a 58-years old female who displayed throat discomfort and harsh voice for nearly a month. Her medical history was unremarkable except for the cervical spine tenderness. When examined with High-Speed Endocam 5562, vocal fold hematoma became visible. **Discussion:** So far, we have found various anatomical variations with or without epithelial damage. High resolution laryngoscopy shows a better and more objective view of vocal fold defects with no room for speculation based on subjective observation of obvious defects. With the use of Wolf endocamera precise positions are determined and accurate treatment can be achieved, also choosing a suitable approach. When surgical treatment is indicated, this imagining improves preoperative understanding of the problem, subsequently increasing the odds of success. **Conclusion:** Once handled by an experienced physician, up to 20 patients can be examined each day. Examination is performed quickly and without the need for local anesthesia. Endocamera offers reliability and objectivity as findings may be recorded and reviewed when necessary. This enables treating the patients adequately as making a fully informed decision is significantly upgraded by superior visual documentation of local condition.

**Key words:** endoscopic camera, high resolution close-up laryngoscopy, vocal folds

**Sažetak. Cilj:** Cilj nam je istaknuti superiornost Wolfove endokamere nad ostalim uređajima za izravnu laringoskopiju visoke rezolucije. Kamera koju koristimo, High-Speed Endocam 5562®, izgrađena je posebno za laringoskopiju, te je opremljena automatskim fokusom, a proizvodi je Richard Wolf GmbH (Knittlingen, Njemačka). **Prikaz slučaja:** Prikazujemo 58-godišnju bolesnicu koja se žali na teškoće s glom i hrapav glas kroz gotovo mjesec dana. Povijest bolesti ne pokazuje osobitosti, osim palpatorne bolne osjetljivosti vratne kralježnice. Pregledom kamerom High-Speed Endocam 5562 jasno smo uočili vokalni hematoma. **Rasprava:** Tijekom svakodnevnih pregleda nalazimo razne anatomske varijacije, neke uz oštećenje, a neke bez oštećenja epitela. Laringoskopija visoke rezolucije omogućuje bolji pregled defekata vokalnih nabora, ne ostavljajući prostor za spekulacije i subjektivnost. Korištenjem Wolfove endokamere određuje se i precizna pozicija lezije, te je lakše odrediti adekvatnu terapiju. Kod indiciranog kirurškog zahvata ovakva vizualizacija poboljšava predoperativno razumijevanje problema, a time i izgleda za uspjeh. **Zaključak:** Ako je kamera u rukama iskusnih liječnika, moguće je obraditi do 20 bolesnika dnevno. Pregled se obavlja brzo i bez potrebe za lokalnom anestezijom. Endokamera nudi pouzdanost i objektivnost, a rezultati se mogu snimiti i pregledati kada je to potrebno. To omogućuje adekvatno liječenje bolesnika i stvaranje potpuno informirane odluke zasnovane na vrhunskoj vizualnoj dokumentaciji lokalnog stanja.

**Ključne riječi:** direktna laringoskopija visoke rezolucije, endoskopska kamera, glasnice

<sup>1</sup>Clinics for Otorinolaryngology and Head and Neck Surgery, Clinical Hospital Centre Rijeka, Rijeka

<sup>2</sup>Department of Forensic Medicine and Criminalistics, Faculty of medicine, University of Rijeka, Rijeka

<sup>3</sup>Clinics for Neurology, Clinical Hospital Centre Rijeka, Rijeka

<sup>4</sup>Institution for emergency medicine Rijeka, Rijeka

Primljeno: 15. 11. 2011.

Prihvaćeno: 29. 3. 2012.

Corresponding author:

\*Aron Grubešić, dr. med.

Institution for emergency medicine Rijeka

Branka Blečića BB, 51 000 Rijeka

e-mail: agrubestic@gmail.com

<http://hrcak.srce.hr/medicina>

## INTRODUCTION

Aim of this report is to introduce the use of a new high resolution endoscope in the endoscopic examination of the upper aero-digestive system and talk over the worth of this tool in the laryngeal lesions' diagnosis. Voice is one of the crucial means of communication and should be taken great care of<sup>1,2</sup>.

In the last three decades, knowledge on the vocal fold has grown and revolutionized clinical practice

In most cases, with an experienced practitioner, examination is performed quickly and without the need for local anaesthesia.

With the use of a high resolution camera precise positions are determined and accurate treatment options can be achieved.

Vocal fold cancers, in most cases, take the form of squamous cell carcinoma.

in laryngology<sup>3</sup>. Since the first observation of the layered microstructure of the human vocal fold made by Hirano advanced diagnostic and surgical methods to raise voice quality. Stroboscopy has been initially developed as the most objective and practical method for clinical evaluation of phonatory mucosa<sup>4</sup>. Introduction of endocam into everyday clinical practice has improved diagnostic possibilities and, as well, provided laryngologists with various new treatment options<sup>3</sup>. Endocamera can be used to diagnose and treat a great number of disorders that have, until now, remained in the realm of a subjective estimation occasionally limited by the vision and expertise.



**Figure 1.** Outlook of the endocamera made by Richard Wolf GmbH (Knittlingen, Germany). Model used herein was labelled "Richard Wolf 5562 Endocam®".

Using an endocamera (Figure 1) made by Richard Wolf GmbH (Knittlingen, Germany), laryngologist can now record and assess the footage more objectively and in direct consultation with colleagues in different institutions<sup>3</sup>. On the other hand, with patients being able to see their vocal chords, cooperation tends to be less of an issue, and therapy more successful.

## CASE REPORT

58-year old female patient presented with discomfort and harsh voice for nearly a month<sup>5</sup>. Her medical history was unremarkable, except for the cervical spine tenderness that we assigned to be occupation-related. She had never smoked, nor had any environmental circumstances that would suggest phoniatric risk. By local inspection none of the abnormalities in the aero-digestive system were pointed out. After obtaining written consent based on the statement that all information would be handled in compliance with the latest revision of the Helsinki declaration, laryngoscopy was used in accordance with existing protocols. Firstly, validity of approach was confirmed through locating the anterior commissure. Laryngoscope was then inserted deeper into the larynx, so the vocal folds can be seen up close, and assurance of proper anatomical sight is obtained. Using a built-in magnifier, minute inspection of edematous vocal fold's mucosa displayed restrained reddish spherical salience of the left vocal chord (Figure 2)<sup>6,7</sup>. After the late was recognized as hematoma, laryngologist suggested expectative treatment<sup>8</sup>. During follow-up, control high-resolution laryngoscopy on 15-day and 1-month checkups, showed notable improvement (Figures 3 and 4). The patient permitted reporting of her case in accordance with current ethical standards.

## DISCUSSION

We present a case of a previously healthy 58-year old female with an unremarkable medical history that arrived with a relatively sudden onset of discomfort and harsh voice which lasted for nearly a month. She was examined by a high resolution endoscope (HR endoscope) which revealed a vocal haematoma of unknown origin. In a diagno-

stic centre without an HR endoscope the usual algorithm would have included a conservative and mostly subjective view through the classic laryngoscope with repeated incursions toward the patient when a second or third opinion is needed. New, powerful endoscopes improve the possibilities of endoscopy as a method. Recently developed HR endoscopes offer considerably higher image quality comparing with first-generation video endoscopes or the older fiber-optic devices<sup>9-11</sup>.

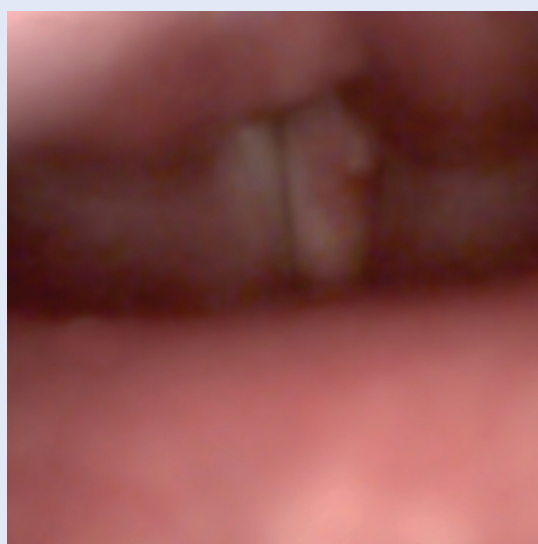
HR endoscopy enabled a better description of the laryngeal lesions (their features and irregularities in surface and borders) with detailed aspect characterization of nearby laryngeal mucosa, especially in pre-malignant lesions<sup>3,6,11</sup>. Besides, the optical zoom does not require a close approach to the laryngeal mucosa, therefore, local anesthesia is not required. This new technology, as previously in gastric, oesophageal and colorectal disorders could also be improved by using vital stain techniques. Also, its significance is especially high in the differentiation of organic dysphonias. However, this is subject to limits imposed by its temporal resolution in recording and interpreting unequal oscillations of the vocal cords. Visual evaluation of minute detail enabled by magnification endoscopy is promising and should be highlighted once more<sup>6</sup>. Inflammation can significantly impair the image seen while seeking the changes indicative of neoplasia, and thus could determine false-positive results. The principle employed is based on a visual illusion and facilitates evaluation of vocal cord undulations. Introduction of fiber-optic technology has enhanced the clinician's access to many hidden parts of the vocal apparatus<sup>9</sup>, even for the outpatients. HR endocamera laryngoscopy has advanced the technique by documenting the examination with images of considerable quality. This allows them to be reviewed subsequently, without subjecting the patient to further, unnecessary discomfort. Also, comparing the images during follow-up is simplified through this process<sup>3,10,11</sup>. By everyday use of high-resolution endocamera, it is now possible to examine, in great detail, the specific structures of the patient's vocal chords, especially as some structures cannot be seen otherwi-

se. This is possible by specific maneuvers such as rotating the laryngoscope into position optimal for observation of the laryngeal ventricle and sacculae. Furthermore, a kymographic analysis embedded in the laryngoscope software was used in order to diagnose polyps and nodes in the vocal chords<sup>3,7,10</sup>.

When in hands of an experienced practitioner, up to 20 patients can be examined per day, their conditions recorded and reviewed. In comparison to conservative options, endocamera offers

High resolution laryngoscopy shows a better and more objective view of vocal fold structures with no room for speculation based on subjective observation of apparent defects.

reliability and objectivity necessary to adequately treat patients who can now make a fully informed decision depending on visual interpretation of their condition. An important part of being able to record visual data is the possibility of review and consultation as well as an objectivized approach to patient treatment<sup>10</sup>. Examination is performed quickly and without the need for local anesthesia. With the use of a HR camera precise positions are determined and accurate treatment options can be achieved. There are several diseases whose importance of discovery is



**Figure 2.** Local finding in first check-up as seen by endocamera. Note the marginated reddish convexity on oedematous vocal fold's mucosa.

crucial in approving the cost of endocamera investment. This was most obvious from the case presented by Mortensen in 2008<sup>12</sup>. He reported a patient who had initially undertaken rigid stroboscopy and found an open phase for the most part, but a normal vibratory pattern. High-speed photography showed a different vibratory frequency for each vocal fold, which suggested paresis. Electromyography of the laryngeal musculature confirmed the diagnosis. Since the confirmation

It aids in the decision making process regarding therapeutic approaches, and when surgical treatment is indicated, a better preoperative understanding of the problem, improving the odds of success.

of this method, we have successfully integrated it into our everyday clinical practice. In endoscopes such as ours, technologies provide both HR and magnification, which allows for detailed inspection of the mucosa and subsequently improves differential diagnosis between different lesions and contributes to further development of the endoscopic diagnosis of various upper aero-digestive tract lesions<sup>5,6,11</sup>.

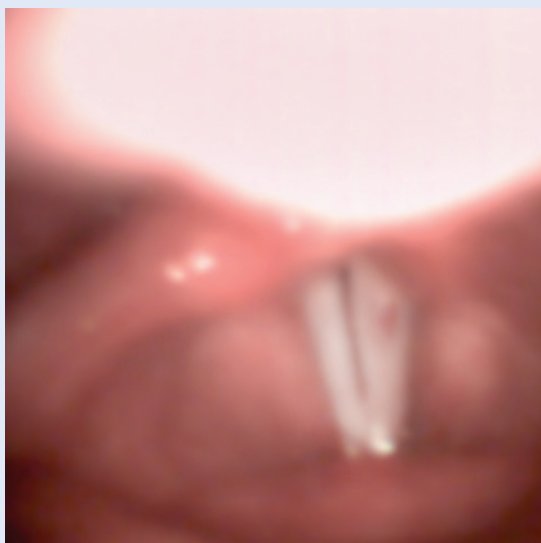
In our clinical practice, we have found a variety of anatomical variations with or without epithelial damage. Thus, we confirmed the superiority of

our endocamera by observing that, with this kind of endoscopy, aside from the ability to obtain enhancement depicting the contours and surface irregularities of the lesions, we have an opportunity to precisely detect irregular laryngeal lesions and also to provide valuable information that may be used to guide the selection of optimal treatment and post-operative follow-up.

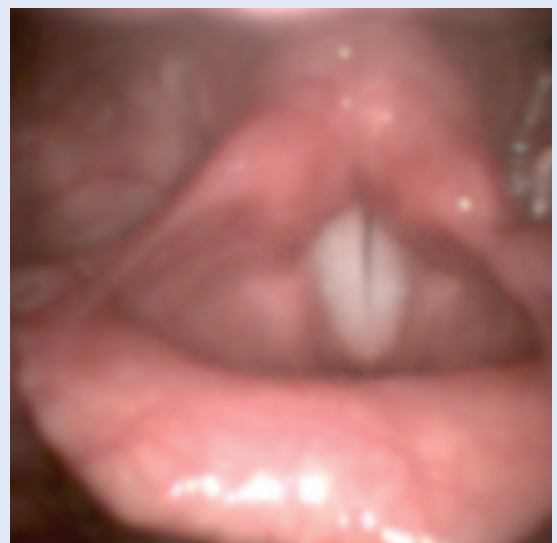## CONCLUSIONS

High resolution laryngoscopy shows a better and more objective view of vocal fold structures with no room for speculation based on subjective observation of apparent defects. One might argue that this technique is more time consuming than conservative examinations but a laryngologist can now record and assess the footage more objectively and in direct consultation with colleagues in different institutions, when necessary. It aids in the decision making process regarding therapeutic approaches, and when surgical treatment is indicated, a better preoperative understanding of the problem, improving the odds of success.

In conclusion, high resolution endoscopy, even though still referring to expensive technology, appears to be a new valid tool improving the endoscopic diagnostic field. There are a few limits and doubts that can probably be overcome by training and grown experience. These recently



**Figure 3.** Gradual improvements on second check-up.



**Figure 4.** Complete disappearance of hematoma and resolution of vocal fold's mucosal oedema.

developed HR endoscopes offer features that allow more mucosal details to be perceived. The necessity to utilize this technique needs to be documented on the upper aero-digestive tract.

#### ACKNOWLEDGMENTS

We extend gratitude towards Otorhinolaringology Clinic for generous cooperation in purchase of Wolf endocam equipment.

#### REFERENCES

1. Stevens KN. *Acoustic Phonetics*. Cambridge: MIT Press, 2000.
2. Titze IR. *Principles of Voice Production*. Englewood Cliffs: Prentice Hall, 1994.
3. Carriero E, Galli J, Fadda G, Di Girolamo S, Ottaviani F, Paludetti G. Preliminary experience with contact endoscopy of the larynx. *Eur Arch Otorhinolaryngol* 2000;257:68-71.
4. Hirano M. Morphological structure of the vocal cord as a vibrator and its variations. *Folia Phoniatr* 1974;26:89-94.
5. Ullis JM, Yanagisawa E. What's new in differential diagnosis and treatment of hoarseness? *Curr Opin Otolaryngol Head Neck Surg* 2009;17:209-15.
6. Bruno MJ. Magnification endoscopy, high resolution endoscopy, and chromoscopy; towards a better optical diagnosis. *Gut* 2003;52:7-11.
7. Johns MM. Update on the etiology, diagnosis, and treatment of vocal fold nodules, polyps, and cysts *Curr Opin Otolaryngol Head Neck Surg* 2003;11:456-61.
8. Branski RC, Verdolini K, Sandulache V, Rosen CA, Hebda PA. Vocal fold wound healing: a review for clinicians. *J Voice* 2006;20:432-42.
9. Maurizi M, Paludetti G, Galli J, Corina L. Electronic fibrovideolaryngoscopy in the diagnosis and surgical treatment of laryngeal pathology. *In: Motta G (ed.) The new frontiers of Otorhinolaryngology in Europe*. Bologna: Monduzzi Ed., 1992;183-6.
10. Kendall KA. High-speed laryngeal imaging compared with videostroboscopy in healthy subjects. *Arch Otolaryngol Head Neck Surg* 2009;135:274-81.
11. Kawaida M, Fukuda H, Kohno N. Digital image processing of laryngeal lesions by electronic videoendoscopy. *Laryngoscope* 2002;112:559-64.
12. Mortensen M, Woo P. High-speed imaging used to detect vocal fold paresis: a case report. *Ann Otol Rhinol Laryngol* 2008;117:684-7.