

Ponavljajuća retencija urina uzrokovana polipom stražnje uretre u osmogodišnjeg dječaka

Nikolić, Harry; Šubat-Dežulović, Mirna; Jašić, Mladen; Valenčić, Maksim;
Butorac Ahel, Ivona; Holjar-Erlić, Izidora

Source / Izvornik: **Medicina Fluminensis : Medicina Fluminensis, 2012, 48, 96 - 100**

Journal article, Published version

Rad u časopisu, Objavljena verzija rada (izdavačev PDF)

Permanent link / Trajna poveznica: <https://um.nsk.hr/um:nbn:hr:184:818656>

Rights / Prava: [In copyright](#)/[Zaštićeno autorskim pravom](#).

Download date / Datum preuzimanja: **2024-08-06**



Repository / Repozitorij:

[Repository of the University of Rijeka, Faculty of
Medicine - FMRI Repository](#)



Recurrent Urine Retention Caused by a Posterior Urethral Polyp in a 8-Year-Old Boy

Ponavljajuća retencija urina uzrokovana polipom stražnje uretre u osmogodišnjeg dječaka

Harry Nikolić^{1*}, Mirna Šubat-Dežulović², Mladen Jašić^{3*}, Maksim Valenčić⁴,
Ivona Butorac-Ahel², Izidora Holjar-Erlić⁵

¹Department of Child Surgery,
University Hospital Center Rijeka, Rijeka

²Department of Pediatrics,
University Hospital Center Rijeka, Rijeka

³Department of Pediatrics,
General Hospital Pula, Pula

⁴Department of Urology,
University Hospital Center Rijeka, Rijeka

⁵Department of Radiology,
University Hospital Center Rijeka, Rijeka

Primljeno: 16. 11. 2011.

Prihvaćeno: 23. 1. 2012.

Corresponding author:

* Mladen Jašić, MD

Department of Pediatrics,

General Hospital Pula

Zagrebačka 30, 52000 Pula, Croatia

e-mail: mladen.jasic@gmail.com

<http://hrcak.srce.hr/medicina>

Abstract. Aim: Polyps of the male posterior urethra are rare and usually benign congenital lesions. We report a case of an 8-year-old boy who presented with recurrent urine retention caused by urethral polyp. **Case report:** At his first admittance to the hospital, the 8-year-old boy presented with urine retention. The performed urethrocystoscopy and cystourethrography were not diagnostic. His condition spontaneously improved, micturition was normal and the boy was discharged. Two years later he presented with recurrent urine retention, and ultrasonography (US) revealed a polypoid mass at the bladder base while cystourethrography showed a filling defect. Magnetic resonance imaging (MRI) revealed the localization of urethral polyp projecting from verumontanum into the bladder cavity. After successful transurethral resection, histological analysis showed fibroepithelial polyp indicating congenital origin. **Discussion:** Urethral polyps are very rare and their etiology is controversial. The presenting symptoms are intermittent urine retention, incomplete bladder emptying, hematuria and urinary infection. Rarely, they are asymptomatic. The diagnosis is usually made by US and voiding cystourethrography (VCUG). Urethrocystoscopy is always diagnostic. The role of MRI is to define the surgical approach to the polypoid lesion. **Conclusions:** The diagnosis of urethral polyp can be made by US, VCUG or MRI but urethrocystoscopy still has a major diagnostic and therapeutic value, especially in boys presenting with urine retention.

Key words: child, polyp, transurethral resection, urethra, urinary retention

Sažetak. Cilj: Polipi stražnje uretre u muške djece rijetke su i obično benigne kongenitalne lezije. U ovom radu prikazat ćemo slučaj osmogodišnjeg dječaka koji je po drugi put primljen u bolnicu zbog akutne retencije urina (ARU) uzrokovane polipom stražnje uretre. **Prikaz slučaja:** Kod prvog primitka dječaka u bolnicu, zbog ARU-a, učinjene su uretrocistoskopija i cistouretrografija. No, navedenim pretragama nije se uspio pronaći uzrok dječakovim tegobama. Njegovo mokrenje postupno se normaliziralo i dječak je otpušten kući. Dvije godine kasnije, kada je ponovno primljen zbog ARU-a, ultrazvukom (UZ) je uočena polipoidna tvorba na bazi mjehura i defekt punjenja na mikcijskoj cistouretrografiji (MCUG). Magnetskom rezonancijom (MR) točno se definiralo mjesto na kojem se nalazi polip; s ishodištem u verumontanumu i protruzijom u mokraćni mjehur, gdje slobodno prominiira. Nakon transuretralne resekcije učinjena je patohistološka analiza kojom je potvrđen fibroepitelni polip koji je vrlo vjerojatno kongenitalan. **Rasprava:** Uretralni polipi izuzetno su rijetki, a njihova etiologija je stalna tema rasprave. Prezentirajući simptomi su intermitentna retencija urina, nepotpuno pražnjenje mjehura, hematurija i urinarna infekcija. Mogu biti i asimptomatski, ali rijetko. Dijagnoza se obično postavlja s UZ-om i MCUG-om. MR definira kirurški pristup polipoznoj tvorbi, dok se uretrocistoskopijom postavlja definitivna dijagnoza. **Zaključci:** Dijagnoza uretralnog polipa može se postaviti sa UZ, MCUG i MR, ali uretrocistoskopija ima važnu ulogu, kako dijagnostičku, tako i terapijsku.

Ključne riječi: dijete, polip, retencija urina, transuretralna resekcija, uretra

INTRODUCTION

Congenital urethral polyps are rare benign lesions of male posterior urethra usually diagnosed during the first decade of life¹, but they can be also found in adolescence², and in the adulthood³⁻⁵. They commonly arise from verumontanum and are typically covered with transitional epithelium over a fibromuscular core⁶⁻⁸. Acquired urethral polyps can develop after infective, irritative, traumatic and obstructive causes^{6,9}. Ultrasonography (US)¹⁰, voiding cystourethrography (VCUG)^{6,9}, computerized tomography (CT)⁶ and magnetic resonance imaging (MRI)⁶ may be diagnostic. The definitive diagnosis, however, should be based on histological findings of the fibroepithelial polyp. Malignancies should be excluded, particularly rhabdomyosarcomas¹. Patients usually present with an acute urinary retention but other symptoms like voiding dysfunction, hematuria or urinary infection may be present^{2,6,7,11}. Formerly, they were mostly treated by open cystotomy^{12,13} but in the last 20 years the preferred treatment option has been transurethral resection, fulguration or laser therapy^{1,2,6,7,11}. They usually do not recur or undergo malignant transformation^{1,6,7}. Since urethral polyps are very rare in children, our intention was to add one more case report to the literature, describing symptoms, diagnostic evaluation and treatment of our patient and comparing them to reports found in recent literature. In addition, we need to point out that two episodes of urine retention were separated by a symptom-free interval of two years duration and this was rather unusual. We did not find any similar cases reported in literature.

CASE REPORT

The 8-year-old boy was hospitalized for the second time because of recurrent urine retention in two years period. At the time of his first admission for acute urine retention, dysuria and gross hematuria, performed imaging studies, including US, VCUG and urethrocystoscopy, were unremarkable. Except for hematuria, diagnostic evaluation was unremarkable – urine culture sterile, calculi, anomalies of urinary tract, possible trauma

and tumors were excluded. After he was catheterized twice, due to anamnesis and clinical findings, we considered chronic constipation to be the cause of urine retention. He was treated for constipation and discharged without voiding problems.

After a symptom-free period of almost two years, he was hospitalized for the second time because of urine retention, gross hematuria and stranguria

The case presents an unusual manifestation of urethral polyp projecting from verumontanum into the bladder cavity. Although the diagnosis can be made by US, VCUG and MRI, only urethrocystoscopy has a major diagnostic and therapeutic value especially in boys presenting with urine retention.

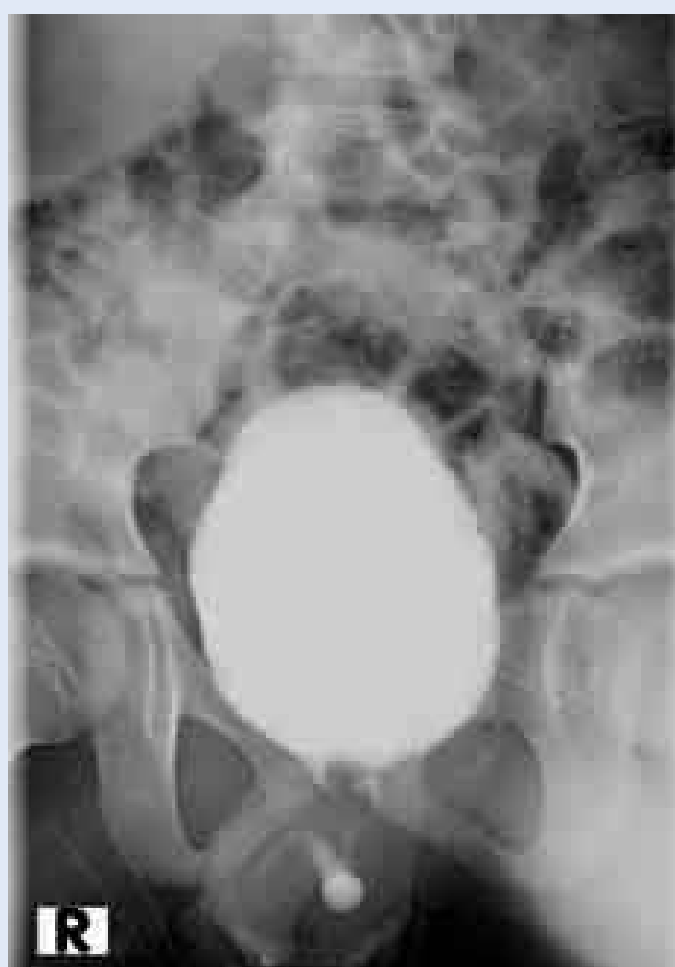

Figure 1. VCUG showing the filling defect at the base of the bladder and in the prostatic urethra. Very thick contrast passage can be seen from the bladder to the anterior urethra.

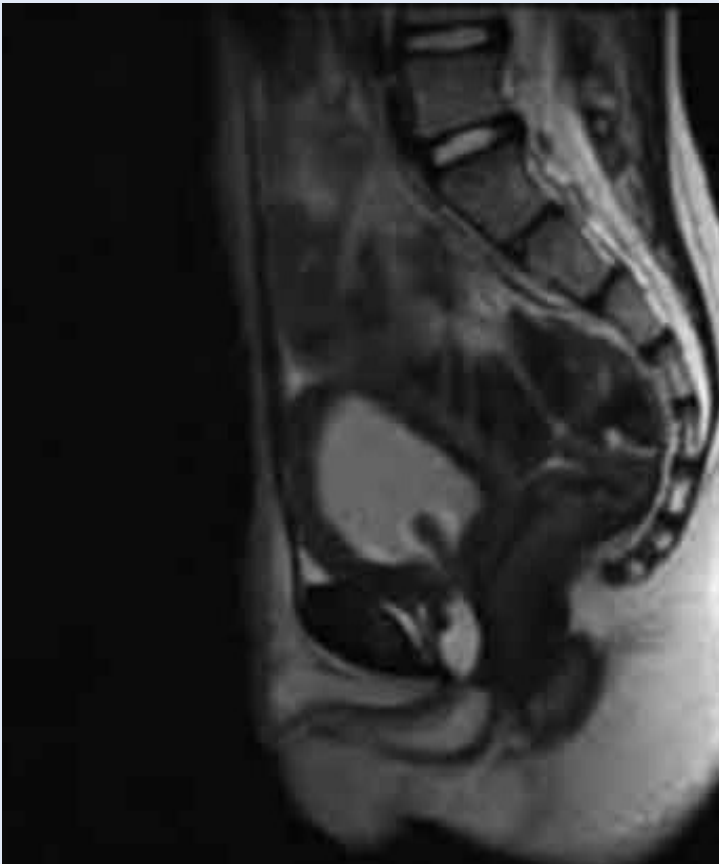

Figure 2. MRI showing the well-circumscribed polypoid lesion (2x1 cm) with low signal intensity, arising from the posterior urethra, passing through the bladder neck and entering the bladder inner space.

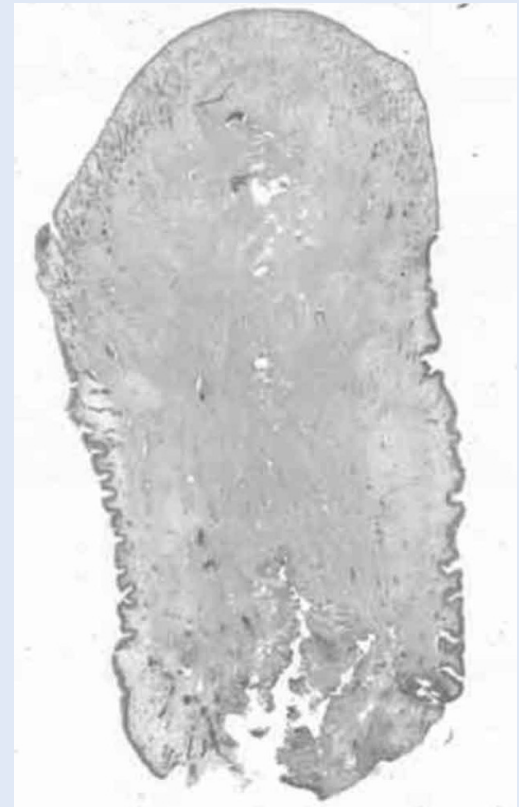


Figure 3. Fibroepithelial polyp (H&E, x5). Fibrovascular tissue partially lined by a transitional epithelium. The epithelium is thin and ulcerated in some parts of the polyp. Granulations are found in the basis of lamina propria.

of a few days duration. Undertaken urgent US showed a thickened bladder wall (6-7 mm) with a soft tissue mass at the bladder base projecting into bladder lumen. The boy was transferred to the tertiary care pediatric center for further evaluation. The color-doppler US confirmed the well-vascularized pedunculated polypous lesion projecting from bladder wall into the lumen. Subsequently undertaken VCUG showed the filling defect arising from the prostatic urethra and at the bladder base (Figure 1). Undertaken MRI revealed the well-circumscribed polypoid lesion measuring 2x1 cm, with low signal intensity, localized in posterior urethra and extending from the verumontanum, passing through the bladder neck and entering the inner space of the bladder (Figure 2). The 8 mm thick bladder wall suggested infravesical obstruction. Transurethral resection using a resectoscope was carried out. The lesion was completely removed with cauterization of the stalk. Histo-

pathology examination showed fibrous tissue partially lined by a transitional epithelium that was thin and ulcerated on some parts of the urethral polyp. Granulations were found on the basis of lamina propria. There was no evidence of malignancy (Figure 3). Following transurethral resection of the polyp, the placed urethral catheter was removed after 48 hours and the boy could void without any difficulties.

After a follow-up period of 6 months, the control urethrocytoscopy showed a normal bladder without pathological changes in the posterior urethra.

DISCUSSION

Genitourinary polyps may be found anywhere from the renal pelvis to the urethra^{7,8,14,15}. Urethral polyps are the most common but rare in both children and adults, mostly found in males and rarely reported in females¹⁻⁶. The first case of urethral

polyp was reported by John Hunter back in 1763 (in an ox), and Sir Henry Thompson reported the first case in a human⁹. Although the first report in humans was more than three centuries ago, the etiology of urethral polyps remains still controversial⁶. If diagnosed in the first decade of life, urethral polyps are considered to be congenital benign lesions of mesodermal origin usually arising from the verumontanum and with no risk of malignancy⁶. Common histological findings of urethral polyps are fibrous core covered with normal transitional urothelium with occasionally found areas of squamous metaplasia and ulceration indicative of fibroepithelial polyp⁶⁻⁸. In our 8-year-old boy, the congenital origin of urethral polyp was very likely due to his age, localization and histological finding of fibroepithelial polyp. However, the presentation with two separate episodes of urine retention in a two years period was rather unusual, and we found no similar presentation in literature. There are several various clinical presentations reported in the literature, ranging from acute to intermittent urine retention, incomplete bladder emptying, hematuria (gross or microhematuria), urinary infection^{1,6-10,14,15} or rarely reported asymptomatic presentation as described by Tsuzuki et al⁸. In their study they showed that half of the polyps discovered were without any symptoms, and emphasized that polyps are more common than the incidence reported in the literature. Differential diagnosis of urine retention beside urethral obstructive lesions include urethral valves, stones, constipation with fecal masses compressing the bladder neck and tumors like urothelial papilloma or rhabdomyosarcoma^{1,6}. When admitted for the first time, based on normal diagnostic tests, including negative urethroscopy (except for hematuria), we excluded all known causes of urine retention and presumed that chronic constipation with faecal masses compressing the bladder neck could be the cause of acute urine retention. However, following the two-years symptom-free period, when he presented for the second time with recurrent urine retention, immediately performed color-doppler US revealed a well vascularized polypoid lesion suggesting urethral polyp⁶. Other imaging studies confirmed the diagnosis; MRI was indicated to rule out the differential diagnosis and to identify the

precise localization of the polyp. Murshidi et al⁷ reported a case of bladder polyp which presented with recurrent urine retention presuming that the localization of polyp lead to episodes of urine retention alternating with symptom-free periods and proposed that chronic localized lamina propria edema might have caused a mucosal bulge culminating into a polyp. This suggestion could be anticipated in our case explaining the long symptom-free period. Furthermore, due to the thickened bladder wall seen on US and confirmed on MRI, we speculated of the possibility of a slowly growing pedunculated urethral polyp acting as intermittent valve and ultimately causing urethral obstruction. Other likely explanation for the slowly growing polyp not seen on first urethroscopy is the instrumentation of urethra that probably triggered the growth of urothelium culminating in urethral polyp. Finally, in any case, one should consider misdiagnosis, as the first US and urethroscopy were not diagnostic.

The diagnosis of urethral polyps is usually made by US and VCUG, but urethroscopy is always diagnostic. Indicated MRI is not only to identify the precise location of the lesion but to define the surgical approach to polypoid lesion. As reported, the polyp can be accessed and removed by transurethral excision or by open cystostomy^{1,2,6,7,11-13}. In 1985, Bruijnes E et al¹³ emphasized that suprapubic approach is generally recommended for resecting a polyp; however, smaller lesions can be resected transurethrally. Schafer J et al¹² in 1989 described three children with infravesical obstruction; two polyps were excised at open cystotomy and one transurethrally. Nowadays, the suprapubic approach is rarely required and is reserved for large lesions. Common urethral polyps are usually removed transurethrally by endoscopic resection electrocautery, cold knife or laser^{1,2,6,7,11}. Eziyi et al⁶ recently reported four children with urethral polyps; US showed the polyp only in one case, VCUG in two cases. Urethroscopy was diagnostic in all four cases. As in our case, all four lesions were resected transurethrally.

Our search of the literature showed that reported cases of urethral polyps were mainly in male children¹⁻¹⁵.

CONCLUSIONS

In the present report we described an unusual presentation of urethral polyp in a child and emphasized that although the diagnosis can be made by US, VCUG and MRI, only urethrocystoscopy has a major diagnostic and therapeutic value especially in boys presenting with urine retention.

LITERATURE

1. Jain P, Shah H, Parekar SV, Borwankar SS. Posterior urethral polyps and review of literature. *Indian J Urol* 2007;23:206-7.
2. Isaac J, Snow B, Lowichik A. Fibroepithelial polyp of the prostatic urethra in an adolescent. *J Pediatr Surg* 2006;41:e29-31.
3. Furuya S, Ogura H, Shimamura S, Itoh N, Tsukamoto T, Isomura H. Clinical manifestations of 25 patients with prostatic-type polyps in the prostatic urethra. *Hinyokika Kyo* 2002;48:337-42.
4. Cacić M, Petrović D, Tentor D, Hutinec Z, Jelasić D. Prostatic polyp in the prostatic urethra. *Acta Med Croatica* 1997;51:111-2.
5. Sekido N, Hinotsu S, Akaza H, Koiso K. Fibroepithelial polyp of the prostatic urethra: report of two cases and review of the literature. *Nippon Hinyokika Gakkai Zasshi* 1994;85:1403-6.
6. Eziyi AK, Helmy TE, Sarhan OM, Eissa WM, Ghaly MA. Management of male urethral polyps in children: Experience with four cases. *Afr J Paediatr Surg* 2009;6:49-51.
7. Murshidi MS, Akl K. A case of urinary bladder benign polyp treated successfully by resection in a child. *Ann Saudi Med* 2007;27:52.
8. Tsuzuki T, Epstein JI. Fibroepithelial polyp of the lower urinary tract in adults. *Am J Surg Pathol* 2005;29:460-6.
9. Downs RA. Congenital polyps of the prostatic urethra: A review of literature and report of two cases. *Br J Urol* 1970;42:76.
10. Redman JF, Lightfoot ML. Congenital posterior urethral polyp in a boy. *Urology* 2003;61:460-1.
11. Iguchi H, Yoshikawa H, Hamashima T, Sasaki H, Ikeuchi T, Kai Y. A case report of posterior urethral polyp in a child. *Hinyokika Kyo* 1994;40:265-7.
12. Schafer J, Porkolab L, Pinter A. Congenital urethral polyps. A rare cause of obstructive uropathy in childhood. *Urologe A* 1989;28:80-3.
13. Bruijnes E, de Wall JG, Scholtmeijer RJ, den Hollander JC. Congenital polyp of the prostatic urethra in childhood. Report of 3 cases and review of literature. *Urol Int* 1985;40:287-91.
14. Aita GA, Begliomini H, Mattos D Jr. Fibroepithelial polyp of the urethra. *Int Braz J Urol* 2005;31:155-6.
15. Beluffi G, Berton F, Gola G, Chiari G, Romano P, Cassani F. Urethral polyp in a 1 month old child. *Pediatr Radiol* 2005;35:691-3.