

# Open vertebroplasty for treating the metastatic compression fractures of the vertebral body and reducing pain syndrome

---

Rapan, Vjeran; Girotto, Dean; Rapan, Domagoj; Kolarević, Vjekoslav; Biuk, Egon; Žulj, Boris; Rapan, Saša

Source / Izvornik: **Medica Jadertina, 2024, 54, 247 - 253**

Journal article, Published version

Rad u časopisu, Objavljena verzija rada (izdavačev PDF)

Permanent link / Trajna poveznica: <https://urn.nsk.hr/urn:nbn:hr:184:749450>

Rights / Prava: [In copyright](#) / [Zaštićeno autorskim pravom.](#)

Download date / Datum preuzimanja: **2025-01-22**



Repository / Repozitorij:

[Repository of the University of Rijeka, Faculty of Medicine - FMRI Repository](#)



## Open vertebroplasty for treating the metastatic compression fractures of the vertebral body and reducing pain syndrome

*Vertebroplastika otvorenim pristupom u liječenju patoloških kompresijskih prijeloma kralježaka uzrokovanih metastatskim tumorskim tvorbama i smanjenje bolnog sindroma*

Vjeran Rapan<sup>1</sup>, Dean Giroto<sup>2</sup>, Domagoj Rapan<sup>1</sup>, Vjekoslav Kolarević<sup>3</sup>,  
Egon Biuk<sup>1</sup>, Boris Žulj<sup>3</sup>, Saša Rapan<sup>1</sup>

<sup>1</sup>Josip Juraj Strossmayer University of Osijek, Faculty of Medicine, Osijek, Croatia

<sup>2</sup>University of Rijeka, Faculty of Medicine, Department of Neurosurgery, Rijeka, Croatia

<sup>3</sup>Josip Juraj Strossmayer University of Osijek, Faculty of Medicine, Department of Orthopaedics, Osijek, Croatia

---

### Summary

**Objectives:** The aim of this study was to examine the efficacy of the operative procedure, open vertebroplasty, by comparing and evaluating the clinical results before and after open vertebroplasty in the treatment of vertebral fractures with spinal canal compression. Success of the surgery is defined by increased or reduced pain intensity before and after the treatment, as assessed using the Visual Analogue Scale (VAS).

**Participants and methods:** Data for the patients treated for vertebral fractures with open vertebroplasty were retrospectively collected at the Institute for Orthopaedics of the Clinical Hospital Centre Osijek. The analyzed data included: gender, duration of the illness, the intensity of pain before and after the treatment (using the VAS), neurological status, radiological changes of the treated vertebral segment, before and after the treatment, grade of vertebral fracture, and extracorporeal cement leakage from the vertebra body to the surrounding tissue during the procedure.

**Results:** The study included 23 patients, of whom 13 were females and ten were males. The difference in pain before and after the surgery was statistically significant. All the patients complained of pain before the surgery, and the pain intensity median was 8 (interquartile range 7, 5 to 9). However, after the surgery, pain intensity decreased in all the patients, and the pain intensity median was 2.5 (interquartile range 2 to 3).

**Conclusion:** Improvement in clinical results of the treatment of vertebral metastatic fractures with spinal stenosis with open vertebroplasty proves to be significant.

**Keywords:** vertebroplasty, spinal fracture, compression fracture, metastasis, pain

---

### Sažetak

**Cilj istraživanja:** Cilj rada je ispitati uspješnost operacijske metode vertebroplastike otvorenim pristupom u liječenju patološkog prijeloma trupa kralješka s kompresijom spinalnog kanala usporedbom kliničke slike prije operacijskog zahvata i nakon njega. Uspješnost je definirana smanjenjem ili povećanjem intenziteta boli pomoću VAS skale (vizualno-analogni skala)<sup>1</sup> prije i nakon operacijske procedure.

**Ispitanici i metode:** Iz medicinske dokumentacije Zavoda za ortopediju KBC-a Osijek retrospektivno su prikupljeni podaci o bolesnicima koji su liječeni vertebroplastikom otvorenim pristupom radi patološkog prijeloma kralješka. Analizirani podaci su: spol, duljina trajanja tegoba, razina bolova prije i nakon operacije (VAS-skalom), neurološki status, te radiološke promjene na operiranom segmentu prije i nakon

zahvata, naročito stupanj prijeloma, te postojanje ekstrakorporalnog istjecanja cementa tijekom zahvata.

**Rezultati:** U istraživanje je bilo uključeno 23 bolesnika, od kojih 13 žena i 10 muškaraca. Uočeno je da su statistički značajne razlike u bolovima prije i nakon obavljenog zahvata vertebroplastike otvorenim pristupom, te da idu u prilog uspješnosti operativnog zahvata. Svi bolesnici su osjećali bolove prije operacije, medijana 8 (interkvartilnog raspona 7,5 do 9), dok je prisutnost boli značajno smanjena nakon operacije kod svih bolesnika, medijana 2,5 (interkvartilnog raspona od 2 do 3)

**Zaključak:** Statistički je značajan napredak u kliničkoj slici pri liječenju prijeloma kralješka uslijed metastaze sa spinalnom stenozom metodom otvorene vertebroplastike.

**Ključne riječi:** vertebroplastika, fraktura kralježnice, kompresivna fraktura, metastaze, bol

## Introduction

The most common site of metastasis in men and second most common in women, after the liver, is the bone, and about two-thirds of all bone metastases are in the spine.<sup>1</sup> Thus, as many as 10% of all patients with malignant tumours suffer from spinal metastases in some stage of their disease.<sup>2</sup> About 12.6% of these patients suffer from pathological vertebral compressive fractures, and 9.6% have spinal cord compression due to metastasis.<sup>3</sup> Apart from the pain, this condition is usually associated with some form of neurological deficit.

Open vertebroplasty is a technique where decompressive laminectomy is combined with vertebroplasty. Decompressive laminectomy is required when there is central or lateral recess stenosis due to fractures. The removal of these elements, which make up the posterior tension band, causes loading transfer to the anterior column, which is already compromised from the fracture. This can lead to increased pain, destabilization, or even progression of fractures. In these cases, vertebroplasty secures stabilization and shows benefits in pain relief. Other patients who require this technique are patients with burst pathological fractures. Patients who are not ideal surgical candidates for open reduction, fusion, and instrumentation because of their age, poor bone quality, and other major comorbidities may be good candidates for less extensive surgery such as a combined decompressive laminectomy and vertebroplasty.<sup>4</sup>

This study presents the results of research conducted on patients with vertebral body fractures with osteolysis and spinal cord compression treated with open vertebroplasty (OV), consisting of laminectomy and application of bone cement into the vertebral body.

## Methods

In this study, the subjects are patients treated by surgical technique - open vertebroplasty at the Department of Orthopedics and Traumatology of

Clinical Hospital Centre (KBC) Osijek in the past five years with the diagnosis of a pathological fracture of the vertebral body due to the metastatic process with compression of the spinal canal. The Ethics Committee of Osijek University Hospital Center gave acceptance for conducting this research. All 23 patients gave their signed consent for collecting data.

For research purposes, we collected data from the history of patients suffering from compressive fracture of the vertebral body which underwent open vertebroplasty at the Department of Orthopedics and Traumatology of KBC Osijek in the past five years. Using available medical records, we analyzed general data about the sex and duration of the disease, pain level before and after surgery (VAS-scale), neurological status, and radiological changes in the operative segment before and after the surgery, especially the degree of fracture and the existence of extracorporeal leakage of cement during the procedure.

The visual-analogue scale (VAS) is the most used scale for measuring pain intensity. The patients were asked to mark on a 10-centimeter-long line the place corresponding to the intensity of their pain, after which the VAS score on the back side of the millimeter scale was read. Zero (0) means without pain, and ten (10) is the most intensive (unbearable) pain.

Open vertebroplasty surgical technique was performed on all patients.

The procedure was performed in general anaesthesia. After preoperative antiseptic skin preparation and covering the surgical area, the lesion level was determined using a diascopy. Typically, the procedure of laminectomy is performed first, decompressing the spinal canal, and then, under the control of the eye, the vertebroplasty needle is inserted into the fractured vertebral body. When the needle position is satisfactory, a thin vertebral biopsy needle contained in the vertebroplasty set is applied to the vertebral body through the first inserted needle. The obtained material is sent to PHD test. After that, bone cement of appropriate viscosity is applied to the vertebral bone. It is very important to control the procedure by diascopy to prevent cement leakage.

Cement is applied until we are satisfied with its position in the last quarter of the vertebral body in latero-lateral LL projection or if there is any epidural, venous, or intradermal cement extravasation. With about 15% of the vertebral body filling (1 to 3.5 ml), the optimal stiffness of the fractured vertebrae is achieved. Patients stay in bed for at least an hour, and 24 hours after the procedure, they are discharged to home.

### Statistics

Categorical data are represented by absolute and relative frequencies. The normality of the data distribution of numeric variables was performed using the Kolmogorov-Smirnov test to establish how observed variables are distributed in research. Based on this, it was decided whether parametric or non-parametric were to be applied. Normality testing was performed for observed variables (factors) in research.

Differences between numeric variables of two dependent groups that do not follow normal distribution were tested using the Wilcoxon test. All P values are two-sided. The level of significance is set at P = 0.05 (31). Statistical analysis was performed by MedCalc Statistical Software, version 17.8.2 (MedCalc Software bvba, Ostend, Belgium).

### Results

The analyzed data for the preoperative and postoperative VAS scale of patients, based on the Kolmogorov-Smirnov test, show the distributed

significance for preoperative 0.006 and for postoperative patients 0.01 (Table 1). Since the significance level is not higher than 0.05 for all observed variables, it can be concluded that the normality of distribution has not been established, and the analysis was conducted through non-parametric tests.

Table 1 Normality of distribution testing  
Tablica 1. Testiranje normalnosti distribucije

	Kolmogorov-Smirnov test <sup>a</sup>		
	Statistic	Df	P-value
VAS (preoperative/prijeoperacijski)	0.218	23	0.006
VAS (3 months after/nakon 3mj)	0.209	23	0.010

a. Lilliefors Significance Correction

The study included 23 patients treated with the open vertebroplasty method for spinal canal stenosis caused by compressive fracture of the vertebral body. Metastatic changes caused fractures in 20 of 23 subjects. Regarding gender, women were prevalent, 13/23, compared to 10/23 males. The median age of the subjects was 61 years (interquartile range 54 to 74 years), ranging from 39 to 81 years.

Metastasis spine changes were common in 7 of 23 subjects with primary breast cancer and in 4 of 23 subjects with myeloma. Osteoporosis is the cause of fracture in 3 of 23 subjects (Figure 1).

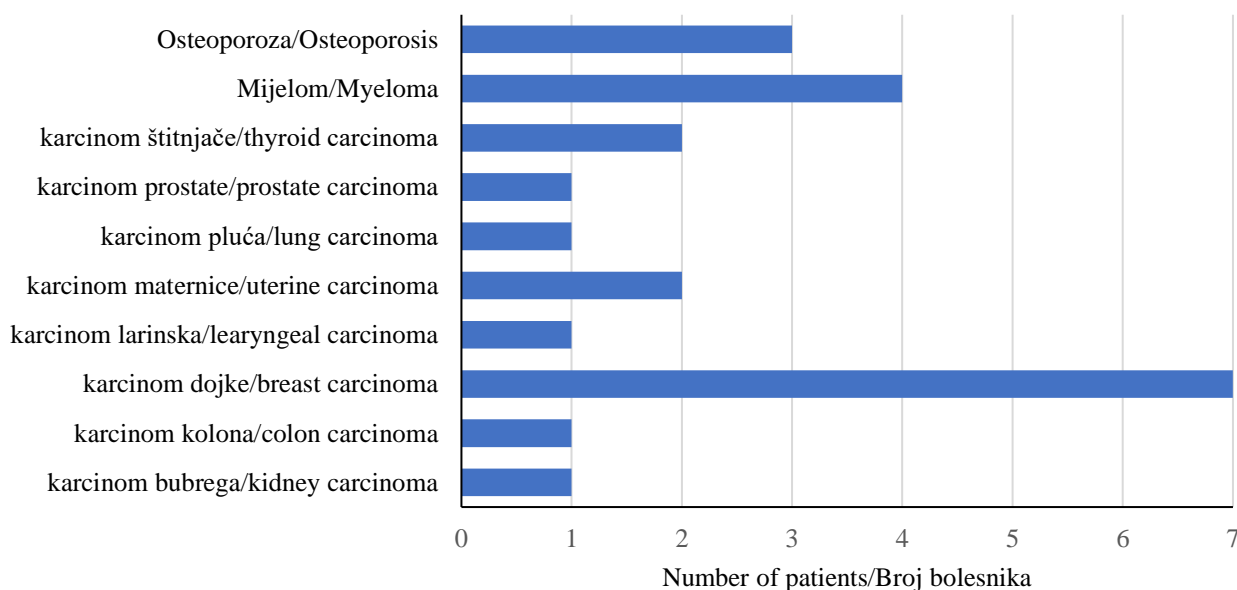


Figure 1 Distribution of subjects according to the cause of the vertebral fracture  
Slika 1. Distribucija bolesnika obzirom na uzrok metastatske frakture kralješka

The diagnostic method of choice for fractures caused by metastases was magnetic resonance imaging (MR). MR was the diagnostic method of choice for fractures caused by metastases in 15 of 20 cases, and computerized tomography (CT) was performed in 5 of 20 subjects.

Vertebral fracture was most common in 13 of 20 subjects in the thoracic spine (Th7 to Th12 vertebra) and 7 of 20 subjects in the lumbar segment (L1, L2, and L3 vertebra). Only one subject had combined L2 and L3 fractures. Th9 fracture was most common in the thoracic region in 4 of 13 subjects (Figure 2).

No extracorporeal leakage of cement or any other cement-related complication was noted during the procedures.

In terms of neurological findings before surgery, 4 of 20 subjects had paraparesis with incontinence, 1 of 20 subjects had just paraparesis, and 4 of 20 subjects had paraparesis and incontinence postoperatively.

The median surgery duration was 60 minutes (interquartile range from 55 to 64 minutes), ranging from 45 to 70 minutes.

The pain intensity was assessed by the VAS scale. The postoperative pain intensity was significantly lower than before surgery (median difference -5.5, 95% confidence difference range from -6.0 to -5; Wilcoxon test,  $P < 0,001$ ) (Table 2).

Table 2. The pre-operative and post-operative pain intensity (n=20)  
 Tablica 2. Prijeoperacijski i poslijeoperacijski intezitet boli (n=20)

Pain scale (VAS scale) <i>Skala boli</i>	Median (interquartile range <i>/interkvartilni raspon</i> )	Difference/Razlika (Hodges – Lehmann)	95% confidence interval <i>povjerenje</i>		$P^*$
			From/Od	To/Do	
Prijeoperacijski/ Pre-surgery	8 (7.5 to 9)	-5.5	-6.0	-5.0	< 0.001
Poslijeoperacijski/ Post-surgery	2.5 (2 to 3)				

\*Wilcoxon test

### Discussion

Osteolytic metastatic spinal lesions are usually secondary because of primary malignancy of other organ systems. Our patients most often have been treated for malignant breast, plasmacytoma, thyroid, and uterine diseases, unlike some other authors who recorded the highest incidence of colon, liver, and prostate malignancy in Asians, while in the Westerners, in addition to malignant breast, prostate and melanoma malignancy, also.<sup>5</sup> Osteolytic metastatic lesions of the vertebral body, perse, are not rare and could cause serious neurovascular complications.

Conservative methods of treatment include

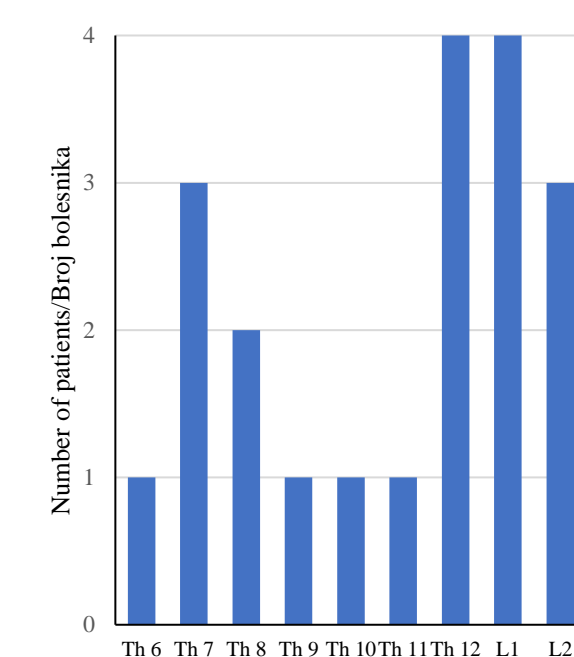


Figure 2 Distribution of subjects according to the location of the fracture

Slika 2. Distribucija bolesnika obzirom na lokalizaciju metastatske frakture kralješka  
 \*Th-thoracal vertebra, L-lumbar vertebra

radiotherapy and chemotherapy. Bisphosphonates, as well as *denosumab*, are also promising a lot in reducing pain due to bone metastasis, bone destruction, and tumor growth. In addition to radiotherapy, chemotherapy, and open surgical treatment (mainly for spinal decompression and stabilization), vertebroplasty and kyphoplasty are also used as minimally invasive methods (to reduce pain and improve mobility). Immobilization with orthoses and analgesic therapy is an option<sup>6</sup> in patients with poor overall condition and contraindications for surgical treatment.

Percutaneous vertebroplasty (PVP) is the most acceptable of all methods for surgical treatment of osteolytic metastatic spinal fractures due to its minimal invasiveness and its effectiveness in

reducing pain, improving the quality of life, and achieving good bone strength and stabilization of the spine.<sup>7,8</sup> Open vertebroplasty offers a safer option for treating destructive vertebral lesions. This procedure, although requiring general anaesthesia and open application of cement, is less invasive compared to fusion procedures requiring less time for surgery, less blood loss, and at the same time being much safer than PVP and significantly cheaper. The lower risk of complications in open vertebroplasty is associated with the immediate visualization and mobilization of neurovascular structures. The technique itself is not very complicated and consists of a combination of laminectomy and vertebroplasty under the control of the eye, making it easier to inject cement into the vertebral body and to control the possible extravasation of the cement into the spinal canal.<sup>9</sup>

Studies to date have shown that PVP on the pathological vertebral spine provides quick relief of pain in up to 80% of patients and spine stability in about 87% of patients, thereby improving the quality of life.<sup>10</sup> Some studies have shown exceptional safety and efficacy using this method in the neck segment.<sup>11-15</sup> The posterior decompression with the addition of kyphoplasty, known as OKP, is recognized as a surgery convenient for pain reduction, neurological improvement, and spine stability. Hsiang (2003) was the first who, in 2003, treated osteoporotic fractures with compression of the spinal canal in 22 patients by this method.<sup>16</sup> Fuentes et al. (2009) reported recently on the use of OKP in a series of 18 patients with severe osteoporotic compression-related fractures associated with neurological disorders, all of which achieved significant pain reduction and neurological progress.<sup>17</sup> Furthermore, Marco et al. (2010) used OKP with calcium phosphate instead of PMMA to treat 38 relatively young and healthy patients suffering from unstable fractures with or without neurological deficits. They showed that this method reconstructed and stabilized the anterior column, restored the spine's height, indirectly and directly decompressed the spinal cord, reduced the deformation of the trunk, and stabilized the posterior column through a posterior approach.<sup>18</sup> Weitao and associates (2012) used open vertebroplasty (OVP) for treating 18 cases with metastatic lesions of the vertebral body which experienced excellent neurological recovery with a significant reduction in pain intensity, except in one case where cement leakage occurred in the lung vein due to the use of low viscous cement.<sup>19</sup> According to our knowledge, no study has evaluated the clinical outcome for patients with myeloma and neurological deficits treated with OKP.

With the development of minimally invasive

surgery methods, vertebral augmentation has been widely used for painful pathological vertebral fractures caused by myeloma. Yang and colleagues (2012) reported that vertebroplasty, in combination with chemotherapy in treating multiple myeloma-related spine fractures, has shown a significant improvement in pain relief<sup>20</sup>, where Štalo's study (2017) fits in researching vertebroplasty in myeloma patients.<sup>21</sup> Kyphoplasty, as a modified version of vertebroplasty, included inflation of the balloon inside the collapsed vertebrae to create the cavity and allow the PMMA discharge into it under reduced pressure, thus reducing the possibility of cement leakage. The report of Zou et al. (2010) included 21 myeloma patients with compression vertebral fracture who underwent 43 kyphoplasty procedures that provided significant and sustained pain reduction, resulting in significant functional improvement for multiple myeloma patients.<sup>22</sup> The impact of PMMA on the tumor tissue and stabilization of the fracture and pain reduction includes stabilization of the spine microfracture and bone structure improvement, monomeric cytotoxicity and thermal effect on the tumor cell and nerve endings, as well as obstruction of the tumor vascularization application by cement application.<sup>23</sup>

In our work, involving 23 patients, with an average age of 61 years, pain reduction from preoperative 8-point pain scores per VAS scale was reduced to 2.5 points immediately after surgery. The effect lasted until the last monitoring without the use of additional analgesics.

Similar results are reported by Jun Pan et al. (2013), with a reduction in pain from 8 to 2 per VAS scale using open kyphoplasty<sup>24</sup> while Fuentes, Boszczyk, Weitao, and Floeth recorded similar results to ours.<sup>14,17,19,25</sup>

Most authors report that the duration of decompression with augmentation by PMMA lasted from 10 to 90 minutes, depending on the number of affected segments. This also matches our study, where the average duration of the surgery was 60 minutes (45-70 minutes). No post-surgery blood transfusion has been recorded. Although some authors state improvement of neurological function in patients after open vertebroplasty or kyphoplasty, we did not notice this in our research. Still, there was no deterioration of the neurological status after the procedure.

It has been shown that both vertebroplasty and kyphoplasty significantly reduce pain due to spinal collapse caused by myeloma and metastases, but have the same complication, i.e. cement leakage into the spinal canal, neural foramina, or pulmonary vein system. Moreover, the incidence of cement



extravasation during vertebroplasty of fractures associated with metastasis is much higher than that associated with osteoporotic fractures due to bone osteolysis.<sup>24</sup> Lee and associates (2009) used a meta-analysis. They reported that the rate of symptomatic leakage is 10% cement in metastatic disease or myeloma and only 1% in osteoporotic collapse. Some other authors noticed leakage in treating fractures in plasmacytoma in more than 30% of cases.<sup>26</sup> Furthermore, leakage in vertebroplasty is much more frequent, primarily due to the application pressure being significantly higher. Likewise, using high-viscosity cement, the leakage rate is reduced considerably in vertebroplasty and almost identical tokyphoplasty.<sup>27</sup>

Unlike the percutaneous method, where the cement leakage control is significantly smaller, in the open method, no single cement leak was recorded in the open method. Other authors describe similar results, where the cement leakage control is significantly smaller, no single cement leak was recorded in the open method.

Other authors describe similar results. Weitaio describes one case of leakage into pulmonary veins, and Fuentes reported two intradiscal leakages.<sup>17,19</sup>

### Conclusion

Despite the small number of subjects in our research, we can say that open vertebroplasty is a highly effective minimally invasive procedure for treatment. Open vertebroplasty is a highly effective minimally invasive procedure for treating spinal vertebral body fractures due to myeloma or spinal metastatic diseases with associated spinal stenosis. It allows simultaneous spinal cord and nerve decompression and stabilization of the spine.

Although the small studies published so far suggest that it allows for excellent clinical results in relieving pain and recovering neuronal function with less blood loss, shorter working time, and fewer complications than some other open operating procedures.

### References

1. Begum R, Anwar MH. Validity and reliability of visual analogue Scale (VAS) for pain measurement. *J Med Case Rep Rev* 2019; 2:11.
2. Riihimäki M, Thomsen H, Sundquist K, Sundquist J, Hemminki K. Clinical landscape of cancer metastases. *Cancer Med* 2018 ;7:5534-5542.
3. Van den Brande R, Cornips EM, Peeters M, Ost P, Billiet C, Van de Kelft E. Epidemiology of spinal metastases, metastatic epidural spinal cord compression and pathologic vertebral compression

- fractures in patients with solid tumors: A systematic review. *J Bone Oncol* 2022;35:100446.
4. Rapan S, Jovanovic S, Gulan G, Boschi V. *Vertebroplastika. Med Flum* 2011;47: 29-36.
5. Wright E, Ricciardi F, Arts M et al. Metastatic Spine Tumor Epidemiology: Comparison of Trends in Surgery Across Two Decades and Three Continents. *World Neurosurg* 2018;114:e809-e817.
6. Gu YF, Li YD, Wu CG, Sun ZK, He CJ. Safety and efficacy of percutaneous vertebroplasty and interventional tumor removal for metastatic spinal tumors and malignant vertebral compression fractures. *AJR Am J Roentgenol* 2014 ;202:W298-305.
7. Pilitsis JG, Rengachary SS. The role of vertebroplasty in metastatic spinal disease. *Neurosurg Focus* 2001;11:e9.
8. Chew C, Craig L, Edwards R, Moss J, O'Dwyer PJ. Safety and efficacy of percutaneous vertebroplasty in malignancy: a systematic review. *Clin Radiol* 2011 ;66:63-72.
9. Wang B, Han SB, Jiang L et al. Intraoperative vertebroplasty during surgical decompression and instrumentation for aggressive vertebral hemangiomas: a retrospective study of 39 patients and review of the literature. *Spine J* 2018 ;18:1128-1135.
10. Rapan S, Batrnek J, Rapan V, Biuk E, Rapan D. Quality of Life in Patients Following Vertebroplasty. *Open Access Maced J Med Sci* 2017;5:42-47.
11. De la Garza-Ramos R, Benvenuti-Regato M, Caro-Orsorio E. Vertebroplasty and kyphoplasty for cervical spine metastases: a systematic review and meta-analysis. *Int J Spine Surg* 2016;10:7.
12. Shetty SR, Ganigi PM, Mandanna BK. Open C2 Vertebroplasty: Case Report, Technique, and Review of Literature. *Asian J Neurosurg* 2017;12:710-714.
13. Dorman JK. Vertebroplasty of the C2 vertebral body and dens using an anterior cervical approach: technical case report. *Neurosurgery* 2010;67:E1143-6.
14. Floeth FW, Herdmann J, Rhee S et al. Open microsurgical tumor excavation and vertebroplasty for metastatic destruction of the second cervical vertebra-outcome in seven cases. *Spine J* 2014;14:3030-7.
15. Guerre P, Kröber M. Open dorsal vertebroplasty of the axis. *Arch Orthop Trauma Surg* 2011;131:591-6.
16. Hsiang J. An unconventional indication for open kyphoplasty. *Spine J* 2003;3:520-3.
17. Fuentes S, Blondel B, Metellus P, Adetchessi T, Gaudart J, Dufour H. Open kyphoplasty for management of severe osteoporotic spinal fractures. *Neurosurgery* 2009;64(5 Suppl 2):350-4; discussion 354-5.
18. Marco RAW, Meyer BC, Kushwaha VP. Thoracolumbar burst fractures treated with posterior decompression and pedicle screw instrumentation supplemented with balloon-assisted vertebroplasty and calcium phosphate reconstruction. *Surgical technique. J Bone Joint Surg Am* 2010;92 Suppl 1 Pt 1:67-76.
19. Weitaio Y, Qiqing C, Songtao G, Jiaqiang W. Open vertebroplasty in the treatment of spinal metastatic disease. *Clin Neurol Neurosurg* 2012;114:307-12.

20. Yang Z, Tan J, Xu Y et al. Treatment of MM-associated spinal fracture with percutaneous vertebroplasty (PVP) and chemotherapy. *Eur Spine J* 2012 ;21:912-9.
21. Šutalo M. Vertebroplastika u liječenju prijeloma kralješka kod plasmocitoma. Diplomski rad. Sveučilište J. J. Strossmayera u Osijeku. Osijek 2017.
22. Zou J, Mei X, Gan M, Yang H. Kyphoplasty for spinal fractures from multiple myeloma. *J Surg Oncol* 2010 ;102:43-7.
23. Urrutia J, Bono CM, Mery P, Rojas C. Early histologic changes following polymethylmethacrylate injection (vertebroplasty) in rabbit lumbar vertebrae. *Spine (Phila Pa 1976)*. 2008;33:877-82.
24. Pan J, Qian ZL, Sun ZY, Yang HL. Open kyphoplasty in the treatment of a painful vertebral lytic lesion with spinal cord compression caused by multiple myeloma: A case report. *Oncol Lett* 2013;5:1621-1624.
25. Boszczyk B. Volume matters: a review of procedural details of two randomized controlled vertebroplasty trials of 2009. *Eur Spine J* 2010;19:1837-40.
26. Lee MJ, Dumonski M, Cahill P, Stanley T, Park D, Singh K. Percutaneous treatment of vertebral compression fractures: a meta-analysis of complications. *Spine (Phila Pa 1976)*. 2009;34:1228-32.
27. Rapan S, Krnić K, Rapan V, Kolarević V. Application of high viscosity bone cement in vertebroplasty for treatment of painful vertebral body fracture. *Med Glas (Zenica)*. 2016;13:148-53.



