

# Case Report: To Stop on Time - One of the Hardest Decisions: 'Loss' of the Stent in a Calcified RCA

---

**Rosović, Ivan; Avdagić, Damir; Miškulin, Rajko**

*Source / Izvornik:* **Acta clinica Croatica, 2024, 63., 116 - 119**

**Journal article, Published version**

**Rad u časopisu, Objavljena verzija rada (izdavačev PDF)**

<https://doi.org/10.20471/acc.2024.63.s1.22>

*Permanent link / Trajna poveznica:* <https://um.nsk.hr/um:nbn:hr:184:230767>

*Rights / Prava:* [Attribution-NonCommercial-NoDerivatives 4.0 International/Imenovanje-Nekomercijalno-Bez prerada 4.0 međunarodna](#)

*Download date / Datum preuzimanja:* **2024-11-25**



*Repository / Repozitorij:*

[Repository of the University of Rijeka, Faculty of Medicine - FMRI Repository](#)





# CASE REPORT: TO STOP ON TIME – ONE OF THE HARDEST DECISIONS: ‘LOSS’ OF THE STENT IN A CALCIFIED RCA

Ivan Rosović, Damir Avdagić and Rajko Miškulin

Thalassotherapia Opatija – Clinic for rehabilitation, treatment and prevention of heart and blood vessels diseases

**ABSTRACT** – A case report of a 63-year-old man who was indicated for invasive coronarography during outpatient treatment. The completed coronarography confirmed a significant stenosis in the highly calcified right coronary artery (RCA). In order to determine the hemodynamic significance of the borderline significant stenosis of the curved branch of the left coronary artery, FFR was performed. Despite the use of non-compliance balloons and high-pressure OPN balloons during elective PCI-RCA, the lesion in question could not be predilated, resulting in the need for the patient to undergo PCI-RCA with rotablation. During the repeated PCI-RCA procedure, the proximal and middle segments were subjected to rotablation. Non-compliant balloon catheters were used to perform a successful predilatation of the middle segment lesion and to try to place a stent in the designated lesion. Due to the calcified curve of the proximal segment, the stent was unable to pass through while being retracted into the leading catheter, causing it to fall into the proximal segment. The stent balloon was used to push the stent and insert it into the curve between the proximal and middle segment. A small balloon catheter (1.2 x 15 mm) successfully passed through the unexpanded stent. After subsequent inflating of the small balloon catheter and further inflating of larger balloons the lost stent was fully expanded and implanted with optimal control coronarography findings.

**Key words:** *coronary artery calcification, rotablation, high-pressure OPN balloon*

## Introduction

Calcified coronary artery stenoses are one of the leading challenges of interventional cardiology. Calcium is one of the main negative predictors of successful percutaneous coronary intervention in terms of the inability to position the stent, its adequate expansion, a possible fracture as well as its falling out of the stent balloon. Phenotypically speaking, there are two types of calcium: eccentric plaque (calcium affects  $< 270^\circ$  of the circumferent vessel lumen) and

concentric plaque (calcium affects  $> 270^\circ$  of the circumferent vessel lumen). The phenotype of calcified lesions is important in predicting the fracture when preparing the lesion. Namely, when dealing with eccentric calcified lesions, after the implementation of predilatation balloons, vessel dissection is expected at the thinnest non-calcified part of the vessel, especially at the transitions between the ‘normal’ and the calcified endothelium. Taking this into account, aggressive post-dilatation of the implanted stent in order to achieve an adequate lumen is not recommended as it may result in vessel perforation, particularly at the marginal transition points between the ‘normal’ endothelium and calcification. When using non-compliant, high-pressure balloons, scoring balloons, cutting balloons, and IVL to prepare concentric calcified

Corresponding author:

Ivan Rosović, Thalassotherapia Opatija, Ul. Maršala Tita 188, 51410 Opatija  
ivan\_rosovic@yahoo.com

lesions, the thinner areas of calcium are fractured without significantly affecting the remaining calcium. Therefore, in such extremely calcified lesions, it is recommended to perform rotablation with the aim of thinning the calcium circumferentially, obtaining a lumen and subsequently performing a successful predilatation and stent implantation.

### Case report

A 63-year-old man with symptoms of chronic coronary syndrome (progression of anginal complaints during exercise) was hospitalised in our institution for invasive coronarography following the findings of outpatient treatment (MSCT coronarography: high Ca score, heart ultrasound: hypocontractility of the lower and anterior wall parts, ergometry: depression of the ST junction up to -1.5 mm in inferior leads, native ECG: progression of changes – load-induced LVH). The coronarography confirmed a significant,

highly calcified stenosis of the middle segment of the right coronary artery (RCA) (**Figures 1 and 2**).

It furthermore confirmed a borderline significant stenosis of the curved branch of the left coronary artery, which was the reason to simultaneously perform FFR-LCX to confirm a hemodynamically insignificant stenosis (0.94 after intracoronary administration of adenosine) (**Figure 3**). The patient was then scheduled for an elective PCI-RCA. After two weeks, elective PCI-RCA was performed (right radial approach, introducer: 6F, guiding catheter: JR 4.0 SH). The extremely calcified stenosis of the middle segment of the RCA was passed by using a Runtrough guidewire and the wire was placed in the PD branch. For better support, another Whisper ES guidewire was placed in the PL branch. A series of predilatations was performed with balloon catheters NC Solarice (2.0 x 2 mm, 16 atm) and NC Trek (2.5 x 12 mm, 18 atm), but without results in the control coronarogram. Then a

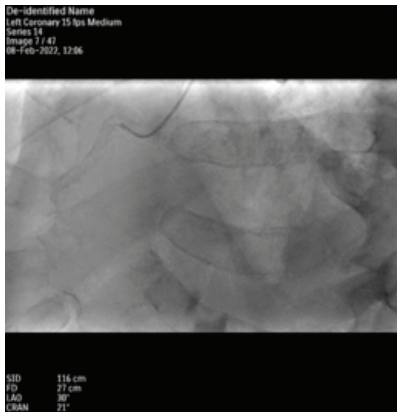


Figure 1: Native RCA (calcium)

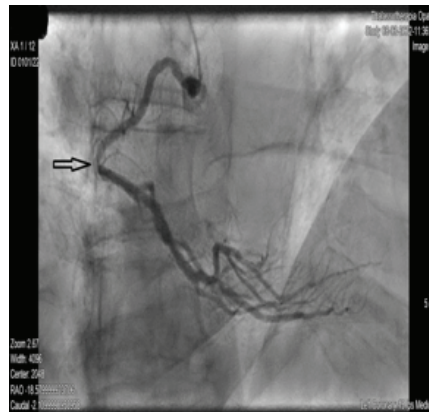

Figure 2: RCA

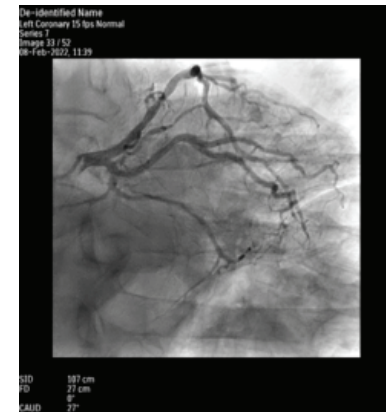

Figure 3: LCA

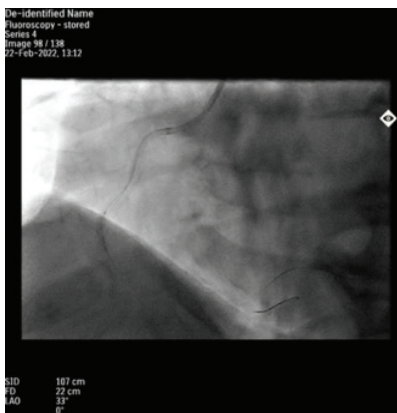


Figure 4

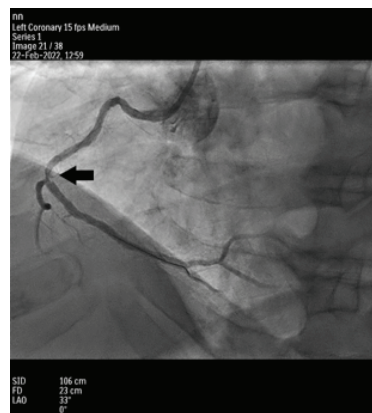


Figure 5

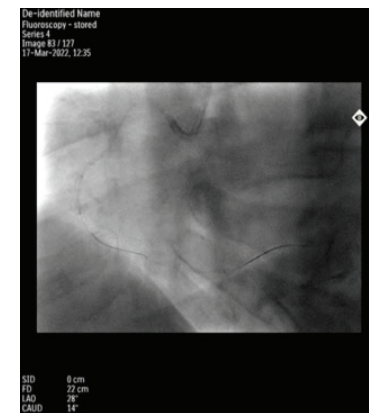


Figure 6

protracted dilatation was performed with an OPN NC balloon catheter (2.5 x 10 mm, 26 atm) (**Figures 4 and 5**), which also proved ineffective.

After that, an OPN NC balloon catheter (3.0 x 10 mm) was applied via extension with the Telescope catheter, but the extremely calcified proximal segment of the RCA was impossible to pass. The procedure was discontinued and the patient was indicated for a repeated PCI-RCA with rotablation. After three weeks, a second attempt at PCI-RCA with rotablation (right radial approach) was initiated. Since the origin of the right coronary artery could not be probed with the guiding catheter AR 1.0 SH (7F), the guiding catheter JR 4.0 SH (7F) had to be used. After the rota wire was placed in the terminal PD, several cycles of rotablation (Rota Link 1.50 mm) of the entire proximal and middle segment of the RCA were performed with a satisfactory control coronarogram

(**Figure 6**). Considering that at that time a shock wave was not available, we used rotablation to try to achieve grinding and microfracturing of calcium in the proximal and middle segment.

Accuforce (2.75 x 12 mm, 14 atm) and NC Quantum (Apex 3.5 x 8 mm, 16 atm) balloon catheters were used to dilate the middle segment lesion with an optimal control coronarogram (**Figure 7**). Then, an attempt was made to implant DES Orsiro (3.5 x 13 mm) into the middle segment lesion, but without success in reaching it. A catheter extension (Telescope) was placed, however, it also failed to pull up the above-mentioned stent, as well as the new shorter and smaller DE stent for easier deliverability of Resolute Onyx (3.0 x 8 mm). The Telescope was removed, and for better support, another Grand Slam guidewire was placed in the PL branch and the rail method applied to try to pull the DES Resolute Onyx stent (3.0

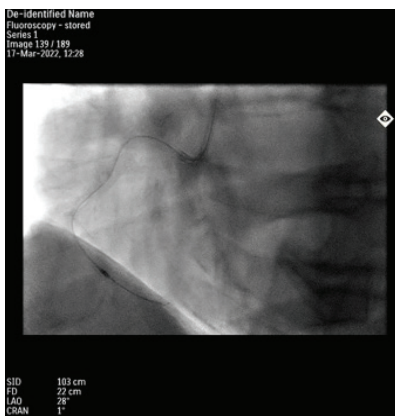


Figure 7

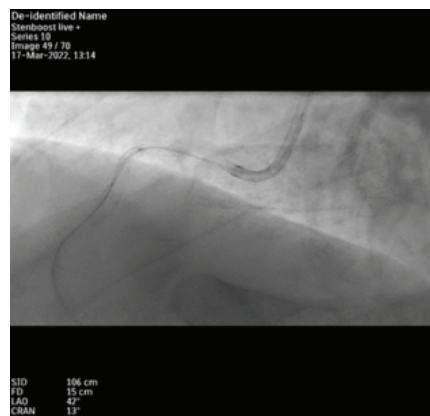


Figure 8

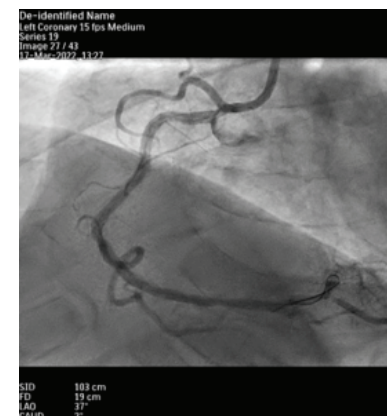


Figure 9

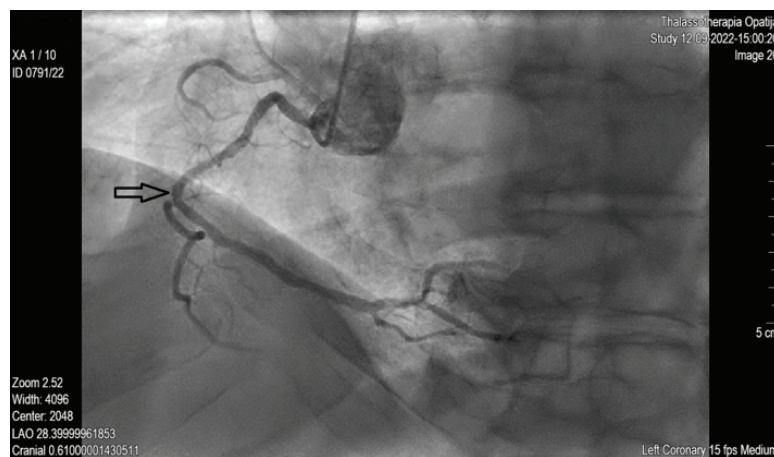


Figure 10

x 8 mm) to the middle segment lesion, but without success. During retraction of the stent into the guiding catheter, the stent fell out. By using the stent balloon, the stent was then pushed into the fold between the proximal and middle segment (**Figure 8**). The stent was then expanded by using balloon catheters Emerge (1.2 x 15 mm, 16 atm), Traveler (2.0 x 12 mm, 14 atm) and Pantera LEO (3.0 x 8 mm, 14 atm) in the specified position with optimal and complete expansion and apposition.

After that, another attempt was made to implant DES Orsiro (3.5 x 13 mm) into the middle segment lesion, but without success in reaching the lesion. The control coronarogram confirmed the dissection of the RCA orifice, which is why another DES Xience PRO (3.0 x 12 mm, 16 atm) was implanted in the orifice. With the NC Traveler balloon catheter (3.5 x 8 mm, 16 atm), the flair of the orifice was performed and an optimal control coronarogram achieved (**Figure 9**).

The hospitalisation went well and the patient was discharged home the next day with an instruction to repeat the coronarography in six months. At the first outpatient follow-up, scheduled one month after the procedure, the patient stated that he felt well and that he tolerated physical efforts much better with minimal chest oppression during intensive exercise. After six months, a control coronarography was performed, which confirmed the adequate passableness of the stents placed in the origin and the proximal segment of the RCA, as well as the adequate passableness of the middle segment at the POBA site (**Figure 10**).

## Discussion

Regardless of modern possibilities (high-pressure balloons, score balloons, cutting balloons, intravascular lithotripsy, coronary rotablation, catheter extensions, etc.), highly calcified coronary heart disease still represents a major challenge in interventional cardiology. The presented case shows all the complexities of calcification because it represents not only difficulty in the preparation of the lesions themselves, but also, as it turned out in our case, an insurmountable obstacle in the delivery of the stent at the site of the prepared lesion, which was not performed either with the help of catheter extension or with the help of buddy wire technique after the entire proximal segment had previously been rotatable. Moreover, when removing the stent into the guiding catheter, it fell out in the calcified proximal segment, which further complicated the

already extremely complex procedure. The following lesson can be drawn from this case: the choice of an adequate guiding catheter and the femoral approach (to achieve maximum support) are mandatory in the case of highly calcified lesions, and we believe that this was precisely the reason for our failure. Namely, after several unsuccessful probing attempts with the guiding catheter AR 1.0 SH (7F) through the right radial path, we continued the procedure with JR 4.0 SH (7F) using the same radial approach. We did not want to waste time converting the procedure and continuing with the right femoral approach, which would have most likely lead to successful probing with a ‘better’ guiding catheter (AR 1.0 SH or AL 1.0 SH (7F)) and ultimately to successful stent implantation. Paradoxically, the intention of saving time led to unexpected complications, failed stent implantation, prolongation of the procedure and unnecessary stress to the operator.

## Conclusion

Calcium poses the main threat to interventional cardiology. Calcified lesions should be approached in a structured manner, knowing that each such lesion carries a potential risk of developing complications. What an operator must bear in mind when embarking on such a ‘journey’ is the following: take all precautionary measures and recognise the moment when you should be satisfied with the achieved result and stop on time, which in the end was a difficult but correct decision in our case.

## References

1. Emile Mehanna, MD; J. Dawn Abbott, MD; Hiram G. Bezerra, MD, PhD. Optimizing Percutaneous Coronary Intervention in Calcified Lesions, *Circulation: Cardiovascular Interventions*. 2018;11:e006813, doi.org/10.1161/CIRCINTERVENTIONS.118.006813

## Sažetak

## PRIKAZ SLUČAJA: „STATI NA VRIJEME, JEDNA OD NAJTEŽIH ODLUKA: „GUBITAK“ STENTA U KALCIFICIRANOJ RCA“

*I. Rosović, D. Avdagić i R. Miškulin*

Prikaz slučaja šezdesettrogodišnjeg muškarca kojemu je temeljem ambulantno učinjene obrade indicirana invazivna koronarografija. Na učinjenoj koronarografiji verificirana je značajna stenoza izrazito kalcificirane desne koronarne arterije (RCA), a zbog granično značajne stenoze zavijene grane lijeve koronarne arterije, učinjen je FFR kojim se isključi hemodinamska značajnost iste. Pacijent je naručen na elektivnu PCI – RCA, ali, usprkos primjeni „non compliance“ balona te high pressure OPN balona, ne uspije se predilatirati navedenu leziju te se u pacijenta indicira pokušaj PCI-RCA uz pomoć rotablacije. Na ponovljenoj PCI-RCA, učini se rotablacija proksimalnog i srednjeg segmenta. Balon kateterima „non compliance“ učini se uspješna predilatacija lezije srednjeg segmenta i pokuša plasirati stent u navedenu leziju. Obzirom da se istim ne uspije proći kalcificirani zavoj proksimalnog segmenta prilikom retrakcije istoga u vodeći kateter dolazi do njegova ispadanja u proksimalni segment. Stent balonom navedeni stent se pogura i uglati u zavoju iz proksimalnog u srednji segment. Kroz neekspandirani stent uspije se proći malim balon kateterom (1,2x15mm) te njegovim napuhivanjem i daljnim napuhivanjem sve većih balona uspije u potpunosti ekspandirati i implantirati otpali stent uz optimalan kontrolni koronarografski nalaz.

Ključne riječi: *kalcificirana koronarna bolest, rotablacija, high pressure OPN balon*