

Enhanced Differentiation of Amiodarone-Induced Thyrotoxicosis Types Using Semi-Quantitative ^{99m}Tc-MIBI Uptake Analysis: A Pilot Study

Fischer, Leo; Girotto, Neva; Ilić Tomaš, Maja; Mavrinac, Martina; Lekić, Andrica; Antončić, Dragana; Bogović Crnčić, Tatjana

Source / Izvornik: **Medical Science Monitor, 2024, 30**

Journal article, Published version

Rad u časopisu, Objavljena verzija rada (izdavačev PDF)

<https://doi.org/10.12659/MSM.945444>

Permanent link / Trajna poveznica: <https://um.nsk.hr/um:nbn:hr:184:082986>

Rights / Prava: [In copyright](#)/[Zaštićeno autorskim pravom.](#)

Download date / Datum preuzimanja: **2025-02-02**



Repository / Repozitorij:

[Repository of the University of Rijeka, Faculty of Medicine - FMRI Repository](#)



Received: 2024.06.09
Accepted: 2024.08.05
Available online: 2024.09.02
Published: 2024.09.25

Enhanced Differentiation of Amiodarone-Induced Thyrotoxicosis Types Using Semi-Quantitative ^{99m}Tc-MIBI Uptake Analysis: A Pilot Study

Authors' Contribution:
Study Design A
Data Collection B
Statistical Analysis C
Data Interpretation D
Manuscript Preparation E
Literature Search F
Funds Collection G

BDEF 1 Leo Fischer
DE 1 Neva Giroto
BDE 1 Maja Ilić Tomaš
CD 2 Martina Mavrinac 
CD 3 Andrica Lekić
BD 4 Dragana Antončić 
ADE 1 Tatjana Bogović Crnčić

1 Department of Nuclear Medicine, Faculty of Medicine, University of Rijeka, Rijeka, Croatia
2 Department of Medical Informatics, Faculty of Medicine, University of Rijeka, Rijeka, Croatia
3 Department of Basic Medical Science, Faculty of Health Studies, University of Rijeka, Rijeka, Croatia
4 Clinical Department of Laboratory Diagnostics, Clinical Hospital Centre Rijeka, Rijeka, Croatia

Corresponding Author: Neva Giroto, e-mail: neva.giroto@uniri.hr

Financial support: This study was supported by the University of Rijeka – project code: uniri-pr-biomed-19-141495

Conflict of interest: None declared

Background: Technetium (^{99m}Tc)-labelled Methoxy-2-Isobutylisonitrile (MIBI) is a diagnostic lipophilic cationic radiotracer used to evaluate the cardiac, breast, thyroid, and parathyroid pathology. This study aimed to evaluate the role of MIBI combined with Tc-^{99m} pertechnetate thyroid scintigraphy, thyroid ultrasonography, and measurement of thyrotropin, thyroid hormones, and autoantibodies to subtype amiodarone-induced thyrotoxicosis (AIT) and the contribution of semi-quantitative analysis of MIBI uptake.


Material/Methods: This cross-sectional study included 36 patients with AIT who underwent thyrotropin, thyroid hormone, and autoantibody analysis using chemiluminescent method, ultrasonography, pertechnetate, and MIBI thyroid scintigraphy with semi-quantitative uptake, including calculation of the target-to-background ratio (TBR) with 2 different background regions. The MIBI washout rate (WR) was analyzed in all groups. Statistical analysis was performed using descriptive statistics, correlations, and the receiver operating characteristic curve – area under the curve (ROC-AUC). The results were compared with the control group.

Results: Based on visual and semi-quantitative analyses, patients were successfully categorized into AIT groups (AIT-1, AIT-2 and AIT-3) but the latter method enabled better differentiation of MIBI uptake between all groups. Additionally, ROC-AUC analysis determined cutoff values which enabled discerning between AIT-1 and AIT-2 groups, and AIT-1 and AIT-3 groups. WR showed no significant difference between all AIT groups and controls ($P>0.05$).

Conclusions: Visual MIBI analysis enabled differentiation between AIT-1 and 2 groups, but the method was substantially improved with semi-quantitative analysis, especially in defining AIT-3 group. However, multicenter collaboration with larger studies is needed to standardize the method and obtain more accurate and consistent results.

Keywords: Arrhythmia • Amiodarone • Technetium Tc 99m Sestamibi • Thyrotoxicosis

Full-text PDF: <https://www.medscimonit.com/abstract/index/idArt/945444>

 5192

 2

 7

 39



Publisher's note: All claims expressed in this article are solely those of the authors and do not necessarily represent those of their affiliated organizations, or those of the publisher, the editors and the reviewers. Any product that may be evaluated in this article, or claim that may be made by its manufacturer, is not guaranteed or endorsed by the publisher

Introduction

Thyrotoxicosis is a clinical condition characterized by elevated serum levels of thyroid hormones and decreased thyrotropin (TSH) level, with an incidence of 50 cases per 100 000 per year [1]. The most common causes are Graves's disease, multinodular toxic goiter and toxic adenoma, while less frequent causes include different types of thyroiditis. It can also be induced with iodine containing drugs, such as iodinated contrast media and amiodarone [1].

Amiodarone is commonly used to treat various supraventricular and ventricular tachyarrhythmias, especially in high-risk cardiac patients [2]. Amiodarone has structural similarities to thyroid hormones and contains about 37% of iodine by weight, which is why its average dosage significantly exceeds the recommended daily intake [3]. Desethylamiodarone, the main metabolite, remains in the body long after discontinuation of therapy [4].

Treatment with amiodarone is associated with several adverse effects, the most common of which are corneal microdeposits, elevated liver enzymes and thyroid dysfunction which has been reported in up to 18% of treated patients [5].

The thyroid adapts to increased iodine supply through the Wolff-Chaikoff effect, by inhibiting iodine organification and reducing thyroid hormone synthesis [6]. However, the adverse effects of amiodarone cannot only be explained by its high iodine content, as it also impairs deiodinases and interferes with the intracellular transport of thyroxine (T₄), consequently decreasing triiodothyronine (T₃) and increasing reverse T₃ levels [5,7]. A direct toxic effect on thyroid cells has also been described [8]. Also, regional iodine supply seems to play a role, since thyrotoxicosis occurs more frequently in regions with iodine deficiency, and hypothyroidism in areas with sufficient iodine intake [9].

The amiodarone-induced thyroid side effects are amiodarone-induced hypothyroidism (AIH), a consequence of the inability of the thyroid gland to escape the Wolff-Chaikoff effect, easily treated with levothyroxine, and amiodarone-induced thyrotoxicosis (AIT) [5,10,11].

AIT can present as amiodarone-induced thyrotoxicosis type 1 (AIT-1) and type 2 (AIT-2) [11,12].

AIT-1 usually develops in patients with pre-existing thyroid pathology (autoimmune changes or multinodular goiter) and is caused by excess iodine in the drug, while AIT-2 develops as a result of the damage to thyroid tissue due to the direct cytotoxic effect of the drug [11,12]. In addition to AIT-1 and AIT-2, a mixed type (AIT-3) is also reported, in which both pathogenic mechanisms seem to occur simultaneously [13].

Amiodarone-induced thyrotoxicosis is more challenging to treat than AIH, especially in cardiac patients, as it can exacerbate pre-existing conditions such as atrial fibrillation, which increases morbidity and mortality rates [14]. Thionamides, sometimes with the addition of perchlorate, are used in AIT-1, while AIT-2 is usually treated with glucocorticoids, but the discontinuation of amiodarone is recommended in most cases [13,14]. The treatment becomes more complex when elements of both types of AIT coexist, usually with a combination of both drugs therefore, an accurate diagnosis of the underlying cause of thyrotoxicosis with the distinction between AIT-1 and AIT-2 is required [13,15,16]. In refractory cases, a total thyroidectomy is necessary [16,17].

The presence of nodular goiter or Graves' ophthalmopathy, and the high levels of autoantibodies to thyroid peroxidase (TPOAb), thyroglobulin (TGAb), and the TSH receptor (TSI) are more suggestive of the AIT-1 type, but a concomitant destructive process in the thyroid gland cannot be excluded [18]. Inflammatory parameters such as the C-reactive protein (CRP) and interleukin-6 (IL-6) are indicative of AIT-2 but can sometimes be false negative [19].

Thyroid ultrasound with color flow Doppler sonography (CFDS) often shows increased vascularity in AIT-1 patients, but not in AIT-2. [20].

Normal or high 24-h thyroid radioiodine uptake (RAIU) is more typical of AIT-1, but differences in patient iodine intake seem to affect the diagnostic accuracy of RAIU [16,21].

Thyroid scintigraphy with ^{99m}Tc-Methoxy-2-Isobutylisonitrile (MIBI, or sestaMIBI), otherwise used for myocardial and parathyroid imaging and in evaluation of thyroid nodules, has also been proposed for differentiation between AIT types [22,23,24]. MIBI is a complex lipophilic molecule with a positive charge that accumulates in tissues with high mitochondrial content, after passively crossing the cell membrane [23,24]. It is also known to be related to multidrug resistance-gene expression [24].

AIT-1 has been shown to be associated with normal or increased thyroid MIBI uptake due to underlying hyperthyroidism and increased cellular mitochondrial content [25,26,27]. In AIT-2, MIBI does not accumulate in the thyroid as the parenchyma is involved with cell destruction [25,26,27].

However, as visual distinction between the types in question is not straightforward, and mixed form exists as well, semi-quantitative methods have been proposed, mostly involving the target-to-background ratio of MIBI uptake (TBR) [26,27]. The results have not yet been confirmed in larger studies, and the differentiation of the AIT-3 type has not yet been clarified.

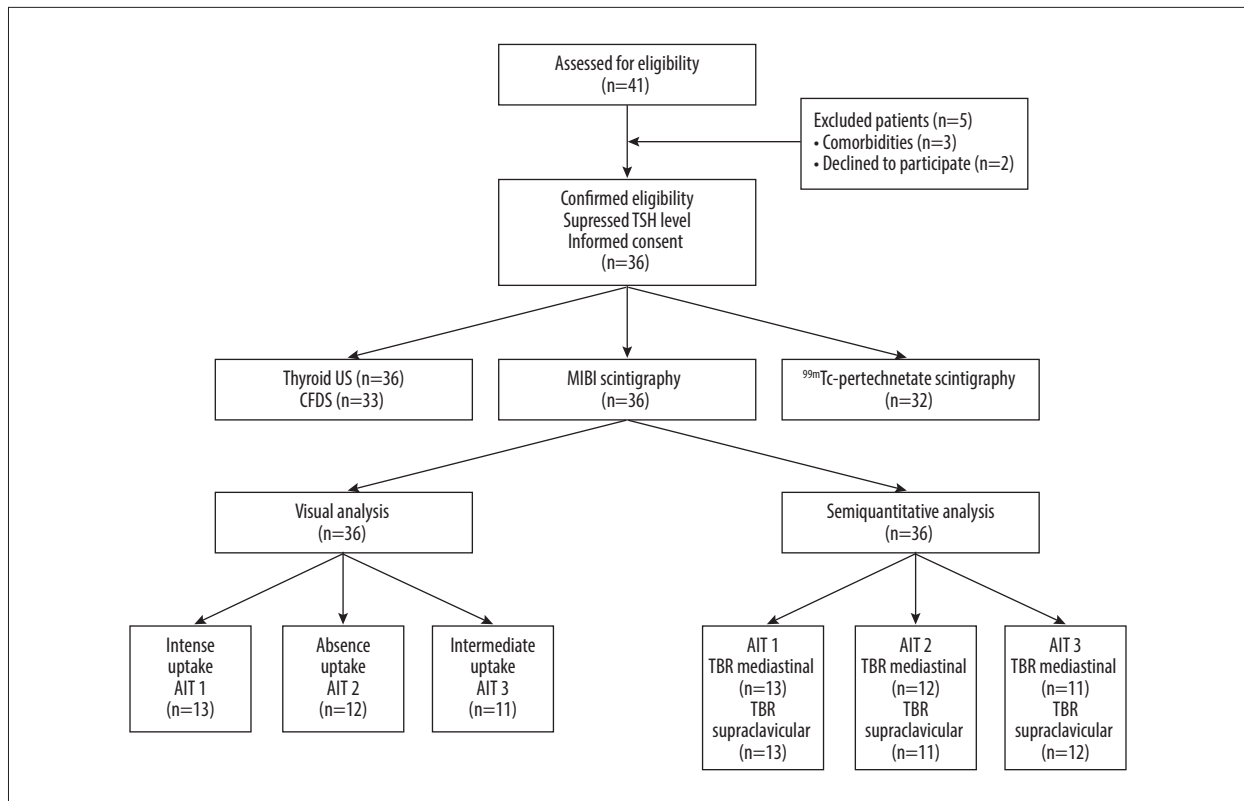


Figure 1. Study flowchart. TSH – thyrotropin; US – thyroid ultrasonography; CFDS – color Doppler flow sonography; MIBI – ^{99m}Tc-Methoxy-2-Isobutylisonitriile; AIT – amiodarone-induced thyrotoxicosis; TBR – target-to-background ratio.

Therefore, this study aimed to evaluate the role of visual MIBI uptake assessment improved by semi-quantitative analysis and washout kinetics, combined with Tc-99m pertechnetate thyroid scintigraphy, thyroid ultrasonography and measurement of thyrotropin (TSH), thyroid hormone, and autoantibodies to subtype amiodarone-induced thyrotoxicosis (AIT) in 36 patients.

Material and Methods

Ethics Statement

The Ethics Committee of the Clinical Hospital Center Rijeka, Croatia approved the study (Register No. 003-05/20-1/50; 2170-29-02/1 and 003-05/23-1/34; 2170-29-02/1-23-2), and all patients signed a written statement of informed consent. The study was performed following institutional guidelines, and all clinical procedures were carried out in accordance with the Declaration of Helsinki.

Participants

For this cross-sectional study conducted at the Clinical Department of Nuclear Medicine, Clinical Hospital Center Rijeka, Croatia from February 2019 to August 2022, a total

of 41 patients with amiodarone-induced thyrotoxicosis were considered potentially eligible out of the total number of patients referred due to amiodarone-induced thyroid dysfunction. Euthyroid or hypothyroid patients on amiodarone treatment with a history of thyroid disease therapy, pregnant women, and patients under 18 and over 90 years of age were excluded.

From the total of 41, 3 patients were additionally excluded due to significant comorbidities, and 2 later declined to participate (Figure 1).

The sample ultimately consisted of 36 patients, 10 females and 26 males. A power analysis was calculated to estimate the number of patients required for the calculation of the receiver operating characteristic curve (ROC), and a sample of 29 participants was obtained.

Study Design

The diagnosis of AIT for each patient was made based on ongoing amiodarone treatment or amiodarone withdrawal within 10 months of thyrotoxicosis onset, clinical and biochemical parameters indicating thyrotoxicosis, according to the current diagnostic clinical guidelines [13,16,28]. All patients had

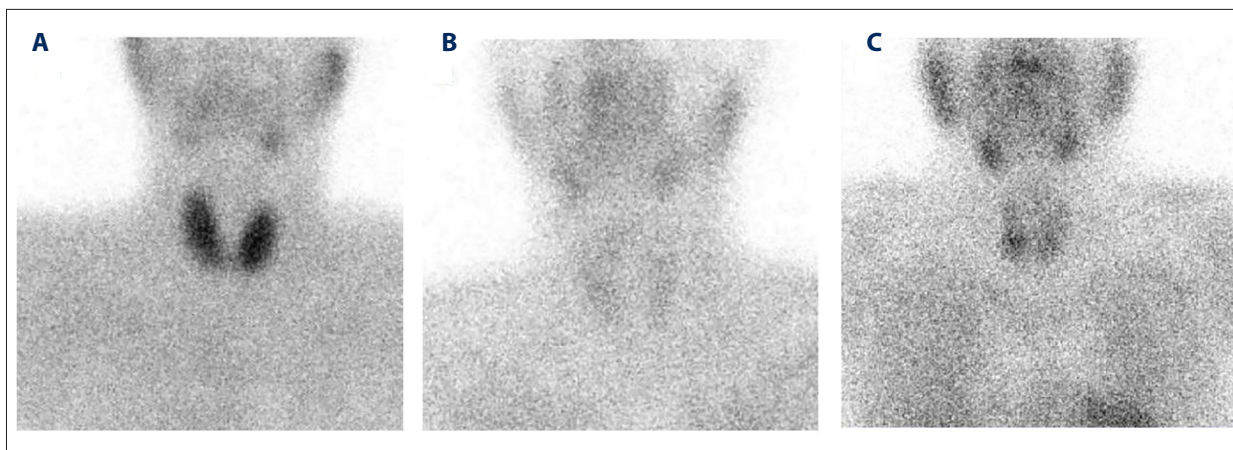


Figure 2. (A-C) ^{99m}Tc -Methoxy-2-Isobutylisonitrile (MIBI) thyroid scintigraphy at 10 min post-injection, anterior projection (early images). Images of amiodarone-induced thyrotoxicosis (AIT) groups (A – AIT-1, B – AIT-2, C – AIT-3).

suppressed serum TSH level, elevated levels of free thyroxine (FT4) and/or free triiodothyronine (FT3).

In addition, the serum levels of TPOAb, TGAb and TSI were determined. All patients underwent MIBI thyroid scintigraphy and ultrasonography, and in 33 out of 36 patients, vascularization was assessed with CFDS. Finally, 32 out of 36 patients also underwent ^{99m}Tc -pertechnetate scintigraphy.

To assess MIBI accumulation in healthy thyroid tissue, a control group was formed from euthyroid patients referred to MIBI scintigraphy due to elevated parathyroid hormone levels between May 2017 and April 2022. Of 466 patients, 30 were included, meeting the following criteria: normal TSH levels, no history of treatment with amiodarone, levothyroxine or anti-thyroid drugs, normal thyroid ultrasonography or thyroid without autoimmune changes. Thyroid nodules, if present, were less than 1 cm in size and metabolically inactive, and no parathyroid mass was discovered on MIBI scintigraphy.

Blood Collection and Thyroid Hormone Analysis

Blood samples were collected for each participant using Vacuette tubes with a gel separator and clot activator (Greiner Bio-One GmbH, Kremsmünster, Austria). Phlebotomy was performed according to the Joint EFLM-COLABIOCLI Recommendation for venous blood sampling [29]. According to the manufacturer's recommendation, samples were left at room temperature for 30 min (clot formation) and then centrifuged for 10 min at $1972\times g$ in a Sigma 2-16PK centrifuge (Sigma Laborzentrifugen GmbH, Osterode am Harz, Germany). All samples were analyzed on the same day. Concentrations of TSH, FT4, FT3, TGAb and TPOAb were measured using a chemiluminescent immunochemical assay (CLIA) on Siemens Atellica IM 1600 analyzer (Siemens Healthcare Diagnostics, Dublin, Ireland). The TSI concentration was measured using the same method (CLIA)

on Siemens Immulite 2000 XPi analyzer (Siemens Healthcare Diagnostics, Dublin, Ireland). The normal values were: TSH (0.55-4.78 mIU/L), FT3 (2.3-6.3 pmol/L), FT4 (11.5-22.7 pmol/L), TPOAb (<35 IU/L), TGAb (<40 IU/L) and TSI (<0.1 IU/L).

Quality control for the determination of all analytes was performed once daily using commercial control material. The measurement of TSH, FT4, and FT3 was monitored using Bio-Rad Liquicheck Immunoassay Controls (Bio-Rad, Hercules, California, USA), while the other analytes were monitored with control material provided by the reagent manufacturer (Siemens Healthcare Diagnostics, Dublin, Ireland).

Thyroid Ultrasonography

All patients underwent ultrasonography of the neck using an Arietta 50 ultrasound machine (Hitachi, Ltd., Tokyo, Japan) with a linear probe of 5-13 MHz. The dimensions of the thyroid gland were determined, and its volume was estimated using the ellipsoid equation formula including a correction factor: $V \text{ (mL)} = \text{length (cm)} \times \text{width (cm)} \times \text{depth (cm)} \times 0.529$ [30]. The reference range for normal thyroid volume was considered to be 10 to 15 mL for adult women and 12 to 18 mL for men [31]. The echogenicity of the parenchyma, the presence of autoimmune changes and possible nodules were assessed. CFDS was used to assess vascularization, which was subsequently graded as normal (0), mildly increased (1), and markedly increased (2).

MIBI Scintigraphy

MIBI imaging was performed using a Symbia T hybrid SPECT-CT (Siemens Healthineers, Erlangen, Germany) and standard eCam dual-head gamma cameras (Siemens Healthineers, Erlangen, Germany) with a low-energy high-resolution collimator, after intravenous injection of 370 MBq of MIBI (Stamicis, Curium Pharma, London, UK) prepared according to the manufacturer's

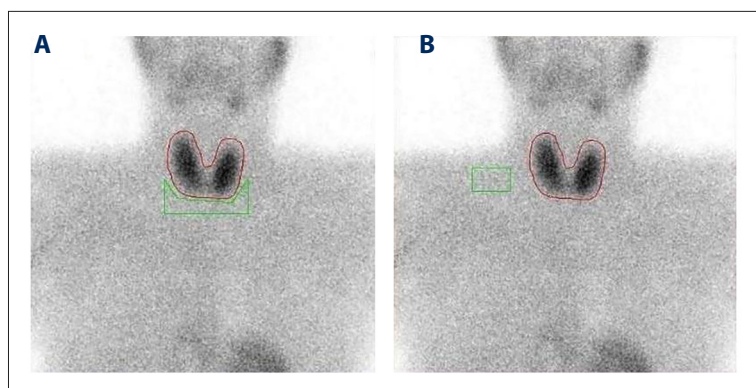

Figure 3. ^{99m}Tc -Methoxy-2-Isobutylisonitrile (MIBI) thyroid scintigraphy at 10 min post-injection, anterior projection (early images). Thyroid and mediastinal regions of interest (A), thyroid and supraclavicular regions of interest (B).

instructions. Two planar images of the neck and the upper mediastinum in anterior projection were acquired at 10 (early images) and 60 minutes (late images) with an acquisition time of 10 minutes, using a 256×256 matrix and zoom 2. Visual analysis of MIBI accumulation was performed by a consensus of 4 experienced nuclear medicine physicians. Based on the intensity of tracer uptake on the early images, 3 groups of patients were defined as follows: AIT-1 group (intense MIBI uptake), AIT-2 group (absent or minimal MIBI uptake) and AIT-3 group (intermediate MIBI uptake) (Figure 2).

For the semi-quantitative analysis of MIBI uptake on the early images, regions of interest (ROI) were drawn over the entire thyroid gland, along with 2 different background regions (BG ROIs) – a single polygonal ROI in the upper mediastinal region and a single rectangular ROI in the right supraclavicular region (Figure 3).

The average number of counts was determined for each region, and the target-to-background ratio (TBR) was calculated for the early images using the following formula:

$$\text{TBR} = (\text{average thyroid gland counts} - \text{average background counts}) / \text{average background counts}$$

Results were grouped by percentiles: ratios between the 66.66th and the 100th percentile indicated the highest thyroid MIBI uptake and were classified as the AIT-1 group, ratios between the 0th and the 33.33rd percentile were classified as the AIT-2 group, and ratios between the 33.33rd and the 66.66th percentile were classified as the AIT-3 group. The ratios were obtained for each background ROI, mediastinal (TBR mediastinal) and supraclavicular (TBR supraclavicular).

The MIBI washout rate (WR) was calculated as the percentage of the reduction of thyroid MIBI uptake on late images [32]. The same ROIs over the thyroid used on early images were copied onto the late images, and the WR was calculated using the following equation:

$$\text{WR} = [(\text{early counts} - \text{delayed counts}) / (\text{early counts})] \times 100 (\%)$$

The values obtained were presented with a median and interquartile range for all 3 patient groups, visually classified as AIT-1, AIT-2 and AIT-3, and the controls.

^{99m}Tc -Pertechnetate Scintigraphy

^{99m}Tc -pertechnetate thyroid imaging was performed using a Symbia T hybrid SPECT-CT (Siemens Healthineers, Erlangen, Germany) and standard eCam dual-head gamma cameras (Siemens Healthineers, Erlangen, Germany) with a low-energy high-resolution collimator. Fifteen minutes after the injection of 74 MBq of ^{99m}Tc -pertechnetate, five-minute planar images acquisition time, using a 256×256 matrix and zoom 2 were acquired in anterior projection with the neck slightly extended. The scintigrams were visually analyzed and classified as positive if thyroid uptake was higher than the background activity and negative if only the background activity was present.

Statistical Analysis

The categorical data collected during the study were presented with absolute and relative values, while the numerical data were presented with median and interquartile ranges (IQR). Age was presented with median and absolute ranges. Non-parametric tests were used because the data are not distributed according to a normal distribution.

Comparisons of TBRs and WRs between the AIT-1, AIT-2, AIT-3 and control groups were calculated using the Kruskal-Wallis test and the Dunn post-hoc test. Data were displayed using Box and Whisker plots.

The receiver operating characteristic curve – area under the curve (ROC-AUC) was used to determine the sensitivity and specificity of TBR and WR and to calculate the optimal cutoff value for semi-quantitative parameters. The criterion for categorizing patients into AIT groups was determined using ROC analysis, and the efficiency of the criterion was determined by the area under the curve (AUC). The correlation between variables was tested using Spearman's (r_s) correlation coefficient.

Statistical analyses were performed using MedCalc version 20.021 (MedCalc Software, Mariakerke, Belgium) and Statistica TIBCO version 14.0.0.15 (Copyright© 2022 Cloud Software Group, Inc.). All *P* values less than 0.05 were considered statistically significant.

Results

Patient Characteristics

A total of 36 participants were included in the study (10 female and 26 male). The median age was 69.5 years (range: 36-84 years).

All patients were treated with amiodarone (25-400 mg per day, median 200 mg) for a period of 2 to 60 months (median 24 months), except for one patient who was treated with amiodarone for 9 years before the onset of symptoms. In all cases, amiodarone was discontinued at the time of referral or earlier, and the longest period between the discontinuation of therapy and the first visit was 10 months.

Thyroid MIBI Scintigraphy in AIT

Visual Analysis of MIBI Thyroid Uptake

According to the visual analysis, 13 patients with intense MIBI uptake at 10 minutes after injection were classified into the AIT-1 group, while 12 patients with none or minimal MIBI accumulation were classified into the AIT-2 group. Eleven patients had intermediate MIBI uptake and were classified into the AIT-3 group or mixed type.

Visual Analysis Comparisons with Biochemical and Imaging Data in AIT Patients

The ultrasonographic and ^{99m}Tc-pertechnetate scan data of the patients as well as the classification of patients into AIT groups 1-3 according to the visually assessed MIBI uptake intensity are shown in **Table 1**.

The median duration of amiodarone therapy varied between the groups. The longest median was 36 months (range 12-108) in the AIT-2 group, followed by 12 months (range 6-60) in the AIT-3 group and 8 months (range 2-36) in the AIT-1 group, but the difference between the groups was not statistically significant (*P*=0.117). There were also no significant differences in amiodarone doses between the groups (data not shown, *P*=0.828).

The TSH serum concentration was undetectable or below the lower limit in all patients. The median values of FT4 in groups AIT-1, AIT-2, and AIT-3 were 24.80 pmol/L (IQR 23.09-28.60),

41.80 pmol/L (IQR 30.75-55.65) and 28.10 pmol/L (IQR 25.10-36.86), and those of FT3 were 6.27 pmol/L (IQR 5.08-9.81), 8.20 pmol/L (IQR 6.41-13.40) and 7.00 pmol/L (IQR 6.24-7.80), respectively. A total of 13 patients tested positive for thyroid autoantibodies, mainly in the AIT-1 group, in which all 3 antibody types were equally represented: 3 patients with positive TSI, 3 with elevated TPOAbs and 3 with positive TgAbs. In the AIT-2 group there were 3 TSI-positive patients, 2 with elevated TPOAb and 1 with positive TgAbs. In the AIT-3 group, only 2 patients had elevated TPOAbs. There were no significant differences in the prevalence of thyroid autoantibodies between the AIT groups (data not shown, *P*=0.971).

A thyroid ultrasonography was performed in all patients, and CFDS was performed in 33 of 36 patients to assess vascularization. The thyroid was enlarged in 9 out of 13 patients in the AIT-1 group, 3 out of 12 patients in the AIT-2 group, and 5 out of 11 patients in the AIT-3 group. In the majority, thyroid parenchyma vascularization was normal, except for 8 patients (2 from the AIT-1 group, 3 from the AIT-2 group and 3 from the AIT-3 group), in whom it was mildly or markedly increased. The frequency of autoimmune and nodular changes in thyroid parenchyma was similar in all groups (**Table 1**; *P*=0.613 and *P*=0.347, respectively).

A ^{99m}Tc-pertechnetate scan was performed in 32 out of 36 patients and was negative in all except 3 patients from the AIT-1 group and one patient from the AIT-2 group, where the thyroid uptake was higher than the background activity (**Table 1**).

Semi-Quantitative Analysis of MIBI Thyroid Uptake with Mediastinal Background Region

After calculating the target-to-background MIBI uptake ratio using the mediastinal region (TBR mediastinal) by percentiles, 13 patients were assigned to the AIT-1 group, 12 patients to the AIT-2 group, and 11 to the AIT-3 group. The AIT-1 group had the highest value of MIBI uptake with a median of 0.77 (IQR: 0.69-0.93), followed by the AIT-3 group with a median of 0.57 (IQR: 0.51-0.59), while the AIT-2 group had the lowest MIBI uptake ratio with a median of 0.36 (IQR: 0.32-0.39). The differences in TBR mediastinal between all AIT groups were statistically significant (*P*<0.001) (**Figure 4A**). Compared to the visual method, the semi-quantitative analysis based on TBR mediastinal reclassified a total of 14 patients into different AIT groups, but only 2 of them switched between group 1 and group 2.

In the control group, the TBR mediastinal median value was 0.67 (IQR: 0.55-0.77), and thus significantly higher than in the AIT-2 group (*P*<0.001). Comparisons of the control group with other AIT groups were also performed and were not statistically significant (**Figure 4A**).

Table 1. Imaging data of patients with amiodarone-induced thyrotoxicosis (AIT) categorized in 3 groups (AIT-1, AIT-2 and AIT-3), according to the visual analysis of the ^{99m}Tc-Methoxy-2-Isobutylisonitrile (MIBI) uptake.

Patients	AIT groups according to visual MIBI uptake	Thyroid ultrasonography			Scintigraphy with ^{99m} Tc pertechnetate	
		Volume	AITD	CDFS		Nodules
1	1	2	-	0	+	-
2	1	2	+	0	+	-
3	1	1	-	2	-	+
4	1	2	+	2	-	+
5	1	2	-	0	+	-
6	1	2	-	0	+	+
7	1	3	+	0	+	NA
8	1	2	+	0	+	-
9	1	3	+	0	-	-
10	1	2	-	0	-	-
11	1	2	-	NA	+	-
12	1	2	-	0	+	-
13	1	1	+	0	-	-
14	2	1	-	NA	+	-
15	2	1	-	1	-	-
16	2	2	-	0	-	-
17	2	1	+	0	-	-
18	2	1	-	0	+	-
19	2	3	-	2	+	-
20	2	1	+	0	-	-
21	2	2	+	0	-	-
22	2	1	+	0	-	-
23	2	1	-	2	-	+
24	2	1	-	0	+	-
25	2	2	+	0	-	NA
26	3	2	-	NA	+	-
27	3	3	-	2	+	-
28	3	2	+	2	-	-
29	3	2	-	0	-	-
30	3	1	+	2	-	-
31	3	1	-	0	+	-
32	3	2	+	0	+	-

Table 1 continued. Imaging data of patients with amiodarone-induced thyrotoxicosis (AIT) categorized in 3 groups (AIT-1, AIT-2 and AIT-3), according to the visual analysis of the ^{99m}Tc-Methoxy-2-Isobutylisonitrile (MIBI) uptake.

Patients	AIT groups according to visual MIBI uptake	Thyroid ultrasonography			Scintigraphy with ^{99m} Tc pertechnetate	
		Volume	AITD	CDFS		
33	3	2	–	0	+	–
34	3	1	+	0	–	NA
35	3	1	+	0	+	–
36	3	1	–	0	–	NA

AIT – amiodarone-induced thyrotoxicosis; MIBI – ^{99m}Tc-Methoxy-2-Isobutylisonitrile; AITD – autoimmune thyroid disease (present +, absent –), thyroid ultrasonography (volume within – 1, above – 2, below normal range – 3); CDFS – color Doppler flow sonography (normal – 0, mildly increased – 1, markedly increased vascularization – 2), thyroid nodules (present +, absent –), scintigraphy with ^{99m}Tc-pertechnetate (uptake higher than background +, only background activity –); NA – not available.

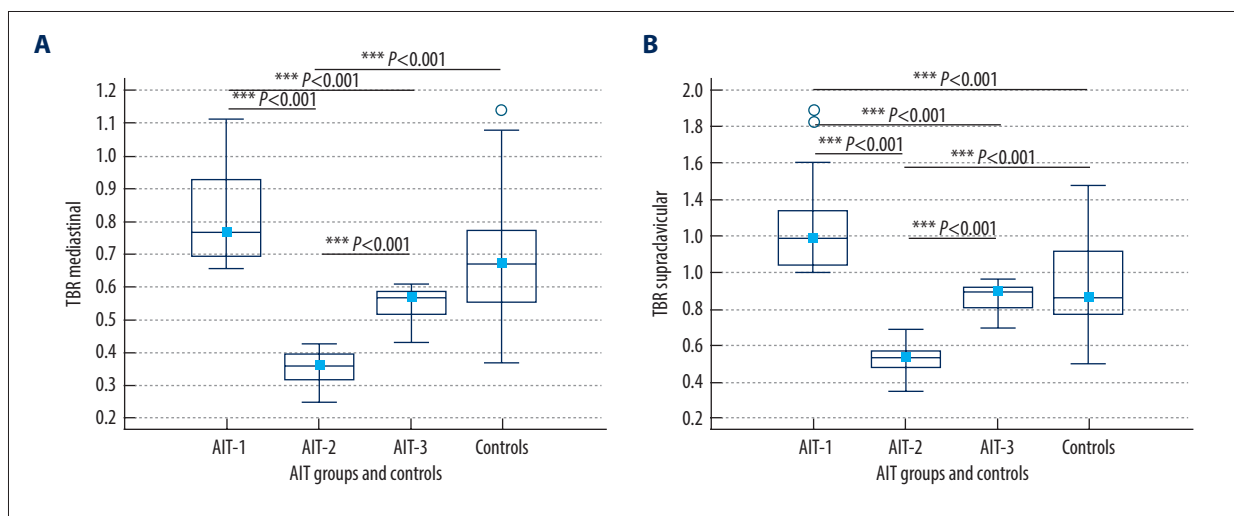


Figure 4. Comparison of ^{99m}Tc-Methoxy-2-Isobutylisonitrile (MIBI) thyroid uptake target-to-background ratios (TBRs) in amiodarone-induced thyrotoxicosis (AIT-1, AIT-2, AIT-3) and control groups. Using the mediastinal background region (TBR mediastinal), the differences in MIBI uptake between all AIT groups were statistically significant, while the control group had a significantly higher uptake compared to the AIT-2 group (A). Using the supraclavicular background region (TBR supraclavicular), the differences in MIBI uptake between all AIT groups were statistically significant. The control group had a significantly lower MIBI uptake compared to the AIT-1 group and a significantly higher uptake compared to the AIT-2 group (B). Results are presented as median, interquartile ranges and total range. Level of statistical significance: *** $P < 0.001$ (MedCalc Software, version 20.021, Mariakerke, Belgium).

Semi-Quantitative Analysis of MIBI Thyroid Uptake with Supraclavicular Background Region

After calculating the target-to-background MIBI uptake ratio using the supraclavicular background region (TBR supraclavicular), 13 patients were categorized into the AIT-1 group, 11 into the AIT-2 group, and 12 into the AIT-3 group. The AIT-1 group had the highest MIBI uptake TBR (median 1.19; IQR 1.04-1.34), the AIT-3 group had a median of 0.89 (IQR 0.80-0.92), and the AIT-2 group had the lowest MIBI uptake ratio (median 0.53;

IQR 0.48-0.57). The differences between all AIT groups were statistically significant ($P < 0.001$) (Figure 4B).

In the control group, the median TBR supraclavicular was statistically different from the median TBR supraclavicular in groups AIT-1 and AIT-2 (all $P < 0.001$). The AIT-1 had a significantly higher uptake than the control group (median 0.86; IQR 0.77-1.12). On the other hand, the AIT-2 group had a significantly lower uptake than the control group (Figure 4B).

Table 2. The correlation between visual analysis and target-to-background ratio of ^{99m}Tc -Methoxy-2-Isobutylisonitrile (MIBI) uptake results using the mediastinal and supraclavicular regions of interest in all amiodarone-induced thyrotoxicosis groups.

Pair of variables N=36	Spearman (r_s)	P-value
Visual & TBR mediastinal ROI	0.34	0.043
Visual & TBR supraclavicular ROI	0.24	0.148

TBR – target-to-background ratio; ROI – region of interest.

Compared to the visual method, following the semi-quantitative analysis using supraclavicular TBR, 16 patients altogether were reclassified into different AIT groups, but only 3 of them switched between group 1 and group 2.

The Correlation Between Visual and Semi-Quantitative Analysis

To compare the results of the semi-quantitative analysis with those of the visual analysis, a correlation between the 2 methods was performed. The correlation between the results of the visual analysis and the calculation of the target-to-background MIBI uptake ratio using the mediastinal region was positive and significant, with the $r_s=0.34$ ($P=0.043$). However, the correlation between the results of the visual analysis and the calculation of the MIBI uptake TBR using the supraclavicular region was not statistically significant, with the $r_s=0.24$ ($P=0.148$) (Table 2). On the other hand, a positive, very good to excellent correlation was found between the 2 different background regions ($r_s=0.76$, $P<0.001$).

Cutoff Values to Differentiate AIT Types with ROC-AUC Analysis

The ROC-AUC analysis was introduced to determine the cutoff values for the TBR of the MIBI uptake to more accurately distinguish the AIT-1 group from the AIT-2 group using both mediastinal and supraclavicular background regions.

A cutoff value of ≤ 0.422 was determined using the mediastinal background region (100% sensitivity, 100% specificity, AUC=1) and that of ≤ 0.687 using the supraclavicular region (100% sensitivity, 100% specificity, AUC=1) (Figure 5).

The ROC-AUC analysis was also performed to determine cutoff values for the target-to-background ratio of MIBI uptake between the AIT-1 group and the AIT-3 group using both the mediastinal and supraclavicular background regions.

A cutoff value of ≤ 0.607 was determined using the mediastinal region (100% sensitivity, 100% specificity, AUC=1) and that of ≤ 0.962 using the supraclavicular region (100% sensitivity, 100% specificity, AUC=1) (Figure 6).

Thyroid MIBI Washout Rates

MIBI washout rates were calculated in patients visually categorized into the AIT-1, AIT-2, AIT-3 and control groups.

The median MIBI WR in the control group was 28.4% (IQR 23.15-40.76%). There were no significant differences in the WR between patients in groups AIT-1, AIT-2 and AIT-3 and the control group (all $P>0.05$) (Figure 7).

Discussion

The diagnosis of amiodarone-induced thyrotoxicosis is usually straightforward, but differentiation between specific AIT types remains challenging, although necessary in order to choose the appropriate treatment modality. To address this, several laboratory tests and imaging methods have been introduced, including MIBI scintigraphy with visual analysis [33]. However, using MIBI for visual distinction between the types in question is not straightforward, especially in selecting mixed cases. Therefore, this study aimed to evaluate the role of visual MIBI uptake assessment, enhanced with semi-quantitative analysis and washout kinetics to subtype AIT in 36 patients. Comparisons with Tc-99m pertechnetate thyroid scintigraphy, thyroid ultrasonography and measurement of thyrotropin, thyroid hormones and autoantibodies were also performed.

According to the visual evaluation, patients were easily categorized in AIT-1 and AIT-2 groups in cases when MIBI uptake was clearly positive or absent, but the mixed, AIT-3 type was more difficult to define. Therefore, we introduced the semi-quantitative analysis using 2 different BG regions (mediastinal and supraclavicular) as a more objective approach that could increase diagnostic accuracy.

Using semi-quantification, more accurate assignment of patients in AIT-1, AIT-2 and AIT-3 groups has been achieved, and the differences in MIBI uptake between all groups resulted statistically significant.

Additionally, we have performed a ROC-AUC analysis and obtained the cutoff values for MIBI uptake using TBR. This enabled

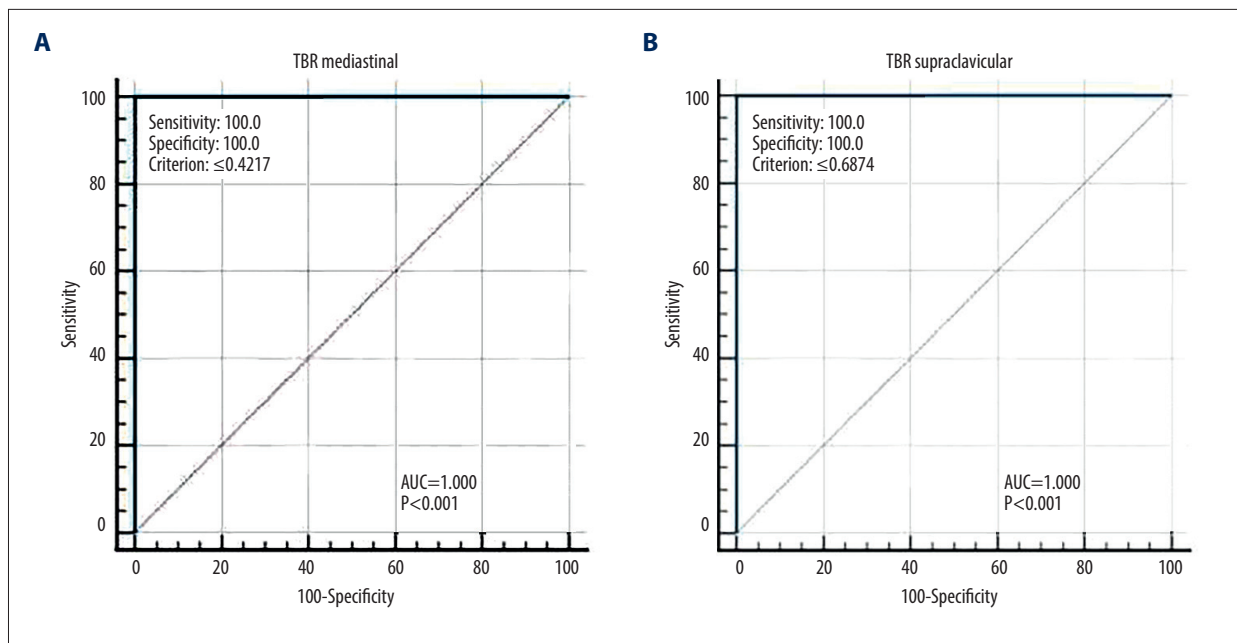


Figure 5. Receiver operating characteristic curve analysis of the target-to-background ratio (TBR) between amiodarone-induced thyrotoxicosis groups 1 and 2. An optimal cutoff value of ≤ 0.422 was determined using the mediastinal background region (TBR mediastinal) (A) and a cutoff value of ≤ 0.687 using the supraclavicular region (TBR supraclavicular) (B). Area under curve (AUC)=1.000 (MedCalc Software, version 20.021, Mariakerke, Belgium).

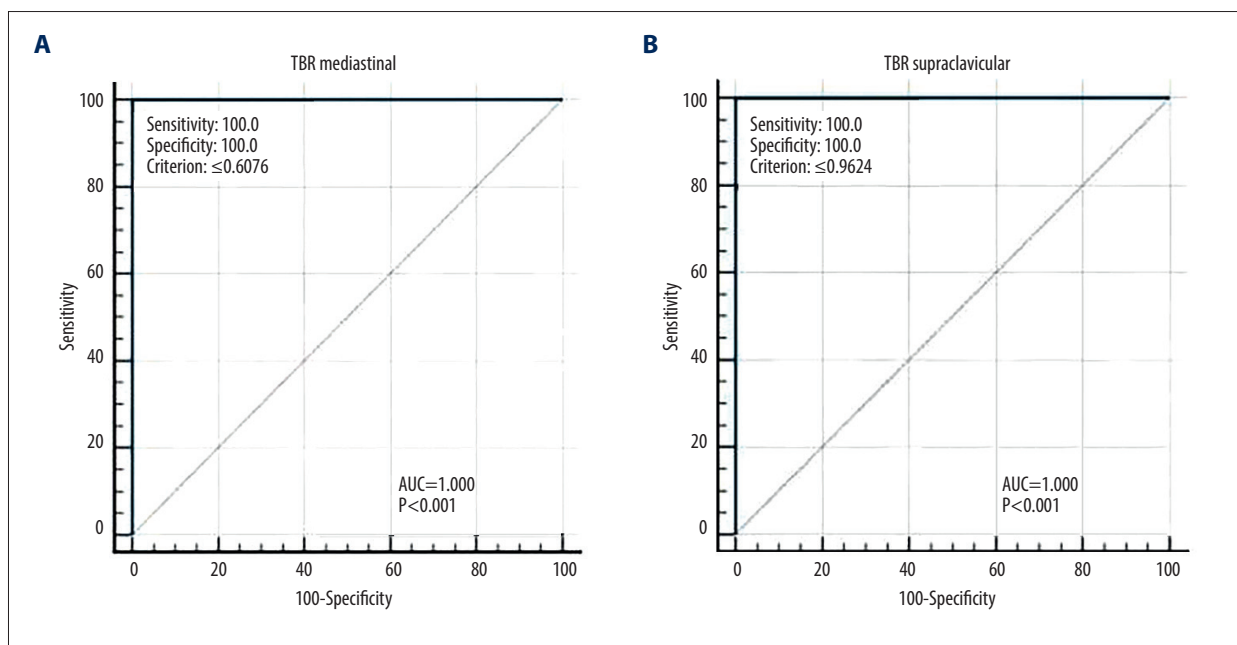


Figure 6. Receiver operating characteristic curve analysis of the target-to-background ratio between amiodarone-induced thyrotoxicosis groups 1 and 3. A cutoff value of ≤ 0.607 was determined using the mediastinal background region (TBR mediastinal) (A) and a cutoff value of ≤ 0.962 using the supraclavicular region (TBR supraclavicular) (B). Area under curve (AUC)=1.000 (MedCalc Software, version 20.021, Mariakerke, Belgium).

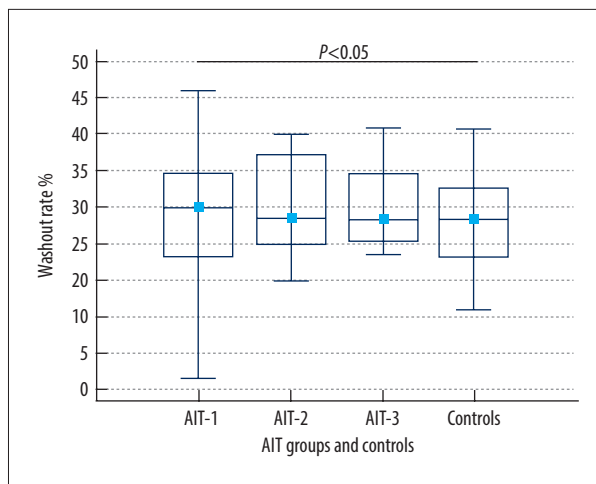


Figure 7. ^{99m}Tc -Methoxy-2-Isobutylisonitrile (MIBI) washout rates (WR) in patients visually categorized in the amiodarone-induced thyrotoxicosis groups (AIT-1, AIT-2, AIT-3) and the control group. There were no significant differences in the WR between patients in groups AIT-1, AIT-2 and AIT-3 and the control group. Results are presented as median, interquartile ranges and absolute ranges ($P>0.05$) (MedCalc Software, version 20.021, Mariakerke, Belgium).

more accurate differentiation between AIT-1 and AIT-2 groups, and AIT-1 and AIT-3 groups. Finally, to investigate whether there is any difference in MIBI washout kinetics between AIT groups, we have analyzed WR, but the results turned not significantly different ($P>0.05$).

According to Piga et al, visual analysis of MIBI thyroid uptake on early images is an effective diagnostic tool for differentiation between AIT type 1 and 2. The authors reported that an increased MIBI uptake in mitochondria-rich thyroid cells corresponds to AIT-1, whereas a lack of MIBI accumulation, a consequence of thyroid cell necrosis and apoptosis, indicates AIT-2 [33]. However, differentiation between AIT types by visual analysis can be difficult due to its subjective nature and the individual experience of the interpreter [34].

In our study, the visual analysis was also straightforward and consistent in the case of AIT-2, as accumulation was absent or minimal, but the evaluation between AIT-1 and the mixed type was more challenging. Only early images were considered in the evaluation as these showed the clearest accumulation patterns. Late images did not contribute significantly to diagnostic accuracy, as the washout rate resembled that of the control group.

Further, the results of visual analysis have been interpreted in the context of clinical, biochemical and imaging data obtained from ^{99m}Tc -pertechnetate scan and ultrasonography with CFDS.

No differences were found between the AIT groups in the clinical presentation of the patients or in the thyroid hormone and thyrotropin levels. There were also no significant differences in TSI, TPOAb, and TgAb levels between AIT types, suggesting that antibody markers cannot be used to differentiate between types of thyrotoxicosis, which is consistent with previous studies [18]. There was no statistically significant difference in the duration of the therapy or the dosage of amiodarone between AIT groups. However, a trend was noted suggesting that AIT-2 cases tend to manifest at a slightly later time point.

Ultrasonography is usually performed in the initial evaluation of AIT. It has been suggested that changes in vascularization, whether increased or decreased, may serve as a valuable indicator for distinguishing between different types of AIT [20]. In our study group, vascularization was not increased in most patients, which is consistent with the characteristics of AIT-2. There were also no significant differences between any of the groups regarding the occurrence of autoimmune and nodular changes in thyroid parenchyma. Although these findings are consistent with results obtained from literature and indicate that ultrasonography is of valuable assistance, it might not always be reliable for accurate differentiation of AIT types [35].

Oki et al compared the results of scintigraphy with ^{99m}Tc -pertechnetate and MIBI in patients on amiodarone therapy, but their study included only 4 hyperthyroid patients [36]. In our study, pertechnetate scintigraphy did not contribute to the diagnostic differentiation of the AIT types, as most patients did not show visible uptake. These results are comparable to those of Wiersinga et al, who reported reduced pertechnetate uptake in patients with suppressed TSH and amiodarone treatment [37].

Previous research has already shown the limited benefit of both RAIU and the IL-6 biomarker. Therefore, these 2 factors were not included in our study [19,21].

Although useful in differentiation of AIT types, the visual analysis of MIBI accumulation is not as successful when MIBI uptake is not clearly positive or negative. Therefore, we proposed the semi-quantitative analysis with the aim to increase diagnostic accuracy. To the best of our knowledge, only 2 authors have proposed a semi-quantitative approach to date, but with different imaging times and background regions [26,27]. Censi et al recorded early and late images, at 15 and 60 minutes, and performed quantification only on early images using the supraclavicular region. Pattison et al used the mediastinal region with a series of static images at 2, 10, 15 and 60 minutes after injection [26]. We performed a semi-quantitative analysis of the MIBI uptake at 10 minutes using both the supraclavicular and the mediastinal region. A statistically significant difference in median uptake values was found between all 3 groups of AIT patients using both BG ROIs. The results suggest that

MIBI scintigraphy with semi-quantitative analysis has the potential to differentiate between different types of AIT.

The MIBI thyroid uptake from all 3 AIT groups was compared with the uptake in euthyroid patients. Limited data is available in literature on this topic [38]. Pattison et al performed a semi-quantitative analysis of MIBI accumulation in 17 subjects with normal thyroid function and used the data as an approximate guide for their interpretation of TBR [27]. Using semi-quantification with TBR, we have obtained a median value of thyroid MIBI uptake in 30 individuals with healthy thyroids.

Comparing the median MIBI uptake values between the control and AIT groups, differences were detected in results obtained from the 2 background regions. For the mediastinal region, the MIBI uptake was significantly lower in the AIT-2 group than in the control group, while for the supraclavicular region, the uptake was significantly higher in the AIT-1 group and lower in the AIT-2 group. Since there was no statistically significant difference between the AIT-3 group and the control group for either BG ROI, it can be concluded that the accumulation of MIBI in mixed AIT group is similar to that in the euthyroid patients.

Furthermore, our results showed a positive and statistically significant correlation between the results of the visual and the semi-quantitative MIBI thyroid uptake analysis using the mediastinal background region. In contrast, visual and semi-quantitative analyses using the supraclavicular region did not show a positive correlation. The different results might be caused by overlapping tissue content and the subjectivity of visual interpretation. Interestingly, there was a positive and significant correlation between results obtained using 2 different background regions, confirming that quantification can improve diagnostic accuracy and help distinguish between different types of AIT.

Using the semi-quantitative method with both BG regions resulted in 3 AIT groups with a similar number of patients as the visual analysis. However, a total of 30 patients were reclassified (16 with the supraclavicular and 14 with the mediastinal region), of which only 5 switched between the AIT-1 and AIT-2 group, with the largest number of reclassified patients coming from the mixed, AIT-3 group.

Censi et al. proposed to improve the differentiation of AIT types using a cutoff value determined by calculating the TBR [26]. Based on the final clinical diagnosis as a reference standard, a ROC-AUC cutoff value was proposed for distinguishing between AIT-2 and mixed types (>0.482) [26].

In our study, we also performed a ROC-AUC analysis to determine the cutoff values for MIBI uptake TBR. For this purpose,

MIBI uptake values were calculated for both the mediastinal and supraclavicular background regions and divided by percentiles. To differentiate between AIT-1 and AIT-2, a cutoff value of ≤ 0.422 was determined when using the mediastinal background region and ≤ 0.687 when using the supraclavicular region.

In addition, we applied the same approach to distinguish between AIT-1 and AIT-3 groups, which could be helpful in identifying patients belonging to the true mixed group. In this case, a cutoff value of ≤ 0.607 was determined using the mediastinal region, whereas a threshold value of ≤ 0.962 was determined using the supraclavicular background region. The proposed cutoff value was not affected by clinical normalization [39].

The MIBI washout rate has been reported as a helpful tool in diagnostic workup of thyroid nodules due to its high negative predictive value [22]. In contrast, according to our results, the washout rate analysis did not significantly contribute to distinguishing between AIT groups, since it was similar to the control group, approximately 30%. Therefore, it can be concluded that late MIBI images did not add value to the differentiation of AIT types.

Our results, together with previous studies on the semi-quantitative analysis of MIBI accumulation, underline the importance of this method. The statistically significant difference in MIBI accumulation between all 3 AIT types and the ROC analysis, which established clear cutoff values, confirmed the contribution of semi-quantitative analysis to visual interpretation, crucial for the selection of appropriate treatment.

Although the results of this study are promising, they come from a small cohort of patients, which is a significant limitation. This underlines the need for further studies with larger samples. In addition, since MIBI is not a thyroid-specific molecule and has the affinity for a number of tissues with high mitochondrial content, it is still not widely accepted in the routine diagnostic workup [13,16].

Also, insufficient MIBI imaging standardization, crucial for clarity and ease of comparison between studies is missing, which may lead to contradictory results. Nevertheless, this study provides valuable data on MIBI uptake in functionally normal thyroid parenchyma and demonstrates the potential of MIBI uptake quantification to differentiate between AIT patient groups.

Conclusions

Although visual MIBI assessment remains essential, its subjective nature and dependence on experience has its limitations. Our study highlights the diagnostic potential of semi-quantitative MIBI analysis in the differentiation of AIT types, especially in

distinguishing AIT-3 (mixed) cases. It also emphasizes the need for multicenter collaboration with larger studies to standardize the method and obtain more accurate and consistent results.

Department and Institution Where Work Was Done

This study was performed at the Clinical Department of Nuclear Medicine, Clinical Hospital Centre Rijeka, Croatia.

References:

1. Blick C, Nguyen M, Jialal I. Thyrotoxicosis. In: StatPearls. Treasure Island (FL): StatPearls Publishing; July 4, 2023
2. Istratoaie S, Sabin O, Vesa ŞC, et al. Efficacy of amiodarone for the prevention of atrial fibrillation recurrence after cardioversion. *Cardiovasc J Afr*. 2021;32(6):327-38
3. Colunga Biancatelli RM, Congedo V, Calvosa L, et al. Adverse reactions of amiodarone. *J Geriatr Cardiol*. 2019;16(7):552-66
4. Srinivasan M, Ahmad L, Bhindi R, Allahwala U. Amiodarone in the aged. *Aust Prescr*. 2019;42(5):158-62
5. Medić F, Bakula M, Alfirević M, et al. Amiodarone and thyroid dysfunction. *Acta Clin Croat*. 2022;61(2):327-41
6. Trohman RG, Sharma PS, McAninch EA, Bianco AC. Amiodarone and thyroid physiology, pathophysiology, diagnosis and management. *Trends Cardiovasc Med*. 2019;29(5):285-95
7. Fischer AJ, Enders D, Eckardt L, et al. Thyroid dysfunction under amiodarone in patients with and without congenital heart disease: results of a nationwide analysis. *J Clin Med*. 2022;11(7):2027
8. Ylli D, Wartofsky L, Burman KD. Evaluation and treatment of amiodarone-induced thyroid disorders. *J Clin Endocrinol Metab*. 2021;106(1):226-36
9. Anfinson OG, Lima K. Amiodarone-induced thyrotoxicosis. *Amiodaronindusert tyreotoksikose*. *Tidsskr Nor Laegeforen*. 2021;141(16): 21.0047
10. Mohammadi K, Shafie D, Vakhshoori M, et al. Prevalence of amiodarone-induced hypothyroidism; A systematic review and meta-analysis. *Trends Cardiovasc Med*. 2023;33(4):252-62
11. Barvalia U, Amlani B, Pathak R. Amiodarone-induced thyrotoxic thyroiditis: A diagnostic and therapeutic challenge. *Case Rep Med*. 2014;2014:231651
12. Macchia PE, Feingold KR. Amiodarone induced thyrotoxicosis. In: Feingold KR, Anawalt B, Blackman MR, et al., eds. *Endotext*. South Dartmouth (MA): MDText.com, Inc.; June 1, 2022
13. Cappellani D, Bartalena L, Bogazzi F. Short review: Novel concepts in the approach to patients with amiodarone-induced thyrotoxicosis. *J Endocrinol Invest*. 2024;47(2):275-83
14. Gencer B, Cappola AR, Rodondi N, Collet TH. Challenges in the management of atrial fibrillation with subclinical hyperthyroidism. *Front Endocrinol (Lausanne)*. 2022;12:795492
15. Lisco G, Accardo G, Pupilli C, et al. Perchlorates in the treatment of hyperthyroidism and thyrotoxicosis: a comprehensive review. *Endocrine*. 2024;85(1):1-10
16. Bartalena L, Bogazzi F, Chiovato L, et al. 2018 European Thyroid Association (ETA) guidelines for the management of amiodarone-associated thyroid dysfunction. *Eur Thyroid J*. 2018;7(2):55-66
17. Cappellani D, Papini P, Di Certo AM, et al. Duration of exposure to thyrotoxicosis increases mortality of compromised AIT patients: The role of early thyroidectomy. *J Clin Endocrinol Metab*. 2020;105(9):dgaa464
18. Tomisti L, Urbani C, Rossi G, et al. The presence of anti-thyroglobulin (TgAb) and/or anti-thyroperoxidase antibodies (TPOAb) does not exclude the diagnosis of type 2 amiodarone-induced thyrotoxicosis. *J Endocrinol Invest*. 2016;39(5):585-91
19. Schubert L, Bricaire L, Groussin L. Amiodarone-induced thyrotoxicosis. *Ann Endocrinol (Paris)*. 2021;82(3-4):163-66
20. Eaton SE, Euinton HA, Newman CM, et al. Clinical experience of amiodarone-induced thyrotoxicosis over a 3-year period: Role of colour-flow Doppler sonography. *Clin Endocrinol (Oxf)*. 2002;56(1):33-38
21. Jhavar N, Chirila R. How do I diagnose and treat my patient's amiodarone-induced thyrotoxicosis? *Cleve Clin J Med*. 2023;90(7):409-12
22. Schenke SA, Campenni A, Tuncel M, et al. Diagnostic performance of ^{99m}Tc-Methoxy-Isobuty-Isonitrite (MIBI) for risk stratification of hypofunctioning thyroid nodules: A European multicenter study. *Diagnostics (Basel)*. 2022;12(6):1358
23. Petranović Oščariček P, Calderoni L, et al. Molecular imaging of thyroid and parathyroid diseases. *Expert Rev Endocrinol Metab*. 2024;19(4):317-33
24. Rizk TH, Nagalli S. Technetium 99m sestamibi. In: StatPearls. Treasure Island (FL): StatPearls Publishing; July 3, 2023
25. Saowapa S, Chamroonrat W, Suvikapakornkul R, Sriphrapradang C. Incidental breast lesion detected by technetium-99m sestamibi scintigraphy in a patient with primary hyperparathyroidism. *World J Nucl Med*. 2019;19(1):69-71
26. Censi S, Bodanza V, Manso J, et al. Amiodarone-induced thyrotoxicosis: Differential diagnosis using ^{99m}Tc-SestaMIBI and Target-to-Background Ratio (TBR). *Clin Nucl Med*. 2018;43(9):655-62
27. Pattison DA, Westcott J, Lichtenstein M, et al. Quantitative assessment of thyroid-to-background ratio improves the interobserver reliability of technetium-99m sestamibi thyroid scintigraphy for investigation of amiodarone-induced thyrotoxicosis. *Nucl Med Commun*. 2015;36(4):356-62
28. Ross DS, Burch HB, Cooper DS, et al. 2016 American Thyroid Association guidelines for diagnosis and management of hyperthyroidism and other causes of thyrotoxicosis [published correction appears in *Thyroid*. 2017;27(11):1462]. *Thyroid*. 2016;26(10):1343-421
29. Simundic AM, Bölenius K, Cadamuro J, et al. Joint EFLM-COLABIOCLI Recommendation for venous blood sampling. *Clin Chem Lab Med*. 2018;56(12):2015-38
30. Konca C, Elhan AH. Unveiling the accuracy of ultrasonographic assessment of thyroid volume: A comparative analysis of ultrasonographic measurements and specimen volumes. *J Clin Med*. 2023;12(20):6619
31. Chaudhary P, Pamnani J, Rana K, Khandekar AK. Exploring the association between thyroid density assessed by non-contrast computed tomography and serum thyroid-stimulating hormone (TSH) levels in hypothyroid patients. *Cureus*. 2023;15(11):e48653
32. Nakajima K, Miyauchi H, Hirano KI, et al. Practice recommendation for measuring washout rates in ¹²³I-BMIPP fatty acid images [published correction appears in *Ann Nucl Med*. 2024;38(1):9]. *Ann Nucl Med*. 2024;38(1):1-8
33. Piga M, Cocco MC, Serra A, et al. The usefulness of ^{99m}Tc-sestaMIBI thyroid scan in the differential diagnosis and management of amiodarone-induced thyrotoxicosis. *Eur J Endocrinol*. 2008;159(4):423-29
34. Elshimy G, Alsayed M, Targovnik J, et al. The use of ^{99m}Tc-methoxy-isobutyl-isonitrite (sestaMIBI) uptake on scintigraphy (^{99m}Tc-STS) in amiodarone-induced thyrotoxicosis: Case series and review of the literature. *Case Rep Endocrinol*. 2020;2020:2493460
35. Wong R, Cheung W, Stockigt JR, Topliss DJ. Heterogeneity of amiodarone-induced thyrotoxicosis: evaluation of colour-flow Doppler sonography in predicting therapeutic response. *Intern Med J*. 2003;33(9-10):420-26
36. Oki GC, Zantut-Wittmann DE, de Oliveira Santos A, et al. Tc-99m sestamibi thyroid imaging in patients on chronic amiodarone treatment: A comparison with Tc-99m pertechnetate imaging. *Clin Nucl Med*. 2010;35(4):223-27
37. Wiersinga WM, Touber JL, Trip MD, van Royen EA. Uninhibited thyroidal uptake of radioiodine despite iodine excess in amiodarone-induced hypothyroidism. *J Clin Endocrinol Metab*. 1986;63(2):485-91
38. Santos AO, Zantut-Wittmann DE, Nogueira RO, et al. ^{99m}Tc-sestaMIBI thyroid uptake in euthyroid individuals and in patients with autoimmune thyroid disease. *Eur J Nucl Med Mol Imaging*. 2005;32(6):702-7
39. Hershman JM. Quantitative uptake of sestamibi differentiates type 1 from type 2 amiodarone-induced thyrotoxicosis. *Clinical Thyroidology*. 2018;30(9):415-17

Declaration of Figures Authenticity

All figures submitted have been created by the authors who confirm that the images are original with no duplication and have not been previously published in whole or in part