

The “Cello Technique”: A New Technique for Ultrasound-Assisted Calcaneoplasty

Rakovac, Ivan; Mađarevic, Tomislav; Tudor, Anton; Prpić, Tomislav;
Šestan, Branko; Mihelic, Radovan; Šantic, Veljko; Jurkovic, Hrvoj; Ružić,
Lana

Source / Izvornik: **Arthroscopy Techniques**, 2012, 1, e91 - e94

Journal article, Published version

Rad u časopisu, Objavljena verzija rada (izdavačev PDF)

<https://doi.org/10.1016/j.eats.2012.04.001>

Permanent link / Trajna poveznica: <https://urn.nsk.hr/urn:nbn:hr:184:212858>

Rights / Prava: [In copyright](#) / [Zaštićeno autorskim pravom](#).

Download date / Datum preuzimanja: **2024-12-23**



Repository / Repozitorij:

[Repository of the University of Rijeka, Faculty of
Medicine - FMRI Repository](#)



The “Cello Technique”: A New Technique for Ultrasound-Assisted Calcaneoplasty

Ivan Rakovac, M.D., Ph.D., Tomislav Madarevic, M.D., Anton Tudor, M.D., Ph.D.,
Tomislav Prpic, M.D., Ph.D., Branko Sestan, M.D., Ph.D.,
Radovan Mihelic, M.D., Ph.D., Veljko Santic, M.D., Ph.D., Hrvoj Jurkovic, M.D., and
Lana Ruzic, M.D., Ph.D.

Abstract: The “cello technique” is a new calcaneoplasty technique for the treatment of Haglund disease. It is an ultrasound-assisted technique for resection of the posterosuperior part of the calcaneus. It is possible to resect the posterosuperior part of the calcaneus under direct ultrasound control with the patient in the prone position, with a dorsally positioned ultrasound probe, in line with the Achilles tendon fibers (sagittal line), and with the abradar in the posteromedial working portal. We describe in detail the technique for this new procedure in foot and ankle surgery. This innovative technique offers the possibility of expanding the indications for ultrasound-guided surgery in other fields of orthopaedic surgery.

In 1928 Haglund¹ described retrocalcaneal pain caused by a calcaneal prominence, an enlarged posterosuperior border of the “os calcis.” The first described operative treatment option was open resection of the posterosuperior part of the calcaneus and inflamed retrocalcaneal bursa. In 2001 van Dijk et al.² described endoscopic resection of the calcaneal prominence; they named the procedure “endoscopic calcaneoplasty,” and many surgeons followed this technique. We started performing endoscopic calcaneoplasty in 2009. Despite very good results comparable to those reported in the literature, 15% of our patients had residual calcaneal prominence and

residual pain after the functional rehabilitation program and required subsequent reoperation. Because of that, we started to control our resection intraoperatively with radiography and ultrasound (US). After a learning-curve period, we excluded perioperative radiographic control and then endoscopic surveillance, and soon only US-assisted resection was performed. The purpose of this report is to present our new technique for US-assisted calcaneoplasty named the “cello technique” (Fig 1).

TECHNIQUE

During endoscopic US-controlled calcaneoplasty, the patient is placed in a prone position as in the posterior ankle arthroscopy techniques described by van Dijk et al.³ The operation begins with the positioning of the skin incision. With the 1.2 mm muscular needle and under US control (GE Logiq500 Pro; GE Healthcare, Wauwatosa, WI), we search for the correct position for the skin incision for a single posteromedial portal (Fig 2A).

The entrance for the approach should be positioned as close to the distal Achilles tendon insertion as possible (Fig 2B, Video 1). Because of the narrow

From the University Hospital for Orthopaedic Surgery Lovran (I.R., T.M., A.T., T.P., B.S., R.M., V.S.), Lovran, Croatia; General Hospital Vukovar (H.J.), Vukovar, Croatia; and School of Kinesiology, University of Zagreb (L.R.), Zagreb, Croatia.

The authors report that they have no conflicts of interest in the authorship and publication of this article.

Received January 11, 2012; accepted April 19, 2012.

Address correspondence to Tomislav Madarevic, M.D., University Hospital for Orthopaedic Surgery Lovran, Marsala Tita 1, 51415 Lovran, Croatia. E-mail: tomislav.madjarevic@gmail.com

© 2012 by the Arthroscopy Association of North America

2212-6287/1218/\$36.00

http://dx.doi.org/10.1016/j.eats.2012.04.001



FIGURE 1. Cello technique schematic description. We named the US-guided calcaneoplasty the “cello technique” based on the visual association: the US probe as the cello and the abrader as the bow.

space that sometimes makes entry difficult, any position below the level of the posterosuperior tip of the calcaneus should suffice. The skin incision is followed by blunt dissection and insertion of an abrader (4.5-mm blade; Smith & Nephew, Andover, MA) over the top of the calcaneal prominence.

The abrasion of the posterosuperior part of the calcaneus begins under direct US control. Determining the orientation of the blunt and sharp portions of the abrader by looking at the abrader handle is of extreme importance, although the blade can be distinguished by US.

The US probe is always parallel to the Achilles tendon in the sagittal plane and perpendicular to the frontal plane of the calcaneus (Figs 1 and 2A). The most demanding step of the operation is the simultaneous movement of the US probe and the abrader tip to always keep the resection visible in the US field. During calcaneal resection, the bone dust produces US re-echo, creating the need for rinsing by use of a syringe. Rinsing is important to achieve better visualization and to prevent heterotopic ossification.

Intraoperative resection is controlled in 2 ways: according to preoperative planning in millimeters and our preferred method, with the positioning of the foot

in maximal dorsal extension (Fig 3). If there is no impingement between the tendon and calcaneus, then the resection is sufficient. The resection must be continued to the Achilles tendon insertion, which is the point where the convexity of the posterosuperior part of the calcaneus ends and tendon insertion fibers begin (Figs 2B and 3).

After resection, the endoscope should be introduced to visually check the extent of the bump resection and the preservation of the Achilles tendon fibers. While learning the US-guided technique, we suggest radiographic visualization for further control of the resection. No drainage is needed. The skin is closed with a single suture, and a compressive dressing is applied. Rehabilitation is begun on the first postoperative day,

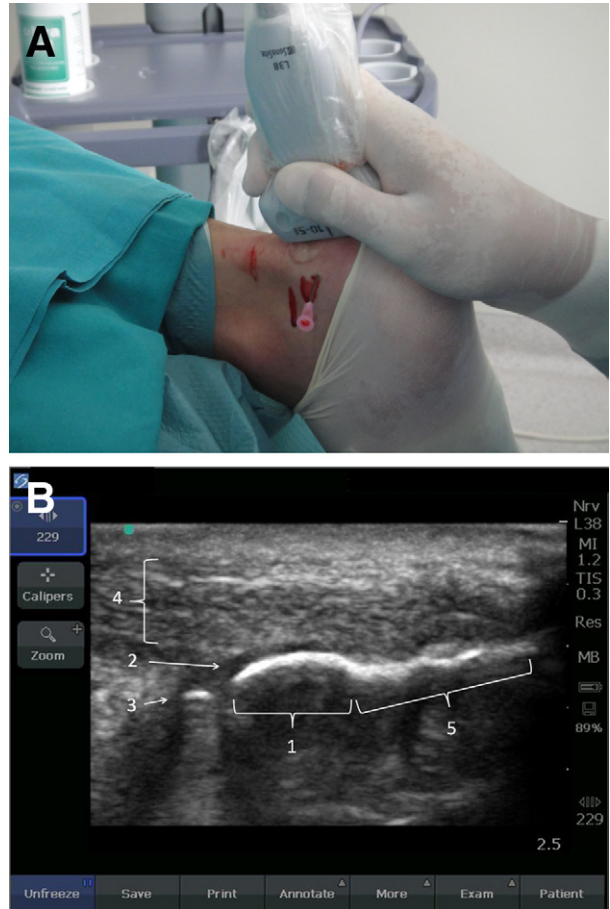


FIGURE 2. (A) Beginning of cello technique. Positioning of the US probe and the posteromedial portal with the patient in the prone position (right calcaneus). (B) US visualization at the beginning of US-assisted calcaneoplasty: Haglund deformity (1), retrocalcaneal bursitis (2), needle (3), Achilles tendon (4), and Achilles tendon insertion (5).

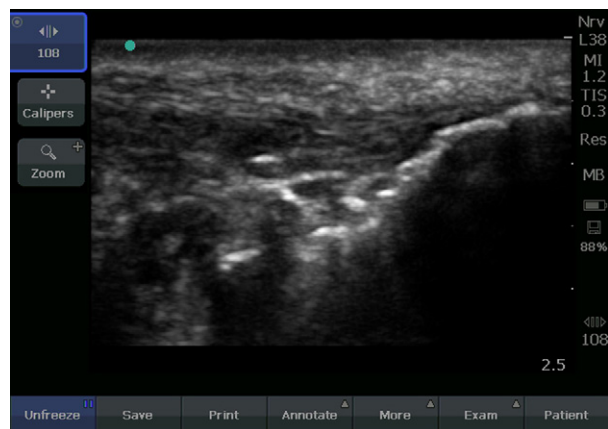

FIGURE 3. US visualization at the end of US-assisted calcaneoplasty. The posterosuperior part of the calcaneus is resected: with the ankle in dorsal extension, there is no impingement between bone and the Achilles tendon.

and full weight bearing is allowed. Analgesia is administered as needed.

DISCUSSION

The treatment of Haglund disease is mainly conservative, and it includes shoe modification, activity modification, nonsteroidal anti-inflammatory medication, padding, physical therapy, and infiltration into the retrocalcaneal bursa with corticosteroids. When nonoperative treatment fails, calcaneoplasty is indicated. Surgical treatment comprises open or endoscopic resection of the posterosuperior part of the calcaneus. After open surgery, partial resection and poor results have been reported.⁴ Endoscopic resection is currently the state-of-the-art treatment, but in our hands a rate of residual deformity of 15% was

observed. Cadaveric studies using either an open or endoscopic technique have found similar possibilities for damaging the medial part of the Achilles tendon, the tendon of the plantar muscle, and most importantly, the sural nerve.⁵ We started to monitor our endoscopic resection intraoperatively with US and radiography. Soon, it was clear that US guidance alone was sufficient for a precise and controlled resection, and we excluded the intraoperative radiographic control and endoscopic visualization. We started with US-guided os calcis resection as described, and we named it the “cello technique” based on a visual association: the US probe as the cello and the abrader as the bow (Fig 1).

There are many potential benefits to US-guided resection of the posterosuperior part of the calcaneus. By using US, the visualization is obtained noninvasively and no skin incisions apart from a medial working portal are needed, which leads to a good esthetic result. With only a medial working portal, the sural nerve is not in danger during surgery. Because US is penetrating the soft tissues, no soft tissue is removed for bone visualization, respecting the principles of minimally invasive surgery. During the surgery, in the same US visual field, we have the Achilles tendon, the retrocalcaneal recess, and the bone, allowing the surgeon to achieve precise bone removal—just the right amount to prevent the Achilles tendon from impinging the bone and retrocalcaneal bursa in any part of the foot and ankle movement. When the surgeon is familiar with US visualization, the resection can be performed quickly and safely (Table 1). Because the visualization is indirect, there is also no need for the use of tourniquet. In addition, an advantage of this technique is the elimination of radiation, with respect

TABLE 1. *Tips and Pearls, Pitfalls, and Key Points for US-Assisted Calcaneoplasty*

Tips and Pearls	Pitfalls	Key Points
Preoperatively position the foot that will be operated on above the other foot to enable easier manipulation with the instruments.	Insufficient resection, especially at the most dorsomedial part of the prominence, is possible if there is an unsatisfactory foot position.	Control of impingement between the calcaneus and Achilles tendon in maximal dorsal flexion should be achieved.
Always control the position of the sharp part of the abrader.	Possible damage to the Achilles tendon, especially the medial part, is possible.	Look out for the position of the abrader (look at the handle before you start abrading).
Palpate the insertion of the Achilles tendon with an instrument.	Insufficient resection is possible.	Control the residual deformity with US and palpation.
Connect the suction pole of the abrader to the water system.	Insufficient bone dust removal and heterotopic ossification are possible.	Better visualization and cooling of the abrader are important; multiple rinsings during surgery result in better visualization.

to unnecessary radiographic control during the diagnostics and in the postoperative protocol.

The risk of the US-controlled technique is damage to the Achilles tendon, especially damage to the medial Achilles tendon column. With careful US and abradar manipulation, this problem can be minimized. Insufficient bone dust washout can potentially lead to heterotopic ossification. Multiple rinsings using the syringe through the posteromedial portal remove the bone dust and enhance visualization. An additional lavage method is the insertion of the needle syringe laterally with the suction through the abradar medially, but with this, there is a moderate risk of sural nerve damage.

In selecting patients for the cello technique, it is important to differentiate symptoms related to the enlarged posterosuperior part of the calcaneus and retrocalcaneal bursitis from insertional or noninsertional Achilles tendinitis because these conditions cannot be treated with the presented technique. Alfredson⁶ described US- and Doppler-guided mini-surgery for midportion Achilles tendinosis.

In this article we present technical tips for US-controlled os calcis resection. A prospective study has been started in our hospital to compare open, endoscopic, and US-guided resection, and the results will be reported. The expected advantages of the cello

technique are minimal soft-tissue damage, precise resection, faster rehabilitation, and obviously, because there is only 1 skin incision, better esthetic results.

In summary, any technique used in calcaneoplasty has to satisfy the condition of sufficient bone removal to prevent impingement in the retrocalcaneal space. US-controlled resection offers the possibility of precise resection and real-time surveillance of the resection. The cello technique has all the potential advantages of minimally invasive surgery and opens the field of US-guided surgery to other orthopaedic conditions.

REFERENCES

1. Haglund P. Beitrag zur Klinik der Achillessehne. *Z Orthop Chir* 1928;49:49-58.
2. van Dijk CN, van Dyk GE, Scholten PE, Kort NP. Endoscopic calcaneoplasty. *Am J Sports Med* 2001;29:185-189.
3. van Dijk CN, de Leeuw PA, Scholten PE. Hindfoot endoscopy for posterior ankle impingement. Surgical technique. *J Bone Joint Surg Am* 2009;91:287-298 (Suppl 2).
4. Wiegerinck JI, Kok AC, van Dijk CN. Surgical treatment of chronic retrocalcaneal bursitis. *Arthroscopy* 2012;28:283-293.
5. Lohrer H. Comparison of endoscopic and open resection for Haglund tuberosity in a cadaver study. *Foot Ankle Int* 2006;27:445-450.
6. Alfredson H. Ultrasound and Doppler-guided mini-surgery to treat midportion Achilles tendinosis: Results of a large material and a randomised study comparing two scraping techniques. *Br J Sports Med* 2011;45:407-410.