

The use of the "Airtraq Laryngoscope" for securing proper positioning of an endotracheal tube during bedside percutaneous dilatational tracheostomy

Šustić, Alan; Protić, Alen; Juranić, Jurica

Source / Izvornik: **Signa vitae : journal for intensive care and emergency medicine, 2011, 6, 61 - 62**

Journal article, Published version

Rad u časopisu, Objavljena verzija rada (izdavačev PDF)

Permanent link / Trajna poveznica: <https://um.nsk.hr/um:nbn:hr:184:573995>

Download date / Datum preuzimanja: **2025-02-05**



Repository / Repozitorij:

[Repository of the University of Rijeka, Faculty of Medicine - FMRI Repository](#)



The use of the 'Airtraq Laryngoscope' for securing proper positioning of an endotracheal tube during bedside percutaneous dilatational tracheostomy

ALAN ŠUSTIĆ • ALEN PROTIĆ • JURICA JURANIĆ

ALAN ŠUSTIĆ (✉) •

ALEN PROTIĆ •

JURICA JURANIĆ

Department of Anesthesiology and ICU

University Hospital Rijeka

Krešimirova 42, 51000 Rijeka

Croatia

Phone: + 385 51 407400

Fax: + 385 51 218407

E-mail: alan.sustic@medri.hr

Percutaneous dilatational tracheostomy (PDT) is a widely used and accepted method for long-term ventilation of critically ill patients in many intensive care units (ICUs). However, serious complications related to PDT have been reported, including several cases of intraoperative loss of airway with fatal consequences. (1) Generally, this is the result of the required delicate position of the endotracheal tube (ETT) during PDT, with a partially deflated cuff located at the level of the vocal cords. This position of the ETT may lead to accidental extubation and loss of airway during the procedure, especially in difficult patients with a short, bull neck. On the other hand, too deep a position of the tip of the ETT can lead to accidental puncture of Murphy's eye, with impalement of the ETT. (2) Unfortunately, the operator performing the PDT evaluates the correct position of the tip of the ETT on the basis of questionable, indicative, indirect parameters and clinical signs such as: capnography, the curve on the ventilator monitor and respiratory movements of the thoracic wall.

Recently, the new, disposable intubating device, Airtraq (Prodol Meditec S.A., Vizcaya, Spain) optical laryngoscope (AL), has been used successfully in difficult airway patients. (3) The AL is

a device with internal arrangement of the optical component and exaggerated curvature of the blade that allows excellent viewing of the vocal cords and epiglottis without alignment of the oral, pharyngeal and tracheal axes. Also, the AL has a channel that is used to direct the ETT through the vocal cords, directly or using wireless monitoring, once visualization has been achieved. The wireless monitor allows real-time visualization of all intubating procedures for more than one person.

The purpose of our short investigation was to evaluate the usefulness of the AL with wireless monitoring for initial positioning and maintaining an optimal position of the ETT during PDT. We hypothesized that initial positioning of the ETT with the AL should be at least as swift and precise as by classic laryngoscopy, probably with less expressed hemodynamic changes that follow laryngoscopy. We further assumed that continuous monitoring of the ETT position by the AL, with a wireless monitor, would enable optimal airway management during the whole procedure of PDT.

After hospital ethical board approval, 30 critically ill adult patients who required a PDT were enrolled (without any exclusion criteria) in the prospective study. All PDT were performed by experienced

operators using the guide-wire dilating forceps technique (Portex Ltd, UK)

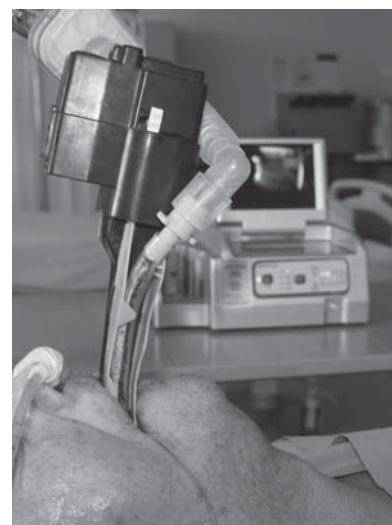


Figure 1. Airtraq optical laryngoscope "in situ" immediately before tracheostomy.

. Bronchoscopy guidance was not used, but in several difficult cases PDT was guided by ultrasonography as previously described. (4) The endotracheal tube was positioned using the AL in the following manner. An appropriately sized (regular for ETT 7.0-8.5 mm; small for ETT 6.0-7.5 mm) and well lubricated AL was inserted into the oral cavity on

the left side of the ETT and the ETT was gently pushed into the guiding canal of the AL. Then, the AL was slowly drawn over the ETT with its top positioned in the vallecula. The view of the ETT, located between the vocal cords, is optimized by slightly lifting the blade in the vallecula. Then the cuff of the ETT was deflated and the ETT was withdrawn until the cuff was visible partly between and partly below the vocal cords. In this position, the cuff was re-inflated under eye

control. After securing a correct ETT position, the AL was delicately fixed with fixing tape and left "in situ" during PDT (figure 1). Thus, the operator has the possibility to control visually on the screen the exact position of the ETT during the whole procedure. The initial positioning of the ETT was done without any problems in all cases. At all times, including during the initial positioning of the ETT, hemodynamic and respiratory parameters were stable, including peripheral arterial O₂ satu-

ration as well as end-tidal CO₂. Not in one PDT were signs of hemodynamic or respiratory instability observed, nor oxygen desaturation of arterial blood, hypercarby or loss of passable airway. In all performed PDTs the operator had perfect vision of the exact position of the ETT during the whole procedure. In conclusion, the AL with wireless monitoring is very suitable for airway management during PDT and this device offers important additional security for the operator.

REFERENCES

1. Kost KM. Endoscopic percutaneous dilatational tracheostomy: a prospective evaluation of 500 consecutive cases. *Laryngoscope* 2005;115:1-30.
2. Mphanza T, Jacobs S, Chavez M. A potential complication associated with percutaneous tracheostomy with an endotracheal tube with Murphy eye in situ. *Anesthesiology* 1998;88:1418.
3. Maharaj CH, Buckley E, Harte BH, Laffey JG. Endotracheal intubation in patients with cervical spine immobilization. A comparison of Macintosh and Airtraq laryngoscopes. *Anesthesiology* 2007;107:53-9.
4. Šustić A. Role of ultrasound in the airway management of critically ill patients. *Crit Care Med* 2007;35:S173-7.