

# Minimalno invazivni anterolateralni pristup s pacijentom na leđima tijekom aloartroplastike kuka

---

Gulan, Gordan; Jurdana, Hari; Mikačević, Marijan; Zec, Andrej; Mokrović, Hrvoje; Jotanović, Zdravko; Prpić, Tomislav; Šestan, Branko; Legović, Dalen; Šantić, Veljko

Source / Izvornik: **Medicina Fluminensis : Medicina Fluminensis, 2015, 51, 41 - 51**

Journal article, Published version

Rad u časopisu, Objavljena verzija rada (izdavačev PDF)

Permanent link / Trajna poveznica: <https://um.nsk.hr/um:nbn:hr:184:232951>

Rights / Prava: [In copyright](#)/[Zaštićeno autorskim pravom.](#)

Download date / Datum preuzimanja: **2024-08-25**



Repository / Repozitorij:

[Repository of the University of Rijeka, Faculty of Medicine - FMRI Repository](#)





# Anterolateral minimally invasive approach in hip arthroplasty with the patient in the supine position – a surgical technique

## Minimalno invazivni anterolateralni pristup s pacijentom na leđima tijekom aloartroplastike kuka

Gordan Gulan\*, Hari Jurdana, Marijan Mikačević, Andrej Zec, Hrvoje Mokrović, Zdravko Jotanović, Tomislav Prpić, Branko Šestan, Dalen Legović, Veljko Šantić

**Abstract.** In the past 60 years, primary THA has been one of the most successful and most performed orthopaedic procedure. Over the years, hip arthroplasty has changed, and research continues to improve its results. Better materials and design provide patients with an increased range of motion with enhanced stability and very low wear. In recent years, there have been a number of reports describing the performance of THA through smaller incisions using minimally invasive surgical techniques, aimed to spare the soft tissue, especially the abductor musculature. These techniques allow less post-operative pain, reduced blood loss, shorter hospitalization, better functional recovery and faster return to everyday routine. However, tissue sparing techniques can result in numerous complications related to the learning curve. Today four minimally invasive approaches have been described and many of their modifications. All of them are technically demanding, and may require specialized instruments and equipments. This article describes in detail the surgical technique of a minimally invasive anterolateral hip approach with patients in the supine position, including the preoperative setting, with pearls and tips based on the authors' experience.

**Key words:** arthroplasty; hip; minimally invasive surgery; technique

**Sažetak.** Zadnjih 60-ak godina primarna zamjena zgloba kuka predstavlja jednu od najučinkovitijih i najizvođenijih operacija u ortopediji. Tijekom godina navedeni zahvat doživio je značajne promjene s ciljem unaprijeđenja kvalitete života pacijenata. Upotreba boljih materijala i promjena dizajna implantata omogućili su bolju stabilnost, veću pokretljivost i veću trajnost proteze kuka. Kako bi se smanjila kirurška trauma, očuvala abduktorna miškulatura te ubrzao oporavak bolesnika počelo se s korištenjem minimalno invazivnih tehnika. Pri uporabi takvih tehnika smanjen je gubitak krvi, smanjena poslijeoperacijska bol, skraćen je boravak u bolnici i postignut bolji funkcionalni oporavak i povratak svakodnevnim aktivnostima. Krivulja učenja je nešto dulja pri savladavanju takvih tehnika, koje sa sobom nose i neke komplikacije. Do danas su opisane četiri osnovne tehnike minimalno invazivne kirurgije, te njihove brojne modifikacije. Za većinu ovih tehnika potrebni su posebni instrumenti konstruirani za tu namjenu. U ovom radu detaljno je opisana tehnika minimalno invazivnog antero-lateralnog pristupa s pacijentom na leđima pri ugradnji totalne proteze kuka uključujući i prijeoperacijsko namještanje pacijenta te ostale tehničke detalje.

**Cljučne riječi:** aloartroplastika; kuk; minimalno invazivna kirurgija; tehnika

Clinic for Orthopaedic Surgery Lovran,  
Faculty of Medicine University of Rijeka,  
Rijeka, Croatia

Received: 1.08.2014  
Accepted: 28.12.2014

**\*Corresponding author:**

Prof. Gordan Gulan, MD, PhD  
Clinic for Orthopaedic Surgery Lovran,  
Faculty of Medicine University of Rijeka  
Šetalište Maršala Tita 1, 51 415 Lovran,  
Croatia  
e-mail: gordan.gulan@gmail.com

<http://hrcak.srce.hr/medicina>

## INTRODUCTION

Surgical approach utilized in total hip arthroplasty (THA) has been identified as an important factor that may influence THA stability and post-surgical abductor functioning<sup>1,2</sup>. Many approaches have been described since Sir John Charnly started the modern era of hip arthroplasty. They can be grouped according to the patient's position on the operating table (lateral decubitus, supine), the direction through which the hip is ap-

It is not necessary to perform the operation via the smallest possible skin incision, but rather to perform it with minimal soft-tissue trauma, while sparing all muscle attachments.

proached (medial, anterior, anterolateral, lateral, posterior), or according to the muscles involved (intermuscular or transmuscular).

In the last few years, the minimally invasive approaches for hip arthroplasty have gained great popularity. All of them represent modified versions of the classic approach to the hip, allowing a smaller skin incision and better cosmetic. At the beginning of the era of application of the minimally invasive hip surgery, many authors argued about the definition of small incision. On average, most of them agreed that 10 cm is the upper threshold for using the term 'mini incision'.

Today, in order for an intervention to be defined as truly 'minimally invasive', it is not necessary to perform the operation via the smallest possible skin incision, but rather to perform it with minimal soft-tissue trauma, while sparing all muscle attachments. An ideal soft tissue sparing approach should provide a small incision with adequate intraoperative view, without muscle damage or detachment during bone preparation and component implantation. With this aim, four MIS approaches have been developed: anterior<sup>3,4</sup>, anterolateral<sup>5</sup>, posterior<sup>6</sup>, and two incision approaches<sup>7</sup>. According to Laffose et al., only anterolateral (intermuscular) and direct anterior approach (intermuscular and internervous) are in line with this concept because other approaches include sectioning of short external rotators, and

Mardones et al. showed that in the MIS two-incision approach<sup>8</sup>, lesion of the GM with or without short external rotators may occur<sup>9</sup>.

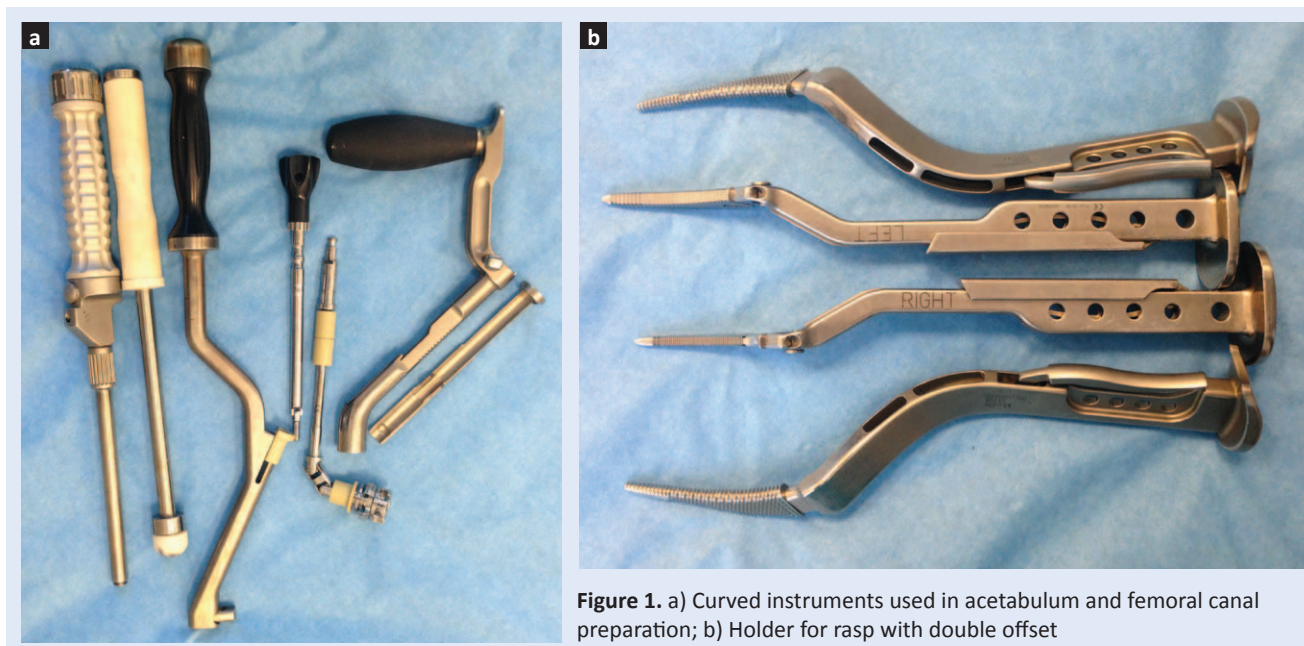
In the last few years, the anterolateral MIS approach has become increasingly popular among hip surgeons. It is also known as the modified Watson-Jones approach, because it is a modification of the standard approach described in 1936 by Sir Reginald Watson Jones<sup>10</sup>. This approach follows the intermuscular plane between the tensor fascia lata muscle (TFL) and the gluteus medius muscle (GM), and was first described by Sayre in 1894.

Bertini first described the modification of this approach with the aim to preserve muscle insertions, and Rottinger<sup>5</sup> was among the first to notice the importance of the abductor musculature around the hip. The approach was then modified by Graf, Roth, Pfeil, Jeroch<sup>11-14</sup>.

The AL-MIS approach gained popularity in some centers due to its relative sparing of the abductors, the posterior capsule and external rotators, which may permit early recovery and reduced risk of dislocation, and, not least, requires no special table during intervention, which is the case in direct anterior MIS approach.

Given the reduced space for manipulation due to the small operative field, special instruments have been developed by various companies. While the acetabulum can be prepared and the acetabular cup implanted with standard instruments, specialized rasps with double offset shafts are helpful in preparing the femur. These instruments enable the surgeon to gain access to the canal without damaging GM and without impinging the skin.

Despite improved instrumentation, however, the implementation of these technique is associated with the risk of higher of complication rates, starting from prolonged duration of the procedure, damages to the muscle and tendons during dissection or during tendency to enhance visibility, damages to the superior rim of the acetabulum by over-reaming with a curved reamer, fracture of the great trochanter, malposition of the acetabular cup, malposition of the femoral stem, perforation of the femur and periprosthetic fracture, some of which can be catastrophic<sup>15-17</sup>. Many studies agree that the learning curve for MIS is longer than for other procedures and can sometimes be difficult, depending on the sur-



**Figure 1.** a) Curved instruments used in acetabulum and femoral canal preparation; b) Holder for rasp with double offset

geon's experience in hip arthroplasty, and the approach and instrumentation used before starting with MIS<sup>18</sup>.

Although the original AL-MIS approach was described in lateral decubitus, we found that the AL-MIS approach could be more suitable for intraoperative measuring of the leg length and when intraoperative fluoroscopy or intubation during anesthesia is needed.


Here we describe in detail the surgical technique of the anterolateral minimally invasive hip approach with patients in the supine position, including the preoperative settings with tips and technical notes based on the authors' knowledge and experience.

#### CONTRAINDICATION

According to our experience, we do not perform the MIS-AL in patients with contraindication which include: patients with BMI > 30, hip dysplasia Crow type IV, patients with previous hip surgery, revision arthroplasty, especially femoral revision, hip tumors or metastatic bone disease.

#### ANESTHESIA

Anesthesia is given in agreement with the anesthesiologist. General or spinal anesthesia may be used, provided it allows muscle relaxation, which is prerequisite for performing MIS hip arthroplasty.



**Figure 2.** Set of instruments for AL-MIS approach

#### INSTRUMENTS AND IMPLANTS

Almost all types of hip prosthesis can be used with AL-MIS in the supine position. We prefer using the curved stem because it allows better soft

tissue sparing, preserving the trochanter bony mass during bone preparation, and easier implantation of the femoral stem. (Figure 1).

For anterolateral minimally invasive hip arthroplasty, we routinely use uncemented implants developed by Zimmer and DePuy Johnson and Johnson, with a set of instruments specially developed for the MIS-AL approach. (Figure 2).

#### PATIENT POSITIONING

The standard operating table with two independent leg supports, either of which can be bent, is used. The patient is positioned with the side which is to be operated on the edge of the table. It is important to note that the great trochanter should be positioned on the table where it will be bent (Figure 3). Optionally, the cushion may be used just below the base of the trochanter leaving the tip of the trochanter free from the cushion.

Optionally, the surgical table can be rotated in the opposite direction of the surgeon by 20-30 degrees. When this position is used, the holder should be placed on the opposite side.

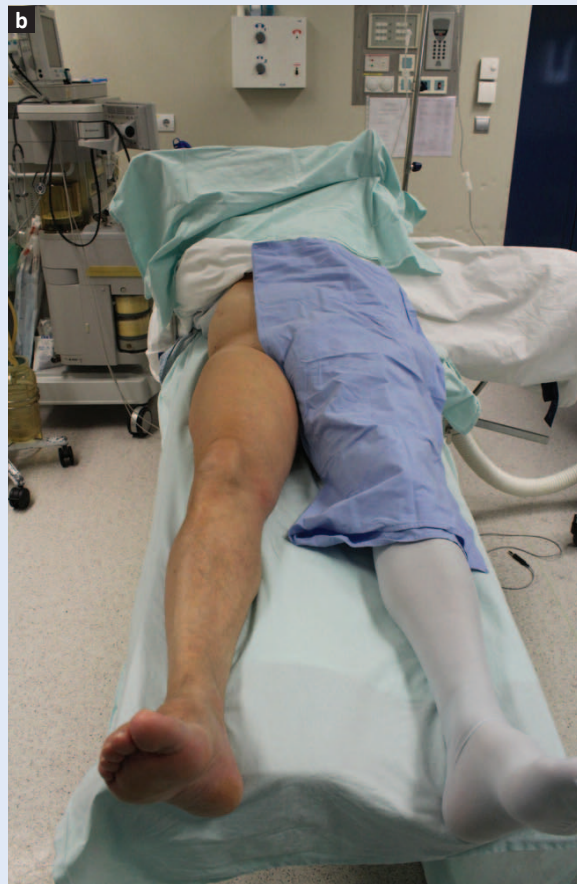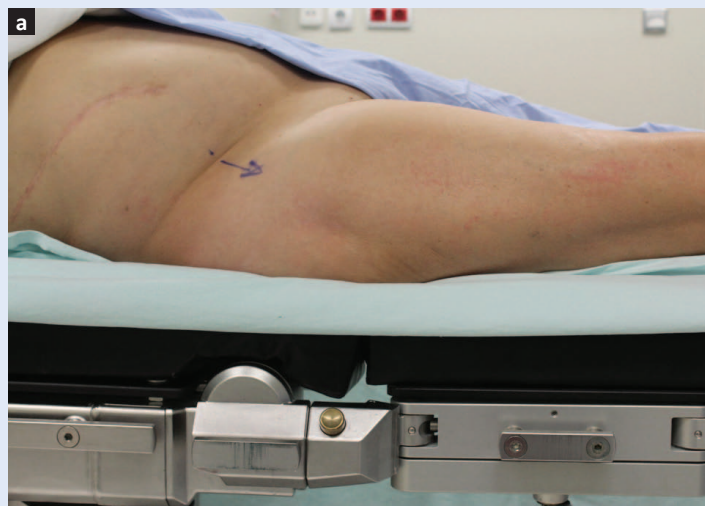#### DRAPING

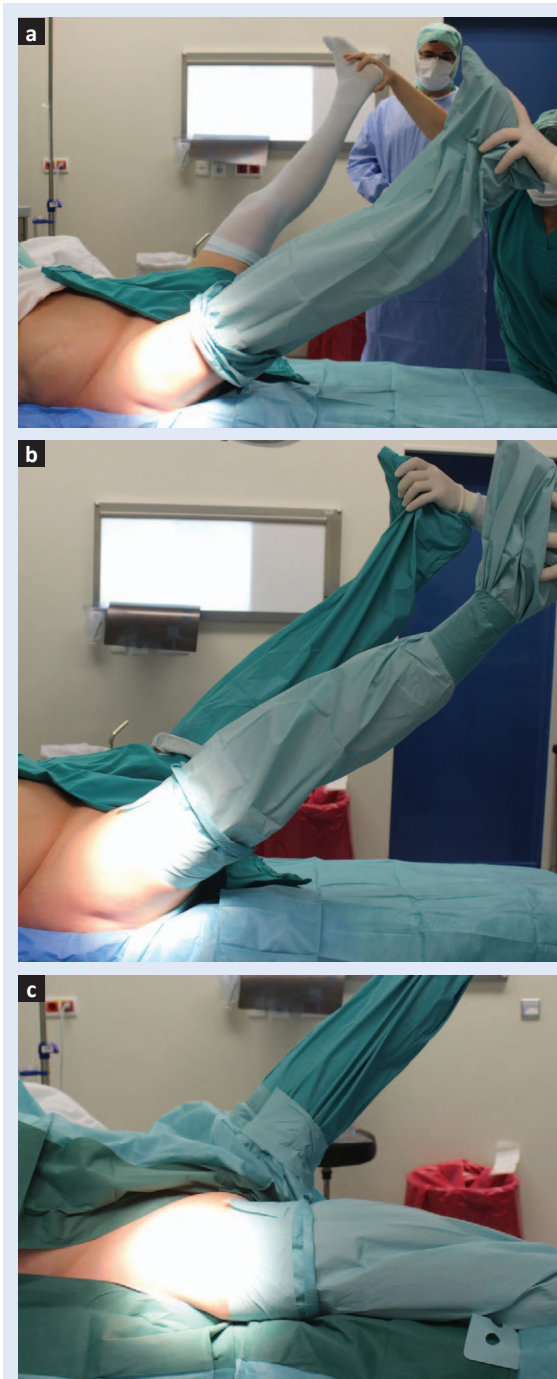
The operating hip is prepared in standard manner from the rib arch to the ankle. The opposite leg is left unsterile, enclosed in an elastic stocking. After covering the table with a sterile drape, a sterile compress is placed between the legs. A sterile stocking is placed on both legs: till the base of the great trochanter on the operating leg, and till the groin on the unsterile side. A large U cover is used for covering the operating side, while the healthy leg is introduced through the hole made on the cover. The drape is fixed around the distal part of the leg with sterile tape, and the hip is covered with surgical foil (Figure 4). We do not use any type of leg holder for the opposite leg.

#### ANATOMIC LANDMARKS AND INCISIONS

The anterior superior iliac spine and the great trochanter are marked with a pen. In slim patients sometimes the prominence on the skin made by the tensor fascia lata muscle (TFL) can be seen, allowing easier placement of the skin in-

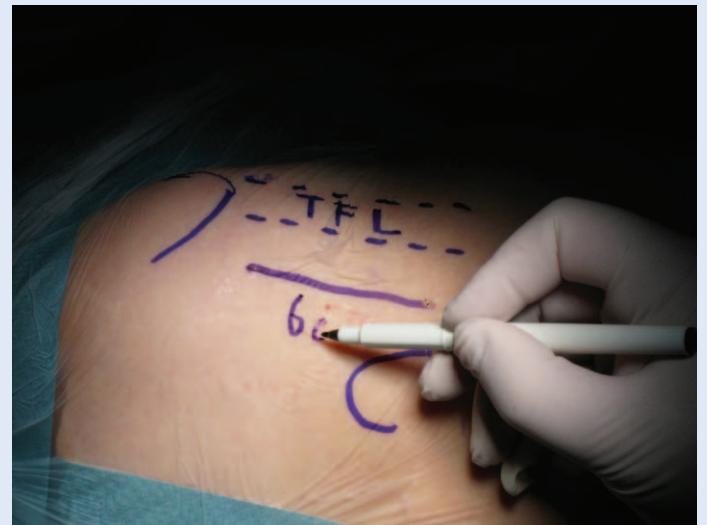**Figure 3.** a) Position of the patient on operating table – view by side. The great trochanter should be positioned just above the point where the table will be bent; b) Position of the patient of operating table – view by front.





**Figure 4.** a) Both legs are raised. The sterile stocking is put on the operated leg first; b) And then on the opposite leg until the groin; c) The stocking is fixed by sterile tape.

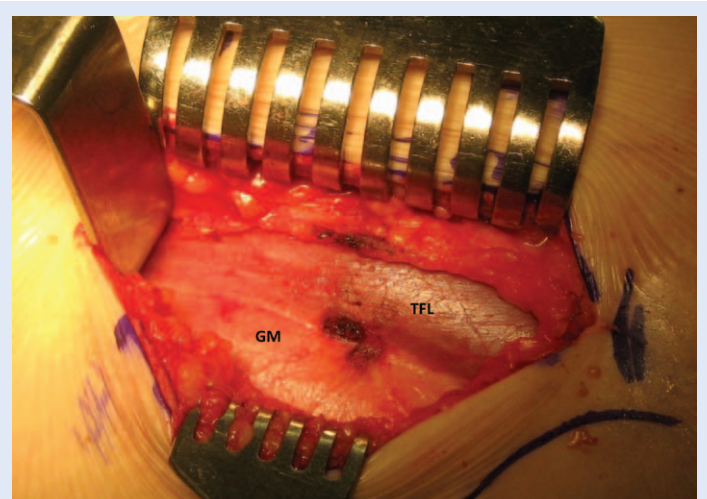
cision between the TFL and the GM. If the TFL cannot be seen, the skin incision is placed parallel with the anterior border of the GT, a little upwardly directed. The length depends on the patient's BMI, varying from 6 cm in a slim female to 10 cm in an obese male (Figure 5).



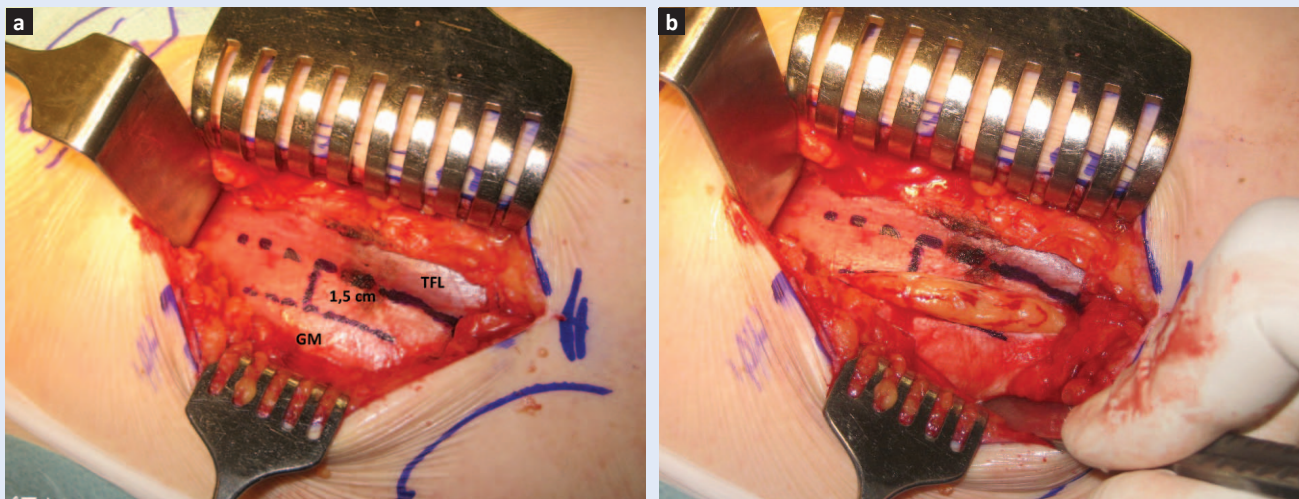
**Figure 5.** Landmarks and planned length and direction of skin incision

### SUPERFICIAL DISSECTION

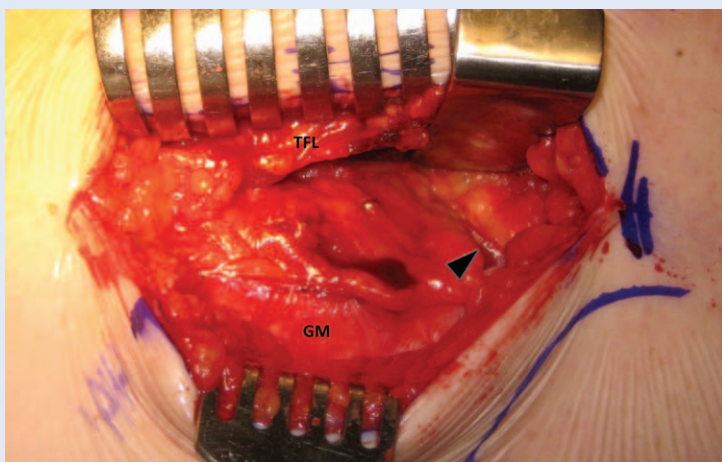
The subcutaneous tissue is incised along the line of the previous skin incision. Blunt instruments or gauze removes the rest of the fat tissue from the underlying fascia lata (FL). In the ventral part of the operative field, the part of the TFL and its connection to the fascia lata is seen (Figure 6). The FL is sharply incised 1-1.5 cm from the TIF insertion in the same direction as the previous incisions (Figure 7). By elevating the anterior part of the fascia with a small instrument, the underlying fibers of the gluteus



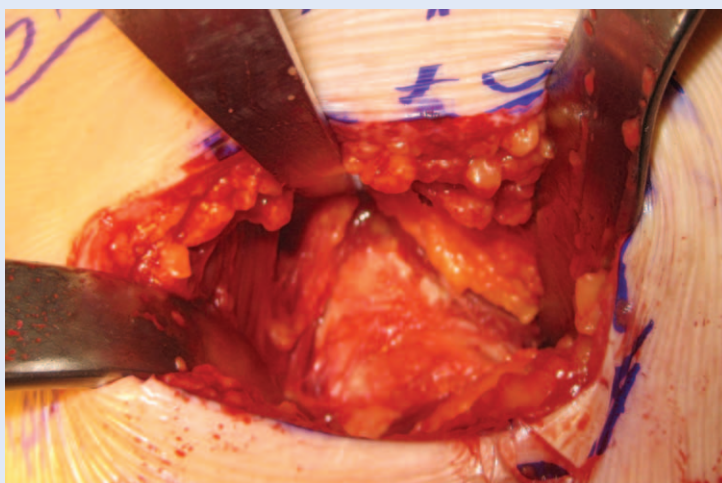
**Figure 6.** After dissection of the subcutaneous tissue the tensor fasciae latae (TFL) and gluteus medius muscle are shown beneath the fascia.



**Figure 7.** a) Incision of the fascia should be made 1-1,5 cm from edge of the TFL. This small flap will be sutured with the rest of fascial tissue at the end of operation; b) If the fascia is incised in the correct position which means at the point where the TFL and GM are separated with fat tissue, it will protrude immediately after incision is made.



**Figure 8.** Small vessels passed through space between TFL and GM drowned in fat tissue (vessel is shown by small arrow).



**Figure 9.** Position of the Hohmann retractors allow nice view of anterior part of the hip capsule

medius, which arise from the fascia, are seen. These fibers must be gently detached from the fascia by blunt dissection. After dissecting the fibers, the interval in the form of a triangle between the TFL and the GM is shown. The distal part of this triangle is filled with fat tissue in which the vessels are hidden (Figure 8). These vessels should be coagulated or ligated before entering this interval by finger or blunt instruments.

#### DEEP DISSECTION

After coagulation of the aforementioned vessels, the index finger is introduced into the interval in the medial and downward direction. At this point, the medial part of the neck all the way to the lesser trochanter can be palpated. A blunt curved Hohmann retractor is introduced parallel and under the index finger, embracing the medial hip capsule. A sharp curved Hohmann retractor is positioned under the GM, embracing the lateral part of the hip capsule. Using a rasp, the capsular insertion of the rectus femoris fibers is removed from the anterior capsule and a curved sharp Hohmann retractor is placed over the anterior part of the acetabulum with its tip directed toward SAIS (Figure 9). We strongly recommend slight hip flexion during these maneuvers by placing a sterile cushion under the ipsilateral knee. Optionally, a Steinmann pin can be used and introduced

in the lateral portion of the acetabulum as protection of the GM.

### CAPSULAR INCISION

Once the anterior capsule is visualized till the acetabular rim, the incision should be done. Depending on the surgeon's preferences, a Z or T incision can be used when we plan suturing the capsule at the end of the surgery. In cases of RA or high grade OA, the anterior capsular tissue should be removed.

### FEMORAL NECK OSTEOTOMY

After removing the capsular tissue, the Hohmann retractors are placed inside the joint over the medial and lateral portions of the femoral neck. All osteophytes from the head and neck should be removed by rongeur or chisel, as well as the remaining capsule at the neck base (Figure 10). This procedure allows excellent visualization of the femoral neck, almost till the intertrochanter line.

This is a prerequisite for performing neck osteotomy which can be done in one act, or as double osteotomy when the slice of the bone from the neck is removed first and then the femoral head extracted using a tap (Figure 11). This should be carried out with caution because during removal of the head, part of the GM can be damaged.

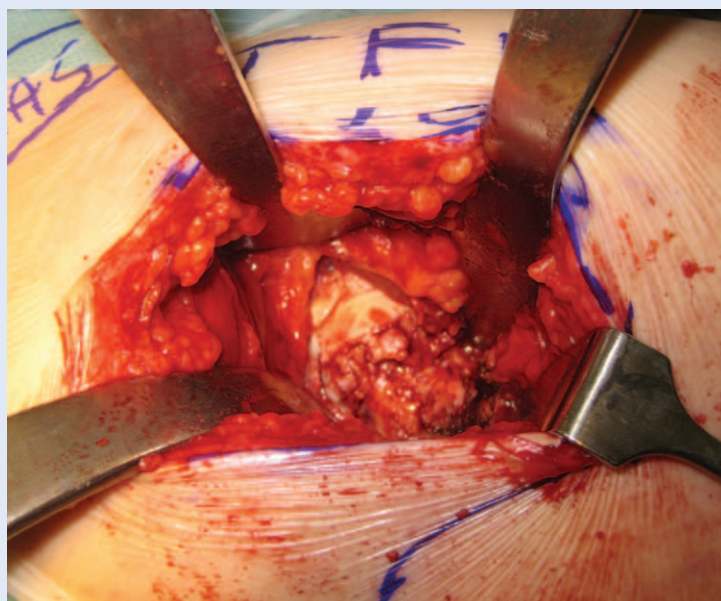
### ACETABULAR PREPARATION

When the femoral head is removed, an additional Hohmann retractor is placed over the distal and anterior parts of the acetabulum adjacent to the ligamentum transversum acetabuli. This allows a broad view of the acetabulum (Figure 12). First, a chisel or small diameter reamer should remove the osteophytes covering the bottom of the acetabulum until the fossa acetabuli is shown. At this point, all acetabular landmarks can be identified.

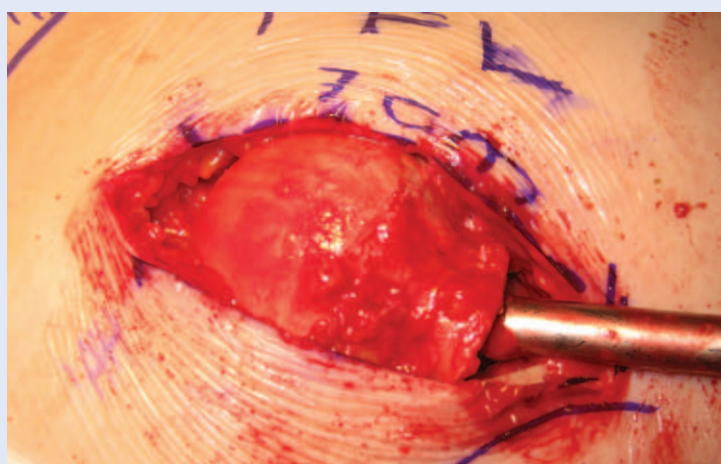
This is an important step, which allows us to ream the acetabulum in the proper direction and depth. A standard straight reamer holder or an offset holder can be used. After preparation of the acetabulum, the acetabular cup is implanted (Figure 13, 14). The size of the reamer

depends on the type of the cup used, it should be smaller than the cup in the press-fit cementless prosthesis, or larger when a cemented cup is used. The difference depends on the type of the prosthesis, the bony quality and the surgeon's preference.

During the learning curve, many details of the procedure have to be adopted, as they can significantly influence the success of the surgery and the occurrence of complications.

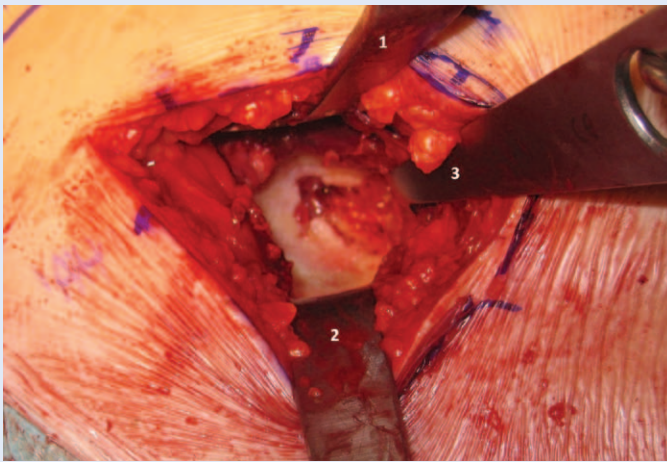


**Figure 10.** Osteophytes covering the femoral neck should be removed prior neck osteotomy

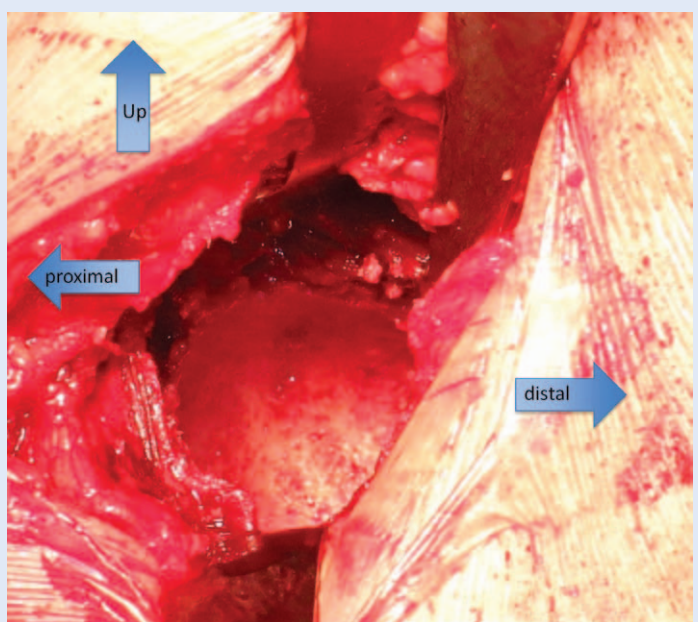


**Figure 11.** Extraction of the femoral head. Incision is average length as diameter of the femoral head





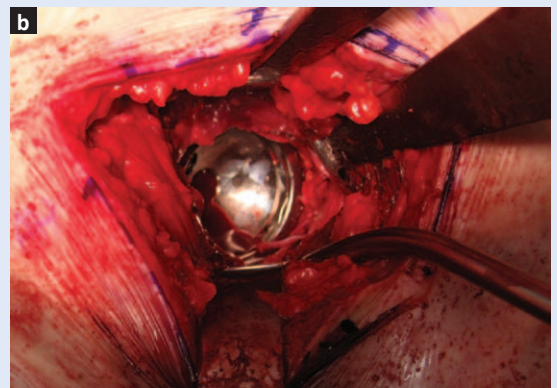
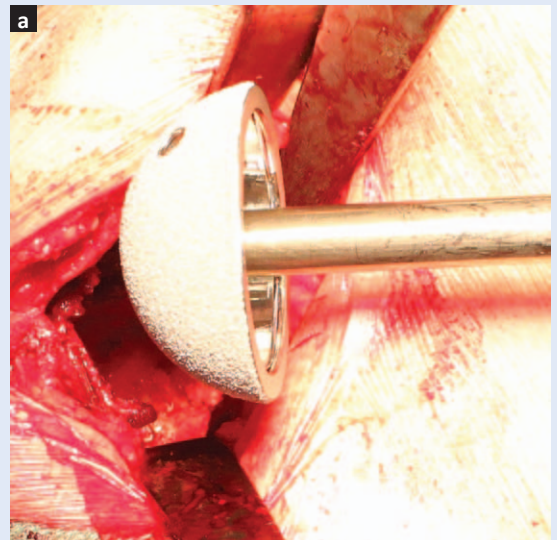
**Figure 12.** Position of the Hohman retractors allow broad view of whole acetabulum. First retractor is placed in superior part of the acetabular wall, the second in the opposite direction and pull the proximal part of the femur below the acetabulum. Third Hohman is placed over the distal and anterior part of the acetabulum adjacent to ligamentum transversum acetabuli.



**Figure 13.** Acetabulum after reaming showing cancellous bone good vascularity

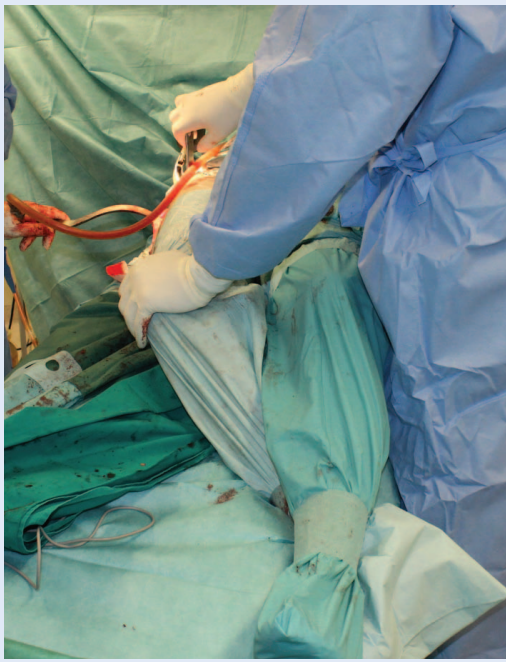
#### FEMORAL PREPARATION

The operated leg is placed adducted below the opposite one with maximal external rotation (Figure 15). By using a hooked instrument introduced in the canal, the proximal femur is pulled upward a few times, and the remaining capsule is removed first from the superior part of the neck, thus allowing approach to the fossa trochanteri-



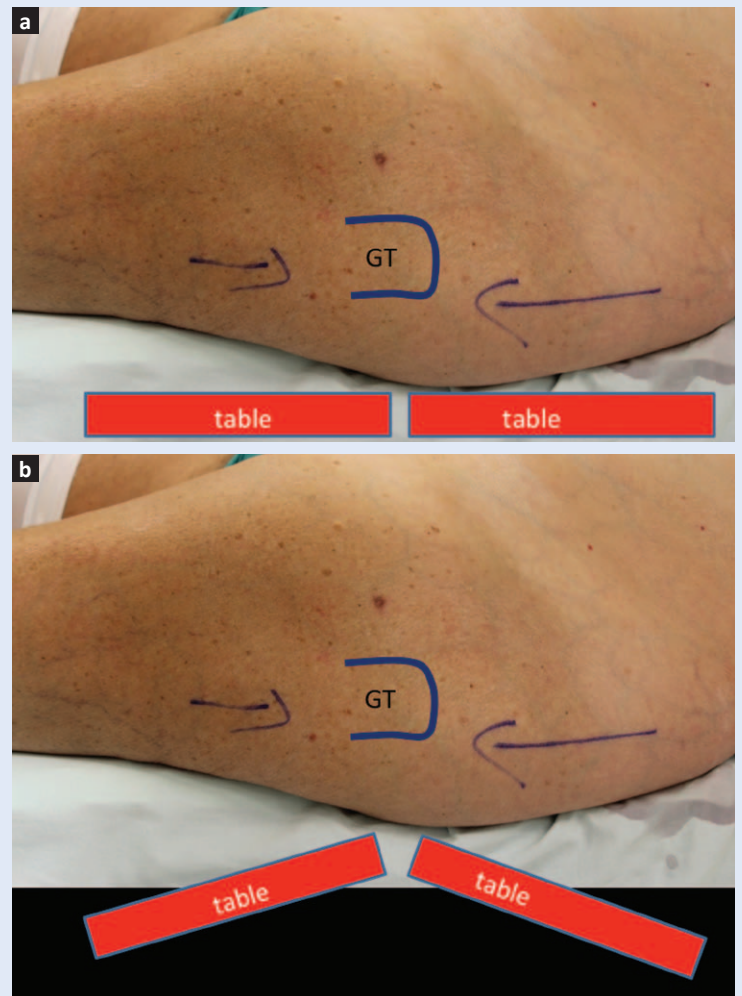
**Figure 14.** a) Cementless acetabular cup prior implantation; b) implanted cementless acetabular cup

ca, and then from the medial part of the neck, but only till the external rotators, using a cautery. The insertion of the external rotator should not be damaged during this procedure. This step is important and allows additional mobilization of the femur, which can be tested by pulling the femur again with the hook. Adduction of the operating leg is slightly advanced, and maximal external rotation is performed. Both legs of the operating table are lowered, and the patient is placed in the anti-Trendelenburg position (Figure 16). This maneuver allows lateralization of the femoral canal and easy preparation and instrument manipulation. The femoral canal is then rasped according to preoperative plan (Figure 17) and the femoral stem is implanted using a straight or curved holder (Figure 18). After setting the probe for femoral neck length, the hip is easily repositioned and its stability is checked in

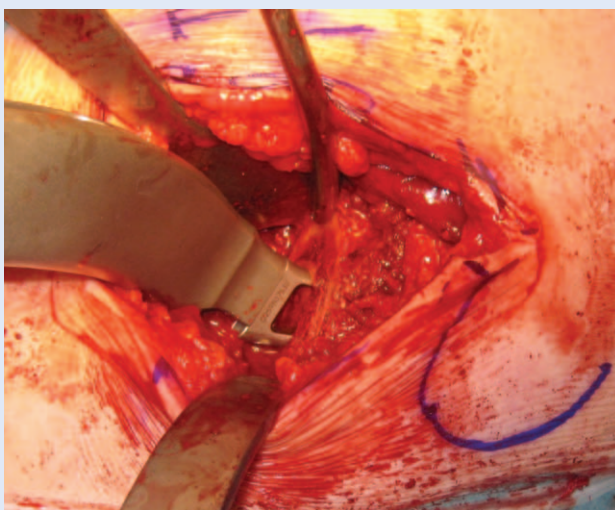


**Figure 15.** Position of the operated leg during femoral canal preparation is in average 30° of abduction and maximal external rotation.

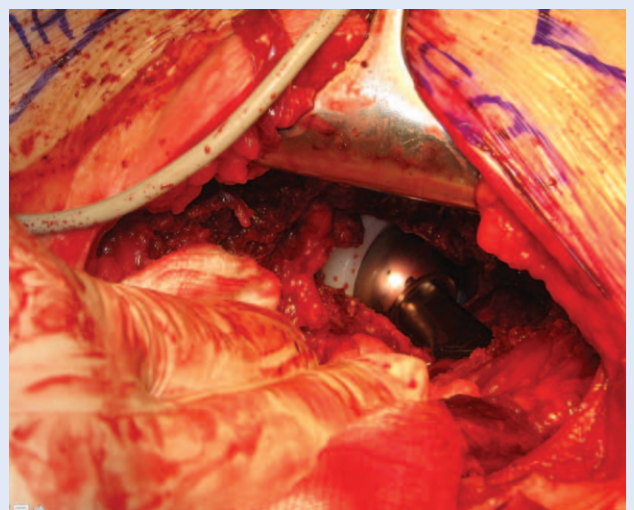
various positions. We always use a neutral position in the coronal and sagittal planes with maximal external rotation, as the most vulnerable position for dislocation. The leg length should also be checked. If we are satisfied with the stability and the leg length, the final component is implanted (Figure 19). At the end of the procedure, the TFL and the GM have remained almost intact (Figure 20).



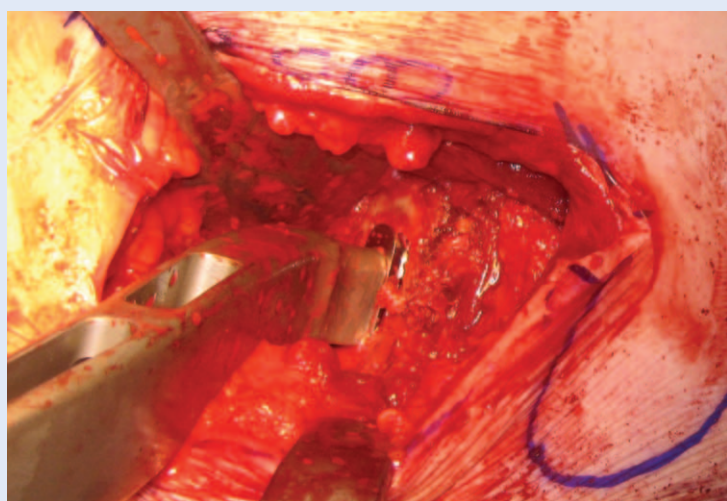
**Figure 16.** a) The great trochanter is positioned just above the point of the table where it will be bent; b) Bending the leg allow rising of the great trochanter in the operative field and easier manipulation with the proximal femur during canal preparation.



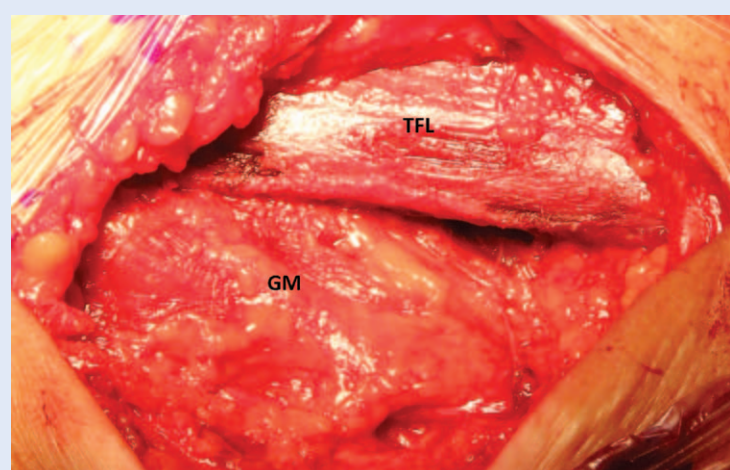
**Figure 17.** Femoral canal preparation with femoral rasp double offset holder



**Figure 18.** Implantation of the femoral stem



**Figure 19.** Intraoperative view on after reposition of the hip. Stability should be checked in all direction with leg in external rotation.



**Figure 20.** GM and TFL at the end of the procedure remains almost intact

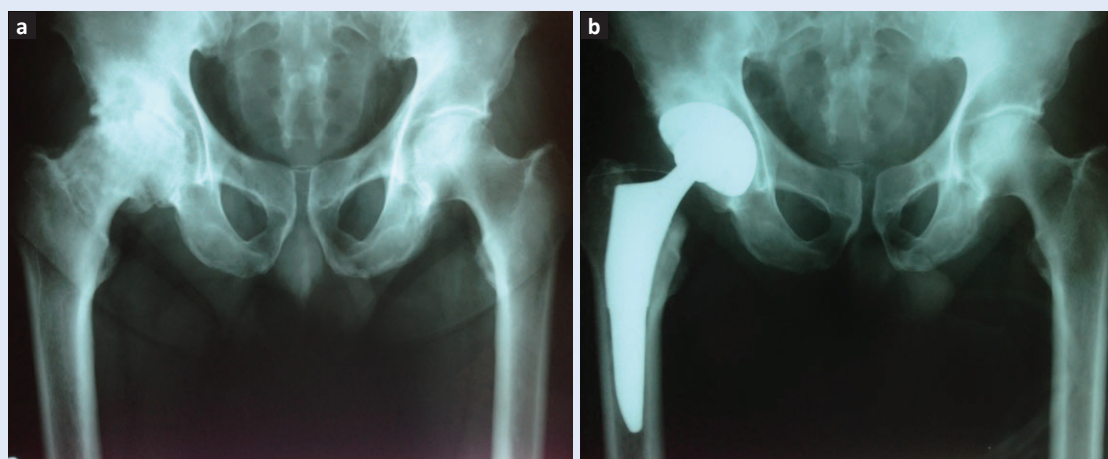
The hip is abundantly washed. Drain is introduced and suture of the fascia, the subcutaneous tissue and the skin is performed. The positions of the implanted components are checked with plain X-ray. An X-ray of the pelvis with both hips should be done (Figure 21).

#### POSTOPERATIVE PROTOCOL

The patient is moved from the operating table to the recovery room. The operated leg should be in slight abduction and internal rotation to prevent hip dislocation during transfer. On the recovery bed, the operated leg is placed in the neutral position. Patients are recommended to use crutches for 6 weeks, but this depends on their health status and age.

#### CONCLUSION

According to our experience, AL-MIS hip arthroplasty in the supine position is a safe, efficient and reproducible procedure, which is easier to perform with special instruments and a curved femoral implant. AL-MIS allows patients faster recovery with less postoperative pain and shorter hospitalization. During the learning curve, many details of the procedure have to be adopted, as they can significantly influence the success of the surgery and the occurrence of complications.



**Figure 21.** a) Preoperative plain X-ray of the pelvis with both hips; b) Postoperative plain X-ray showing good positioned of the component with restoration of the rotation center and the femoral offset.

## REFERENCES

1. DeWal H, Su E, DiCesare PE. Instability following total hip arthroplasty. *Am J Orthop* 2003;32:377-82.
2. Masonis JL, Bourne RB. Surgical approach, abductor function, and total hip arthroplasty dislocation. *Clin Orthop Relat Res* 2002;405:46-53.
3. Kennon R, Keggi JM, Westmore RS, Zatorski L, Huo M, Keggi KJ. Total hip arthroplasty through a minimally invasive anterior surgical approach. *J Bone Jt Surg (Am)* 2003;85:39-48.
4. Siguier T, Siguier M, Brumpt B. Mini-incision anterior approach does not increase dislocation rate: a study of 1037 total hip replacements. *Clin Orthop* 2004;164-73.
5. Bertin KC, Röttinger H. Anterolateral mini-incision hip replacement surgery: a modified Watson-Jones approach. *Clin Orthop* 2004;429:248-55.
6. Goldstein WM, Branson JJ, Berland KA, Gordon AC. Minimal-incision total hip arthroplasty. *J Bone Jt Surg (Am)* 2003;85:33-8.
7. Berger R, Duwelius P. The two-incision minimally invasive total hip arthroplasty: technique and results. *Orthop Clin North Am* 2004;35:163-72.
8. Laffosse JM, Chiron P, Moliner F, Bensafi H, Puget J. Prospective and comparative study of the anterolateral mini-invasive approach versus invasive posterior approach for primary total hip replacement. Early results. *Int Orthop* 2007;31:597-603.
9. Mardones R, Pagnano M, Nemanich J, Trousdale R. Muscle damage after total hip arthroplasty done with the two-incision and mini-posterior techniques. *Clin Orthop* 2005;441:63-7.
10. Watson-Jones R. Fractures of the neck of the femur. *Br J Surg* 1936;23:787-808.
11. Graf R, Azizbaig-Mohajer M. Minimally invasive total hip replacement with the patient in the supine position and the contralateral leg elevated. *Oper Orthop Traumatol* 2006;18:317-29.
12. Roth A, Venbrocks RA. Total hip replacement through a minimally invasive, anterolateral approach with the patient supine. *Oper Orthop Traumatol* 2007;19:442-57.
13. Jerosch J, Theising C, Fadel M. Antero-lateral minimal invasive (ALMI) approach for total hip arthroplasty technique and early results. *Arch Orthop Trauma Surg* 2006;126:164-73.
14. Pfeil J, Siebert WE. *Minimally Invasive Surgery in Total Hip Arthroplasty*. Berlin, Heidelberg: Springer Verlag, 2000.
15. Woolson ST, Mow CS, Syquia JF, Lannin JV, Schurman DJ. Comparison of primary total hip replacements performed with a standard incision or a mini-incision. *J Bone Joint Surg Am* 2004;86-A:1353-8.
16. de Beer J, Petruccioli D, Zalzal P, Winemaker MJ. Single-incision, minimally invasive total hip arthroplasty: length doesn't matter. *J Arthroplasty* 2004;19:945-50.
17. Fehring T, Mason J. Catastrophic complications of minimally invasive hip surgery. *J Bone Joint Surg* 2005;87-A:711-4.
18. Kreder HJ, Deyo RA, Koepsell T, Swiontkowski MF, Kreuter W. Relationship between the volume of total hip replacements performed by providers and the rates of postoperative complications in the state of Washington. *J Bone Joint Surg Am* 1997;79:485-94.