

Solitarna metastaza primarnog skvamoznog karcinoma vagine u tibiji: prikaz slučaja

Pavić Mamula, Jelena; Tkalčić, Lovro; Miletić, Damir; Veljković Vujaklija, Danijela

Source / Izvornik: **Medicina Fluminensis, 2023, 59, 195 - 199**

Journal article, Published version

Rad u časopisu, Objavljena verzija rada (izdavačev PDF)

https://doi.org/10.21860/medflum2023_300579

Permanent link / Trajna poveznica: <https://urn.nsk.hr/urn:nbn:hr:184:359914>

Rights / Prava: [Attribution 4.0 International](#)/[Imenovanje 4.0 međunarodna](#)

Download date / Datum preuzimanja: **2024-07-23**



Repository / Repozitorij:

[Repository of the University of Rijeka, Faculty of Medicine - FMRI Repository](#)



Solitary Metastasis in the Tibia as a Feature of Primary Squamous Vaginal Carcinoma: A Case Report

Solitarna metastaza primarnog skvamoznog karcinoma vagine u tibiji: prikaz slučaja

Jelena Pavić Mamula¹, Lovro Tkalčić¹, Damir Miletić^{1, 2}, Danijela Veljković Vujaklija^{1, 2*}

Abstract. Aim: Primary vaginal cancer is rare, comprising about 3% of all gynaecological malignancies. Solitary bone metastases to appendicular skeleton are extremely rare and there are only few published reports. We report the case of isolated metastasis in the tibia as a feature of primary squamous vaginal carcinoma. We present this case because of its rarity and for documentation and discussion purposes. **Case report:** We present a case of a 44-year old woman diagnosed with squamous vaginal cancer in June 2015. Computed tomography of the thorax, abdomen and pelvis revealed no distant metastases. She was treated with interstitial intracavitary brachytherapy and concomitant chemoradiotherapy. In March 2016 she was admitted to our hospital because of the swelling and the pain in the lower right leg. There was no history of trauma and plain radiographs were normal. Two months later, after further progression of pain, plain radiographs showed intramedullary permeative bone lesion with cortical disruption of tibial diaphysis and local soft tissue swelling. MRI and core needle biopsy confirmed vaginal cancer metastasis containing tumor cells identical to the primary tumor. The patient was treated with radiotherapy and chemotherapy. Despite the treatment there was further progression of the disease with multiple bone metastases and eventually lung and brain metastases. **Conclusion:** This case report is another reminder that although extremely rare, solitary metastatic bone lesions of vaginal cancer are possible. Since symptoms mimic various benign conditions, it is important to consider bone metastasis as possible diagnosis in patients with progressive bone pain not responding to analgesic treatment.

Keywords: Diagnostic imaging; Neoplasm Metastasis; Vaginal Neoplasms

Sažetak. Cilj: Primarni karcinom vagine vrlo je rijedak, čini oko 3 % svih ginekoloških tumora. Solitarne metastaze u kosti aksijalnog skeleta iznimno su rijetke, sa svega nekoliko prikazanih slučajeva. U svrhu dokumentiranja i diskusije prikazujemo iznimno rijedak slučaj izolirane metastaze skvamoznog karcinoma vagine u tibiji. **Prikaz slučaja:** Prikazujemo slučaj žene u dobi od 44 godine kod koje je u lipnju 2015. dijagnosticiran skvamozni karcinom vagine. Računalna tomografija toraksa, abdomena i zdjelice nije pokazala udaljene metastaze. Liječena je intersticijalnom brahiterapijom i konkomitantnom kemoradioterapijom. U ožujku 2016. zaprimljena je u našu bolnicu zbog otoka i bolova desne potkoljenice. U anamnezi nije bilo podatka o traumi i standardni radiogrami bili su normalni. Dva mjeseca kasnije, nakon daljnje progresije bolova, standardni radiogrami pokazali su intramedularnu permeativnu koštanu leziju i destrukciju kortikalne kosti dijafize tibije uz otok okolnih mekih tkiva. MR i biopsija širokom iglom potvrdila je metastazu karcinoma vagine koja sadrži tumorske stanice identične primarnom tumoru. Pacijentica je liječena radioterapijom i kemoterapijom. Usprkos svim postupcima liječenja, bolest je u idućem periodu napredovala s brojnim koštanim metastazama te, u konačnici, metastazama pluća i mozga. **Zaključci:** Ovaj prikaz slučaja još je jedan podsjetnik da su,

¹ Clinical Hospital Centre Rijeka, Department of Radiology, Rijeka, Croatia

² University of Rijeka, Faculty of Medicine, Department of Radiology, Rijeka, Croatia

***Corresponding author:**

Danijela Veljkovic Vujaklija, MD, PhD
Clinical Hospital Centre Rijeka, Department of Radiology
Krešimirova 42, 51000 Rijeka, Croatia
E-mail: danijelavv@uniri.hr

<http://hrcak.srce.hr/medicina>

iako iznimno rijetke, solitarne koštane metastaze karcinoma vagine moguće. Budući da simptomi metastaza u kostima imitiraju razna benigna stanja, u pacijenata s progresivnim bolovima u kostima koji ne popuštaju na terapiju analgeticima, važno je uzeti u obzir i metastaze kao moguću dijagnozu.

Ključne riječi: karcinom vagine; metastaze; slikovni prikaz

Despite metastasis to bone is common in solid tumors, the prevalence of solitary bone metastasis in vaginal carcinoma is unknown but is probably extremely rare due to few documented cases.

INTRODUCTION

We report the case of isolated metastasis in the tibia as a feature of primary squamous vaginal carcinoma. This is one of the few documented cases of metastasis to appendicular skeleton. We present this case because of its rarity and for documentation and discussion purposes.

CASE REPORT

A 44-year-old woman was diagnosed with vaginal cancer in June 2015. On gynecological examination, an exophytic 50 mm lesion was seen on the posterior vaginal wall, which bled easily on contact. There were no palpable inguinal lymph nodes. Biopsy taken from the lesion was reported as poorly differentiated squamous carcinoma. Magnetic resonance imaging (MRI) revealed an extensive neoplasm of posterior and lateral vaginal walls infiltrating the pelvic diaphragm with unilaterally enlarged lymph nodes of the obturator group. There was no evidence of the involvement of the cervix. No distant metastases were seen on subsequent staging computed tomography (CT) of the thorax, abdomen, and pelvis. The patient underwent interstitial intracavitary brachytherapy and concomitant chemoradiotherapy. The follow-up MRI showed small residual tumor and inapparent obturator lymph nodes. We have to inform about patient being exposed to diethylstilbestrol. In March 2016 the patient was admitted to our clinic complaining of progressive pain and swelling of her lower leg. No history of trauma was reported. Plain radiographs of the lower leg were

taken, showing no pathomorphological change (Figure 1). Two months later, after further progression of pain plain radiography showed intramedullary permeative bone lesion with cortical disruption of tibial diaphysis and surrounding soft tissue thickening (Figure 2). MRI showed an extensive soft tissue mass with large extraosseous component with marked signal enhancement after administration of intravenous Gadolinium based contrast. The ADC values were low indicating high cellularity of the lesion (Figure 3). Additionally, PET-CT scan was obtained, showing no other distant metastasis.

Core needle biopsy of the lesion described above was performed and pathohistological report confirmed metastatic lesion containing tumor cells identical to the primary tumor.

The patient underwent radiation therapy and chemotherapy with 5-Fluorouracil after multidisciplinary team (oncologist, orthopedic surgeon, radiologist) consensus.

The follow up MR in August 2016 revealed the same size of the metastatic bone lesion in the tibia but with decreased cellularity indicating favorable response to treatment. On the same day MR of the pelvis revealed bone lesions in both ischial tuberosities highly suspicious of metastases. Bone scintigraphy performed in September 2016 confirmed the suspected metastatic lesions and revealed a new lesion in the right calcaneus. In October 2016 the patient underwent surgery for the clinically evident metastasis in the right labia majora which was subsequently confirmed on pathohistological analysis. She was treated with chemotherapy (paclitaxel and carboplatin). Follow up PET/CT in November 2016 revealed the progression of known bone metastases and several new osseous lesions subsequently treated with palliative radiotherapy and Disodium pamidronate. During 2017 she received 6 cycles of chemotherapy with 2 separate cycles of palliative radiotherapy over ischial tuberosity and right femur. Despite the treatment there was further progression of the disease confirmed on follow up PET/CT studies performed in January and October 2018 with multiple bone metastases and eventually lung and brain metastases. The patient died little over three years after the initial diagnosis.

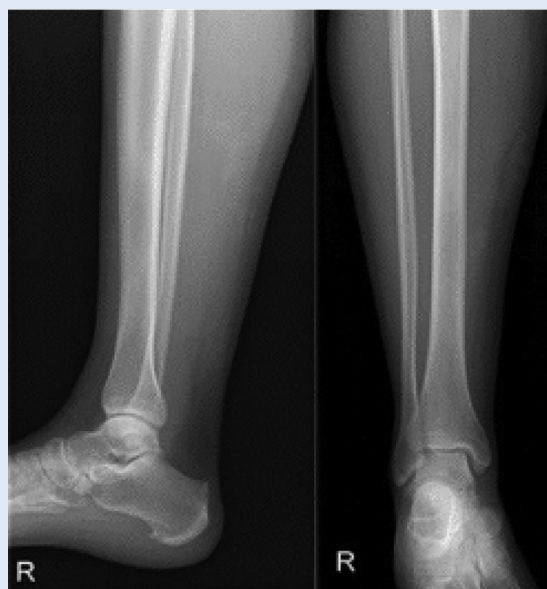

Figure 1. Plain x-rays of the right lower leg. No evident bone lesion is seen.

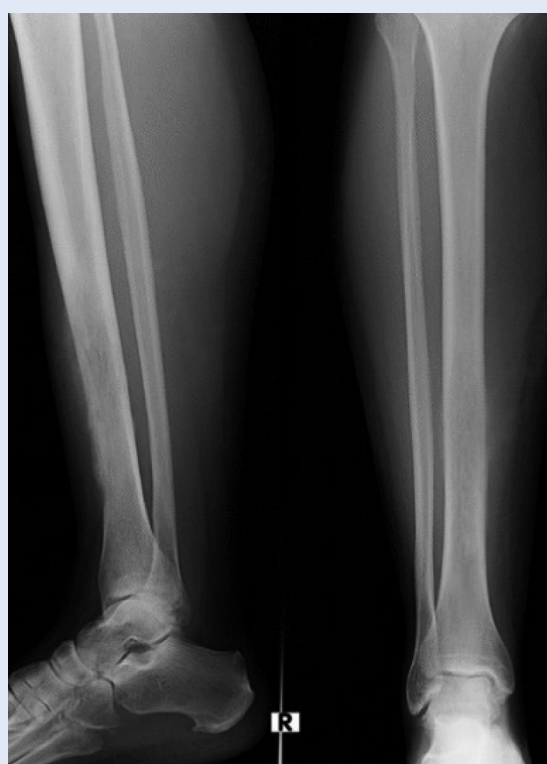

Figure 2. Follow up plain x-rays of the right lower leg. Intramedullary permeative bone lesion with cortical disruption of tibial diaphysis and surrounding soft tissue thickening.

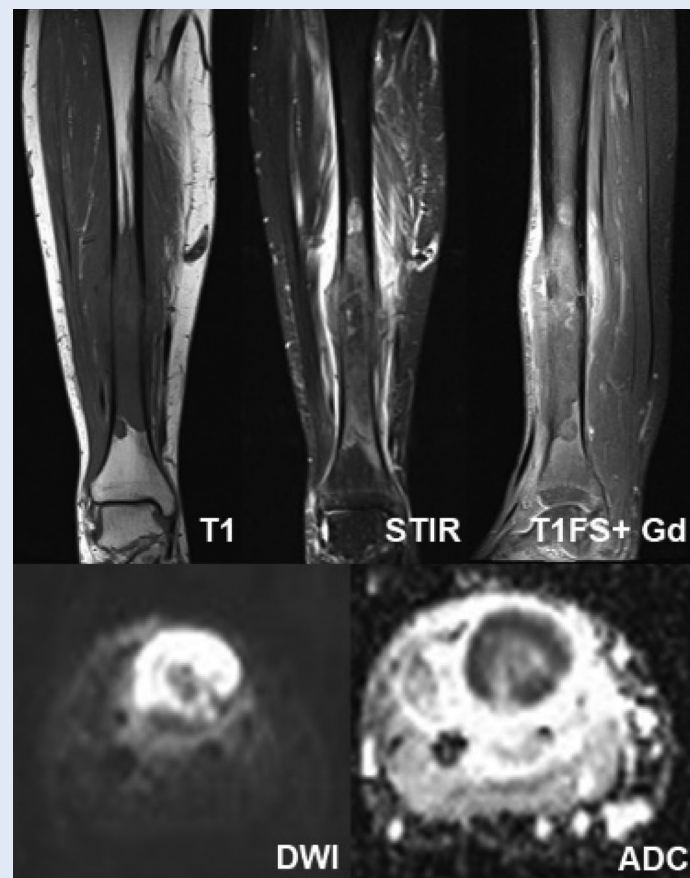


Figure 3. Magnetic resonance imaging (MRI) of the right lower leg. Coronal T1-weighted MRI scan (T1) shows an extensive low signal mass in the tibial diaphysis with extraosseous spread. The surrounding bone marrow oedema is better seen on coronal STIR images (STIR). Sagittal contrast-enhanced T1-weighted MRI scan (T1FS+Gd) shows strong contrast enhancement of the mass. High signal on Diffusion-weighted images (DWI) and low apparent diffusion coefficient (ADC) indicate high cellularity of the lesion.

DISCUSSION

Vaginal cancer is a rare entity comprising about 3% of all gynecologic cancers. The most common histopathological type is squamous cell carcinoma mainly affecting postmenopausal women with peak incidence at age older than 70 years being followed by adenocarcinoma. The adenocarcinoma commonly affects younger women (median age, 19 years) and is more likely to metastasize to the lungs and lymph nodes. Moreover, the rising incidence of invasive vaginal cancer in younger women is in strong association with human papillomavirus (HPV) infection (93%)¹. A subtype, clear cell adenocarcinoma, is associated with *in utero* exposure to diethylstilbestrol and is found in 2% of exposed females¹.

As other gynecologic malignancies, vaginal cancer is classified according to the International Federation of Gynecology and Obstetrics (FIGO). MRI, which is not included in FIGO classification, has been shown to accurately contribute to diagnosis, local staging and dissemination of disease in vaginal cancer². Other imaging modalities, such as FDG-PET and CT are useful for staging, follow up and treatment planning².

Since symptoms mimic various benign conditions, it is important to consider bone metastasis as possible diagnosis in cancer patients with progressive bone pain not responding to analgesic treatment.

One of the most important prognostic factors is lymph node involvement. Typical patterns of lymph node involvement are variable and unreliable; however, inguinal lymph node involvement has been implicated in aggressive tumor behavior and lower rates of survival^{1,3}.

Hematogenous metastasis distribution in patients with vaginal cancer was shown in a study comprising 44 patients with disseminated disease. Overall, 51 metastatic sites were described: lung in 25 cases, followed by 9 paraaortic, 8 liver, 5 bone, 3 peritoneal and 1 brain metastatic site, proving that vaginal carcinoma is not confined to abdominal cavity⁴.

Bone metastasis from vaginal cancer is uncommon, especially in the distal appendicular skeleton. The rarity of vaginal cancer bone metastasis is further confirmed by study showing results of autopsies performed on 305 patients with primary carcinomas of the cervix, endometrium, ovaries, fallopian tubes, vulva, and vagina⁵. Skeletal metastases were detected in 49 cases, but no cases of osseous metastasis from vaginal carcinoma⁵. Also, a more recent study of surgical management of bone metastases including 18 patients surgically treated for metastatic gynecologic tumors of bone showed metastases from uterus, cervix, and ovary, but not vaginal cancer bone metastases⁶.

Through literature search we found only one case of solitary skeletal metastasis being the presenting feature of vaginal carcinoma – a case of fibula

metastasis⁷. Cases of metastatic vaginal carcinoma of the temporal bone, acrometastasis to hand and to humerus were also shown⁸⁻¹⁰.

CONCLUSION

Despite metastasis to bone is common in solid tumors, the prevalence of solitary bone metastasis in vaginal carcinoma is unknown but is probably extremely rare due to few documented cases. Even more rare is further progression to bones without another organ metastasis.

Since symptoms mimic various benign conditions, it is important to consider bone metastasis as possible diagnosis in a patient with progressive bone pain not responding to analgesic treatment.

Traditionally, patients with bone metastasis have advanced stage disease, and the utility of surgical intervention is unclear. Some advocate minimal intervention and aggressive pain control, whilst others support more aggressive surgical intervention due to the unresponsiveness of these metastatic lesions to chemotherapy, radiotherapy and other noninvasive measures⁶. Due to the rarity of bone metastasis from gynecologic malignancies, the prognosis of these patients after surgical treatment has not been well established⁶.

This case report is yet another alert that although extremely rare, isolated metastatic bone lesions of vaginal cancer are possible and in the appropriate clinical setting should not be missed.

Conflicts of Interest: Authors declare no conflicts of interest.

REFERENCES

1. Gardner S, Sunil J, Klopp H, Devine E, Sagebiel T, Viswanathan C et al. Primary vaginal cancer: role of MRI in diagnosis, staging and treatment. *Br J Radiol* 2015;88: 20150033.
2. FIGO Committee on Gynecologic Oncology. Current FIGO staging for cancer of the vagina, fallopian tube, ovary and gestational trophoblastic neoplasia. *Int J Gynecol Obstet* 2009;105:2-4.
3. Hellman K, Lundell M, Silfverswärd C, Nilsson B, Hellström AC, Frankendal B. Clinical and histopathologic factors related to prognosis in primary squamous cell carcinoma of the vagina. *Int J Gynecol Cancer* 2006;16: 1201-11.
4. Chyle V, Zagars GK, Wheeler JA, Wharton JT, Delclos L. Definitive radiotherapy for carcinoma of the vagina: outcome and prognostic factors. *Int J Radiat Oncol Biol Phys* 1996;35:891-905.

5. Abdul-Karim FW, Kida M, Wentz WB, Carter JR, Sorensen K, Macfee M et al. Bone metastasis from gynecologic carcinomas: a clinicopathologic study. *Gynecol Oncol* 1990;39:108-14.
6. Ji T, Eskander R, Wang Y, Sun K, Hoang BH, Guo W. Can surgical management of bone metastases improve quality of life among women with gynecologic cancer? *World J Surg Oncol* 2014;12:250.
7. Tjalma WA, Somville J. Fibula metastasis as the presenting feature of vaginal cancer. *Eur J Gynecol Oncol* 2011;32:114-6.
8. Corey JP, Nelson E, Crawford M, Riester JW, Geiss R. Metastatic vaginal carcinoma to the temporal bone. *Am J Otol* 1991;12:128-31.
9. Khosla D, Rai B, Patel FD, Sapkota S, Srinivasan R, Sharma SC. Acrometastasis to hand in vaginal carcinoma: a rare entity. *J Can Res Ther* 2012;8:430-2.
10. Fisher M, Kuhl M, Feek U, Romingers M, Schipper ML, Hadji P et al. Bone metastases in vulvar cancer: a rare metastatic pattern. In *J Gynecol Cancer* 2005;15: 1173-76.