

Expression of Matrix Metalloproteinase 9 in Primary and Recurrent Breast Carcinomas

Fučkar Čupić, Dora; Cini Tešar, Eleonora; Matušan Ilijaš, Koviljka; Nemrava, Johan; Kovačević, Marinko; Mustać, Elvira

Source / Izvornik: **Collegium antropologicum, 2011, 35 - supplement 2, 7 - 10**

Journal article, Published version

Rad u časopisu, Objavljena verzija rada (izdavačev PDF)

Permanent link / Trajna poveznica: <https://um.nsk.hr/um:nbn:hr:184:867704>

Rights / Prava: [Attribution 4.0 International](#)/[Imenovanje 4.0 međunarodna](#)

Download date / Datum preuzimanja: **2024-08-05**



Repository / Repozitorij:

[Repository of the University of Rijeka, Faculty of Medicine - FMRI Repository](#)



Expression of Matrix Metalloproteinase 9 in Primary and Recurrent Breast Carcinomas

Dora Fučkar Čupić¹, Eleonora Cini Tešar², Koviljka Matušan Ilijaš¹, Johan Nemrava¹, Marinko Kovačević¹ and Elvira Mustać¹

¹ Department of Pathology, School of Medicine, University of Rijeka, Rijeka, Croatia

² Department of Radiation Oncology, Rijeka University Hospital Center, Rijeka, Croatia

ABSTRACT

The matrix metalloproteinases (MMPs) comprise a family of zinc-dependent endopeptidases that are secreted as inactive precursors, which are activated by cleavage of an N-terminal pro-peptide. Their basic mechanisms of action include cancer cell growth, differentiation, apoptosis, migration and invasion, and the regulation of tumour angiogenesis and immune surveillance. The expression of MMP2 and MMP9 has been associated with high potential of metastasis in several human carcinomas including breast cancer. The 29 female patients, 9 premenopausal and 20 postmenopausal, aged from 37 to 79 years were included in this study. Tissue samples were examined in 29 primary and 48 recurrent carcinomas using the tissue microarrays which included 102 cores of primary breast carcinomas and 96 of recurrent breast carcinomas. Immunohistochemistry determined a pattern of expression for MMP9. The staining was diffuse cytoplasmic, strong, moderate, faint/weak and negative. The majority of the breast carcinomas stained homogeneously for MMP9 on tumor cells. Statistically significant correlation was found for the expression of MMP9 between primary and recurrent breast carcinomas in general ($p < 0.001$) and in tumors that were grouped as recurrence before ($p = 0.039$) and after 24 months ($p < 0.001$). Strong expression of MMP9 was observed in primary tumors that recurred after 24 months, median: 162.5 (score range 0–300) and those tumors that recurred before 24 months of the initial diagnosis, median: 102.5 (score range 0–250) ($p = 0.026$).

Key words: breast carcinoma, MMP9, primary, recurrent

Introduction

The matrix metalloproteinases (MMPs) comprise a family of zinc-dependent endopeptidases that consist of more than 21 human MMPs and numerous homologues from other species. MMPs are multidomain proteins and are secreted as inactive precursors, which are activated by cleavage of an N-terminal pro-peptide. Their basic mechanism of action is degradation of proteins, regulation of various cell behaviours with relevance for cancer biology. These include cancer cell growth, differentiation, apoptosis, migration and invasion, and the regulation of tumour angiogenesis and immune surveillance¹. Among these, gelatinases comprised of gelatinase A (MMP-2) and gelatinase B (MMP-9), are associated with the malignant phenotype of tumor cells, because of their unique ability to degrade the type-IV collagen, a major component of the basement membrane. The gelatinases are secreted as zymogens and cleave to the active form and

their function is tightly regulated by several different mechanisms². Many investigators have reported the clinical significance of MMP2 and MMP9 in breast cancer^{3,4}.

The objective of the current project is to investigate the expression patterns of the MMP9 staining in primary breast carcinomas and developed local recurrence of the disease with possible influence on tumor invasion and survival.

Patients and Methods

Study population

The study included women with breast cancers which developed local recurrence of the disease. Breast cancer tissue, primary mass and tissue from the local recurrence were obtained from the archival tissue samples at the

Department of Pathology, Rijeka University School of Medicine.

The 29 female patients, 9 premenopausal and 20 postmenopausal, aged from 37 to 79 years were included in this study. Criteria for inclusion were: histopathological diagnosis, availability of paraffin-embedded tissue specimens and clinical data confirming local recurrence of cancer disease. All patients included were diagnosed from 1995 to 2007. Tissue samples were examined by two independent pathologists (D.F.Č. and E.M.) to confirm the presence of malignant tissue, in both material, 29 primary and 48 recurrent carcinomas and to validate histopathologically primary carcinomas using the classification of breast tumors according to the WHO⁵. The tissue microarrays were constructed and they contained replicate 1-mm cores of tumor tissue, 102 cores of primary breast carcinomas and 96 of recurrent breast carcinomas.

Immunohistochemistry

For immunohistochemistry, tissue microarray slides were deparaffinised and rehydrated in graded alcohols. Epitope retrieval was carried out depending on the antibody we used. The slides were then incubated with primary antibody provided with the Kit, in a DAKO TechMate Horizon automated immunostainer (LJL Biosystems Inc, Sunnyvale, USA), 3,3 diamino-benzidine was used as the chromogen. Substitution of the primary antibody with an isotype matched IgG and omission of the primary antibody served as negative control.

MMP9

The samples were stained by primary antibody for MMP9, which was a mouse monoclonal antibody toward a human proform of MMP9 (clone 15W2; NCL-MMP9-439; Novocastra, Newcastle, UK). Producer's recommended dilutions 1:10–1:80 and 60 minutes primary antibody incubation at 25 °C resulted in strong cytoplasmic coloration of cells with invisible nucleus, accompanied with dark brown background, therefore the procedure was modified: working dilution was of 1:400 with overnight pretreatment. As positive control we used strongly staining normal liver tissue sections. MMP9 antibody is raised against a 134 amino acid portion of the C-terminal region of the mature human MMP9 molecule.

ER (estrogen receptors) and PR (progesterone receptors)

The samples were stained by anti receptor antibody; monoclonal mouse antibody, anti human estrogen receptor (clone 1D5, isotype IgG1-kappa, DakoCytomation, Glostrup, Denmark) (dilution 1:50) and monoclonal mouse antibody, anti human progesterone receptor (clone PgR 636, isotype IgG1-kappa, DakoCytomation, Glostrup, Denmark) (dilution 1:50). Previously identified strongly staining tumor tissue sections served as positive controls.

Ki67 proliferation index

Staining was obtained by monoclonal mouse antibody, anti Ki67 (MIB-1, 1:75; DakoCytomation, Glostrup, Denmark). Positive staining of chromatin in dividing cells served as internal positive control.

HER2 receptors

HER2 immunostaining was performed using HercepTest (DakoCytomation, Glostrup, Denmark).

Immunohistochemical scoring

ER and PR were evaluated by the Allred score method^{6,7}. For HER2 staining was used a scoring system according to SCO/CAP 2007 guidelines⁸. Expression of MMP9 was cytoplasmic on tumor cells. The staining results were quantified by calculation of a complete H-score that considers both staining intensity and the percentage of cells stained at a specific range of intensities. A complete H-score was calculated by summing the products of the percentage cells stained at a given staining intensity (0–100) and the staining intensity (0–3). For example: a specimen with 10% of cells staining 3+, 30% of cells staining 2+, 20% of cells staining 1+, and 40% of cells unstained would have a complete H-score of $(3 \times 10) + (2 \times 30) + (1 \times 20) = 110^9$.

Statistical analysis

Various methods of descriptive and analytic biomedical statistics were used: Spearman correlation test, Chi-square test, Mann-Whitney U-test. Mann-Whitney U-test was used for comparison of relative MMP9 expression between the two different groups. Spearman correlation test was applied to evaluate the statistical significance between the two values.

Statistical differences with p value < 0.05 were considered significant. The data were analyzed by SPSS PACKAGE Release 7.0 for PC (SPSS Inc, Chicago, USA).

Results

Immunohistochemistry determined a pattern of expression for MMP9. The staining was stromal and diffuse cytoplasmic, strong, moderate, faint/weak and negative (Figure 1). The majority of the breast carcinomas stained homogeneously for MMP9 on tumor cells. Expression of MMP9 was found in 96 out of 102 cores of primary breast carcinomas (94.1 %) and in 81 out of 96 cores of recurrent breast carcinomas (84.4 %) without any significant correlation to clinical stage. Statistically significant correlation was found for the expression of MMP9 between primary and recurrent breast carcinomas in general ($p < 0.001$) (Figure 2) and in tumors that were grouped as recurrence before ($p = 0.039$) and after 24 months ($p < 0.001$) (Table 1). Strong expression of MMP9 was observed in primary tumors that recurred after 24 months, median: 162.5 (score range 0–300) and those tumors that recurred before 24 months of the initial diagnosis, median: 102.5 (score range 0–250) ($p = 0.026$) (Figure 3).

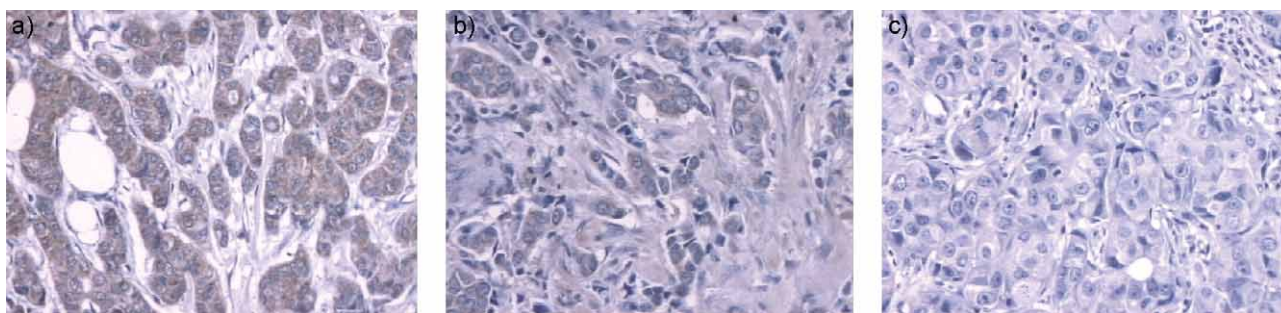


Fig. 1. Pattern and intensity of MMP9 immunostaining. a) strong cytoplasmic; b) moderate cytoplasmic and stromal; c) negative.

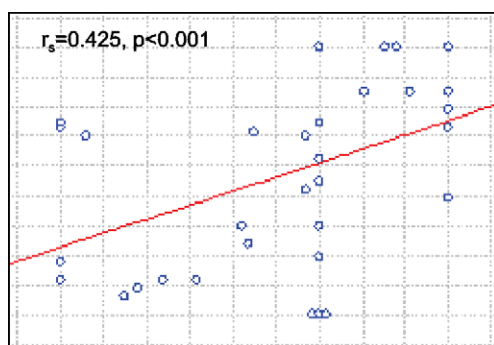


Fig. 2. Correlation between relative expression of MMP9 in primary and recurrent breast carcinomas.

Higher expression of MMP9 was found in recurrent tumors, after 24 months, median: 200.0 (score range 0–300) and those tumors that recurred before 24 months of the initial diagnosis, median: 110.0 (score range 0–250) ($p=0.003$) (Figure 4). Among data that were not shown inverse correlation was found for ER ($p=0.005$) with primary carcinomas which developed recurrence after 24 months and secondary tumor mass. Statistically significant correlation was not found for PR ($p=0.880$), HER2 receptors ($p=0.129$) and Ki67 proliferation marker ($p=0.349$).

Discussion and Conclusion

The expression of MMP2 and MMP9 has been associated with high potential of metastasis in several human carcinomas including breast cancer¹⁰. Controversial data exists concerning the prognostic value of MMP9 in breast carcinoma¹¹. In this study high expression of MMP9 in primary breast carcinoma cells was associated with the local relapse of the disease, mostly after 24 months after the initial diagnosis. Scorilas et al. reported that reduced MMP-9 expression in breast carcinoma cells was associated with poor prognostic factors such as large tumor

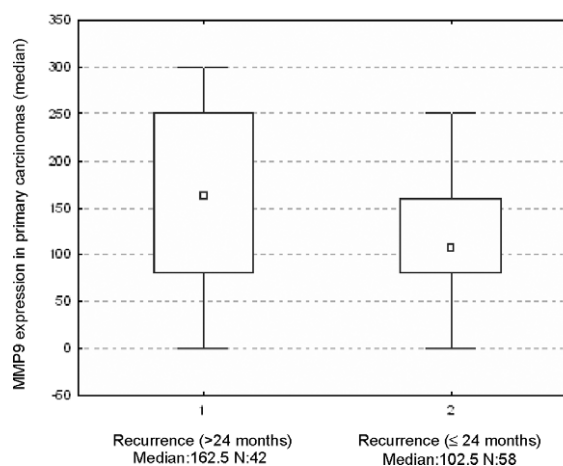


Fig. 3. Comparison between expression of MMP9 in primary carcinomas which developed local recurrence before 24 months and after 24 months (Mann-Whitney U-test): $p=0.026$.

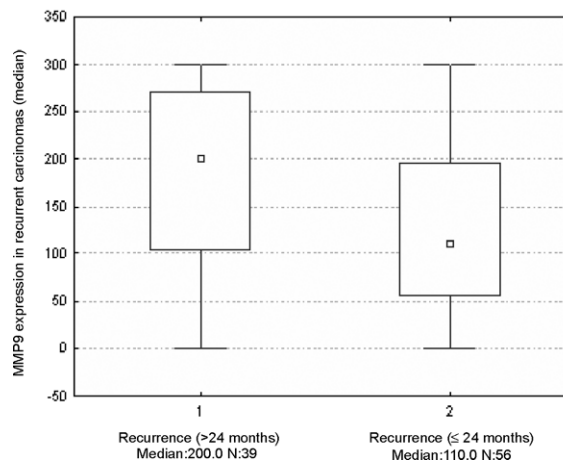


Fig. 4. Comparison between expression of MMP9 in recurrent carcinomas which developed tumor mass before 24 months and after 24 months (Mann-Whitney U-test): $p=0.003$.

TABLE 1
CORRELATION BETWEEN RELATIVE EXPRESSION OF MMP9 IN PRIMARY AND RECURRENT BREAST CARCINOMAS
(Spearman correlation)

	Recurrence (all)	Recurrence (≤ 24 months)	Recurrence (>24 months)
MMP9	$r_s=0.425, p<0.001$	$r_s= 0.282, p=0.039$	$r_s=0.565, p<0.001$

size and poor survival for N-patients¹². In our study a third of the primary carcinomas were smaller than 2 cm, a second third bigger than 2 cm and the remaining third were T4 carcinomas (infiltrated and exulcerated skin of the breast). In the present study, positive MMP9 expression was related to negative ER in the recurrent carcinomas which developed within 24 months after the diagnosis of the breast carcinoma was established. A possible explanation is that positive MMP9 expression may represent an increase in the active enzyme form that could lead to metastatic process and increased malignancy, for example, via enhanced angiogenic activity¹³. MMP9 expression, in addition, may be affected by hormones stimulating cell growth and invasiveness via acceleration of the expression of MMPs including MMP9¹⁴. McGowan et al found that MMP-1, -9, -12, -14 and -15, were significantly associated with poor outcome. All these MMPs,

apart from MMP9, were also associated with outcome in the systemically untreated patients, suggesting that these are pure prognostic factors for breast cancer¹⁵.

In conclusion, our analysis of a published database showed that the overexpression of MMP9 on tumor cells of the primary and recurrent breast carcinomas are predictors of poor outcome for the breast cancer patients and finally evaluation of the MMP9 expression may add information of the behaviour of the cancer with probably local metastatic potential.

Acknowledgment

This work was supported by the Ministry of Science, Education and Sports of the Republic of Croatia (grant No. 062-0620095-0077).

REFERENCES

1. EGEBLAD M, WERB Z, *Nat Rev Cancer*, 2 (2002) 161. — 2. STRENLICHT MD, WERB Z, *Annu Rev Cell Dev Biol*, 17 (2001) 463. — 3. TALVENSAARI-MATTILA A, PAAKKO P, HOYHTYA M, BLANCO-SEQUEIROS G, TURPEENIEMI-HUJANEN T, *Cancer*, 83 (1998) 1153. — 4. LIU SC, YANG SF, YEH KT, YEH CM, CHIOU HL, LEE CY, *Clin Chim Acta*, (2006) 371. — 5. TAVASSOLI FA, DEVILLEE P, *World Health Organisation Classification of Tumours. Tumours of the Breast and Female Genital Organs* (IARC Press, Lyon, 2003). — 6. HARVEY JM, CLARK GM, OSBORNE CK, *J Clin Oncol*, 17 (1999) 1474. — 7. ALLRED DC, HARVEY JM, BERARDO M, CLARK GM, *Mod Pathol*, 11(1998) 155.

— 8. WOLFF AC, HAMMOND ME, SCHWARTZ JN, *J Clin Oncol*, 25 (2007)118. — 9. CREGGER M, BERGER AJ, RIMM LD, *Arch Pathol Lab Med*, 130 (2006) 1026. — 10. LI HC, CAO DC, LIU Y, *Breast Cancer Res Treat*, 88 (2004) 75. — 11. RAHKO E, JUKKOLA A, MELKKO J, *Anticancer Res*, 24 (2004) 4247. — 12. SCORILAS A, KARAMERIS A, ARNOGIANNAKI N, *Br J Cancer*, 84 (2001) 1488. — 13. BELOTTI D, PAGANONI P, MANENTI L, *Cancer Res*, 63 (2003) 5224. — 14. MIZUMOTO H, SAITO T, ASHIHARA K, *Int J Cancer*, 100 (2002) 401. — 15. MCGOWAN PM, DUFFY MJ, *Ann Oncol*, 19 (2008) 1566.

D. Fučkar Čupić

Department of Pathology, School of Medicine, University of Rijeka, Braće Branchetta 20, 51000 Rijeka, Croatia
e-mail: dorica9@gmail.com

EKSPRESIJA MATRIKSNE METALOPROTEINAZE 9 U PRIMARNIM I RECIDIVIRAJUĆIM KARCINOMIMA DOJKE

SAŽETAK

Matriksne metaloproteinaze (MMP) su obitelj endopeptidaza ovisnih o cinku, koje se izlučuju u obliku inaktivnih prekursora, a oni se aktiviraju cijepanjem N-terminalnog propeptida. Matriksne metaloproteinaze su uključene u rast tumorskih stanica, diferencijaciju, apoptozu, migraciju i invaziju, kao i regulaciju tumorske angiogeneze i imuni nadzor. Ekspresija MMP2 i MMP9 vezana je uz izraženi metastatski potencijal nekolicine karcinoma u ljudi, uključujući i karcinom dojke. Dvadeset i devet bolesnica, od kojih 9 u premenopauzi i 20 u postmenopauzi, starosti od 37 do 79 godina, bile su uključene u ovo istraživanje. Ispitani su tkivni uzorci 29 primarnih i 48 recidivirajućih karcinoma koristeći tkivne mikroareje, a to je uključilo 102 uzorka primarnih i 96 recidivirajućih karcinoma dojke. Način ekspresije MMP9 u tumorskim stanicama određen je imunohistokemijski. Bojenje je bilo difuzno citoplazmatsko, a jačina ekspresije označena kao jaka, umjerena i slaba ili negativna. Većina karcinoma dojke ekspresirala je homogeni način obojenja citoplazme tumorskih stanica na MMP9. Statistički značajna korelacija za ekspresiju MMP9 nađena je između primarnih i rekurentnih karcinoma dojke općenito ($p < 0.001$) i u tumorima grupiranim kao recidivni tumori prije ($p = 0.039$) i nakon 24 mjeseca ($p < 0.001$). Jaka ekspresija MMP9 nađena je u primarnim tumorima koji su recidivirali nakon 24 mjeseca, median: 162.5 (raspon 0–300) i u onim tumorima koji su recidivirali prije 24 mjeseca od prve postavljene dijagnoze, median: 102.5 (raspon 0–250) ($p = 0.026$).