

# Management of Post-LASIK Ectasia

---

**Bohač, Maja; Biščević, Alma; Pjano, Melisa; Jagić, Mateja; Gabrić, Doria; Lukačević, Selma; Mravičić, Ivana**

Source / Izvornik: **Materia Socio Medica, 2023, 35, 73 - 78**

**Journal article, Published version**

**Rad u časopisu, Objavljena verzija rada (izdavačev PDF)**

<https://doi.org/10.5455/msm.2023.35.73-78>

Permanent link / Trajna poveznica: <https://um.nsk.hr/um:nbn:hr:184:554372>

Rights / Prava: [Attribution-NonCommercial-NoDerivatives 4.0 International/Imenovanje-Nekomercijalno-Bez prerada 4.0 međunarodna](#)

Download date / Datum preuzimanja: **2025-01-04**



Repository / Repozitorij:

[Repository of the University of Rijeka, Faculty of Medicine - FMRI Repository](#)



DOI: 10.5455/msm.2023.35.73-78

Received: Feb 14 2023; Accepted: Mar 11, 2023

© 2023 Maja Bohac, Alma Biscevic, Melisa Ahmedbegovic-Pjano, Mateja Jagic, Doria Gabric, Selma Lukacevic, Ivana Mravivic

This is an Open Access article distributed under the terms of the Creative Commons Attribution Non-Commercial License (<http://creativecommons.org/licenses/by-nc/4.0/>) which permits unrestricted non-commercial use, distribution, and reproduction in any medium, provided the original work is properly cited.

## CASE STUDY

Mater Sociomed. 2023 Mar; 35(1): 73-78

# Management of Post-LASIK Ectasia

Maja Bohac<sup>1</sup>, Alma Biscevic<sup>1,2</sup>, Melisa Ahmedbegovic-Pjano<sup>2</sup>, Mateja Jagic<sup>1</sup>, Doria Gabric<sup>1</sup>, Selma Lukacevic<sup>1</sup>, Ivana Mravivic<sup>1</sup>

## ABSTRACT

**Background:** Corneal ectasia is a sight-threatening complication of corneal refractive surgery characterized by progressive steepening and thinning of the cornea and subsequent loss of best-corrected visual acuity. **Objective:** To report the clinical outcomes following treatment of post-laser in situ keratomileusis (LASIK) induced ectasia. **Methods:** This is a retrospective case series of 7 patients (10 eyes) which developed post-LASIK ectasia. In these cases of postoperative ectasia, the presented clinical signs were either forme fruste keratoconus, thin cornea, posterior elevation map value > +15.0µm, or residual stromal bed < 300µm. All cases were treated with either collagen crosslinking (CXL) alone or combined with PRK or CXL and phakic intraocular implant using the Dresden protocol and a slight modification thereof. In all cases, the flap was created using the Moria M2 mechanical microkeratome (average flap thickness 118.15±12.88µm), and refractive error was corrected using the Wavelight Allegretto excimer laser. **Results:** Average preoperative corrected visual acuity (CDVA) was 0.75 (±0.26) Snellen. Postoperative CDVA significantly increased to 0.86 (±0.13) Snellen (p=0.04, paired t-test). One eye lost three lines of its baseline CDVA (before ectasia), while all other eyes regained lines of CDVA. All cases remained stable during the follow-up. **Conclusion:** Several surgical procedures are used for the management of corneal ectasia. However, the best surgical approach should be determined based on the state of progression of the disease. Although ectasia remains a potentially devastating complication after refractive surgery, most patients can regain functional visual acuity with appropriate management, and corneal transplantation is infrequently indicated.

**Keywords:** LASIK, ectasia, crosslinking, keratoconus, corneal tomography.

## 1. BACKGROUND

Corneal ectasia is a sight-threatening complication of corneal refractive surgery characterized by progressive steepening and thinning of the cornea and subsequent loss of best-corrected visual acuity (1-7). The estimated incidence of post-LASIK ectasia is between 0.04% to 0.09% (2, 8-10). Although several identifiable risk factors connected with ectasia have been reported (2, 5-7, 11-13), and guidelines established to prevent ectasia, the problem can still occur even in patients free from any of the well-known risks

There are various options for the treatment of post-LASIK ectasia. Corneal-collagen cross-linking (CXL) is a preferred procedure whose primary goal is to halt the condition's progression (14-17). The 'Dresden protocol' was established as a valuable procedure for the efficient clinical delivery of CXL. Nowadays, it can be combined with photorefractive keratectomy (PRK) (16-18) or intracorneal ring segments (19-22) to modulate and stabilize the cornea and improve visual acuity. Other options include contact lenses (23, 24) and lamellar keratoplasty (25).

## 2. OBJECTIVE

The aim of this paper was to investigate the clinical responses of a small series of post-LASIK ectasia cases treated with either CXL alone or CXL combined with PRK or CXL and phakic intraocular implant using the Dresden protocol and a slight modification thereof.

## 3. METHODS

This is a retrospective case series of 7 patients (10 eyes) which developed post-LASIK ectasia. In these cases of postoperative ectasia, the presented clinical signs were either forme fruste keratoconus, thin cornea, posterior elevation map value > +15.0µm, or

<sup>1</sup>University Eye Hospital Sijetlost, School of Medicine University of Rijeka, Zagreb, Croatia

<sup>2</sup>Eye Clinic Sijetlost, Sarajevo, Bosnia and Herzegovina

### Corresponding author:

Alma Biscevic, MD, PhD, Eye Clinic Sijetlost Sarajevo, Bosnia and Herzegovina. E-mail: [alma@svjetlost-sarajevo.ba](mailto:alma@svjetlost-sarajevo.ba). ORCID ID: <https://orcid.org/0000-0002-6496-2853>.

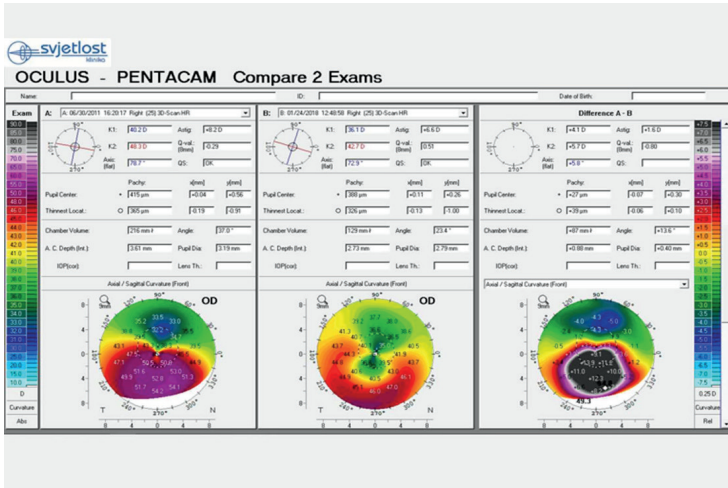


Figure 1. Difference map of the right eye from Case 1 six years after CXL

residual stromal bed < 300µm. All cases were treated with either collagen cross-linking (CXL) alone or combined with PRK or CXL and phakic intraocular implant using the Dresden protocol and a slight modification thereof. In all cases, the flap was created using the Moria M2 mechanical microkeratome (average flap thickness 118.15±12.88µm), and refractive error was corrected using the Wavelight Allegretto excimer laser.

#### 4. CASE REVIEW AND MANAGEMENT OF THE 10 EYES WITH ECTASIA

The main results from the patient charts are shown in Table 1. Here follow a case-by-case description and management of each patient.

##### CASE 1 (Eye 1)

A 31-year-old male underwent bilateral LASIK in November 2008 for moderate myopic astigmatism. One year

after LASIK, he complained of decreased visual acuity in his right eye with uncorrected distance Snellen visual acuity (UDVA) of 0.3 in the right and 0.8 in the left eye. Corrected distance Snellen visual acuity (CDVA) was 0.5 with +1.00DS/-4.00DCx70 in the right eye, and the residual refractive error in the left eye was negligible.

Corneal tomography revealed inferior corneal ectasia in his right eye with steepening of 2.2D and maximal keratometry reading (Kmax) of 54.8D. In his left eye, the suspicious elevation of the posterior elevation map was noted with a Kmax of 43.6D. The patient was treated with collagen crosslinking (CXL) in his right eye. Standard Dresden protocol<sup>26</sup> was used with 30 min riboflavin with Dextran (Ricrolin™, Sooft Italia, Montegiorgio, Italy) soak followed by 3mW/

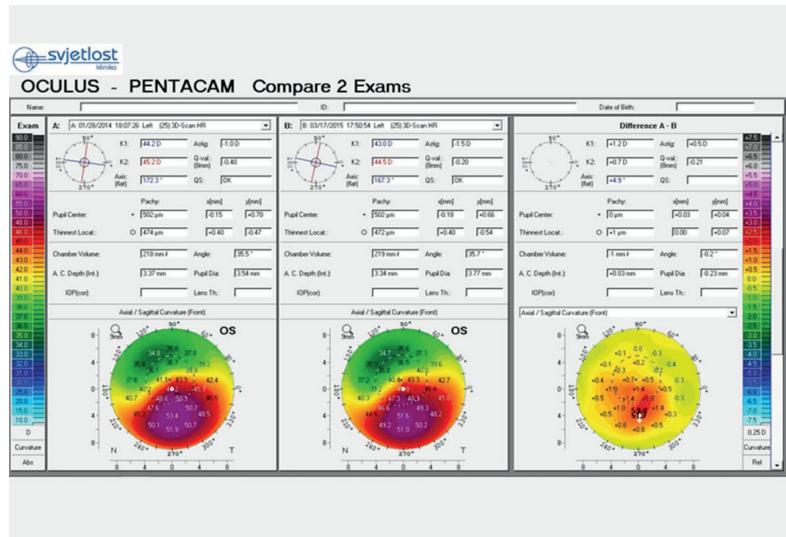


Figure 2. Difference map of the left eye from Case 5 one year after CXL

cm<sup>2</sup> irradiation for 30 minutes (Vega™, CSO–Costruzione Strumenti Oftalmici, Florence, Italy) (Figure 1).

Two years later, the patient was implanted with a toric implantable Collamer Lens (Visian ICL™, Staar Surgical AG, Nidau, Switzerland) with complete restoration of visual acuity. Seven years after CXL, Kmax in the right eye is 49.3D. His left eye is now showing suspicious signs of instability without any progressive deterioration of visual acuity or increase in Kmax.

The postoperative retrospective chart review revealed, for both eyes, anterior sagittal map irregularity and posterior map elevation (PME) of +24.0µm for the right eye and +8.0µm for the left eye. Family history was negative for keratoconus, and otherwise, the patient was healthy.

##### CASE 2 (Eye 2)

A 23-year-old male underwent LASIK treatment for high myopia in his left eye and Verisyse™ phakic IOL (Abbott Medical Optics Inc, Santa Ana, California, USA)

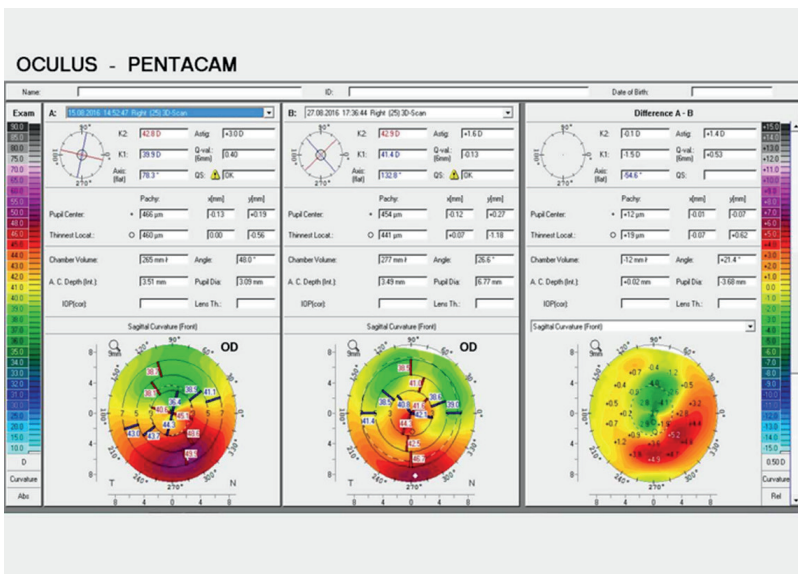


Figure 3. Difference map of the right eye from Case 6 two weeks after corneal wavefront-guided PRK and CXL

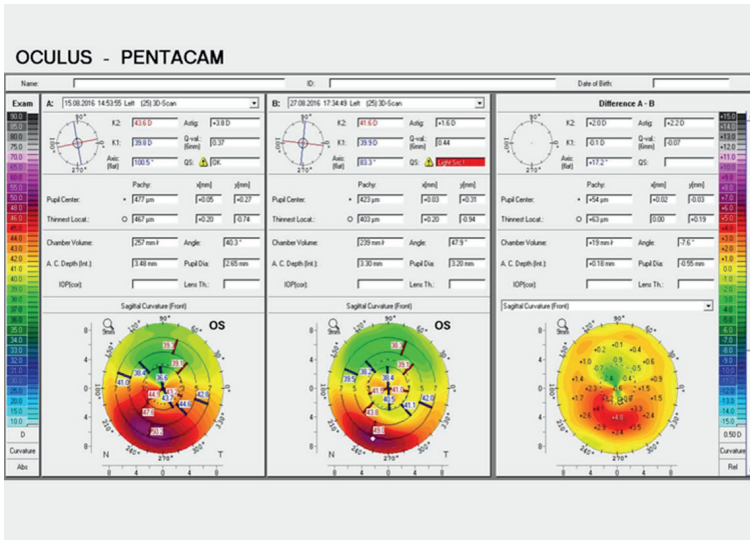


Figure 4. Difference map of the left eye from Case 6 two weeks after corneal wavefront-guided PRK and CXL

implantation in his right eye in April 2008. Three years after LASIK, he complained of decreased visual acution his left eye with UDVA of 0.3 in the left and 0.6 in the right. CDVA was 0.7 with +1.00DS/-4.00DCx110 in the left eye and 0.9 with pl/-1.50DCx 90 in the right eye. Corneal tomography revealed inferior corneal ectasia in his left eye with a Kmax of 62.1D and normal corneal tomography in his right eye with a Kmax of 44.3D. The patient was treated with standard Dresden protocol<sup>26</sup> CXL (Ricola™, Sooft Italia, Montegiorgio, Italy, Vega™, CSO–Costruzione Strumenti Oftalmici, Florence, Italy) in his left eye and wears spectacles. During the follow-up, Kmax decreased to 57.8D in his left eye while his right eye remained stable.

The postoperative retrospective chart review revealed no corneal irregularities except the corneal thickness of 496µm at the thinnest point and relatively deep myopic ablation of -8.0D (112µm ablation). The family history was negative for keratoconus, but the patient developed severe allergies 18 months before ectasia was detected. He acquired a pollen allergy and was treated with systemic mast cell stabilizers. However, he felt his allergy only slightly improved after therapy.

**CASE 3 (Eyes 3 and 4)**

A 42-year-old male underwent bilateral LASIK in February 2012 for mixed astigmatism in his right eye and myopic astigmatism in his left eye. Eight months after LASIK, he complained of decreased visual acuity in his right eye with a UDVA of 0.03 in the right and 1.0 in the left eye. CDVA was 0.1 with pl/-4.00DCx 80 in the right eye and plano in the left eye. Corneal tomography revealed inferior corneal ectasia in his right eye with Kmax readings of 49.4D. In his left eye, the suspicious

elevation of the posterior elevation map was noted with Kmax readings of 44.8D. The patient was treated with corneal wavefront-guided trans-PRK (Schwind Amaris 750S™, Schwind Eye-Tech-Solutions, Kleinostheim, Germany) with CXL (Dresden protocol<sup>26</sup>-Ricola™, Sooft Italia, Montegiorgio, Italy, Vega™, CSO–Costruzione Strumenti Oftalmici, Florence, Italy) at the same session. Ten months later, he complained of blurred vision in his left eye with a UDVA of 0.6 in the left and 0.5 in the right. Corrected distance visual acuity was 1.0 with pl/-1.50DCx70 in the left eye and plano in the right eye. Corneal tomography revealed inferior corneal ectasia in his left eye and increased Kmax readings to 48.6D. The patient was treated with corneal wavefront-guided trans-PRK (Schwind Amaris 750S™, Schwind Eye-Tech-Solutions, Kleinostheim,

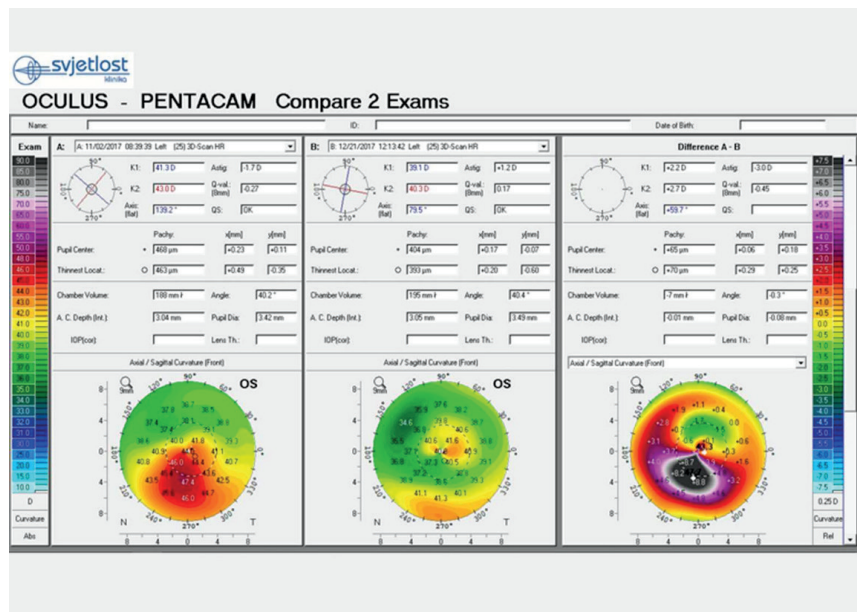


Figure 5. Difference map of the left eye from Case 7 two months after corneal wavefront-guided PRK and CXL

Germany) with CXL (Dresden protocol<sup>26</sup>-Ricola™, Sooft Italia, Montegiorgio, Italy, Vega™, CSO–Costruzione Strumenti Oftalmici, Florence, Italy) at the same session for his left eye also. Three years after trans-PRK +CXL, his right eye was experiencing a hyperopic shift while his left eye was stable. The final CDVA in his right eye was 0.7 with +3.00DS/-1.50DCx110, and in his left eye, 1.0 with -0.50DS/-0.50DCx80. His Kmax readings are still decreasing; on the last follow-up visit were 46.0D in the right eye and 45.3D in the left eye.

The postoperative retrospective chart review revealed normal anterior sagittal maps. Posterior elevation in his right eye was +22.0µm, and in the left eye was +9.0µm. Family history was negative for keratoconus, and otherwise, the patient was healthy.

**CASE 4 (Eye 5)**

A 24-year-old female underwent bilateral LASIK in September 2008 for moderate myopic astigmatism. Five

years after LASIK, she complained of decreased visual acuity in her left eye with a UDVA of 0.6 in the left and 1.0 in the right eye. CDVA was 1.0 with +0.25DS/-0.75DCx110 in the left eye and plano in the right eye. Corneal tomography revealed inferior corneal ectasia in her left eye with a Kmax of 48.4D and normal tomography in her right eye with a Kmax of 45.8D. The patient was treated with CXL (Dresden protocol<sup>26</sup>-Ricrolin™, Sooft Italia, Montegiorgio, Italy, Vega™, CSO—Costruzione Strumenti Oftalmici, Florence, Italy) in her left eye. During the follow-up, Kmax decreased to 47.2D in her left eye and remained stable. Her right eye showed signs of instability without progression or affection of visual acuity with stable Kmax readings.

The postoperative retrospective chart review revealed asymmetric bow tie on the anterior sagittal maps of both eyes with inferior/superior steepening of 1.6D in her right eye and 1.2 in her left eye with normal posterior elevation maps. Family history was negative for keratoconus, and otherwise, the patient was healthy.

#### CASE 5 (Eye 6)

A 38-year-old male underwent bilateral LASIK in September 2008 for low myopia. Six years after LASIK, he complained of decreased visual acuity in his left eye with a UDVA of 0.3 in the left and 1.0 in the right eye. CDVA was 0.8 with -0.75DS/-4.00DCx115 in the left eye and plano in the right eye. Corneal tomography revealed inferior corneal ectasia in his left eye with a Kmax of 53.4D. In his right eye, the suspicious elevation of the posterior elevation map was noted with a Kmax of 42.2D. The patient was treated with CXL (Dresden protocol<sup>26</sup>-Ricrolin™, Sooft Italia, Montegiorgio, Italy, Vega™, CSO—Costruzione Strumenti Oftalmici, Florence, Italy) in his left eye. During the follow-up, Kmax decreased to 51.7D in his left eye and remained stable (Figure 2). His right eye showed signs of instability without progression or affection of visual acuity with stable Kmax readings.

The postoperative retrospective chart review revealed an asymmetric bow tie on the anterior sagittal map in both eyes with inferior/superior steepening of 0.9D in his right eye and 1.2 in his left eye with suspicious PME of +29.0μm in his right and normal posterior elevation in his left eye. Family history was negative for keratoconus, and otherwise, the patient was healthy.

#### CASE 6 (Eyes 7 and 8)

A 24-year-old male underwent bilateral LASIK in June 2011 for low myopic astigmatism. Five years after LASIK, he complained of decreased visual acuity in both eyes, with a UDVA of 0.5 in the right and 0.6 in the left eye. CDVA was 0.8 with -1.50DCx80 in the right eye and -2.50DCx100 in the left eye. Corneal tomography revealed inferior corneal ectasia in both his eyes with a Kmax of 49.9D in the right eye and 50.4D in the left eye. The patient was treated with ocular wavefront-guided trans-PRK (Schwind Amaris 750S™, Schwind Eye-Tech-Solutions, Kleinostheim, Germany) with CXL (Dresden protocol<sup>26</sup>-Ricrolin™, Sooft Italia, Montegiorgio, Italy, Vega™, CSO—Costruzione Strumenti Oftalmici, Florence, Italy) in the same session first his right eye and seven days later his left eye. Three months after trans-PRK

and CXL, his CDVA was 1.0 in both eyes, with -0.50DS in his left eye and -0.50 DCx100 in his left eye. Kmax readings decreased to 47.9D in the right eye and 48.5D in the left eye and remained stable during the follow-up (Figures 3 and 4).

The postoperative retrospective chart review revealed normal anterior sagittal and posterior elevation maps. The only exception was the thin cornea (487/483μm), but the correction was -2.25DS-0.75DCx60 and -2.25Ds/-0.75DCx160. Family history was negative for keratoconus. However, the patient developed severe allergies, for which he did not seek treatment for two years after LASIK.

#### CASE 7 (Eyes 9 and 10)

A 20-year-old female underwent bilateral LASIK in December 2011. Her right eye was slightly amblyopic (CDVA 0.8) and had mixed astigmatism with high cylinder, while her left eye had only low myopia. Six years after LASIK, she complained of decreased visual acuity in both eyes with UDVA of 0.4 in the right and 0.6 in the left eye. CDVA was 0.8 with -2.25DCx60 in the right eye and -2.25DCx120 in the left eye. Corneal tomography revealed inferior corneal steepening at the anterior surface and increased elevation at the posterior surface in both eyes. Kmax in the right eye was 45.7D, and in the left eye, 47.7D. The patient was treated with corneal wavefront-guided trans-PRK (Schwind Amaris 750S™, Schwind Eye-Tech-Solutions, Kleinostheim, Germany) with CXL at the same session first for her left eye and one month later, her right eye. For this patient, riboflavin with hydroxyethyl methylcellulose (Peschke®M, Peschke Trade, Huenenberg, Switzerland) was used, and the patient was irradiated for 10 minutes with 9mW/cm<sup>2</sup> (CCL-365-Vario™, MLase Ag, Germering, Germany). Two months after trans PRK and CXL, her UDVA was 0.7 in both eyes, and refraction did not reveal any correction. Kmax decreased in both eyes at 42.6D in the right eye and 43.3D in the left eye (Figure 5).

The postoperative retrospective chart review revealed normal anterior sagittal and posterior elevation maps and a relatively thin cornea (500/496μm). Family history was negative for keratoconus. However, the patient reported mild allergies, for which she did not seek any treatment, with ocular involvement.

## 5. DISCUSSION

Corneal ectasia is a rare complication of laser in situ keratomileusis (LASIK) that can have a devastating effect on visual function (1-7). Recent studies identify preoperative risk factors for corneal ectasia, including abnormal corneal topography, low residual stromal bed thickness, relatively young patient age, low preoperative corneal thickness, percent tissue altered  $\geq 0.4$ , and additional topographic screening strategies have been proposed (2, 5-7, 11-13). Therefore, improved patient screening should significantly reduce the incidence of postoperative ectasia. However, when ectasia develops, it must be addressed to improve the patient's visual function.

Contact lenses are frequently required to achieve good functional vision. Still, they do not halt the progression

of the disease, and ectatic progression can lead to intolerance of contact lenses (23, 24, 27, 28).

CXL is an in vivo intrastromal photo-oxidative technique achieved with riboflavin and ultraviolet-A aiming to address the advancing corneal ectasia or keratoconus progression. CXL can achieve additional covalent bonding between stromal collagen, stabilizing the collagen framework structure (26, 29-31). For our first cases that presented with reasonably good corrected distance visual acuity, we used the standard Dresden protocol (26) with stable long-term results. All patients were corrected with spectacles after surgery. One patient wanted to be a spectacle and contact lens free and was implanted with a toric ICL after corneal parameters became stabilized. Phakic intraocular lenses are viable options for correcting ectasia/keratoconus patients with good corrected visual acuity (32, 33).

Topography (TG) and wavefront-guided (WG) treatments were initially designed to correct corneal irregularities, or, in the case of WG ablations, whole eye high-order aberrations and improve the quality of vision (16-18, 34-36). Although their effects on corneal regularity and improvement in the quality of vision are well recognized, they still pose a challenge regarding refractive predictability. With the advent of CXL, which increases the biomechanical strength of the cornea, TG or WG PRK with simultaneous or sequential CXL has gained widespread acceptance (16-18, 34-36). In our study, we used simultaneous TG PRK with CXL. Initially, we used the standard Dresden protocol (26), then switched to 9mw irradiation after reviewing reports of good stability with accelerated protocols (37, 38). One of the limitations when using this technique is that the unpredictable flattening effect of CXL may lead to an unexpected hyperopic shift. We encountered such a hyperopic overcorrection in one patient (1 eye). Similar results were reported by Lin et al. (34) where 8 out of 75 eyes developed a hyperopic shift of up to +2.00D after treatment with simultaneous topography-guided PRK and CXL at the same session.

Several surgical procedures are being used for the management of corneal ectasia. The best surgical approach should be reached based on the state of progression of the disease. Although ectasia remains a potentially devastating complication after refractive surgery, most patients can regain functional visual acuity with the appropriate management, and corneal transplantation is infrequently indicated (26). However, when required, the results are similar to those achieved in keratoconus patients.

It would be helpful to have a multicenter prospective longitudinal study with longer follow-ups to detect more ectasia cases and better estimate the actual incidence of post-LASIK ectasia and the safety and efficacy of the currently proposed treatments.

## 6. CONCLUSION

Several surgical procedures are used for the management of corneal ectasia. However, the best surgical approach should be determined based on the state of progression of the disease. Although ectasia remains

a potentially devastating complication after refractive surgery, most patients can regain functional visual acuity with appropriate management, and corneal transplantation is infrequently indicated.

- **Author's contribution:** All authors were involved in all steps of preparation this article. Final proofreading was made by the first author.
- **Conflict of interest:** None declared.
- **Financial support and sponsorship:** Nil.

## REFERENCES

1. Seiler T, Koufala K, Richter G. Iatrogenic keratectasia after laser in situ keratomileusis. *J Refract Surg.* 1998; 14(3): 312-317.
2. Santhiago MR, Giacomini N, Smadja D, Bechara SJ. Ectasia risk factors in refractive surgery. *Clin Ophthalmol.* 2016 Apr 20; 10: 713-720. doi: 10.2147/OPHTH.S51313.
3. Ikeda T, Shimizu K, Igarashi A, Kasahara S, Kamiya K. Twelve-Year Follow-Up of Laser in situ Keratomileusis for Moderate to High Myopia. *BioMED Research International.* 2017; 2017: 9391436. doi:10.1155/2017/9391436.
4. Kamiya K, Igarashi A, Hayashi K, Negishi K, Sato M, Bissen-Miyajima H; Survey Working Group of the Japanese Society of Cataract and Refractive Surgery. A Multicenter Prospective Cohort Study on Refractive Surgery in 15 011 Eyes. *Am J Ophthalmol.* 2017; 175: 159-168. doi: 10.1016/j.ajo.2016.12.009.
5. Giri P, Azar DT. Risk profiles of ectasia after keratorefractive surgery. *Curr Opin Ophthalmol.* 2017; 28(4): 337-342. doi: 10.1097/ICU.0000000000000383.
6. Randleman JB, Russel B, Ward MA, Thompson KP, Stulting RD. Risk factors and prognosis for corneal ectasia after LASIK. *Ophthalmology.* 2003; 110(2): 267-275.
7. Binder PS. Ectasia after laser in situ keratomileusis. *J Cataract Refract Surg.* 2003; 29(12): 2419-2429.
8. Randleman JB. Evaluating risk factors for ectasia: what is the goal of assessing the risk? *J Refract Surg.* 2010; 26: 236-237. doi: 10.3928/1081597X-20100318-02.
9. Moshirfar M, Smedley JG, Muthappan V, et al. Rate of ectasia and incidence of irregular topography in patients with unidentified preoperative risk factors undergoing femtosecond laser-assisted LASIK. *Clinical Ophthalmology.* 2014; 8: 35-42. doi:10.2147/OPHTH.S53370.
10. Pallikaris IG, Kymionis GD, Astyrakakis NI. Corneal ectasia induced by laser in situ keratomileusis. *J Cataract Refract Surg.* 2001; 27(11): 1796-1802.
11. Santhiago MR, Smadja D, Gomes BF, Mello GR, Monteiro ML, Wilson SE, Randleman JB. Association between the percent tissue altered and post-laser in situ keratomileusis ectasia in eyes with normal preoperative topography. *Am J Ophthalmol.* 2014; 158(1): 87-95. doi: 10.1016/j.ajo.2014.04.002.
12. Saad A, Binder PS, Gatinel D. Evaluation of the percentage tissue altered as a risk factor for developing post-laser in situ keratomileusis ectasia. *J Cataract Refract Surg.* 2017; 43(7): 946-951. doi: 10.1016/j.jcrs.2017.04.040.
13. Santhiago MR. Percent tissue altered and corneal ectasia. *Curr Opin Ophthalmol.* 2016; 27(4): 311-315. doi: 10.1097/ICU.0000000000000276.

14. Hafezi F, Kanellopoulos J, Wiltfang R, Seiler T. Corneal collagen crosslinking with riboflavin and ultraviolet A to treat induced keratectasia after laser in situ keratomileusis. *J Cataract Refract Surg.* 2007; 33(12): 2035-2040. doi: 10.1016/j.jcrs.2007.07.028.
15. Kymionis GD, Diakonis VF, Kalyvianaki M, et al. One-year follow-up of corneal confocal microscopy after corneal cross-linking in patients with post laser in situ keratomileusis ectasia and keratoconus. *Am J Ophthalmol.* 2009; 147: 774–778. doi: 10.1016/j.ajo.2008.11.017.
16. Kanellopoulos AJ, Binder PS. Management of corneal ectasia after LASIK with combined, same-day, topography-guided partial transepithelial PRK and collagen cross-linking: the Athens protocol. *J Refract Surg.* 2011; 27: 323–331. doi: 10.3928/1081597X-20101105-01.
17. Kymionis GD, Portaliou DM, Diakonis VF, et al. Management of Post Laser In Situ Keratomileusis Ectasia with Simultaneous Topography Guided Photorefractive Keratectomy and Collagen Cross-Linking. *The Open Ophthalmology Journal.* 2011; 5: 11-13. doi: 10.2174/1874364101105010011.
18. Tamayo GE, Castell C, Vargas P, Polania E, Tamayo J. High-resolution wavefront-guided surface ablation with corneal cross-linking in ectatic corneas: a pilot study. *Clin Ophthalmol.* 2017 Oct 3; 11: 1777-1783. doi: 10.2147/OPTH.S140627
19. Alio J, Salem T, Artola A, Osman A. Intracorneal rings to correct corneal ectasia after laser in situ keratomileusis. *J Cataract Refract Surg.* 2002; 28: 1568–1574.
20. Kymionis GD, Tsiklis NS, Pallikaris AI, et al. Long-term follow-up of Intacs for post-LASIK corneal ectasia. *Ophthalmology.* 2006; 113: 1909–1917.
21. Siganos CS, Kymionis GD, Astyrakakis N, Pallikaris IG. Management of corneal ectasia after laser in situ keratomileusis with INTACS. *J Refract Surg.* 2002; 18: 43–46.
22. Lam K, Rootman DB, Lichtinger, A, Rootman DS. Post-LASIK ectasia treated with intrastromal corneal ring segments and corneal crosslinking. *Digital Journal of Ophthalmology: DJO.* 2013; 19(1): 1-8. doi:10.5693/djo.02.2012.10.001.
23. Roncone DP. Toric soft contact lens fit in a postoperative LASIK keratoectasia patient with high and irregular astigmatism. *Optometry.* 2011 Dec; 82(12): 751-756. doi: 10.1016/j.optm.2011.06.011.
24. O'donnell C, Welham L, Doyle S. Contact lens management of keratectasia after laser in situ keratomileusis for myopia. *Eye Contact Lens.* 2004 Jul; 30(3): 144-146.
25. McAllum PJ, Segev F, Herzig S, Rootman DS. Deep anterior lamellar keratoplasty for post-LASIK ectasia. *Cornea.* 2007 May; 26(4): 507-511. doi:10.1097/ICO.0b013e318033b4e9.
26. Wollensak G, Spoerl E, Seiler T. Riboflavin/ultraviolet -a-induced collagen crosslinking for the treatment of keratoconus. *AM J Ophthalmol.* 2003; 135: 620-627.- Dresden protocol.
27. Woodward M, Randleman B, Russel B, Lynn MJ, Ward MA, Stulting RD. Visual rehabilitation and outcomes for ectasia after corneal refractive surgery. *J Cataract Refract Surg.* 2008; 34(3): 383-388. doi: 10.1016/j.jcrs.2007.10.025.
28. Choi HJ, Kim MK, Lee JL. Optimization of contact lens fitting in keratectasia patients after laser in situ keratomileusis for myopia. *Eye Contact Lens.* 2004; 30: 144-146. doi: 10.1016/j.jcrs.2003.10.013
29. Raiskup-Wolf F, Hoyer A, Spoerl E, Pillunat LE. Collagen crosslinking with riboflavin and ultraviolet-A light in keratoconus: long-term results. *J Cataract Refract Surg.* 2008; 34(5): 796-801. doi: 10.1016/j.jcrs.2007.12.039.
30. Wollensak G. Crosslinking treatment of progressive keratoconus: new hope. *Curr Opin Ophthalmol.* 2006 Aug; 17(4):356-360. doi: 10.1097/01.icu.0000233954.86723.25
31. Spoerl E, Huhle M, Seiler T. Induction of cross-links in corneal tissue. *Exp Eye Res.* 1988; 66(1): 97-103.
32. Hashemian SJ, Saiepoor N, Ghiasian L, et al. Long-term outcomes of posterior chamber phakic intraocular lens implantation in keratoconus. *Clin Exp Optom.* 2018 Mar 23. doi: 10.1111/cxo.12671.
33. Esteve-Taboada JJ, Domínguez-Vicent A, Ferrer-Blasco T, Alfonso JF, Montés-Micó R. Posterior chamber phakic intraocular lenses to improve visual outcomes in keratoconus patients. *J Cataract Refract Surg.* 2017; 43(1): 115-130. doi: 10.1016/j.jcrs.2016.05.010.
34. Lin DT, Holland S, Tan JC, Moloney G. Clinical results of topography-based customized ablations in highly aberrated eyes and keratoconus/ectasia with cross-linking. *J Refract Surg.* 2012; 28(11): S841-S848.
35. Kanellopoulos AJ, Binder PS. Collagen cross-linking (CCL) with sequential topography-guided PRK: a temporizing alternative for keratoconus to penetrating keratoplasty. *Cornea.* 2007; 26(7): 891-895. doi: 10.1097/ICO.0b013e318074e424.
36. Kanellopoulos AJ. Comparison of sequential vs same-day simultaneous collagen cross-linking and topography-guided PRK for treatment of keratoconus. *J Refract Surg.* 2009; 25(9): S812-S818. doi: 10.3928/1081597X-20090813-10
37. Kymionis GD, Tsoulnaras KI, Liakopoulos DA, Skatharoudi CA, Grentzelos MA, Tsakalis NG. Corneal Stromal Demarcation Line Depth Following Standard and a Modified High Intensity Corneal Cross-linking Protocol. *J Refract Surg.* 2016; 32(4):218-222. doi: 10.3928/1081597X-20160216-01.
38. Spadea L, Di Genova L, Tonti E. Corneal stromal demarcation line after 4 protocols of corneal crosslinking in keratoconus determined with anterior segment optical coherence tomography. *J Cataract Refract Surg.* 2018 Apr 20. pii: S0886-3350(18)30235-9. doi: 10.1016/j.jcrs.2018.02.017.