

Novorođenačka crijevna opstrukcija uzrokovana duodenalnom membranom: prikaz dvaju slučajeva

Dukić, Andrija; Lugonjić, Danijel; Bilić Čače, Iva; Bosak Veršić, Ana

Source / Izvornik: **Medicina Fluminensis, 2023, 59, 78 - 82**

Journal article, Published version

Rad u časopisu, Objavljena verzija rada (izdavačev PDF)

https://doi.org/10.21860/medflum2023_292452

Permanent link / Trajna poveznica: <https://urn.nsk.hr/urn:nbn:hr:184:624606>

Rights / Prava: [Attribution 4.0 International](#)/[Imenovanje 4.0 međunarodna](#)

Download date / Datum preuzimanja: **2024-05-30**



Repository / Repozitorij:

[Repository of the University of Rijeka, Faculty of Medicine - FMRI Repository](#)



Neonatal Intestinal Obstruction Caused by a Perforated Duodenal Web: A Report of Two Cases

Novorođenačka crijevna opstrukcija uzrokovana duodenalnom membranom: prikaz dvaju slučajeva

Andrija Dukić^{1*}, Danijel Lugonjić¹, Iva Bilić Čače^{1, 2}, Ana Bosak Veršić^{1, 3}

¹ University of Rijeka, Faculty of Medicine, Rijeka, Croatia

² Clinical Hospital Center Rijeka, Department of Pediatrics, Rijeka, Croatia

³ Clinical Hospital Center Rijeka, Department of Pediatric Surgery, Rijeka, Croatia

Abstract. Aim: To report the clinical courses of two patients with intestinal obstruction caused by duodenal web, who were diagnosed with this rare congenital anomaly at Clinical Hospital Center Rijeka in a span of 5 months. **Case report:** One of the patients was prenatally suspected to have duodenal obstruction due to ultrasonographic findings, while the other showed signs of obstruction by not tolerating oral intake from the second day of life (DOL). Ceasing enteral feeding, placing a nasogastric tube and introducing intravenous hydration and parenteral nutrition was performed as initial management. Abdominal ultrasonography, abdominal radiography, upper gastrointestinal contrast study and contrast enema were performed but showed no signs of obstruction. Both patients showed improvement in tolerating oral intake over the next few days. However, the first patient did not tolerate meals exceeding 15 mL of infant formula, and the second patient again did not tolerate any oral intake from the 15th day of life. A broad diagnostic workup was repeated but did not show conclusive evidence of obstruction regarding the first patient. Esophagogastroduodenoscopy found duodenal obstruction of unknown origin regarding the second patient. Laparotomy was performed on the 19th and 25th DOL, respectively. Duodenal web was visualized and excised in both patients following duodenotomy. Postoperative recovery was orderly with minor nonsurgical complications. The patients were discharged from hospital on the 21st and 36th postoperative day, respectively. **Conclusions:** Diagnosing a perforated duodenal web is often challenging because of possible intermittent nature of its symptoms. Exploratory laparotomy is sometimes required to reach diagnosis.

Keywords: congenital abnormalities; diagnostic imaging; duodenal obstruction; infant, newborn; laparotomy

Sažetak. Cilj: Prikazati klinički tijek dviju djevojčica s kongenitalnom crijevnom opstrukcijom uzrokovanom duodenalnom membranom, liječenih od ove rijetke anomalije u Kliničkom bolničkom centru Rijeka u razmaku od pet mjeseci. **Prikaz slučaja:** Kod prve je djevojčice sumnja na duodenalnu opstrukciju postavljena zbog prenatalnog ultrazvučnog nalaza, dok je kod druge sumnja na opstrukciju postavljena postnatalno jer od drugog dana života nije tolerirala oralni unos hrane. U sklopu inicijalnog zbrinjavanja u obje je djevojčice obustavljena enteralna i uvedena parenteralna prehrana, postavljena je nazogastrična sonda te uvedena parenteralna nadoknada volumena. Ultrazvuk abdomena, radiografija abdomena, pasaža crijeva i irigografija nisu pokazali znakove gastrointestinalne opstrukcije. Obje djevojčice ubrzo su počele sve bolje tolerirati enteralni unos. Međutim, prva djevojčica nije tolerirala obroke veće od 15 mL instant-formule, a druga nakon 15. dana života ponovno nije tolerirala enteralni unos hrane. Ponovljena je široka dijagnostička obrada koja u prve djevojčice nije dokazala duodenalnu opstrukciju. U druge je djevojčice ezofagogastroduodenoskopijom utvrđena duodenalna opstrukcija nepoznate etiologije. U 19., odnosno 25. danu života provedena je laparotomija. Intraoperativno, nakon duodenotomije, u oba je slučaja vizualizirana duodenalna membrana koja je potom ekscidirana. Poslijeoperacijski oporavak bio je uredan s manjim nekirurškim

*Corresponding author:

Andrija Dukić

University of Rijeka, Faculty of Medicine
Braće Branchetta 20, 51000 Rijeka, Croatia
E-mail: andrijaduk@gmail.com

<http://hrcak.srce.hr/medicina>

komplikacijama. Djevojčice su otpuštene iz bolnice 21., odnosno 36. poslijeoperacijskog dana. **Zaključci:** Postavljanje dijagnoze duodenalne membrane često je vrlo složeno zbog intermitentne prirode simptoma. Eksplorativna laparotomija katkad je nužna kako bi se postavila konačna dijagnoza.

Ključne riječi: duodenalna opstrukcija; kongenitalne abnormalnosti; laparotomija; novorođenče; slikovna dijagnostika

INTRODUCTION

Duodenal web is a rare congenital anomaly with a reported incidence of 1 in 10,000 to 40,000 newborns¹. The web is actually a membrane causing a partial or complete obstruction of the duodenal lumen. A complete duodenal web usually causes gastric distension and vomiting, typically after the first feeding. The vomiting can either be bilious or non-bilious, depending on the level of the obstruction relative to the papilla of Vater. A perforated duodenal web may present with a variety of symptoms depending on the amount of oral intake which can pass through the obstructed duodenum. Symptoms range from vomiting after every feeding to vomiting lesser amounts of food only occasionally.

Duodenal obstruction can sometimes be diagnosed prenatally if the characteristic “double bubble” sign or polyhydramnios is detected. Postnatally, the “double bubble” sign on abdominal radiography is highly suggestive of duodenal obstruction, while an air-fluid level in the duodenum is not as specific. Upper gastrointestinal contrast study may be performed in addition to confirm the diagnosis and rule out malrotation with midgut volvulus. A contrast enema can be used to further investigate the level of a potential intestinal obstruction. However, perforated webs are sometimes impossible to diagnose using prior methods and may require an esophagogastroduodenoscopy or even exploratory surgery to finally determine the nature of the obstruction.

During June-October 2020, two cases of a particular subtype of congenital duodenal stenosis were treated at Clinical Hospital Center Rijeka. The aim of this paper is to report the clinical courses of the two cases, especially highlighting the diagnostic challenges which can occur when dealing with a perforated duodenal web.

CASE SERIES

CASE 1

A premature baby girl was vaginally delivered at 34 weeks following premature rupture of the membranes. Her birth weight was 1740 g and Apgar scores were 10/10. She was transferred to the neonatal intensive care unit (NICU). During the 1st day of life (DOL), the patient was fed enterally without difficulties. However, on the 2nd

Our two cases show that vomiting due to incomplete duodenal obstruction is often intermittent, with periods of improvement and deterioration. Intermittent vomiting can cause difficulties in determining the diagnosis, especially because it can lead to nonconclusive findings when using gastrointestinal imaging methods.

DOL she started vomiting after feeding. A nasogastric tube was placed resulting in drainage of green fluid through the tube, indicative of an obstruction below the level of the papilla of Vater. Abdominal radiography showed excessive gas in the stomach, but the “double bubble” sign was absent. Upper gastrointestinal contrast study showed no signs of obstruction (Figure 1). Par-

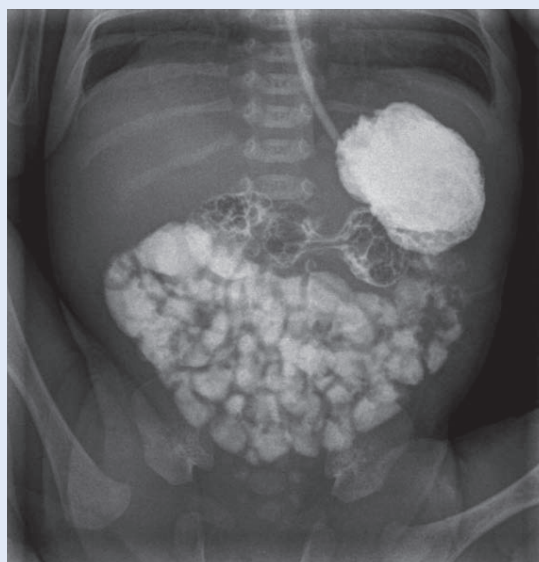

Figure 1. Anteroposterior view of abdomen during upper gastrointestinal contrast study shows the whole small intestine filled with contrast. This suggests no significant obstruction is present at duodenal level.

tially standardized total parenteral nutrition (PSTPN) was introduced. Trophic enteral feeding was implemented from the 4th until the 7th DOL, when the drainage of green fluid through the nasogastric tube reoccurred. Contrast enema showed no signs of distal intestinal obstruction. On the 10th DOL, a repeated upper gastrointestinal contrast study was performed which showed a slower rate of contrast flow through the descending duodenum, but without typical signs of stenosis or obstruction. Enteral feedings were re-

When all available diagnostic imaging methods are exhausted without reaching conclusive diagnosis, but a high suspicion of duodenal obstruction is raised, exploratory laparotomy can be performed as the final diagnostic and therapeutic measure.

introduced in form of 10 mL meals of preterm infant formula. On the 11th DOL, an improvement in tolerating oral intake was noticed and the amount of feeding formula per meal was gradually increased. However, the patient did not tolerate meals exceeding 15 mL of infant formula. On the 15th DOL, an abdominal ultrasound was performed, showing a distension of the pylorus and proximal duodenum with signs of aperistalsis, suggesting the obstruction of the duodenum and indicating the need for surgical intervention. On the 19th DOL, the patient underwent exploratory laparotomy. Intraoperatively, the duodenum was visualized with no apparent abnormalities. An attempt of placing a nasogastric tube into the distal part of duodenum was unsuccessful. A longitudinal duodenotomy was performed and the duodenal membrane was visualized and excised. Postoperative recovery was orderly with enteral intake introduced on the 5th postoperative day. The girl was discharged from hospital on the 21st postoperative day. At the age of 15 months, she exhibits normal psychomotor development.

CASE 2

A full-term baby girl was vaginally delivered at 38 weeks. Prenatally, a polyhydramnios accompanied by a "double bubble" sign was observed, suggesting duodenal obstruction. Her birth weight

was 3500 g and Apgar scores were 9/10. However, 50 minutes postnatally, she became tachypneic with signs of dyspnea requiring transfer to NICU. Her blood oxygen saturation level was 70%. Oxygen supplementation (1 L/min) was applied, increasing blood oxygen saturation to more than 95%. A nasogastric tube was placed due to prenatal ultrasound findings suggestive of duodenal obstruction. Abdominal and chest radiography, abdominal ultrasonography and upper gastrointestinal contrast study were performed, showing no signs of gastrointestinal obstruction. From the 2nd DOL, the patient was enterally fed without difficulties, consuming 65 mL of baby formula per meal. However, on the 6th DOL she started vomiting small amounts following the meal. During the next few days, the vomiting became more abundant until the 15th DOL, when she could not tolerate any oral intake. A nasogastric tube was placed resulting in a drainage of about 40 mL of light-green fluid through the tube. PSTPN was introduced. In addition to performing contrast enema, all previously used imaging methods were repeated, again showing no signs of gastrointestinal obstruction. An esophagogastroduodenoscopy was performed on the 22nd DOL. The endoscope could not be passed into the descending part of duodenum, suggesting an obstruction whose exact nature could not be identified. On the 25th DOL, the patient underwent laparotomy. Intraoperatively, a ring-like constriction near the middle of the descending part of duodenum was spotted. After performing a longitudinal duodenotomy, an intraluminal membrane was visualized about 1,5 cm proximal from the papilla of Vater. The membrane was excised, and the duodenum was sutured. Early postoperative recovery was orderly. Enteral feedings were introduced on the 5th postoperative day and gradually increased during following days. A supraventricular tachycardia occurred in a few instances and was successfully managed using adenosine and amiodarone. On the 13th postoperative day, the patient was febrile and blood culture showed presence of *S. aureus*. The infection was successfully managed by dual antibiotic therapy. The girl was discharged from the hospital on the 36th postoperative day.

DISCUSSION

In 1937, Ladd classified the causes of congenital duodenal obstructions as either intrinsic or extrinsic. Intrinsic causes include duodenal atresia, stenosis, duplication, and diaphragm (duodenal web). Extrinsic causes include malrotation of the intestine, congenital bands, annular pancreas etc.². Bailey et al. reported that vomiting occurs in 90% of duodenal obstruction cases, while abdominal distention, dehydration and weight loss are found in less than 25% of the cases³. However, our two cases show that vomiting due to incomplete duodenal obstruction is often intermittent, with periods of improvement and deterioration. Intermittent vomiting can cause difficulties in determining the diagnosis, especially because it can lead to nonconclusive findings when using gastrointestinal imaging methods.

When an infant presents with severe vomiting, it is crucial to radiologically exclude malrotation with midgut volvulus, as it presents a surgical emergency with a high risk of intestinal necrosis and death^{4,5}. Other causes of duodenal obstruction can be managed electively.

Initial management of intestinal obstruction includes cessation of enteral feeding and placement of a nasogastric or orogastric tube for drainage. Intravenous hydration and parenteral nutrition should be introduced, and potential electrolyte imbalances corrected. In our cases we took all those measures as soon as intestinal obstruction was suspected, and electrolyte imbalances correction was not necessary.

Diagnostic tools for duodenal obstruction include prenatal ultrasonography, postnatal abdominal ultrasonography, abdominal radiography, upper gastrointestinal contrast study, contrast enema and esophagogastroduodenoscopy. Computed tomography (CT) and magnetic resonance imaging (MRI) provide good anatomic detail but are not routinely used in cases of congenital duodenal obstruction⁴. All mentioned diagnostic tools were used in our cases, except for CT and MRI. However, we showed that even combining several diagnostic methods is sometimes insufficient in reaching a conclusive diagnosis on the presence and nature of duodenal obstruction. In our first case, all available diagnostic imaging meth-

ods were exhausted without reaching conclusive diagnosis, but a high suspicion of duodenal obstruction was raised. Exploratory laparotomy was performed as the final diagnostic and therapeutic measure.

Bailey et al. report that about one in three patients with duodenal obstruction have associated anomalies³. This highlights the need for a broad diagnostic workup, including a search for cardiac anomalies, central nervous system anomalies and other gastrointestinal defects. In our cases, we performed numerous diagnostic measures to find potential associated anomalies, including echocardiography and electroencephalography, but didn't find any.

Duodenal web surgery is usually carried out laparotomically, as has been done with our patients. A longitudinal duodenotomy followed by excision of the obstructive membrane is usually performed (Figure 2)⁶. Membranes localized near the major duodenal papilla should be managed without injuring the papilla of Vater. Positive outcomes have been achieved using laparoscopic approach for congenital duodenal obstruction repair. However, these procedures are technically demanding and still reserved for select pediatric surgical centers⁷. A few cases of successful endoscopic management of congenital duodenal webs have been reported^{8,9}. This minimally invasive

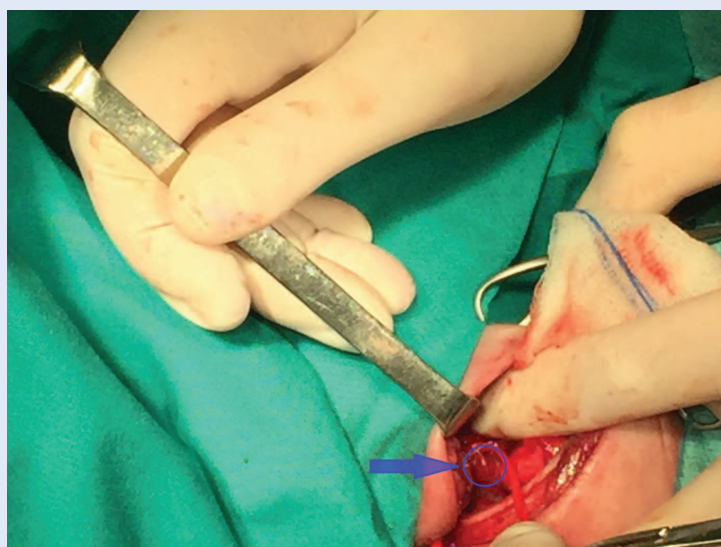


Figure 2. The obstructive web was visualized after longitudinal duodenotomy. On this intraoperative image, the web (marked by the blue circle) can be seen as a thin membrane leaning on the duodenal mucosa.

technique potentially provides faster recovery and less complications compared to surgical treatment. However, the procedure is not yet fully developed and has a high risk of complications such as excessive bleeding, failure to close the membranotomy wound and elevated pancreatic enzymes suggesting pancreatic injury. Severe complications may eventually require surgical management¹⁰.

CONCLUSIONS

Imperforated duodenal web is a rare congenital condition which can cause serious consequences and must be carefully diagnosed and managed. Diagnosing a perforated duodenal web is often challenging because of possible intermittent nature of vomiting which may be the only early symptom. There is a wide array of diagnostic tools available to investigate a suspected perforated duodenal web. However, the condition sometimes requires exploratory laparotomy to reach diagnosis. Duodenal web is usually treated by duodenotomy and web excision.

Conflicts of interest: Authors declare no conflicts of interest.

REFERENCES

1. Beeks A, Gosche J, Giles H, Nowicki M. Endoscopic dilation and partial resection of a duodenal web in an infant. *J Pediatr Gastroenterol Nutr* 2009;48:378-81.
2. Ladd WE. Congenital duodenal obstruction. *Surgery* 1937;1:878.
3. Bailey PV, Tracy TF Jr, Connors RH, Mooney DP, Lewis JE, Weber TR. Congenital duodenal obstruction: a 32-year review. *J Pediatr Surg* 1993;28:92-5.
4. Brinkley MF, Tracy ET, Maxfield CM. Congenital duodenal obstruction: causes and imaging approach. *Pediatr Radiol* 2016;46:1084-95.
5. Lampl B, Levin TL, Berdon WE, Cowles RA. Malrotation and midgut volvulus: a historical review and current controversies in diagnosis and management. *Pediatr Radiol* 2009;39:359-66.
6. Sarin YK, Sharma A, Sinha S, Deshpande VP. Duodenal webs: an experience with 18 patients. *J Neonatal Surg* 2012;1:20.
7. Boo YJ, Gödeke J, Engel V, Muensterer OJ. A case report of laparoscopic duodenal atresia repair in a neonate using a novel miniature stapling device. *Int J Surg Case Rep* 2017;30:31-33.
8. Barabino A, Gandullia P, Arrigo S, Vignola S, Mattioli G, Grattarola C. Successful endoscopic treatment of a double duodenal web in an infant. *Gastrointest Endosc* 2011;73:401-3.
9. Beeks A, Gosche J, Giles H, Nowicki M. Endoscopic dilation and partial resection of a duodenal web in an infant. *J Pediatr Gastroenterol Nutr* 2009;48:378-81.
10. Barabino A, Arrigo S, Gandullia P, Vignola S. Duodenal web: complications and failure of endoscopic treatment. *Gastrointest Endosc* 2012;75:1123-4.