

# Akutni koronarni sindrom u bolesnika na terapiji inhibitorom tirozin kinaze - prikaz slučaja

---

**Spicijarić, Matko; Tomulić, Vjekoslav; Zaputović, Luka**

*Source / Izvornik:* **Cardiologia Croatica, 2022, 17, 384 - 389**

**Journal article, Published version**

**Rad u časopisu, Objavljena verzija rada (izdavačev PDF)**

<https://doi.org/10.15836/ccar2022.384>

*Permanent link / Trajna poveznica:* <https://urn.nsk.hr/urn:nbn:hr:184:237134>

*Rights / Prava:* [Attribution 4.0 International](#)/[Imenovanje 4.0 međunarodna](#)

*Download date / Datum preuzimanja:* **2024-09-12**



*Repository / Repozitorij:*

[Repository of the University of Rijeka, Faculty of Medicine - FMRI Repository](#)



## Akutni koronarni sindrom u bolesnika na terapiji inhibitorom tirozin kinaze – prikaz slučaja

### Acute Coronary Syndrome in a Patient on Tyrosine Kinase Inhibitor Therapy – Case Report

**Matko Spicijarić\***

**Vjekoslav Tomulić,**

**Luka Zaputović**

Klinički bolnički centar Rijeka,  
Rijeka, Hrvatska

University Hospital Centre  
Rijeka, Rijeka, Croatia

**SAŽETAK:** Inhibitori tirozin kinaze sve se češće primjenjuju kao dio onkološke terapije zahvaljujući svojem protutumorskom učinku i učinku protiv angiogeneze. Jedan od značajnijih predstavnika navedene skupine lijekova jest sunitinib, oralni višeciljni inhibitor koji se upotrebljuje kod određenih oblika gastrointestinalnih stromalnih tumora, metastatskog karcinoma bubrežnih stanica i proširenoga neuroendokrinog tumora gušterače. Osim pozitivnih učinaka navedene skupine lijekova, zabilježeni su i oni neželjeni. Ovisno o autorima, 10 do 30 % bolesnika doživjelo je neki oblik kardiovaskularnog (KV) događaja u vrijeme primjene inhibitora tirozin kinaze. Ovim radom prikazuje se slučaj 73-godišnjeg bolesnika koji je zbog metastatskog tumora desnog bubrega prvotno operiran, a potom liječen sunitinibom. Otprilike osam mjeseci od početka navedene terapije bolesnik dolazi u Objedinjeni hitni bolnički prijam zbog boli u prsima. Izvedenim elektrokardiogramom postavljena je sumnja na akutni koronarni sindrom uz elevaciju ST-segmenta u inferiornim, posteriornim i lateralnim odvodima. Hitnom koronarografijom prikazala se okluzija proksimalnog dijela desne koronarne arterije te se nastavilo s primarnom perkutanom koronarnom intervencijom. S obzirom na to da u bolesnika nisu ranije zabilježeni značajniji KV komorbiditeti, postavljena je sumnja na potencijalnu povezanost s primjenom inhibitora tirozin kinaze. Promatrani radovi stranih autora slične tematike pokazali su znatnu učestalost širokoga spektra KV događaja. Pojedina su istraživanja pokazala da primjena te skupine lijekova dovodi do porasta arterijskoga tlaka, krutosti arterija i smanjenja elastičnosti. Naveden je i prikaz slučaja talijanskih autora koji opisuju da je bolesnik nakon 2 godine primjene sorafeniba podvrgnut kardiokirurškom zahvatu ugradnje prenosnica, iako nije imao značajnijih KV komorbiditeta. Kao zaključak promatranih radova i ovog prikaza bolesnika, nameće se potreba za kvalitetnijim KV praćenjem onkoloških bolesnika na terapiji inhibitorima tirozin kinaze u svrhu prevencije neželjenih događaja i ishoda.

**SUMMARY:** The use of tyrosine kinase inhibitors is becoming increasingly common in oncological therapy due to their anti-tumor and anti-angiogenic effects. One of the more significant representatives of this group of medications is sunitinib, an oral multi-target inhibitor used in certain forms of gastrointestinal stromal tumors, metastatic renal cell carcinoma, and advanced neuroendocrine pancreatic cancer. In addition to the positive effects of this group of medications, some unwanted effects have also been observed. Depending on the authors, 10% to 30% of patients experienced some form of cardiovascular (CV) event during the application of tyrosine kinase inhibitors. Herein we present the case of a 73-year-old patient who initially received surgery for metastatic cancer in the right kidney, followed by treatment with sunitinib. Approximately eight months after starting this treatment, the patient presented to the Integrated Emergency Hospital Admission department due to chest pains. An electrocardiogram was performed, and suspicion of acute coronary syndrome with ST-segment elevation in the inferior, posterior, and lateral leads was established. Emergency coronarography showed occlusion of the proximal part of the right coronary artery, and treatment continued with primary percutaneous coronary intervention. Given that no significant CV comorbidities had been previously recorded in the patient, a potential link to the application of tyrosine kinase inhibitors was suspected. Examination of other international publications on similar topics indicates a significant incidence of a wide spectrum of CV events associated with these medications. Some studies found that the application of this group of medications leads to increased arterial pressure, arterial stiffness, and reduced elasticity. A case report by Italian authors described a patient who underwent a cardiosurgical bypass procedure after 2 years of sorafenib use, despite having no significant CV comorbidities. These publications and the present case report lead to the conclusion that higher-quality CV monitoring is needed in oncological patients using tyrosine kinase inhibitors with the goal of preventing unwanted events and outcomes.

**KLJUČNE RIJEČI:** akutni koronarni sindrom, inhibitori tirozin kinaze, sunitinib, kardiotoksičnost.

**KEYWORDS:** acute coronary syndrome, tyrosine kinase inhibitors, sunitinib, cardiotoxicity.

**CITATION:** *Cardiol Croat.* 2022;17(11-12):384-9. | <https://doi.org/10.15836/ccar2022.384>

**\*ADDRESS FOR CORRESPONDENCE:** Matko Spicijarić, Klinički bolnički centar Rijeka, T. Strižića 3, Rijeka, HR-51000 Rijeka, Croatia. / Phone: +385-91-899-0341 / E-mail: [matko.spicijaric@gmail.com](mailto:matko.spicijaric@gmail.com)

**ORCID:** Matko Spicijarić, <https://orcid.org/0000-0002-0117-1835> • Vjekoslav Tomulić, <https://orcid.org/0000-0002-3749-5559>  
Luka Zaputović, <https://orcid.org/0000-0001-9415-9618>

**TO CITE THIS ARTICLE:** Spicijarić M, Tomulić V, Zaputović L. Acute Coronary Syndrome in a Patient on Tyrosine Kinase Inhibitor Therapy – Case Report. *Cardiol Croat.* 2022;17(11-12):384-9. | <https://doi.org/10.15836/ccar2022.384>

**TO LINK TO THIS ARTICLE:** <https://doi.org/10.15836/ccar2022.384>

#### RECEIVED:

October 15, 2022

#### UPDATED:

October 19, 2022

#### ACCEPTED:

November 3, 2022



## Uvod

Sunitinib kao oralni, višeciljni inhibitor tirozin kinaze ima izravan protutumorski učinak i učinak protiv angiogenezne aktivnosti djelujući putem nekoliko vrsta tirozinkinaznih receptora<sup>1</sup>. Prema Europskoj agenciji za lijekove, registriran je za liječenje gastrointestinalnoga stromalnog tumora kada nije moguće kirurško liječenje, a već je provedena terapija imatinibom, zatim kod metastatskog karcinoma bubrežnih stanica i proširenih neuroendokrinih tumora gušterače<sup>2</sup>. Uprkos brojnim pozitivnim učincima, sunitinib u dijela bolesnika izaziva i one neželjene. Neki od njih su hemoragični događaji, poremećaji probavnog sustava, poremećaji kože, poremećaji bubrežne funkcije, poremećaji štitnjače, arterijska hipertenzija, arterijski i venski tromboembolijski događaji pa čak i aneurizme i disekcije arterija<sup>3,4</sup>. Osim navedenih neželjenih događaja, zabilježeni su i određeni oblici poremećaja funkcije srca. Najčešće su ishemija miokarda i smanjenje istisne frakcije lijeve klijetke, manje česti kongestivno zatajivanje srca, infarkt miokarda, perikardijalni izljev i produljenje QT-intervalu, a rijetki *torsades de pointes* aritmija.

## Prikaz slučaja

U svibnju 2022. godine u Klinici za bolesti srca i krvnih žila hospitaliziran je 73-godišnji bolesnik pod slikom akutnog infarkta miokarda s elevacijom ST-segmenta. Inicijalno dolazi u Objedinjeni hitni bolnički prijam (OHBP) kolima hitne medicinske pomoći zbog tupih boli u prsnom košu, koje su se pojavile na dan prijma oko 8.30 sati. Dolazak u OHBP zabilježen je tek sedam sati nakon pojave simptoma. Boli su bile tupoga karaktera, najjači u središtu prsnog koša, uz propagaciju u desnu ruku, te su bili praćeni hladnim prenojavanjem.

Riječ je o bolesniku koji je prije u dvama navratima liječen zbog primarnog tumora prostate i bubrega. Godine 2015. učinjena je radikalna prostatektomija te se u daljnjem tijeku prate uredne vrijednosti PSA markera. Godine 2021. ustanovljena je novotvorina desnog bubrega s metastazama u lijevu nadbubrežnu žlijezdu. U srpnju iste godine izvedena su radikalna desnostrana nefrektomija i lijevostrana adrenaletomija. Naknadno je, histološki, potvrđen karcinom svijetlih stanica. U listopadu, 3 mjeseca nakon provedenoga operativnog liječenja, započeta je biološka terapija sunitinibom 50 mg prema shemi 4 tjedna uzimanja, 2 tjedna stanke. U travnju 2022. godine doza je smanjena na 37,5 mg. Subjektivno, u cijelome vremenu uzimanja lijeka bolesnik je bio bez tegoba, a laboratorijski je praćen povišen kreatinin od 120 do 150  $\mu\text{mol/L}$ . Posljednji pregled kod onkologa obavljen je potkraj travnja, tjedan dana prije akutnoga koronarnog sindroma (AKS). Od potencijalnih komorbiditeta koji su mogli pridonijeti razvoju AKS-a bolesnik je imao pretilost, dok arterijska hipertenzija, šećerna bolest, hiperkolesterolemija i pušenje nisu prije zabilježeni.

Bolesniku je, prehospitalno, tim hitne medicinske pomoći ordinirao 300 mg acetilsalicilatne kiseline i 180 mg tikagrelora. Odmah nakon dolaska u OHBP izmjereni su uredni vitalni parametri, a klinički status srca i pluća bio je bez osobitosti. Prema protokolu odmah je obavljen 12-kanalni elektrokardiogram kojim se verificira sinusni ritam frekvencije oko 50/min uz znatnu elevaciju ST-segmenta u inferiornim, posteriornim i lateralnim odvodima (**Slika 1**). Uzorkovani su laboratorijski nalazi i testiranje (PCR) na SARS-COV-2, a bolesnik je

## Introduction

As an oral, multi-target tyrosine kinase inhibitor, sunitinib has a direct anti-tumor effect as well as an effect against angiogenic activity, acting via several types of tyrosine kinase receptors<sup>1</sup>. According to the European Medicines Agency, it is registered for the treatment of gastrointestinal stromal tumors when surgical treatment is not possible and imatinib therapy has already been administered, as well as in metastatic kidney cell carcinoma and advanced neuroendocrine pancreatic cancer<sup>2</sup>. Despite having many positive effects, sunitinib also causes unwanted effects in some patients. These include hemorrhagic events, digestive disorders, skin disorders, kidney function disorders, pancreatic disorders, hypertension, arterial and venous thromboembolic events, and even aneurisms and arterial dissections<sup>3,4</sup>. In addition to these unwanted events, certain forms of heart function disorders have also been reported. The most common are myocardial ischemia and reduction in left ventricular ejection fraction, with the less common ones including congestive heart failure, myocardial infarction, pericardial effusion, and QT interval prolongation, and Torsades de Pointes arrhythmia being a rare effect.

## Case report

In May 2022, a 73-year-old man was hospitalized at the Clinic for Heart and Vascular Diseases with a clinical picture of acute myocardial infarction with ST-segment elevation. He initially presented by ambulance vehicle to the Integrated Emergency Hospital Admission (IEHP) department for dull aches in the chest that had manifested on the day of admission at approximately 8.30. Arrival at the IEHP was recorded as late as seven hours after appearance of the symptoms. The pain was dull, strongest in the middle of the chest with propagation to the right arm, and was accompanied with cold sweats.

Earlier, the patient had been treated twice for primary prostate and kidney tumors. A radical prostatectomy had been performed in 2015, and normal PSA markers were observed during follow-up. In 2021, a neoplasm was observed in the right kidney, with metastases in the left adrenal gland. Radical right-side nephrectomy and right-side adrenalectomy were performed in July, 2021. Clear cell carcinoma was subsequently histologically confirmed. In October, three months after the surgical treatment, biological therapy with sunitinib 50 mg was started, using a schema of 4 weeks of drug intake followed by a 2-week pause. The dose was reduced to 37.5 mg in April 2022. The patient was without subjective complaints during the whole treatment period, and laboratory monitoring observed elevated creatinine levels of 120 to 150  $\mu\text{mol/L}$ . The last oncological examination had been performed at the end of April, a week before the onset of acute coronary syndrome (ACS). Of the potential comorbidities that could have contributed to the development of ACS, the patient suffered from obesity, whereas arterial hypertension, diabetes, hypercholesterolemia, and smoking had not been observed.

The emergency medical team administered prehospital 300 mg aspirin and 180 mg of ticagrelor. Immediately upon presentation to the IEHP, examination showed normal vital parameters and unremarkable clinical heart and lungs status. Based on the recommended treatment protocol, a 12-lead electrocardiogram was immediately performed to verify sinus rhythm, which was found to have a frequency of approx-

žurno pripremljen za invazivnu kardiološku obradu. Hitnom koronarografijom prikazano je deblo lijeve koronarne arterije uredne morfologije iz koje se uočavaju tortuotična prednja silazna grana uredne morfologije i cirkumfleksna arterija, također uredne morfologije. Dominantna desna koronarna arterija bila je okludirana u proksimalnom segmentu (**Slika 2**), te se nastavilo s primarnom perkutanom koronarnom intervencijom. Žicom vodilicom uspjela se proći akutna okluzija te je potom balonskim kateterom učinjena predilatacija. Kontrolnim su angiogramom prikazani odljevni trombi do iza kruksa, a zbog stenozе i tortuoziteta srednjeg segmenta nije se uspio plasirati tromboaspiracijski kateter. Potom je odlučeno da se u navedene segmente postave dva stenta obložena lijekom, zatim se aspiracijskim kateterom učinila tromboaspiracija,

imate 50/min with significant ST-segment elevation in the inferior, posterior, and lateral leads (**Figure 1**). Laboratory samples were collected, a PCR test for SARS-COV-2 was performed, and the patient was rapidly prepared for invasive cardiological procedure. Emergency coronarography showed unremarkable morphology of the left main continuing into a tortuous left anterior descending artery and circumflex artery, also of unremarkable morphology. The dominant right coronary artery was occluded in the proximal segment (**Figure 2**), and primary percutaneous coronary intervention was continued. The acute occlusion was successfully passed with the guide wire, and predilatation was performed with a balloon catheter. Coronary angiography showed outflow thrombi up to beyond the crux, and an aspiration catheter could not be used due the tortuosity of the middle seg-

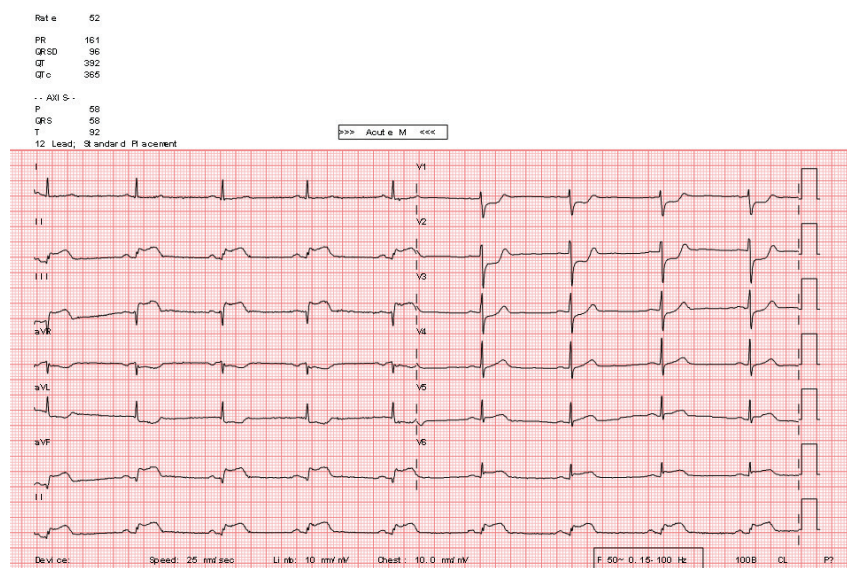


FIGURE 1. Initial 12-lead electrocardiogram upon arrival at the Emergency Department.

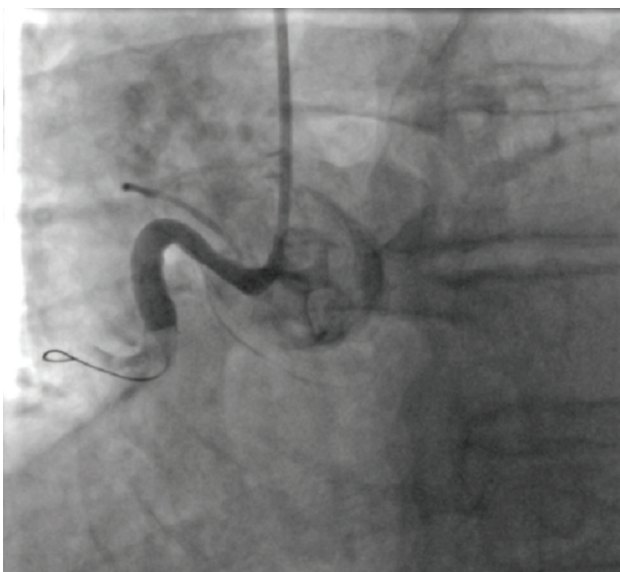


FIGURE 2. Proximal occlusion of the right coronary artery.

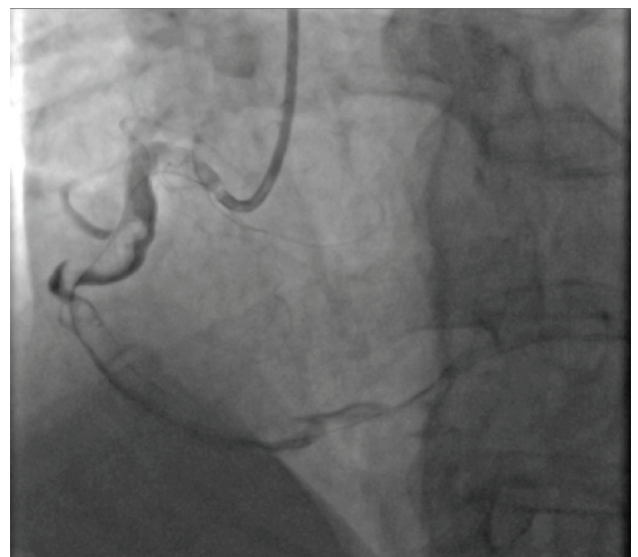


FIGURE 3. Right coronary artery after percutaneous coronary intervention.

a nakon toga i mehanička trombektomija kojom se uspjelo izvući više ugrušaka, no još uvijek uz distalni protok TIMI 0/1. Dodatno je pristupljeno dilataciji svih segmenata balonskim kateterom te je uz obilne količine tromba postignut distalni protok TIMI 1/2 (**Slika 3**). Nakon zahvata ordinirana je 24-satna infuzija tirofiban. U zaključku intervencije planirana je elektivna rekonarografija.

Nakon završetka intervencije bolesnik je smješten na Zavod za intenzivno kardiološko liječenje, a tada pristižu i ranije izvađeni laboratorijski nalazi. Ističu se vrijednosti visoko osjetljivog troponina T 365 ng/L (ref. <14) i kreatinina 137 μmol/L. Istog dana razvija se hemiplegija. Pokrenut je postupak za hitnu trombektomiju, no učinjenim CT-om mozga, CT perfuzijom mozga i CT karotidografijom i cerebralnom angiografijom nije pronađen patomorfološki supstrat za navedene tegobe. Stoga nije indicirano neurointervencijsko liječenje, kao ni sistemska tromboliza. Idućeg dana dolazi do spontanog oporavka neurološkog statusa, no laboratorijski se prati znatan porast visokoosjetljivog troponina T na više od 18 000 ng/L, kao i porasta kreatinina na 167 μmol/L. Trećeg dana boravka bolesnik postaje febrilan do 38 °C, uzorkovane su hemokulture i urinokulture, a empirijski je bio uveden ceftriakson. Laboratorijski je praćeno pogoršanje parametara bubrežne funkcije i porast kreatinina na 305 μmol/L, CRP-a na 165 mg/L i prokalcitonina na 1,19 μg/L. S obzirom na pad diureze te sumnje na postkontrastnu nefropatiju, pojačan je parenteralni i peroralni unos tekućine, a uveden je i furosemid kontinuirano. Četvrtog dana boravka nastaje hemodinamski urušaj te se započinje s inotropnom i vazoaktivnom potporom dobutaminom i noradrenalinom. Usprkos prije ordiniranoj terapiji kreatinin se povećava na 528 μmol/L te je, prema preporuci nefrologa, započeta vensko-venska hemodijafiltracija. Orijentacijskim je ultrazvukom prikazan biventrikularni ispad kontraktilnosti uz hemodinamski neznatčan perikardijalni izljev ispred desne klijetke. Usprkos svim poduzetim mjerama liječenja, nastupa pogoršanje stanja uz razvoj ireverzibilnoga hemodinamskog urušaja, što je dovelo do smrtnog ishoda petog dana hospitalizacije.

## Rasprava

U uvodnom su dijelu rada nabrojene brojne nuspojave sunitiniba, s naglaskom na one povezane s kardiovaskularnim (KV) sustavom. Samim time navedena je tema postala predmet brojnih radova. Tako su Schmidinger *i sur.* proučavali kardiotskičnost sunitiniba i sorafeniba u bolesnika s metastatskim karcinomom bubrega<sup>5</sup>. Na početku rada također se navodi da do razvoja kardiotskičnih učinaka dolazi u otprilike 10 % bolesnika na terapiji tirozinkinaznim inhibitorima. Posljedično navedenom, postavlja se pitanje o potrebi kvalitetnijeg KV monitoringa ne bi li se u ranoj fazi otkrili znakovi oštećenja miokarda. Cilj istraživanja bio je pratiti kliničke, biokemijske i elektrokardiografske znakove oštećenja miokarda, a provedena je u 86 bolesnika. Kao KV događaj definiran je porast biljega nekroze, simptomatska aritmija, novonastala ventrikularna disfunkcija i AKS. Od ukupnoga broja bolesnika, gotovo 34 % je doživjelo određeni KV događaj. Trećina navedenih bolesnika bila je podvrgnuta koronarnoj angiografiji, no u svih je ona bila bez osobitosti. U zaključku autori navode kako je oštećenje srca uzrokovano tirozinkinaznim inhibitorima u velikoj mjeri podcijenjeno. Doda li se tomu nepoznati mehanizam oštećenja srca, potreba za redovitom elektrokar-

ment. Two drug-eluting stents were placed in the abovementioned segments, followed by aspiration thrombectomy and mechanical thrombectomy that was successful in extracting multiple blood clots, but the distal flow was still TIMI 0/1 despite the treatment. Further dilatation of all segments with a balloon catheter was performed, and TIMI 1/2 was achieved despite numerous blood clots (**Figure 3**). After the procedure, 24-hour tirofiban infusion was prescribed. Elective rekonarography was planned to reevaluate the condition.

After the intervention, the patient was placed in the intensive cardiological treatment ward, and the laboratory findings for the previously collected samples became available. The most notable results were high-sensitivity troponin T values at 365 ng/L (reference value <14) and creatinine 137 μmol/L. The patient developed hemiplegia on the same day. An emergency thrombectomy protocol was initiated, but brain CT, CT brain perfusion, and CT angiography of cerebral and carotid arteries did not find any pathomorphological substrate for the patient's issues. Thus, no neurointerventional treatment or systemic thrombolysis were indicated. Spontaneous recovery of neurological status occurred on the next day, but laboratory findings showed a significant increase in high-sensitivity troponin T to over 18.000 ng/L as well as an increase in creatinine to 167 μmol/L. On the third day, the patient became febrile, with a temperature of up to 38 °C; blood and urine samples were taken, and ceftriaxone was introduced based on previous experience. Laboratory results showed deterioration of renal function parameters and an increase in creatinine to 305 μmol/L, CRP to 165 mg/L, and procalcitonin to 1.19 μg/L. Due to reduced diuresis and suspected post-contrast nephropathy, parenteral and peroral liquid intake was increased, and continuous furosemide was introduced. Hemodynamic collapse occurred on the fourth day of the patient's hospital stay, and inotropic and vasoactive support using dobutamine and noradrenaline was initiated. Despite the previously prescribed treatment, creatinine increased to 528 μmol/L, and venovenous hemodiafiltration was initiated on the nephrologist's recommendation. Ultrasound showed reduced biventricular contractility with hemodynamically insignificant pericardial effusion in front of the right ventricle. The patient's condition deteriorated despite all the treatment measures, with the development of irreversible hemodynamic collapse leading to a fatal outcome on the fifth day of hospitalization.

## Discussion

Numerous side-effects of sunitinib have been listed in the Introduction section, with an emphasis on those that are associated with the cardiovascular (CV) system. This has become the topic of numerous studies. Schmidinger *et al.* examined the cardiotoxicity of sunitinib and sorafenib in patients with metastatic kidney cancer<sup>5</sup>. At the beginning of their paper, they also state that cardiotoxic effects develop in approximately 10% of patients undergoing treatment with tyrosine kinase inhibitors. Consequently, the issue of the need for higher-quality CV monitoring must be addressed in order to detect signs of myocardial damage in the early phase. The goal of the study was to monitor the clinical, biochemical, and echocardiographic signs of myocardial damage, and it was conducted on 86 patients. A CV event was defined as increase in necrosis markers, symptomatic arrhythmia, newly-developed ventricular dysfunction, and ACS. Out of the total number of patients, almost 34% experienced some CV event. A third of these patients underwent coronary angiography, but no abnormalities were detected in any of them. In their conclusion, the authors state that heart damage caused by tyrosine kinase inhibitors

diografskom i biokemijskom evaluacijom nameće se kao nužnost.

Catino *i sur.* u multicentričnom prospektivnom istraživanju prikazali su utjecaj sunitiniba na KV sustav<sup>6</sup>. Rad je uključivao ukupno 84 bolesnika koji su bolovali od metastatskog karcinoma bubrega. Rezultati su pokazali da je nakon 3,5 tjedana primjene sunitiniba sistolički tlak u prosjeku narastao za 9,5 mmHg, a dijastolički za 7,2 mmHg. Također je zaključeno da se povećavaju krutost arterija i njihov periferni otpor, a smanjuje se elastičnost.

Abbondanza Pantaleo *i sur.* u prikazu slučaja obradili su razvoj stenozе koronarnih arterija u bolesnika na terapiji sorafenibom<sup>7</sup>. U uvodnom se dijelu rada navodi da postoji nekoliko opisanih slučajeva koronarne bolesti srca povezanih s terapijom sorafenibom, odnosno inhibitorima tirozin kinaze. U podlozi navedenih slučajeva bio je arterijski vazospazam, bez angiografijom verificirane stenozе. U tom prikazu slučaja bila je riječ o 58-godišnjem bolesniku bez promjenjivih čimbenika KV rizika. Zbog otkrivenog tumora bubrega s metastazama prvotno je podvrgnut operacijskom liječenju, a zatim i terapiji sorafenibom. Prije uvođenja terapije inhibitorima tirozin kinaze učinjeni su ultrazvuk srca i koronarna angiografija, koji su pokazali uredan nalaz. Nakon otprilike 2 godine primjene terapije bolesnik se požalio na intoleranciju napora i povremene boli u prsnom košu. Ubrzo je učinjena koronarografija kojom je prikazana subokluzivna lezija zajedničkog debila i središnjeg dijela cirkumfleksne arterije. Zbog navedenog bolesnik je bio podvrgnut kardiokiruškom zahvatu – izvedeno je trostruko aortokoronarno premoštenje. Važno je napomenuti da je bolesnik za cijeloga vremena uzimanja terapije redovito kontroliran.

Ranpure *i sur.* u metaanalizi prikazali su do tada objavljenog istraživanja i obradili rizik od ishemije miokarda i tromboembolijskih događaja u bolesnika na terapiji inhibitorima angiogeneze, u ovom slučaju bevacizumabom<sup>8</sup>. Uključena su ukupno 2322 bolesnika, a rezultati su pokazali da je ukupna incidencija visokostupanjске ishemije srca 1,5 %, dok je relativni rizik s obzirom na kontrolnu skupinu bio 2,14, što upućuje na to da primjena bevacizumaba znatno povećava rizik od ishemije srca, i to za 114 %.

## Zaključak

Inhibitori tirozin kinaze svakako imaju važnu ulogu kao terapija za određene vrste tumora, no samim time ne smiju se zanemariti njihovi potencijalni negativni učinci. Analizom literature vezane uz kardiotoksične nuspojave navedenih lijekova dolazi se do zaključka da su one učestale, a, prema nekim istraživanjima, razvije ih oko 10 % bolesnika. Ova tema dodatno privlači pozornost s obzirom na to da sam mehanizam nastanka kardiotoksičnosti nije poznat. Razvoj AKS-a opisanog u ovom prikazu bolesnika ne može se sa sigurnošću pripisati djelovanju sunitiniba, no prije navedenom analizom sličnog slučaja talijanskih autora ne može se niti zanemariti potencijalna povezanost, osobito zato što promatrani bolesnici nisu imali značajnije KV komorbiditete. Zbog svega navedenog važno je istaknuti nezamjenjivost provođenja kvalitetnog KV monitoringa u vrijeme primjene ove vrste terapije. Time bi se mogli navrijeme primijetiti neželjeni KV događaji, prilagoditi onkološko liječenje i na taj način izbjeći prekidanje liječenja zloćudne bolesti.

is greatly underestimated. Given that the mechanism of heart damage is not known, regular echocardiographic and biochemical evaluation is clearly a necessity.

Catino et al. conducted a multicentric prospective study that examined the influence of sunitinib on the CV system<sup>6</sup>. The study included a total of 84 patients who suffered from metastatic kidney cancer. The results showed an increase in systolic pressure by an average of 9.5 mmHg and an increase in diastolic pressure of 7.2 mmHg after 3.5 weeks of sunitinib application. Additionally, the authors concluded that arterial stiffness and their peripheral resistance had increased, and their elasticity had decreased.

Abbondanza Pantaleo et al. published a case report in which they described the development of coronary artery stenosis in a patient treated with sorafenib<sup>7</sup>. In the introductory part of the paper, they state there are several reported cases of coronary heart disease associated with sorafenib therapy, i.e. with tyrosine kinase inhibitors. Arterial vasospasm was the underlying cause in these cases, without stenosis verified by angiography. This case report described a 58-year-old patient without modifiable CV risk factors. Due to the discovery of a kidney tumor with metastases, the patient was initially treated surgically, followed by sorafenib therapy. Before tyrosine kinase inhibitors were introduced, a heart ultrasound and coronary angiography were performed, which were unremarkable. After approximately two years of treatment, the patient complained of lack of tolerance to exertion and occasional chest pains. Coronarography was performed shortly thereafter, which showed a subocclusive lesion of the left main trunk and the middle part of the circumflex artery. Consequently, the patient underwent cardiac surgery – a triple coronary artery bypass was performed. It is important to note that the patient had been undergoing regular follow-up during the entire treatment period.

A meta-analysis by Ranpure et al. examined studies published on this topic and evaluated the risk of myocardial ischemia and thromboembolic events in patients on angiogenesis inhibitors, in this case bevacizumab<sup>8</sup>. A total of 2322 patients were included, and the results showed that the total incidence of severe heart ischemia was 1.5%, and the relative risk in comparison with the control group was 2.14, which indicates that the application of bevacizumab significantly increases the risk of heart ischemia, namely by 114%.

## Conclusion

Tyrosine kinase inhibitors certainly have a significant role in the treatment of specific types of tumors, but this does not mean that their potential negative effects should be neglected. Literature analysis regarding the cardiotoxic side-effects of these medications leads to the conclusion that these side-effects are common: according to some studies, they develop in approximately 10% of patients. This issue elicits additional attention due to the fact that the mechanism of cardiotoxicity itself is not known. The development of ACS described in this case report cannot be ascribed to the effects of sunitinib with certainty, but the analysis of a similar case described above that was reported by Italian authors shows that the potential association cannot be ignored, especially since the patients were monitored and did not have significant CV comorbidities. Due to all of the above, it is important to emphasize the irreplaceable role of performing high-quality CV monitoring during the application of this therapy. This could allow timely detection of unwanted CV events, making adjustments in oncological treatment, and thus avoid stopping treatment for the malignant disease.

