

Short Stature - the Tip of the Iceberg of a Serious Illnesses - a Case Report

**Butorac Ahel, Ivona; Baraba Dekanić, Kristina; Bašić, Anđela;
Severinski, Srećko; Palčevski, Goran; Roganović, Jelena**

Source / Izvornik: **Central European journal of paediatrics, 2021, 17, 124 - 127**

Journal article, Published version

Rad u časopisu, Objavljena verzija rada (izdavačev PDF)

<https://doi.org/10.5457/p2005-114.300>

Permanent link / Trajna poveznica: <https://urn.nsk.hr/urn:nbn:hr:184:561491>

Rights / Prava: [Attribution-NonCommercial-NoDerivatives 4.0 International/Imenovanje-Nekomercijalno-Bez prerada 4.0 međunarodna](#)

Download date / Datum preuzimanja: **2025-02-02**



Repository / Repozitorij:

[Repository of the University of Rijeka, Faculty of
Medicine - FMRI Repository](#)



Short Stature – the Tip of the Iceberg of a Serious Illnesses – a Case Report

Ivona Butorac Ahel¹, Kristina Baraba Dekanić¹, Anđela Bašić², Srećko Severinski¹, Goran Palčevski¹, Jelena Roganović¹

¹Department of Pediatrics, Clinical Hospital Center Rijeka, Croatia, ²Department of Pediatrics, General Hospital Pula, Croatia

Correspondence: ivonabuah@gmail.com; Tel: + 385 51 659 157; Fax.: + 385 51 623 126

Received: July 26, 2021; **Accepted:** September 10, 2021

Abstract

Objective – The aim of this paper was to emphasize the importance of a complete physical examination of a child referred to a pediatric endocrinologist due to short stature. Although short stature is usually considered to be a sign of an endocrinological disease, a broad spectrum of other pediatric disorders may be the cause of growth retardation. **Case Report** – A 9-year-old girl was referred to a pediatric endocrinologist due to short stature. Physical examination revealed her height to be 120 cm (-2.7 SD) and her weight to be 17.75 kg (-3.93 SD). In addition, she looked extremely pale and had tachycardia (130 bpm). Laboratory tests revealed severe microcytic anemia. A wide diagnostic work-up was performed, without revealing a clear cause of the disease. It was found out that the girl had never started eating solid food and that her diet was extremely limited. Psychological and psychiatric evaluation were done. She received 7 doses of iron sucrose in total. During her hospital stay she was fed with enteral formulas, and food intake was gradually increased with the introduction of solid foods. Complete laboratory recovery from anemia was achieved within 2 months. In parallel with nutritional replenishment, her height and weight improved. **Conclusion** – This case demonstrates the importance of a thorough physical examination and preventive routine periodic evaluation in order to prevent further health impairment and possible life-threatening complications.

Key Words: Growth ■ Undernutrition ■ Anemia ■ Child.

Introduction

Somatic growth is a very complex process influenced by numerous genetic and environmental factors. Normal growth is one of the most reliable indicators of good children's health, adequate nutrition and a favorable psycho-emotional environment. Most healthy infants and children grow in a predictable fashion, following a typical pattern of progression in weight, length/height, and head circumference. Anthropometry has been an important tool in the assessment of children's growth. Growth charts show the child's growth pictorially over time, and help health care professionals monitor the progress of growth and make timely interventions in cases of growth impairment. A child's growth is considered to be in the normal range when its anthropometric parameters are within $\pm 2SD$ of the

mean (1). The term "undernutrition" implies inadequate nutrition, which includes an insufficient quantity of food as well as inadequate consumption of food in qualitative terms (2). Childhood malnutrition can have long-term physical and cognitive consequences, such as micronutrient deficiencies, anemia and anthropometrics (2).

We present the case of a girl in whom only short stature was recognized as a medical problem. Subsequently several more serious medical difficulties were determined, including life-threatening anemia.

Case Report

A 9-year-old girl was initially referred to a pediatric endocrinologist due to short stature. She was born as a second twin at term from an uneventful

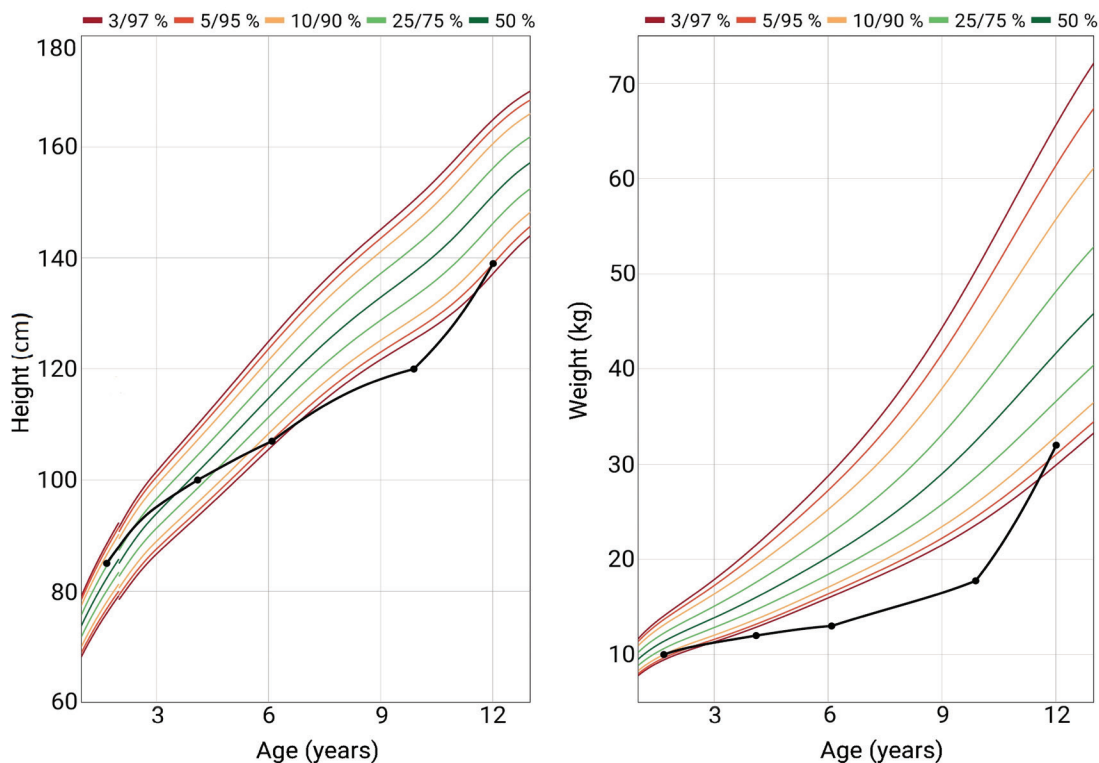


Fig. 1. Patient's growth parameters.

pregnancy, with birth weight 2780 g. She and her sister are the only children in an average middle-income family without any other comorbidities. The girls were generally healthy and visited their primary pediatrician occasionally, without any laboratory evaluation. Our patient was fed with regular milk formula, and complementary feeding was started at the age of 6 months, without any food allergy. She never started eating solid food and refused most food. Her diet was extremely limited - she ate only mixed fruit smoothies, shop bought yogurts and chocolate puddings. At the age of 9, the school medicine specialist referred both girls to a pediatric endocrinologist due to short stature, but nobody noticed their insufficient eating habits. Her growth velocity was 2.5 cm in the previous two years (Fig. 1). On the day of admission to the hospital the girl was extremely pale, cachectic, cardiocirculatory compensated, tachycardic 130/min, with a systolic cardiac murmur of 1/6 intensity, palpable liver and spleen 2 cm under the right and left costal arches,

and without peripheral edema. Her height was 120 cm (-2.7 SD), weight 17.75 kg (-3.93 SD) and body mass index (BMI) 12.5 kg/m² (-3 SD). Laboratory findings revealed severe microcytic anemia (Table 1).

Although the patient was hemodynamically stable, we assessed that intensive monitoring for the first 24 hours was indicated. After admission she received two doses of filtered red blood cell concentrates. On the second day she was transferred to the Department of Hematology for further evaluation and treatment. A broad diagnostic work-up was performed. A gastroenterologist excluded malabsorption and maldigestion as a cause of the disease. Thyroid function was normal. The bone age corresponded to a 6-year-old girl which was the consequence of undernutrition. The psychological assessment was performed using Raven's Progressive Matrices, Bender Gestalt test, Beck's Anxiety Inventory and Fear, Anxiety and Stress Scale/Assessment. The girl's normal intellectual functioning

Table 1. Laboratory Results at the Admission

Laboratory tests	Results	Reference intervals
RBC	2,98	4.07 – 5.42 ×10 ¹² /L
Hgb	33	118 – 149 g/L
Hct	0.143	0.354 – 0.450 L/L
MCV	48	76.5 – 92.1 fL
MCH	11.1	24.3 – 31.5 pg
Rtc	43	20 – 94×10 ⁹ /L
WBC	5.3	4.4 – 11.6×10 ⁹ /L
Trc	361	178 – 420×10 ⁹ /L
AST	24	14 – 39 U/L
ALT	6	11 – 37 U/L
ALP	108	179 – 472 U/L
GGT	14	10 – 24 U/L
Albumin	46	41.6 – 50.8 g/L
Ferritin	9	6 – 60 µg/L
LDH	230	152 – 284 U/L
Fe	<2	6 – 31 µmol/L
UIBC	84	31 – 72 µmol/L
TIBC	85	53 – 84 µmol/L
TSH	1.8	0.58 – 4.1 mIU/L
FT4	16.2	12.6 – 21 pmol/L
IgA	3.1	0.4 – 2.4 g/L
Anti – tTg IgA	2	negative <10; positive >10 U/mL
Anti – DGP IgG	<0.8	negative <10; positive >10 U/mL
IGF - 1	6.5	10.4 – 30.3 nmol/L
IGFBP - 3	77.9	62.6 – 246.9 nmol/L
Vitamin D	33.9	>75 nmol/L

was established. She verbalized the fear of chewing food which she preferred to swallow as a mouthful, and tension was noticed even at the mention of food. During her hospital stay she was fed by enteral formulas and food intake gradually increased with the introduction of solid foods. There was no need for tube feeding. Parenteral substitution therapy was administered. She received 7 doses of iron sucrose, with complete laboratory recovery within 2 months. Due to vitamin D deficiency, oral replacement therapy was started. She was regularly monitored by a child psychiatrist. Social services were involved and with their help the family dynamics became normal. The girl started to eat sol-

id food within 6 months. She gained weight and adequate height velocity was achieved. The girl is now 12 years old and her anthropometrics are as follows: body weight 32 kg (-1.53 SD), and height 139 cm (-1.75 SD), BMI 16.1 kg/m² -0.66 SD) respectively.

Her twin sister had similar anthropometric measures: her body weight was 17 kg (-3.93 SD), body height was 122 cm (-2.7 SD), and body mass index (BMI) 11.4 (-4.4 SD) respectively. She had better eating habits and was not anemic. Both girls have changed their eating habits. They have started eating a greater variety of foods and are very successful in martial sport.

Discussion

We decided to present this case report to highlight a few important things. Neither parents, healthcare professionals nor school teachers noticed that the girl had an eating problem. The fact that a child with such severe anemia was presented to a pediatric endocrinologist rather than to the emergency department really surprised us.

Short stature has to be evaluated endocrinologically. A broad spectrum of other pediatric disorders may be the cause of developmental and growth retardation. Endocrine disorders that affect growth occur in only about 5% of children (3). In fact, the most common causes of short stature beyond the first years of life are familial short stature and constitutional growth delay, which are normal, non-pathological variants of growth. Many systemic disorders have secondary effects on growth, including undernutrition, gastrointestinal diseases (especially celiac disease and Crohn's disease), renal diseases, and glucocorticoid therapy. Children with growth failure resulting from a gastrointestinal disease tend to have a greater deficit in weight than height, in contrast to those with endocrine disorders, who are often overweight-for-height. Keeping these facts in mind, all patients in whom weight deficiency is more pronounced than height deficiency should be referred to a gastroenterologist first. Psychiatric disorders may also be the cause of undernutrition; one

of them could be avoidant/restrictive food intake disorder (ARFID).

ARFID was recently recognized and defined according to the Diagnostic and Statistical Manual of Mental Disorders (DSM-V) as a failure to meet nutritional needs leading to short stature, failure to thrive, nutritional deficiency and/or psychological impairment (4). This diagnosis arose out of the earlier DSM-IV feeding disorder of infancy and early childhood, but it can be found in adulthood as well (5). It can be linked with various causes, such as decreased appetite, and avoidance of food associated with trauma and fear of choking, vomiting and/or nausea (4). The condition is not related to other medical or psychiatric conditions, such as distorted body image or preoccupation with body weight (6). ARFID is connected to numerous complications of malnutrition, such as micronutrient (iron deficiency anemia, vitamin D deficiency) and macronutrient deficiency, growth retardation, pubertal delay and decreased bone mineral density (7). Patients also have high dependence on enteral feeding (tube feeding) and/or oral nutritional supplements and can have medical conditions that require immediate hospitalization (bradycardia, prolonged QT interval on electrocardiogram, hypotension) (6, 8). There are no therapeutic guidelines for ARFID, but a multidisciplinary approach is needed (6).

Our patient has many elements of ARFID, with a clear impact seen in growth retardation and life-threatening iron deficiency anemia. With a multidisciplinary approach, which included different pediatric subspecialists, a psychologist and a psychiatrist, the girl recovered successfully. Social deprivation may also be one of the reasons why the girl had all these health-related difficulties, and it underlines the importance of a comprehensive approach to a child with non-specific signs and symptoms. Although we did not diagnose ARFID since it is a relatively new diagnosis, we retrospectively concluded that the girl might have had that condition. The purpose of emphasizing it is to raise awareness of ARFID. This case shows how basic anthropometric measurements can reveal the tip of the iceberg hidden behind growth retardation.

Conclusion

This case demonstrates the importance of evaluating the physical signs, anthropometric measurements, dietary information and behavior regarding food consumption, in order to detect a medical problem correctly, and prevent further health impairment and possible life-threatening complications. Primary pediatricians and school medicine specialists who perform routine periodic evaluations play a key role in that process.

Authors' Contributions: Conception and design: IBA, KBD, AB; Drafting the article: IBA, KBD, AB; Revising it critically for important intellectual content: IBA, KBD, SS, GP, JR; Approved final version of the manuscript: IBA, KBD, SS, GP, JR.

Conflict of Interest: The authors declare that they have no conflict of interest.

References

1. De Onis M, Onyango AW, Borghi E, Siyam A, Nishida C, Siekmann J. Development of a WHO growth reference for school-aged children and adolescents. *Bull World Health Organ.* 2007;85(9):660-7.
2. Martins VJ, Toledo Florêncio TM, Grillo LP, do Carmo P Franco M, Martins PA, Clemente AP, et al. Long-Lasting Effects of Undernutrition. *Int J Environ Res Public Health.* 2011;8(6):1817-46.
3. Rogol AD, Hayden GF. Etiologies and early diagnosis of short stature and growth failure in children and adolescents. *J Pediatr.* 2014;164:S1-14.e6.
4. American Psychiatric Association. *Diagnostic and statistical manual of mental disorders (DSM-5)*. Washington DC: American Psychiatric Association; 2013.
5. Thomas JJ, Lawson EA, Micali N, Misra M, Deckersbach T, Eddy KT. Avoidant/Restrictive Food Intake Disorder: a Three-Dimensional Model of Neurobiology with Implications for Etiology and Treatment. *Curr Psychiatry Rep.* 2017;19(8):54.
6. Seetharama S and Fields EL. Avoidant and Restrictive Food Intake Disorder. *Pediatr Rev.* 2020; 41(12):613-22.
7. Katzman DK, Norris ML, Zucker N. Avoidant Restrictive Food Intake Disorder. *Psychiatr Clin North Am.* 2019;42(1):45-57.
8. Norris ML, Robinson A, Obeid N, Harrison M, Spettigue W, Henderson K. Exploring avoidant/restrictive food intake disorder in eating disordered patients: a descriptive study. *Int J Eat Disord.* 2014;47(5):495-9.