

# Rijedak maligni filodes tumor dojke s heterolognom liposarkomatoznom diferencijacijom

---

Valković Zujić, Petra; Grebić, Damir; Tomašić, Ana-Marija

Source / Izvornik: **Medicina Fluminensis : Medicina Fluminensis, 2016, 52, 253 - 256**

Journal article, Published version

Rad u časopisu, Objavljena verzija rada (izdavačev PDF)

Permanent link / Trajna poveznica: <https://um.nsk.hr/um:nbn:hr:184:945626>

Rights / Prava: [In copyright](#)/[Zaštićeno autorskim pravom.](#)

Download date / Datum preuzimanja: **2024-08-27**



Repository / Repozitorij:

[Repository of the University of Rijeka, Faculty of Medicine - FMRI Repository](#)



# Rare malignant phyllodes tumor with heterologous liposarcomatous differentiation

## Rijedak maligni filodes tumor dojke s heterolognom liposarkomatoznom diferencijacijom

Petra Valković Zujčić<sup>1\*</sup>, Damir Grebić<sup>2</sup>, Ana-Marija Tomašić<sup>3</sup>

**Abstract. Aim:** Phyllodes tumor are rare fibroepithelial neoplasms that account for less than 1% of all breast neoplasms. They usually present as fast growing, clinically benign lesion. They usually occur in middle-age women (40-50 years). At mammography or ultrasound, phyllodes tumors mostly present as well-circumscribed oval or lobulated lesion similar to fibroadenoma. A diagnosis is made by histopathologic tumor analysis which shows biphasic characteristics: epithelial and stromal component. The analysis of the stromal component is crucial as the stromal component determines its malignant potential. A phyllodes tumor can be difficult to distinguish from a proliferative fibroadenoma at core needle biopsy so final histopathologic classification requires surgical excision. Malignant phyllodes tumors with heterologous components are extremely rare. **Case report:** We present a case of 35-year-old woman who had excisional biopsy of both breasts due to fibroadenomas 5 years ago. On the last ultrasound exam, a newly developed lesion of the right breast was detected with benign morphologic characteristic so a fine needle aspiration was performed. At breast examination, a firm, mobile mass was palpated, without signs of local tissue infiltration. Based on the obtained findings, a benign lesion was considered so excisional biopsy of the entire lesion was performed. **Conclusion:** The authors present a rare case of a young patient with previous excision biopsies due to multiple fibroadenomas who developed a recurrent tumor with benign clinical characteristics. The pathohistological analysis showed that it was a case of malignant phyllodes tumor with heterologous liposarcomatous differentiation manifesting as a collision tumor adjacent to a complex fibroadenoma.

**Key words:** fibroepithelial neoplasms; liposarcoma; phyllodes tumor

**Sažetak. Cilj:** Filodes tumori su rijetke fibroepitelne neoplazme koje obuhvaćaju < 1 % svih novotvorina dojke. Uglavnom se prezentiraju kao brzorastući, klinički benigni čvorovi pretežno u četvrtom i petom desetljeću života. Mamografske i ultrazvučne karakteristike filodes tumora su poput dobroćudnih lezija dojki s obzirom na to da se prezentiraju kao oštro ograničene, ovalne ili okrugle lezije nalik fibroadenomom. Dijagnoza se postavlja patohistološkom analizom tumora koji ima bifazične karakteristike: epitelnu i stromalnu komponentu. Pažljiva karakterizacija stromalne komponente je kritična, budući da su upravo karakteristike stromalnih stanica one koje određuju njegov maligni potencijal. Temeljem širokoiglene biopsije ne može se sa sigurnošću razlikovati filodes tumor od proliferativnog fibroadenoma, stoga konačna patohistološka dijagnoza zahtijeva eksciziju lezije. Maligni filodes tumori heterologne diferencijacije vrlo su rijetki. **Prikaz slučaja:** Prikazujemo slučaj 35-godišnje žene kojoj su prije 5 godina ekscipirani fibroadenomi objiju dojki. Na posljednjem ultrazvučnom pregledu nađena je novonastala lezija desne dojke morfološki dobroćudnih karakteristika te je učinjena aspiracijska punkcija. Klinički se palpirao bezbolni pomični tvrdi čvor. Klinička dijagnoza upućivala je na tumor benignih karakteristika te je pacijentici učinjena tumorektomija u lokalnoj anesteziji. **Zaključak:** Radi se o slučaju pacijentice kod koje se nakon multiplih fibroadenoma razvio recidivni tumor klinički benignih karakteristika, ali je patohistološka analiza pokazala da se radi o malignom filodes tumoru u blizini kojeg se nalazio kompleksni fibroadenom, što bi moglo upućivati na malignu transformaciju fibroadenoma u maligni filodes tumor.

**Ključne riječi:** fibroepitelne neoplazme; filodes tumor; liposarkom

<sup>1</sup>Department of Radiology, University Hospital Rijeka, Rijeka

<sup>2</sup>Department of General Oncologic Surgery, University Hospital Rijeka, Rijeka

<sup>3</sup>Intern of General Medicine, University Hospital Rijeka, Rijeka

\*Corresponding author:

Petra Valković Zujčić, dr. med.

Department of Radiology

University Hospital Rijeka

Krešimirova 42, 51 000 Rijeka

e-mail: petra.valkovic@gmail.com

<http://hrcak.srce.hr/medicina>

## INTRODUCTION

Phyllodes tumors (PT) are rare fibroepithelial tumors of the breast. They represent approximately 2-3% of breast fibroepithelial neoplasms, and less than 1% of breast tumors<sup>1</sup>. Fibroepithelial lesions may be benign (fibroadenoma, tubular adenoma) or potentially malignant (phyllodes tumor). The diagnosis consists of pathohistological evaluation of the tumor, which has biphasic characteristics: epithelial and stromal elements.

Adequate preoperative diagnosis of the phyllodes tumor is important because of its malignant potential and its tendency to recur and so that proper management of the tumor, which often does include surgery, can be pursued as early as possible.

Precise characterization of the connective tissue is required in view of the fact that stromal components are crucial for the assessment of the malignant potential of the tumor<sup>2</sup>. Complete surgical removal of the tumor is mandatory due to the high risk of local recurrence<sup>3-4</sup>.

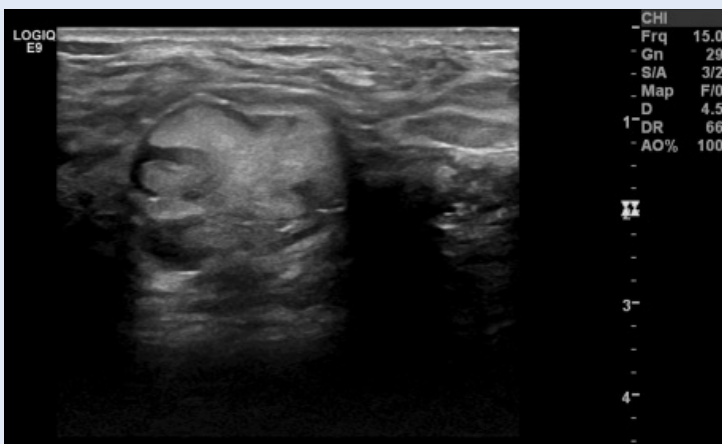
## CASE REPORT

Our patient was a 35-year-old woman who presented with newly developed lesions of the right breast. She had no personal or family history of breast cancer. In 2009, the patient underwent excisional biopsy of both breasts due to fibroadenomas (FA).

In 2014, her annual ultrasound examination revealed a newly formed solid lesion of the right breast measuring 2.4 cm. The detected mass was oval, hyperechoic with lobulated margins and hypoechoic rim, parallel oriented to the skin (figure 1). At the site, fine needle aspiration (FNA) was performed and cytological findings showed sporadic vacuolization of the cytoplasm in the stromal cells with rare larger and bare nuclei was observed with increased cellularity of the stroma. These findings were suggestive of phyllodes tumor with heterologous adipocyte differentiation. At breast examination, a firm, mobile and painless 2.5 cm mass was palpated at the 9 o'clock position of the right breast, without signs of local tissue infiltration. Based on the obtained clinical and cytological findings consistent with PT, excisional biopsy of the entire lesion was performed.

The macroscopic clip of the breast tissue measured 5 × 3.5 × 2.5 cm. On transverse section it was white colored, of rubber consistency, with a central yellow soft leaf-like node. The margins were partly round and well limited with regions of yellowish nodules infiltrating the surrounding tissue. Microscopically, the node was composed of thin leaf-like spaces, lined with epithelium. The stroma was hypercellular, with significant cell atypia, numerous mitoses, infiltrating margins, stromal outgrowing, and with a malignant heterologous component – myxoid liposarcoma. Under the same surgical procedure, another solid, lobular lesion was removed from the right breast, pathohistologically described as complex FA with myxoid stroma, measuring 3 × 2 × 1.5 cm.

Notwithstanding the suggestions in the current literature that wide excision with adequate negative surgical margins could be adequate treatment even for the malignant form of PT, because of the risk of local recurrence (reported as 20% – 30%), and the patient's preference, mastectomy of the right breast with immediate reconstruction with silicone breast implant was performed<sup>3-4</sup>. Prior to mastectomy, magnetic resonance imaging of the breast demonstrated extremely dense breast parenchyma with marked background contrast enhancement with no signs of malignant lesions. Mammography was not performed due to the patient's age.



**Figure 1.** Ultrasound image of an oval, hyperechoic lobulated mass, parallel to the skin surface

Pathohistological examination of the remaining breast tissue after mastectomy demonstrated three additional lesions of the right breast, all of them proven to be FA, and numerous foci of fibrotic changes and adenomatous hyperplasia of the breast.

Oncological treatment in the form of radiotherapy or chemotherapy was not conducted.

## DISCUSSION

Phyllodes tumor typically manifests as a rapidly growing, large palpable mass and may be characterized according to pathologic findings as a benign lesion or as low-grade (borderline) or high-grade malignancy<sup>5</sup>. Sonographic appearance of smaller phyllodes tumor (< 5 cm) may grossly resemble FA<sup>6</sup>. In our case, a PT was suspected on ultrasound due to complex appearance of lobulated lesions and known history of multiple FAs. Fibroadenomas have long been considered benign hyperplastic lesions rather than true neoplastic processes. However, malignant transformation of breast FA to malignant PT has been reported in the literature<sup>7</sup>.

Although core needle biopsy (CNB) is a method of choice for making preoperative diagnosis of breast lesions, in a setting of fibroepithelial lesions with FA at one end of the spectrum and a malignant PT at the other, accuracy in differentiating these two entities is not so straightforward. Because of the heterogeneity and overlap in the histology of both benign and malignant fibroepithelial tumors the distinction between them may be difficult and depending on several factors, including cellular atypism, mitotic activity, stromal cellularity and overgrowth, and borderline characteristics<sup>8</sup>. Typical features that indicate malignant PT are tumor invasion into surrounding tissue, stromal overgrowth, increased cellular pleomorphism, and mitotically active stroma with > 5 mitoses/10 high-power fields. Diagnosis of PT prior to excisional biopsy or lumpectomy is uncommon<sup>9</sup>. Therefore, unless the core biopsy shows only the classic features of a FA, PT should be considered.

Variations of the stromal cellularity, which is a crucial pathohistological element, can be found in FA, as well in PT<sup>11</sup>. Treatment of both histologi-

cal subtypes, benign and malignant PT, requires complete surgical excision with clear margins of 1 cm or greater due to the high risk of local recurrence<sup>3</sup>. If not removed completely, tumors recur in up to 20% of cases<sup>4</sup>. Positive margins, fibroproliferation in the surrounding breast tissue, and necrosis are associated with a marked increase in local recurrence rates<sup>4</sup>. Malignant PT demonstrates a wide spectrum of biologic behavior, and some have the potential for invasive growth, recurrence, or metastasis in rare cases<sup>11</sup>. There are no imaging characteristics that could distinguish benign from malignant PT and only limited information can be assessed by magnetic resonance imaging<sup>12</sup>. In a study by Yabuuchi et al, 30 benign, intermediate, and malignant PTs were compared. Tumors that were hypo- to -iso intense relative to normal breast parenchyma on T2-weighted images or that had a low apparent diffusion coefficient signal on diffusion-weighted images were more likely to demonstrate the unfavorable histological feature of stromal hypercellularity<sup>13</sup>.

The complex FA near to the newly developed tumor could indicate a transformation of fibroadenoma into malignant phyllodes tumor with heterologous liposarcomatous differentiation.

## CONCLUSION

In conclusion, this was a rare case of a young patient with previous excision biopsies due to multiple FA who developed a recurrent tumor with benign clinical characteristics. The pathological report after lumpectomy and revised cytological findings were consistent with malignant PT with sarcomatous elements, which resulted in right breast mastectomy.

Adequate preoperative diagnosis of the phyllodes tumor is important because of its malignant potential and its tendency to recur and so that proper management of the tumor, which often does include surgery, can be pursued as early as possible. There is no reliable way to distinguish between phyllodes tumors and other benign appearing tumors on ultrasound or mammography. Diagnostically, lumpectomy represents a consistent means for pre-operative diagnosis. Treatment can be either wide local excision or mastectomy to achieve histologically

clear margins. In our case, mastectomy with immediate reconstruction was considered to be the appropriate surgical procedure.

**Conflicts of interest statement:** The authors report no conflicts of interest.

## REFERENCES

1. Rowell MD, Perry RR, Hsju JG, Barranco SC. Phyllodes tumors. *Am J Surg* 1993;165:376-9.
2. Tumours of the breast. *In: Tavassoli FA, Devilee P (eds). Pathology and genetics of tumours of the breast and female genital organs. World Health Organization Classification of Tumours.* Lyon, France: IARC, 2003;9-112.
3. Chen WH, Cheng SP, Tzen CY, Yang TL, Jeng KS, Liu CL et al. Surgical treatment of phyllodes tumors of the breast: retrospective review of 172 cases. *J Surg Oncol* 2005;91:185-94.
4. Haydu SI, Espinosa MH, Robbins GF. Recurrent cystosarcoma phyllodes: a clinicopathologic study of 32 cases. *Cancer* 1976;38:1402-6.
5. Rosen PP. Fibroepithelial neoplasms. *In: Weinberg RW, Donnellan K, Palumbo R (eds). Rosen's Breast Pathology, 2nd ed.* Philadelphia: Lippincott Williams & Wilkins, 2001;176-200.
6. Liberman L, Bonaccio E, Hamele-Bena D, Abramson AF, Cohen MA, Dershaw DD. Benign and malignant phyllo-
7. Valdes EK, Boolbol SK, Cohen JM, Feldman SM. Malignant transformation of a breast fibroadenoma to cystosarcoma phyllodes: case report and review of the literature. *Am Surg* 2005;71:348-53.
8. Rosen PP, Oberman HA. Cystosarcoma phyllodes. *In: Rosai J, Sobin LH (eds). Atlas of tumor pathology: tumors of the mammary gland, fasc 7, ser 3.* Washington, DC: Armed Forces Institute of Pathology, 1993;107-14.
9. Nccn.org [Internet]. Fort Washington: National Comprehensive Cancer Network, c2016 [cited 2016 Jan 23]. Available from: <http://www.nccn.org/>.
10. Hsu SD, Chou SJ, Hsieh HF, Chen TW, Cheng MF, Yu JC. Giant malignant mammary phyllodes tumor: report of a case and review of the literature. *Onkologie* 2007;30:45-7.
11. Barrio AV, Clark BD, Goldberg JI, Hoque LW, Bernik SF, Flynn LW et al. Clinicopathologic features and long-term outcomes of 293 phyllodes tumors of the breast. *Ann Surg Oncol* 2007;14:2961-70.
12. Wurdinger S, Herzog AB, Fischer DR, Marx C, Raabe G, Schneider A et al. Differentiation of phyllodes breast tumors from fibroadenomas on MRI. *Am J Roentgenol* 2005;185:1317-21.
13. Yabuuchi H, Soeda H, Matsuo Y, Okafuji T, Eguchi T, Sakai S et al. Phyllodes tumor of the breast: correlation between MR findings and histologic grade. *Radiology* 2006;241:702-9.