

Surgical Correction of Myopia

Bohač, Maja; Pauk Gulić, Maja; Biščević, Alma; Gabrić, Ivan

Source / Izvornik: **Intraocular Lens, 2020**

Book chapter / Poglavlje u knjizi

Publication status / Verzija rada: **Published version / Objavljena verzija rada (izdavačev PDF)**

<https://doi.org/10.5772/intechopen.85644>

Permanent link / Trajna poveznica: <https://um.nsk.hr/um:nbn:hr:184:214421>

Rights / Prava: [Attribution-NoDerivatives 4.0 International](#)/[Imenovanje-Bez prerada 4.0 međunarodna](#)

Download date / Datum preuzimanja: **2024-08-17**



Repository / Repozitorij:

[Repository of the University of Rijeka, Faculty of Medicine - FMRI Repository](#)



We are IntechOpen, the world's leading publisher of Open Access books Built by scientists, for scientists

5,400

Open access books available

134,000

International authors and editors

165M

Downloads

Our authors are among the

154

Countries delivered to

TOP 1%

most cited scientists

12.2%

Contributors from top 500 universities



WEB OF SCIENCE™

Selection of our books indexed in the Book Citation Index
in Web of Science™ Core Collection (BKCI)

Interested in publishing with us?
Contact book.department@intechopen.com

Numbers displayed above are based on latest data collected.
For more information visit www.intechopen.com



Surgical Correction of Myopia

*Maja Bohac, Maja Pauk Gulic, Alma Biscevic
and Ivan Gabric*

Abstract

Myopia is the most prevalent refractive error in the world and its incidence is increasing. Together with conservative methods of treatment, various surgical methods have been proposed. Corneal refractive surgery is probably the most accepted one. Laser in situ keratomileusis (LASIK), photorefractive keratectomy (PRK), and small incision lenticule extraction (SMILE) are suitable for treatment of myopia up to -8.00 D in the younger age group. For patients not suitable for corneal refractive surgery, lens-based procedures are available. Phakic intraocular lenses are suitable for patients younger than 45 years of age with high myopia or some other contraindications for corneal refractive surgery. For older patients, refractive lens exchange (RLE) with implantation of multifocal or monofocal intraocular lenses is gaining popularity.

Keywords: myopia, LASIK, PRK, SMILE, phakic intraocular lenses, refractive lens exchange

1. Introduction

Myopia is a common refractive error in the population. It is defined as an optical aberration in which parallel light rays from a distant image are getting focused on a point anterior to the retina. Hereditary and environmental factors both play an important role in the development of myopia. Myopia typically appears between the age of 6 and 12, and the mean rate of progression is considered to be approximately 0.50 D per year, based on studies of mostly Caucasian children. One of the studies showed that progression of myopia can vary by ethnicity, as well as by age of the child. For instance, in ethnic Chinese children, the progression rate is higher [1].

A recent report in *Nature*, entitled “The Myopia Boom,” demonstrated, and it is now widely accepted, that there is an epidemic of myopia in the developed countries of East and Southeast Asia, paralleled by an epidemic of high myopia [2]. Recent meta-analyses have suggested that close to half of the world’s population may be myopic by 2050, with as much as 10% highly myopic [3]. Correction of refractive error can be achieved conservatively with glasses or contact lenses which is the treatment of choice in the childhood. However, despite the long-standing use of glasses and contact lenses, there are some disadvantages in both forms of optical correction. Increased light scatter, image magnification/minification, discomfort, and inconvenience are some of the issues with glasses, while contact lenses may irritate the ocular surface with increased risk of corneal scratches and infections. After the age of 21, various surgical treatments can be considered. The best surgical option depends on the amount of refractive error and the patient’s cornea, lens, and age. Available options include various laser vision corrections which are aimed on the cornea, implantation

of phakic intraocular lenses (pIOLs), and refractive lens exchange (RLE) with implantation of multifocal and monofocal intraocular lenses (IOLs). It is important to perform a detailed examination of each patient and assess their needs, wishes, and expectations. Doctors need to explain in as much detail as possible what the expected results and risk would be with for the selected surgical method.

2. Corneal refractive surgery

Procedures which involve altering the shape of the cornea with excimer laser are collectively referred to as keratorefractive surgery, refractive keratoplasty, laser vision correction, or refractive corneal surgery.

2.1 Photorefractive keratectomy

Photorefractive keratectomy (PRK) was the first excimer laser technique for the treatment of refractive errors. Seiler performed the first corneal ablation in a live patient in 1985, and McDonald treated the first human sighted eye in 1985 after extensive preclinical investigation [4]. The PRK procedure involves removal of the central corneal epithelium, most commonly performed mechanically (brush, crescent knife, or alcohol) or with excimer laser when it is referred as transepithelial PRK (T-PRK). The denuded anterior stroma is then reshaped by the excimer laser, with either central corneal flattening, steepening, or a torical pattern when treating myopia, hyperopia, or astigmatism, respectively. Due to significant postoperative pain, relatively slow visual recovery, epithelial defects due to irregular healing, and haze development, especially when treating high myopia [5, 6], different techniques of epithelial removal were introduced over time to solve these complications [7]. Recently the role of surface ablations has been reevaluated due to raised issues of potential flap complications, risk of iatrogenic corneal ectasia, and inability to treat thin corneas with laser in situ keratomileusis (LASIK) [8]. With surface ablation techniques, there is no flap involved, and more cornea tissue is preserved, and by some it is still considered the overall safest procedure for treatment of low to moderate myopia [9]. It is performed, especially in corneas with superficial scarring, epithelial dystrophies, or recurrent erosions, in thin corneas, after penetrating keratoplasty and for keratorefractive retreatments. The introduction of mitomycin C and modern surface ablation techniques has also increased the range of treatment and lowered the risk of haze and regression after PRK [10]. Therefore today surface ablation includes several sub-techniques such as epithelial LASIK (epi-LASIK), laser-assisted subepithelial keratectomy (LASEK), and T-PRK [11].

2.2 Laser in situ keratomileusis

The term LASIK was first used in 1990 by Pallikaris [4]. The procedure is performed in two steps. The first step involves the formation of a front corneal flap and the lifting of the flap for the purpose of exposing the corneal stroma. The hinged flap consists of the corneal epithelium, the Bowman membrane, and superficial stroma. The second step is the application of the excimer laser on the stromal bed. Once the ablation with the excimer laser is finished, the flap is returned into its original position.

LASIK has now become the most common elective surgical procedure in the world, presumably because it is almost painless with fast visual recovery, as compared to PRK [4]. Nowadays, there are two techniques available for the formation of the flap—mechanical microkeratomes and femtosecond lasers. The use of femtosecond laser-assisted laser in situ keratomileusis (FsLASIK) offers greater precision in flap

creation leading to better morphological stability of the flap compared to earlier bladed microkeratome keratomileusis. However, changes in the biomechanical strength of the cornea, induction of higher-order aberrations, and flap-related complications can still occur [12]. LASIK reduces the tensile strength of the stroma by about 35% when the ablation takes place between 10 and 30% of the stromal depth [13]. Regarding the available data, and our experience, there is no significant difference in shorter-term refractive stability and induction of high-order aberrations between T-PRK and LASIK (Figures 1 and 2 and Table 1). However, when higher refractive errors are treated, surface ablations pose more risk for haze development and regression [14].

2.3 Small incision lenticule extraction

The femtosecond laser corneal procedure known as small incision lenticule extraction (SMILE) was originally described by Sekundo et al. and became clinically

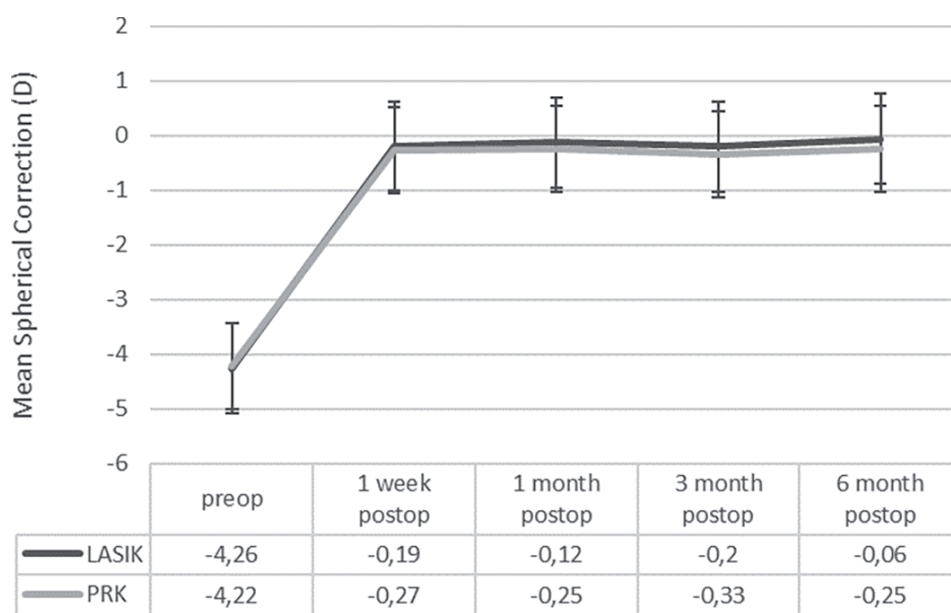


Figure 1.
 Comparison of change in spherical correction over time between T-PRK and LASIK.

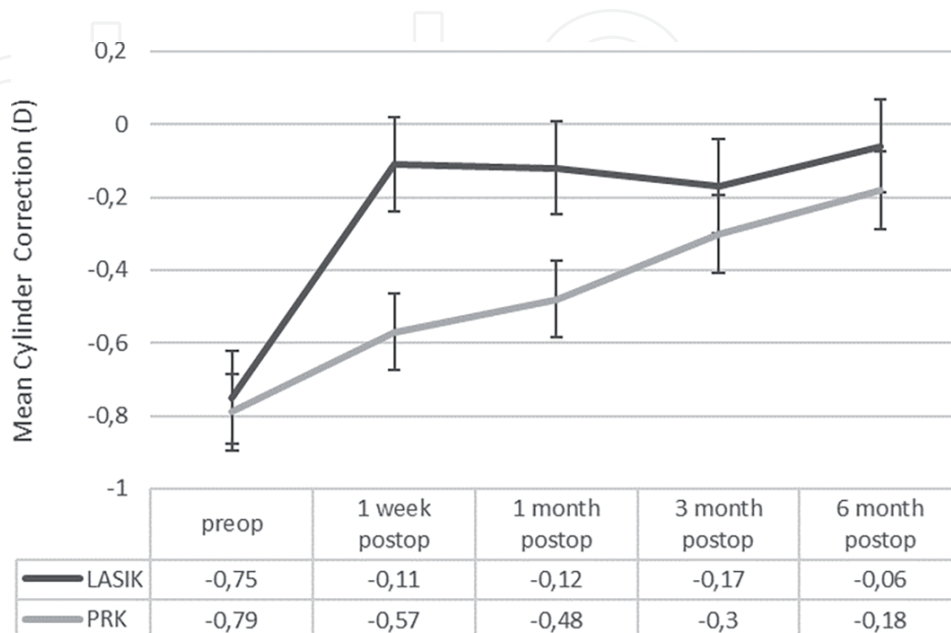


Figure 2.
 Comparison of change in astigmatism correction over time between T-PRK and LASIK.

HIGH ORDER ABERRATIONS AT 5mm PUPIL

	T-PRK			LASIK		
	PreOp	3 month postop	6 month postop	PreOp	3 month postop	6 month postop
COMA (μm)	0,12 \pm 0,07	0,15 \pm 0,09	0,13 \pm 0,1	0,9 \pm 0,07	0,13 \pm 0,09	0,09 \pm 0,07
TREFOIL (μm)	0,08 \pm 0,05	0,14 \pm 0,08	0,10 \pm 0,06	0,09 \pm 0,05	0,10 \pm 0,05	0,08 \pm 0,08
SA (μm)	-0,01 \pm 0,05	-0,01 \pm 0,07	-0,01 \pm 0,05	0,1 \pm 0,09	0,01 \pm 0,05	0,02 \pm 0,03

Table 1. Comparison of change in high-order aberrations over time between T-PRK and LASIK.

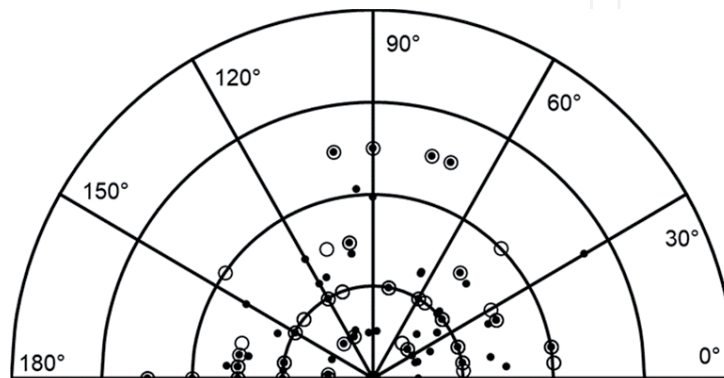


Figure 3. Polar diagram showing target and surgically induced astigmatic values for the SMILE group. The concentric semicircles reduce in 0.50 D steps from -2.00 DC (outermost semicircle) toward zero (central point) in 0.50 DC steps. From right to left, the 0 to 90 to 180° axes are shown in 30° steps. The target and surgically induced astigmatism data points are shown as empty circles and filled dots, respectively.

available in 2011 [15]. The procedure does not require the creation of a flap: two precise intrastromal planar sections are created using a single femtosecond laser to form an intrastromal lenticule. The intrastromal lenticule is dissected from the pocket, grasped with a forceps, and manually extracted through a small incision. The incision is placed at the superior temporal/nasal quadrant, usually angled at 70°, and 2–5 mm in length. The removal of the intrastromal lenticule alters the shape of the cornea, thereby correcting myopia and astigmatism. Since Bowman’s layer remains intact, the procedure offers greater biomechanical stability, especially in the treatment of higher levels of myopia [15]. The flapless property of SMILE obviates the risks associated with LASIK including adverse events at flap creation and dislocation [16].

The tensile strength of the cornea may reduce by 55% after a SMILE procedure when the lenticule is formed and extracted from the anterior half of the stroma. Loss of tensile strength is less profound when the lenticule is extracted from deeper regions of the stroma. Thus, the exact change in the biomechanical properties of the cornea will depend on the amount of ablation and the location where the lenticule is formed [13].

Regarding the available data, and our experience, LASIK and SMILE are comparable procedures in terms of visual quality and reduction of myopia; however, in treating astigmatism LASIK still offers better precision (**Figures 3 and 4**).

2.4 Indications and preoperative preparation for refractive surgery

A detailed review of the patient’s condition before surgery and informing the patient about the results, benefits, and disadvantages of the procedure are the most important steps for a successful outcome of refractive surgery [17].

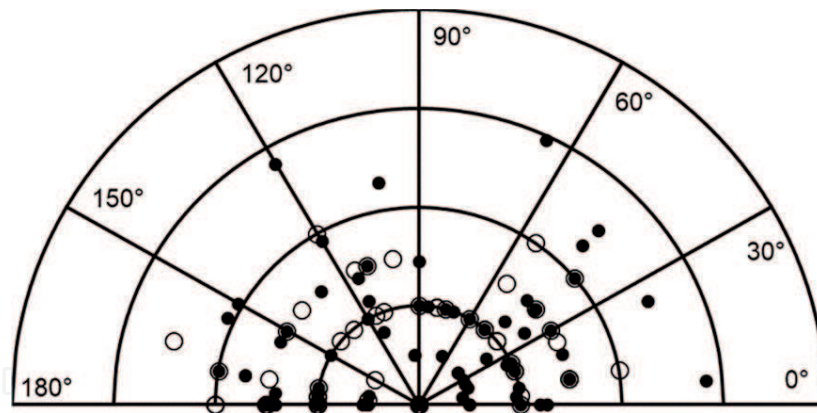


Figure 4. Polar diagram showing target and surgically induced astigmatic values for the FsLASIK group. The concentric semicircles reduce in 0.50 D steps from -2.00 DC (outermost semicircle) toward zero (central point) in 0.50 DC steps. From right to left, the 0 to 90 to 180° axes are shown in 30° steps. The target and surgically induced astigmatism data points are shown as empty circles and filled dots, respectively.

The examination should include detailed medical history (systemic status, medications intake, allergies, ocular status, information about previous ocular surgeries—especially in the case of refractive lens exchange—and information about contact lens wear) and reasons/motivations for refractive surgery to identify patients with unrealistic expectations [18, 19]. It is important for patients to understand that refractive surgery primarily serves to reduce spectacle dependence and contact lens use, and it is not meant to completely remove all optical aids in all situations, for an indefinite time period.

Patients should discontinue contact lens use before the examination (for soft contact lenses, at least a week prior to the examination, and for rigid gas permeable contact lenses, at least 2–3 weeks prior) since corneal topography and biometry measurement can be severely affected by the corneal changes induced by contact lens wear. In the case of corneal warpage syndrome (corneal irregularities caused by contact lenses), contact lenses should be discontinued for at least 4–6 weeks [20].

The preoperative evaluation must include monocular manifest refraction, cycloplegic refraction, uncorrected distance visual acuity (UDVA), corrected distance visual acuity (CDVA), pupillometry, tonometry, anterior chamber depth (ACD) measurement, corneal topography/tomography, pachymetry, aberrometry, tear film quality and quantity, determining the dominant eye, ocular motility, and a fundus examination [18, 21]. Cycloplegic refraction is recommended to exclude the accommodation effect, while in patients in/or close to presbyopia age near visual acuity should be checked also. It is mandatory to check the patient's refractive stability during the time, which can most often be obtained by inspecting the patient's eyeglasses or by reviewing the previous ophthalmological documentation [21].

Contraindications for refractive surgery may relate to systemic or ocular disorders. Absolute systemic contraindications are poorly controlled systemic immune diseases (e.g., rheumatoid arthritis, systemic lupus erythematosus, polyarteritis nodosa), as well as poorly controlled diabetes and AIDS. Such patients have a higher risk of complications associated with prolonged inflammation or corneal healing after refractive surgery [18, 22–24]. Surgical procedures are not recommended during pregnancy and lactation [25].

Ocular absolute contraindications are considered to be poorly controlled or untreated eye inflammation (blepharitis, dry eye syndrome, atopy/allergy), poorly controlled glaucoma, clinically significant lens opacities, Stevens-Johnson syndrome, ocular pemphigoid, and chemical burns of the eye surface [26, 27]. Instability of refraction (i.e., a change greater than 0.50 D within a year) is

considered as an absolute contraindication, as well as insufficient corneal thickness or corneal irregularities suspicious for keratoconus [21, 26, 28, 29]. Precautions are also needed in patients with certain systemic therapies (isotretinoin, amiodarone, sumatriptan, colchicine) [23, 24, 30]. Caution is also required in functional monocular patients and in patients with well-controlled glaucoma. Other relative contraindications are history of uveitis, herpes simplex, and varicella zoster keratitis. In patients with epithelial basal membrane degeneration, LASIK is not recommended, but PRK is the procedure to consider [21, 31].

2.5 Limitations and complications of corneal refractive surgery

Complications of corneal refractive surgery are considered rare. They can be divided in intraoperative and postoperative complications (which can be early or delayed).

Regarding the intraoperative complications, they are mainly correlated with corneal flap creation or excimer laser ablation. During the era of microkeratome, flap-related complications were encountered more often and fell within 3%; with the introduction of femtosecond lasers, they were almost nullified; however, some complications specific to femtosecond lasers appeared [32].

Flap-related complications include free or partial flap creation, incomplete and irregular flap creation, thin and perforated flaps, and corneal perforation. Those complications were mostly related to corneal anatomy (flat <41.00 D or steep >46.00 D corneas, small corneal diameter), inadequate suction, mechanical failure—a defect in the dissection blade or motor unit—and surgeon experience. Penetration into the anterior chamber is extremely rare and may occur during lamellar dissection or excimer laser photoablation usually on extremely thin corneas with old scars [33].

Femtosecond-related complications are closely correlated with cavitation bubbles and formation of the flap. They are presented in the form of confluent cavitation bubbles in the corneal lamellae or anterior chamber which can interfere with excimer laser systems and vertical gas breakthrough which is presented in the forms of incomplete buttonholes or difficulties in dissecting the flap due to tissue bridges [34]. Temporary hypersensitivity to light and rainbow glare are complications exclusively related to energy and pattern of femtosecond lasers characterized with normal visual acuity and photophobia without inflammation or light dispersion in low light conditions [35].

Laser-related complications include decentration of excimer laser ablation, irregular astigmatism, and formation of central islands. Those complications are clinically characterized by poor uncorrected and corrected distance visual acuity complaints of glare, “ghosting” around images and haloes, and refractive astigmatism in the axis of decentration [33].

Early postoperative complications include flap striae, diffuse lamellar keratitis, central toxic keratopathy, pressure-induced steroid keratitis, infectious keratitis, and epithelial ingrowth.

Flap striae are caused by misalignment of the flap; peripheral striae usually are asymptomatic; however, central location of the striae is associated with loss in corrected distance visual acuity and night vision disturbances [33, 36].

Diffuse lamellar keratitis (Sands of Sahara syndrome) is a sterile inflammation probably caused by the introduction of toxins in the flap interface [37, 38]. It is graded in four stages, with stage one and two being mild and visually unthreatening, while stage four can lead to corneal melting and permanent changes [33, 39]. In comparison to diffuse lamellar keratitis, central toxic keratopathy is a rare noninflammatory central corneal opacification linked to enzymatic degradation of keratocytes with spontaneous resolution and mild central opacification which often causes refractory hyperopic shift [40].

Pressure-induced stromal keratitis is also easily mistaken with diffuse lamellar keratitis but is caused by postoperative steroid use which leads to increase in intraocular pressure and represents as cystoid lamellar edema [41].

Infectious keratitis after LASIK is extremely rare but can be quite serious since invading organisms are already implanted into the deep corneal stroma. The most often isolated organisms include *Streptococcus pneumoniae*, *Staphylococcus aureus*, *Mycobacterium chelonae*, and *Nocardia asteroides* [33, 42].

Epithelial ingrowth under the LASIK flap is reported to occur in merely 1–2% of patients and is caused by migration of epithelial cells under the flap. It is usually insignificant, but if epithelial cells continue to grow, it can cause flap distortion and melting causing visual disturbances [43].

Late postoperative complications include dry eye, night vision problems, corneal haze, regression of refractive error, and iatrogenic corneal ectasia.

Dry eye syndrome is caused by denervation and cutting of nerve fibers during the formation of the flap, removal of corneal tissue by excimer laser, and changes in the shape of the cornea. Dry eye syndrome is usually transient and symptoms fade away after healing period. It causes discomfort, fluctuation in vision quality, slower healing, and epithelial damage and may lead to regression of refractive error and reduced vision quality [44].

Symptoms of impaired visual quality are usually more expressed during the night due to physiological pupil dilatation. The main causes of nighttime issues are the increase in spherical aberrations at the centrally flattened cornea, decentered ablations, too small optical zones, newly emerging lens opacities, and induced astigmatism [45].

Corneal haze reduces corneal transparency at variable degrees and is more common after PRK and correction of high myopia (> -6.00 D). Besides the ablation depth, it is correlated with an excessive ocular UV-B radiation, duration of the epithelial defect, postoperative steroid treatment, male sex, and certain population with brown iris [46].

Regression of refractive error is defined as return of part of the primary refractive error and is associated with increase in thickness and curvature of the cornea. Potential mechanisms include nuclear sclerosis, stromal synthesis (wound healing), compensatory epithelial hyperplasia, and iatrogenic keratectasia [47].

Postoperative ectasia is linked to biomechanical weakening of the cornea and is characterized with progressive corneal steepening, either centrally or inferiorly, resulting in severe progressive irregular astigmatism and decrease of both uncorrected and best-corrected visual acuity. The incidence of ectasia after LASIK has been estimated between 0.04 and 0.9% [48]. Risk factors include abnormal topographic findings, thin cornea, and high myopia together with young age at the time of surgery [49].

Intraoperative complications of SMILE procedure are usually not sight threatening, and the procedure usually can be continued [13, 15, 50]. The most common complications are incision or cap tears, suction loss, cap perforation, black spots, and opaque bubble layer which lead to cap lenticular adhesions and retained lenticule. Regarding the postoperative complications of SMILE procedure, they are similar to all laser refractive procedures and include epithelial ingrowth, dry eye, diffuse lamellar keratitis, corneal haze, irregular astigmatism, minor interface infiltrates, increased aberrations, and iatrogenic ectasia [50, 51].

3. Intraocular correction of myopia

Two basic intraocular procedures exist: phakic intraocular lens (pIOL) implantation and refractive lens exchange (RLE) with posterior chamber IOL implantation.

3.1 Phakic intraocular lenses

Phakic intraocular lenses (pIOL) provide a safe and effective alternative for young patients with moderate to high refractive errors who may not be suitable candidates for excimer laser procedures or who prefer a reversible form of vision correction with efficacy comparable to results of LASIK [52]. It has been established that attempted corrections of high myopia with excimer laser procedures induce more higher-order aberrations, affecting vision quality and creating problems such as glare, halos, and ghost imaging [53]. Additional advantages of intraocular procedures are a broader range of treatable ametropia, faster visual recovery, more stable refraction, and better visual quality. In addition, the pIOL implantation does not affect accommodation, and the procedure is reversible [52, 54].

Currently, there are two types of phakic intraocular lenses approved for correcting refractive errors: anterior chamber—iris fixated—and posterior chamber. Verisyse and Veriflex lenses are iris-fixated intraocular lenses. More than 160,000 of these lenses have been safely implanted worldwide [55]. The Verisyse pIOL is made from rigid, ultraviolet-absorbing polymethyl methacrylate (PMMA). This lens requires a 5.5–6.5-mm incision, depending on the optic size of the lens, whereas the Veriflex pIOL requires a 3.2-mm incision. The Verisyse pIOL is available for myopia, hypermetropia, and astigmatism. For myopia, the pIOL is available in powers from -1.00 to -23.50 D in 0.50 D steps with two optic diameters of 5.0 or 6.0 mm. The Veriflex pIOL is a foldable implant with 6.0 mm flexible optic made of hydrophobic polysiloxane and features a PMMA haptic. It is available only for myopia in powers ranging from -2.00 to -14.50 D in 0.50 D steps.

The Visian Implantable Collamer Lens (ICL) is a posterior chamber phakic intraocular lens resting in the ciliary sulcus. ICL is made from soft advanced collamer material and requires 3.2 mm incision. It is available for myopia, hypermetropia, and astigmatism. For myopia, the pIOL is available in powers from -0.50 to -18.00 D in 0.50 D steps with four lens diameters (12.1, 12.6, 13.2, 13.6 mm) and optical zone up to 6.1 mm.

3.1.1 Preoperative examination and indications for phakic intraocular lens implantation

The preoperative evaluation of a patient for pIOL is the same as for any kind of refractive procedure. Inclusion criteria are more than 21 years of age, refractive stability (<0.50 D of change) for at least 1 year, ACD ≥ 3.0 mm measured from endothelium, endothelial cell count >2300 cells/mm² (>2500 cell/mm² if <40 years of age, >2000 cells/mm² if >40 years of age), irido-corneal angle $\geq 30^\circ$ (at least grade II by gonioscopy examination), mesopic pupil size <6.00 mm, no anomaly of iris or pupil function, no evolving retinal pathology, absence of uveitis or any kind of ocular inflammation, and absence of glaucoma or any systemic immunological disorder [56, 57].

3.1.2 Intraocular lens power calculation and diameter selection

pIOL optic power is calculated with the software provided by the manufacturer. The calculation is based on the formula developed by van der Heijde [58]. The formula uses the patient's refraction at the 12-mm spectacle plane or the vertex refraction, the corneal keratometry dioptric power at its apex, and central ACD [59]. For Verisyse and Veriflex lenses, only one lens diameter is available, while for the ICL overall diameter depends on the ciliary sulcus diameter and should provide perfect stability with no excess of compression forces to the sulcus and allow correct vaulting. The ICL's diameter should be oversized 0.5–1.0 mm from the white-to-white (WTW)

measurements in myopic eyes and the same length or oversized 0.5 mm in hyperopic eyes. The internal diameter of the ciliary sulcus can be measured by ultrasound biometry (UBM) or can be approximated by horizontal WTW measurement obtained manually using a caliper or automatically by topographic or biometric devices [60].

3.1.3 Limitations and possible complications of phakic intraocular lenses

The complications relating to pIOLs can, at times, be more disabling than those from keratorefractive surgery. Night vision problems, corneal decompensation, glaucoma, cataract formation, dyscoria, uveitis, and endophthalmitis are potential complications after pIOL implantation. Night vision problems such as glare, halos, and diplopia are related to decentration of the pIOL and/or an optic diameter that is too small relative to the pupil size [61].

Surgically induced astigmatism is an issue primarily correlated with rigid Verisyse lenses and incision diameter. However, some investigators reported that the resulting surgically induced astigmatism (SIA) was less than expected [62, 63]. However, when compared with the Veriflex pIOL and ICL, the SIA was significantly higher [64].

Implantation of a pIOL, whether iris fixated or positioned in the posterior chamber, is associated with an accelerated decrease in endothelial cell density (ECD) [60]. Damage to the corneal endothelium may be due to the direct contact between pIOL and the inner surface of the cornea during implantation, from postoperative changes in pIOL position, or from subclinical inflammation, and direct toxicity to the endothelium. The magnitude of ECD loss after phakic intraocular lens implantation surpasses the expected natural annual decrease of 0.6% as reported in a 1997 benchmark study based on 42 adults [65]. Following implantation of an iris-claw phakic intraocular lens, the loss of ECD is highest during the first year varying between 0.75 and 7.2% [66]. Thereafter, the ECD loss continues without following an obvious pattern, to about 8.9% after 10 years. However, with an ICL the impact on the endothelium is claimed to be lower because the implant is placed in the posterior chamber further away from the endothelium itself. For the ICL the ECD loss is about 1.7% after 2 years [60] increasing to 6.2% after 8 years [54] and up to 19.75% after 12 years [67].

In our experience after ICL implantation, there is a linear decrease in ECD over a 3-year period, without any signs of exponential EC loss or reaching a plateau or stable ECD during this time (**Figure 5**).

With modern pIOL designs, increased intraocular pressure (IOP) seems to be relatively uncommon after 3 months postoperatively and is typically thought to be related to corticosteroid response [68]. Posterior chamber pIOLs cause narrowing of anterior chamber angle due to its position in ciliary sulcus, and its sizing (too long lenses which cause excessive vaulting >750 μm) is closely correlated with possible angle-closure glaucoma, pupillary block glaucoma, or pigmentary dispersion glaucoma [69, 70]. Given the risk of pupillary block, peripheral iridectomy or iridotomy is carried out as a preventative measure in anterior pIOL procedures, while in newer models of ICL with aquaport, technology is not needed.

Pupil ovalization/iris retraction is mainly correlated with iris-fixated pIOL and can occur if fixation of the pIOL haptics is performed asymmetrically [61, 68, 71]. No progressive pupil ovalization has been reported.

Formation of cataract due to the iris-claw pIOL is unlikely because the pIOL is inserted over a miotic pupil without contact with the crystalline lens [61]. The incidence of cataract formation was 1.1% for the iris-fixated pIOL. The overall incidence of cataract formation for posterior chamber pIOLs was 9.60%, which is significantly higher in comparison to iris-fixated pIOLs [72]. With various generations of the ICL, appearance of cataract formation is different. The less vaulted

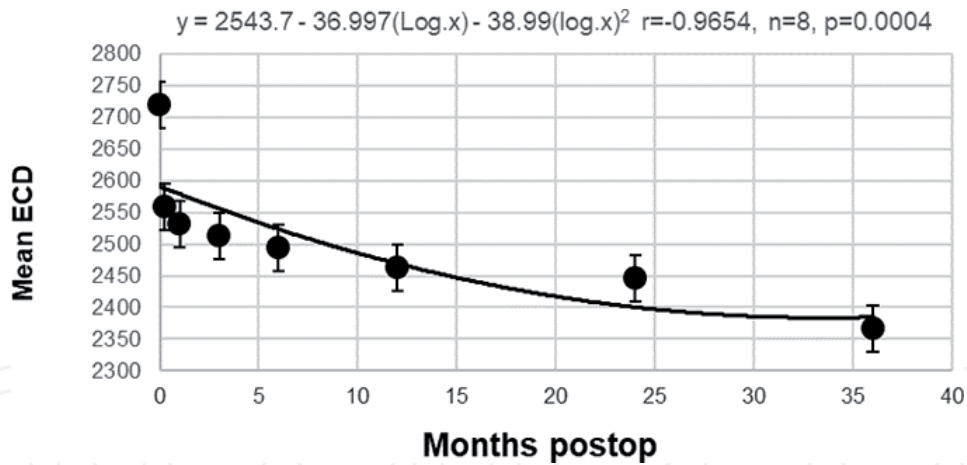


Figure 5. Mean endothelial cell density during the 3-year follow-up (28 eyes); \pm SD error bars are included indicating the variance in the data.

model V3 caused a higher incidence of cataract formation than the newer V4 and V5 models [73]. With the V4 model, the recently published FDA study showed an incidence of 2.1% anterior subcapsular opacities, which is the most common type of cataract after pIOL [59]. Possible reasons are operative trauma, continuous or intermittent contact of the posterior chamber pIOL with the crystalline lens, insufficient nutrition through anterior chamber flow between the posterior chamber pIOL and the crystalline lens, and chronic subclinical inflammation with disruption of the blood-aqueous barrier due to friction between the pIOL and posterior iris or the haptic on the ciliary sulcus [74–76].

The risk of uveitis is a concern given the proximity of pIOLs to the iris, but it does not seem to be a significant long-term complication with modern designs. With iris-fixated pIOLs, a difficulty with enclavation of the iris can lead to iris atrophy and decentration of the implant [52]. Retinal detachment seems to be uncommon and lower than in clear lens extraction cases [68, 77]. A few cases of endophthalmitis have been reported after pIOL implantation, but it seems less common after pIOL implantation and then after cataract surgery [78, 79].

3.2 Refractive lens exchange

Refractive lens exchange (RLE) is by definition used to indicate the replacement of the cataractous/clear crystalline lens with an intraocular lens (IOL) to achieve emmetropia/near emmetropia. The improved efficacy, predictability, and safety of modern-day phacoemulsification have resulted in a resurgence of lens extraction as a modality for correction of high myopia. Increased numbers of RLE are being performed worldwide, especially in patients not suitable for LASIK or pIOL or with early lens changes in the presbyopia age group [80, 81]. Optics of the IOL confer better quality of vision as compared with LASIK, and this optical quality does not degrade with time except in the presence of a posterior capsular opacification. The refractive results are predictable and stable with a larger range of refractive correction possible than with either LASIK or pIOL. RLE addresses refractive error and cataract and with the use of modern multifocal IOLs results in a significant degree of spectacle independence for the patient. Visual recovery is faster, and it is more cost-effective, as the higher cost of pIOLs and future cataract surgery is eliminated. The principles of surgery are in the domain of most cataract/anterior segment surgeons [82].

Overall, patient satisfaction scores after implantation of multifocal IOLs are high. For example, using a 0–10 self-recording analogue scale, you can expect

Postop uncorrected distance visual acuity and patient satisfaction.
Zeiss Trifocal, n= 52, Spearman rho= 0.558, p<0.001
Zeiss Bifocal n= 48, Spearman rho= 0.725, p<0.001

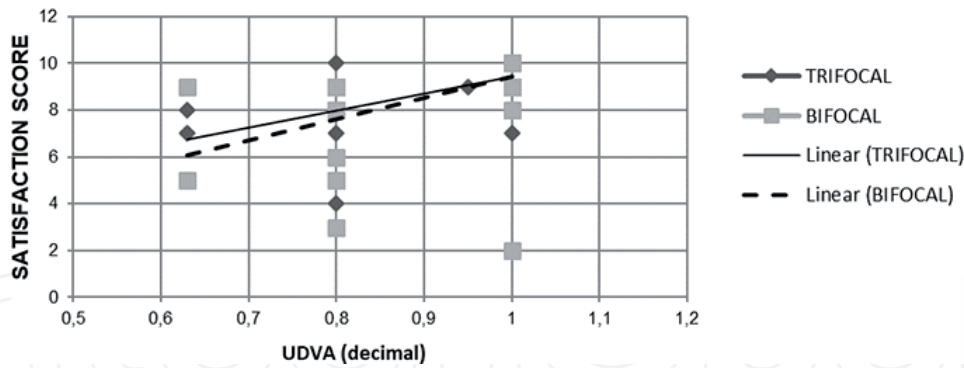


Figure 6.
Postoperative uncorrected distance visual acuity and patient satisfaction after RLE with implantation of multifocal IOLs.

typical average satisfaction scores of 8.8 (Zeiss bifocal IOL, n = 48, range 2–10) and 9.00 (Zeiss trifocal IOL, n = 52, range 4–10). On closer examination satisfaction scores are closely linked to post-op uncorrected distance and intermediate, visual acuity as demonstrated in **Figure 6**.

Advanced technology multifocal IOLs tend to be less forgiving with respect to the surgical technique, multifocal IOL power selection, ocular comorbidities, and patient selection. Comorbidities such as dry eye, vitreomacular pathology, or implant decentration may be tolerated in patients after a monofocal IOL implantation. However, these are much less tolerated by the multifocal IOL patients [83, 84].

Presbyopia-correcting intraocular lenses should provide post-op emmetropia for the best visual outcome, as small amounts of residual refractive errors can limit visual performance and jeopardize the result [85].

3.2.1 Preoperative examination and indications for refractive lens exchange

In evaluating the highly myopic patient, several aspects apart from the routine cataract/refractive surgery assessment should be noted. A detailed past ocular history is important, as previous refractive surgery or phakic intraocular lens implants or retinal problems (e.g., vitrectomy for previous retinal detachment) will affect lens formula choices and their final prognosis. Preoperative assessment should also include a detailed clinical examination of their lens status (e.g., cataract density and any zonular weakness) and refraction status of both eyes, as well as a dilated examination of the fovea and periphery for any retina disorder (e.g., myopic choroidal neovascular membrane, macular schisis, retinal tears, or detachment). Other issues for discussion include the potential use of toric or multifocal IOLs. Ideally, a larger haptic platform toric lens should be used in high myopes to reduce the risk of postoperative lens rotation, as the capsular bag is often large and floppy. In some cases, the use of a capsular tension ring to stretch the capsular bag may be required to prevent rotations. Multifocal IOLs should only be used in an eye with no retinal disorder [86].

Inclusion criteria are more than 40 years of age with myopia not amenable to conventional laser refractive surgery (e.g., high refractive error, corneal irregularities, thin cornea) or phakic IOLs (e.g., shallow anterior chamber, poor endothelial cell count, early cataract changes), presbyopic myopic patients who want reasonable independence from glasses for both distance, and near-vision, myopic patients with early lens changes who desire refractive correction [80, 86]. For multifocal IOL it is important to rule out any irregularities of iris or pupil function, evolving retinal pathology, absence of uveitis, or any kind of ocular inflammation.

3.2.2 Limitations and possible complications of refractive lens exchange

The commonest disadvantage is the loss of accommodation with the need for near-vision glasses in the cases of monofocal IOL and the inherent risk associated with intraocular surgery, especially in high myopes [80]. The risk for endophthalmitis in general cataract surgery with implantation of a posterior chamber IOL is 0.1–0.7% with an optimal antiseptic perioperative treatment regimen [87]. Lens surgery is significantly more challenging in a highly myopic eye for several reasons. The issues that we take for granted in an eye of normal length (22–25 mm) such as the accuracy of axial length measurements and the choice of lens formula become a significant issue in the highly myopic eye as the predicted refractive outcomes are not achieved consistently. Axial length measurement error has been largely overcome by the use of optical interferometry. Despite this, consistent hyperopic errors are still reported. Improved predictive results are obtained with the Barrett Universal II (software constants), Haigis (ULIB), SRK/T, Holladay 2 (software constants), and Olsen (software constants) formulas in eyes with axial lengths greater than 26.0 mm and IOL powers greater than 6.0 D. In the eyes with axial lengths greater than 26.0 mm and IOL less than 6.00 D, the Barrett Universal II formula (software constants) and the Haigis (axial length adjusted) and Holladay 1 formulas (axial length adjusted) should be used [88, 89].

Intraoperatively, a highly myopic eye is surgically more challenging as the anterior chamber is deeper, with a floppy and large capsular bag and occasionally zonular weakness [90]. The anterior chamber is often unstable, and it is even less stable in a previously vitrectomized high myopic patient. There is also a concern that with elongated axial lengths, there is a higher risk of bag instability that can cause impaired vision, and the more complicated the IOL design is, the more sensitive the IOL is to final centration. A study by Soda et al. found that in uncomplicated cataract surgery with an IOL in the bag, the maximum decentration can be 0.3 mm for a satisfying result [91]. In addition, it is reported that myopic patients may exhibit worse results with more reported subjective symptoms and measurable aberrations like coma and glare in mesopic and scotopic lighting conditions compared to non-myopic controls, after multifocal IOL implantation with approximately the same amount of decentration [91]. RLE may increase the risk for retinal detachment and is generally not considered in myopic pre-presbyopic patients who can still accommodate.

The incidence of retinal detachment is especially high among younger age groups (<50 years) and in the eyes with long axial length > 26 mm. The reported incidence of retinal detachment after RLE ranges from 2 to 8%. Meticulous surgery with minimal intraoperative vitreous disturbance and a regular follow-up postoperatively until the occurrence of posterior vitreous detachment can reduce the risk of retinal detachment further. With the higher risk of retinal detachment in younger patients, it is prudent to defer RLE in patients younger than 40 years if possible [92].

Other possible causes of unfavorable visual outcome after uncomplicated phacoemulsification are cystoid macular edema (CME) and choroidal neovascular membrane (CNVM). Overall incidence of subclinical CME diagnosed with optical coherence tomography (OCT) is 5%, and incidence of clinical CME is 3%; however, high myopia does not increase the risk of CME [93]. Reported incidence of CNVM after RLE for myopia is 12.5% [94]; however, whether this was related to the higher degree of myopia with preexisting lacquer crack that was missed or due to some inflammatory mediators and free radicals released after surgery cannot be conclusively proved. Because the reported incidence of CNVM after uncomplicated phacoemulsification is not high, we assume that it is secondary to the degree of myopia,

and it is prudent to perform OCT preoperatively in all RLE patients, especially those with more than 10 D of myopia. The presence of a myopic CNVM in the fellow eye is also considered as a risk factor for developing CNVM in the operated eye [80, 94].

4. Conclusions

Surgical treatment of myopia is a viable, safe, efficient, and predictable method for treating patients with myopia. There are several options of surgical treatment; we as doctors must always use our best judgment and available data to make sure we recommend the best method for each patient and their respective needs while taking into account any possible risk and contraindications. Among elective procedures in medicine, myopia treatment is one of the most commonly performed surgeries because of the positive effect it brings the patients' quality of life.

Author details

Maja Bohac^{1,2*}, Maja Pauk Gulic^{1,2}, Alma Biscevic^{1,2} and Ivan Gabric^{1,2}

1 Specialty Eye Hospital Svjetlost, Zagreb, Croatia

2 School of Medicine, University of Rijeka, Croatia

*Address all correspondence to: maja.bohac@svjetlost.hr

IntechOpen

© 2019 The Author(s). Licensee IntechOpen. This chapter is distributed under the terms of the Creative Commons Attribution License (<http://creativecommons.org/licenses/by/3.0>), which permits unrestricted use, distribution, and reproduction in any medium, provided the original work is properly cited. 

References

- [1] Fan DSP, Rao SK, Cheung EYY, Islam M, Chew S, Lam DSC. Astigmatism in Chinese preschool children: Prevalence, change, and effect on refractive development. *The British Journal of Ophthalmology*. 2004;**88**: 938-941. DOI: 10.1136/bjo.2003.030338
- [2] Dolgin E. The myopia boom. *Nature*. 2015;**519**:276-278. DOI: 10.1038/519276a
- [3] Holden BA, Fricke TR, Wilson DA, Jong M, Naidoo KS, Sankaridurg P, et al. Global prevalence of myopia and high myopia and temporal trends from 2000 through 2050. *Ophthalmology*. 2016;**123**:1036-1042. DOI: 10.1016/j.ophttha.2016.01.006
- [4] Reinstein DZ, Archer TJ, Gobbe M. The history of LASIK. *Journal of Refractive Surgery*. 2012;**28**:291-298. DOI: 10.3928/1081597X-20120229-01
- [5] Ehlers N, Hjortdal JO. Excimer laser refractive keratectomy for high myopia. 6-month follow-up of patients treated bilaterally. *Acta Ophthalmologica*. 1992;**70**:578-586
- [6] Rosman M, Alió JL, Ortiz D, Perez-Santonja JJ. Comparison of LASIK and photorefractive keratectomy for myopia from -10.00 to -18.00 diopters 10 years after surgery. *Journal of Refractive Surgery*. 2010;**26**:168-176. DOI: 10.3928/1081597X-20100224-02
- [7] Sia RK, Coe CD, Edwards JD, Ryan DS, Bower KS. Visual outcomes after Epi-LASIK and PRK for low and moderate myopia. *Journal of Refractive Surgery*. 2012;**28**:65-71. DOI: 10.3928/1081597X-20111004-01
- [8] Ambrósio R, Wilson S. LASIK vs LASEK vs PRK: Advantages and indications. *Seminars in Ophthalmology*. 2003;**18**:2-10
- [9] Ghadhfan F, Al-Rajhi A, Wagoner MD. Laser in situ keratomileusis versus surface ablation: Visual outcomes and complications. *Journal of Cataract and Refractive Surgery*. 2007;**33**:2041-2048. DOI: 10.1016/j.jcrs.2007.07.026
- [10] Hofmeister EM, Bishop FM, Kaupp SE, Schallhorn SC. Randomized dose-response analysis of mitomycin-C to prevent haze after photorefractive keratectomy for high myopia. *Journal of Cataract and Refractive Surgery*. 2013;**39**:1358-1365. DOI: 10.1016/j.jcrs.2013.03.029
- [11] Gimbel HV, DeBroff BM, Beldavs RA, van Westenbrugge JA, Ferensowicz M. Comparison of laser and manual removal of corneal epithelium for photorefractive keratectomy. *Journal of Refractive Surgery*. 1995;**11**:36-41
- [12] von Jagow B, Kohnen T. Corneal architecture of femtosecond laser and microkeratome flaps imaged by anterior segment optical coherence tomography. *Journal of Cataract and Refractive Surgery*. 2009;**35**:35-41. DOI: 10.1016/j.jcrs.2008.09.013
- [13] Reinstein DZ, Archer TJ, Randleman JB. Mathematical model to compare the relative tensile strength of the cornea after PRK, LASIK, and small incision lenticule extraction. *Journal of Refractive Surgery*. 2013;**29**:454-460. DOI: 10.3928/1081597X-20130617-03
- [14] Guerin MB, Darcy F, O'Connor J, O'Keefe M. Excimer laser photorefractive keratectomy for low to moderate myopia using a 5.0 mm treatment zone and no transitional zone: 16-year follow-up. *Journal of Cataract and Refractive Surgery*. 2012;**38**(7):1246-1250. DOI: 10.1016/j.jcrs.2012.03.027
- [15] Sekundo W, Kunert KS, Blum M. Small incision corneal refractive surgery using the small incision lenticule extraction (SMILE) procedure for the correction of myopia and myopic

- astigmatism: Results of a 6 month prospective study. *The British Journal of Ophthalmology*. 2011;**95**:335-339. DOI: 10.1136/bjo.2009.174284
- [16] Wu D, Wang Y, Zhang L, Wei S, Tang X. Corneal biomechanical effects: Small-incision lenticule extraction versus femtosecond laser-assisted laser in situ keratomileusis. *Journal of Cataract and Refractive Surgery*. 2014;**40**:954-962. DOI: 10.1016/j.jcrs.2013.07.056
- [17] Thompson V, Gordon M. Use of the excimer laser in refractive surgery. *Seminars in Ophthalmology*. 1994;**9**:91-96
- [18] Carr J, Hersh P, Tsubota K. Patient evaluation for refractive surgery. In: Azar D, editor. *Refractive Surgery*. 2nd ed. Philadelphia: Elsevier Inc.; 2007. pp. 81-88. DOI: 10.1016/B978-0-323-03599-6.50068-7
- [19] Morse JS, Schallhorn SC, Hettinger K, Tanzer D. Role of depressive symptoms in patient satisfaction with visual quality after laser in situ keratomileusis. *Journal of Cataract and Refractive Surgery*. 2009;**35**:341-346. DOI: 10.1016/j.jcrs.2008.10.046
- [20] Nourouzi H, Rajavi J, Okhovatpour MA. Time to resolution of corneal edema after long-term contact lens wear. *American Journal of Ophthalmology*. 2006;**142**:671-673. DOI: 10.1016/j.ajo.2006.04.061
- [21] Chuck RS, Jacobs DS, Lee JK, Afshari NA, Vitale S, Shen TT, et al. Refractive errors and refractive surgery preferred practice pattern[®]. *Ophthalmology*. 2018;**125**:P1-P104. DOI: 10.1016/j.ophtha.2017.10.003
- [22] Cua IY, Pepose JS. Late corneal scarring after photorefractive keratectomy concurrent with development of systemic lupus erythematosus. *Journal of Refractive Surgery*. 2002;**18**:750-752
- [23] Simpson RG, Moshirfar M, Edmonds JN, Christiansen SM, Behunin N. Laser in situ keratomileusis in patients with collagen vascular disease: A review of the literature. *Clinical Ophthalmology*. 2012;**6**:1827-1837. DOI: 10.2147/OPTH.S36690
- [24] Fraunfelder FW, Rich LF. Laser-assisted in situ keratomileusis complications in diabetes mellitus. *Cornea*. 2002;**21**:246-248
- [25] Sharma S, Rekha W, Sharma T, Downey G. Refractive issues in pregnancy. *The Australian & New Zealand Journal of Obstetrics & Gynaecology*. 2006;**46**:186-188. DOI: 10.1111/j.1479-828X.2006.00569.x
- [26] Seiler T, Koufala K, Richter G. Iatrogenic keratectasia after laser in situ keratomileusis. *Journal of Refractive Surgery*. 1998;**14**:312-317
- [27] Hodge C, Lawless M, Sutton G. Keratectasia following LASIK in a patient with uncomplicated PRK in the fellow eye. *Journal of Cataract and Refractive Surgery*. 2011;**37**:603-607. DOI: 10.1016/j.jcrs.2010.12.036
- [28] Randleman JB, Woodward M, Lynn MJ, Stulting RD. Risk assessment for ectasia after corneal refractive surgery. *Ophthalmology*. 2008;**115**:37-50. DOI: 10.1016/j.ophtha.2007.03.073
- [29] Santhiago MR, Smadja D, Wilson SE, Krueger RR, Monteiro MLR, Randleman JB. Role of percent tissue altered on ectasia after LASIK in eyes with suspicious topography. *Journal of Refractive Surgery*. 2015;**31**:258-265. DOI: 10.3928/1081597X-20150319-05
- [30] Cobo-Soriano R, Beltrán J, Baviera J. LASIK outcomes in patients with underlying systemic contraindications: A preliminary study. *Ophthalmology*. 2006;**113**. DOI: 1118.e1-8. doi:10.1016/j.ophtha.2006.02.023

- [31] Arora T, Sharma N, Arora S, Titiyal JS. Fulminant herpetic keratouveitis with flap necrosis following laser in situ keratomileusis: Case report and review of literature. *Journal of Cataract and Refractive Surgery*. 2014;**40**:2152-2156. DOI: 10.1016/j.jcrs.2014.09.018
- [32] Ahn H, Kim J-K, Kim CK, Han GH, Seo KY, Kim EK, et al. Comparison of laser in situ keratomileusis flaps created by 3 femtosecond lasers and a microkeratome. *Journal of Cataract and Refractive Surgery*. 2011;**37**:349-357. DOI: 10.1016/j.jcrs.2010.08.042
- [33] Farah S, Ghanem R, Azar D. LASIK complications and their management. In: Azar D, editor. *Refractive Surgery*. 2nd ed. Philadelphia: Elsevier Inc.; 2007. pp. 195-221
- [34] Rush SW, Cofoid P, Rush RB. Incidence and outcomes of anterior chamber gas bubble during femtosecond flap creation for laser-assisted in situ keratomileusis. *Journal of Ophthalmology*. 2015;**2015**:542127. DOI: 10.1155/2015/542127
- [35] Stonecipher KG, Dishler JG, Ignacio TS, Binder PS. Transient light sensitivity after femtosecond laser flap creation: Clinical findings and management. *Journal of Cataract and Refractive Surgery*. 2006;**32**:91-94. DOI: 10.1016/j.jcrs.2005.11.015
- [36] Carpel EF, Carlson KH, Shannon S. Folds and striae in laser in situ keratomileusis flaps. *Journal of Refractive Surgery*. 1999;**15**:687-690
- [37] Samuel MA, Kaufman SC, Ahee JA, Wee C, Bogorad D. Diffuse lamellar keratitis associated with carboxymethylcellulose sodium 1% after laser in situ keratomileusis. *Journal of Cataract and Refractive Surgery*. 2002;**28**:1409-1411
- [38] Kaufman SC. Post-LASIK interface keratitis, Sands of the Sahara syndrome, and microkeratome blades. *Journal of Cataract and Refractive Surgery*. 1999;**25**:603-604
- [39] Linebarger EJ, Hardten DR, Lindstrom RL. Diffuse lamellar keratitis: Diagnosis and management. *Journal of Cataract and Refractive Surgery*. 2000;**26**:1072-1077
- [40] Sonmez B, Maloney RK. Central toxic keratopathy: Description of a syndrome in laser refractive surgery. *American Journal of Ophthalmology*. 2007;**143**:420-427.e2. DOI: 10.1016/j.ajo.2006.11.019
- [41] Miyai T, Yonemura T, Nejima R, Otani S, Miyata K, Amano S. Interlamellar flap edema due to steroid-induced ocular hypertension after laser in situ keratomileusis. *Japanese Journal of Ophthalmology*. 2007. DOI: 10.1007/s10384-006-0441-y
- [42] Llovet F, de Rojas V, Interlandi E, Martín C, Cobo-Soriano R, Ortega-Usobiaga J, et al. Infectious keratitis in 204 586 LASIK procedures. *Ophthalmology*. 2010;**117**:232.e1-4-238.e1-4. DOI: 10.1016/j.ophtha.2009.07.011
- [43] Caster AI, Friess DW, Schwendeman FJ. Incidence of epithelial ingrowth in primary and retreatment laser in situ keratomileusis. *Journal of Cataract and Refractive Surgery*. 2010;**36**:97-101. DOI: 10.1016/j.jcrs.2009.07.039
- [44] Albietz JM, Lenton LM, McLennan SG, McLennan SG. Chronic dry eye and regression after laser in situ keratomileusis for myopia. *Journal of Cataract and Refractive Surgery*. 2004;**30**:675-684. DOI: 10.1016/j.jcrs.2003.07.003
- [45] Myung D, Schallhorn S, Manche EE. Pupil size and LASIK: A review. *Journal of Refractive Surgery*. 2013;**29**:734-741. DOI: 10.3928/1081597X-20131021-02

- [46] Alió JL, Muftuoglu O, Ortiz D, Artola A, Pérez-Santonja JJ, de Luna GC, et al. Ten-year follow-up of photorefractive keratectomy for myopia of more than -6 diopters. *American Journal of Ophthalmology*. 2008;**145**:37-45. DOI: 10.1016/j.ajo.2007.09.009
- [47] Alió JL, Soria F, Abbouda A, Peña-García P. Laser in situ keratomileusis for -6.00 to -18.00 diopters of myopia and up to -5.00 diopters of astigmatism: 15-year follow-up. *Journal of Cataract and Refractive Surgery*. 2015;**41**:33-40. DOI: 10.1016/j.jcrs.2014.08.029
- [48] Santhiago MR, Giacomini NT, Smadja D, Bechara SJ. Ectasia risk factors in refractive surgery. *Clinical Ophthalmology*. 2016;**10**:713-720. DOI: 10.2147/OPHTH.S51313
- [49] Giri P, Azar DT. Risk profiles of ectasia after keratorefractive surgery. *Current Opinion in Ophthalmology*. 2017;**28**:337-342. DOI: 10.1097/ICU.0000000000000383
- [50] Chan C, Lawless M, Sutton G, Versace P, Hodge C. Small incision lenticule extraction (SMILE) in 2015. *Clinical and Experimental Optometry*. 2016;**99**:204-212. DOI: 10.1111/cxo.12380
- [51] Ivarsen A, Hjortdal JØ. Topography-guided photorefractive keratectomy for irregular astigmatism after small incision lenticule extraction. *Journal of Refractive Surgery*. 2014;**30**:429-432. DOI: 10.3928/1081597X-20140508-02
- [52] Huang D, Schallhorn SC, Sugar A, Farjo AA, Majmudar PA, Trattler WB, et al. Phakic intraocular lens implantation for the correction of myopia: a report by the American Academy of Ophthalmology. *Ophthalmology*. 2009;**116**:2244-2258. DOI: 10.1016/j.ophtha.2009.08.018
- [53] Applegate RA, Howland HC. Refractive surgery, optical aberrations, and visual performance. *Journal of Refractive Surgery*. 1997;**13**:295-299
- [54] Igarashi A, Shimizu K, Kamiya K. Eight-year follow-up of posterior chamber phakic intraocular lens implantation for moderate to high myopia. *American Journal of Ophthalmology*. 2014;**157**:532-539.e1. DOI: 10.1016/j.ajo.2013.11.006
- [55] Ghanem R, Azer D. Phakic intraocular lenses. In: Yanoff M, Augsburger JJ, editors. *Ophthalmology*. Edinburgh: Mosby, Elsevier; 2009, p. 186
- [56] Pineda-Fernández A, Jaramillo J, Vargas J, Jaramillo M, Jaramillo J, Galíndez A. Phakic posterior chamber intraocular lens for high myopia. *Journal of Cataract and Refractive Surgery*. 2004;**30**:2277-2283. DOI: 10.1016/j.jcrs.2004.03.035
- [57] Javitt JC, Tielsch JM, Canner JK, Kolb MM, Sommer A, Steinberg EP. National outcomes of cataract extraction. Increased risk of retinal complications associated with Nd:YAG laser capsulotomy. The Cataract Patient Outcomes Research Team. *Ophthalmology*. 1992;**99**:1487-1497; discussion 1497-8
- [58] Van Der Heijde GL. Some optical aspects of implantation of an IOL in a myopic eye. *European Journal of Implant Refractive Surgery*. 1989;**1**:245-248. DOI: 10.1016/S0955-3681(89)80082-6
- [59] Sanders DR, Vukich JA, Doney K, Gaston M, Implantable Contact Lens in Treatment of Myopia Study Group. U.S. Food and Drug Administration clinical trial of the Implantable Contact Lens for moderate to high myopia. *Ophthalmology*. 2003;**110**:255-266
- [60] Goukon H, Kamiya K, Shimizu K, Igarashi A. Comparison of corneal endothelial cell density and morphology after posterior chamber phakic

intraocular lens implantation with and without a central hole. *The British Journal of Ophthalmology*. 2017;**101**:1461-1465. DOI: 10.1136/bjophthalmol-2016-309363

[61] Kohnen T, Kook D, Morral M, Güell JL. Phakic intraocular lenses: Part 2: Results and complications. *Journal of Cataract and Refractive Surgery*. 2010;**36**:2168-2194. DOI: 10.1016/j.jcrs.2010.10.007

[62] Alió JL, Mulet ME, Shalaby AMM. Artisan phakic iris claw intraocular lens for high primary and secondary hyperopia. *Journal of Refractive Surgery*. 2002;**18**:697-707

[63] Menezo JL, Aviño JA, Cisneros A, Rodriguez-Salvador V, Martinez-Costa R. Iris claw phakic intraocular lens for high myopia. *Journal of Refractive Surgery*. 1997;**13**:545-555

[64] Couillet J, Guëll J-L, Fournié P, Grandjean H, Gaytan J, Arné J-L, et al. Iris-supported phakic lenses (rigid vs foldable version) for treating moderately high myopia: Randomized paired eye comparison. *American Journal of Ophthalmology*. 2006;**142**:909-916. DOI: 10.1016/j.ajo.2006.07.021

[65] Bourne WM, Nelson LR, Hodge DO. Central corneal endothelial cell changes over a ten-year period. *Investigative Ophthalmology and Visual Science*. 1997;**38**:779-782

[66] Chebli S, Rabilloud M, Burillon C, Kocaba V. Corneal endothelial tolerance after iris-fixated phakic intraocular lens implantation: A model to predict endothelial cell survival. *Cornea*. 2018;**37**:591-595. DOI: 10.1097/ICO.0000000000001527

[67] Moya T, Javaloy J, Montés-Micó R, Beltrán J, Muñoz G, Montalbán R. Implantable collamer lens for myopia: Assessment 12 years after

implantation. *Journal of Refractive Surgery*. 2015;**31**:548-556. DOI: 10.3928/1081597X-20150727-05

[68] Stulting RD, John ME, Maloney RK, Assil KK, Arrowsmith PN, Thompson VM, et al. Three-year results of Artisan/Verisyse phakic intraocular lens implantation. Results of the United States Food And Drug Administration clinical trial. *Ophthalmology*. 2008;**115**:464-472, e1. DOI: 10.1016/j.optha.2007.08.039

[69] Hoyos JE, Dementiev DD, Cigales M, Hoyos-Chacón J, Hoffer KJ. Phakic refractive lens experience in Spain. *Journal of Cataract and Refractive Surgery*. 2002;**28**:1939-1946

[70] García-Feijoó J, Alfaro IJ, Cuiña-Sardiña R, Méndez-Hernandez C, Del Castillo JMB, García-Sánchez J. Ultrasound biomicroscopy examination of posterior chamber phakic intraocular lens position. *Ophthalmology*. 2003;**110**:163-172

[71] Maloney RK, Nguyen LH, John ME. Artisan phakic intraocular lens for myopia: Short-term results of a prospective, multicenter study. *Ophthalmology*. 2002;**109**:1631-1641

[72] Chen L-J, Chang Y-J, Kuo JC, Rajagopal R, Azar DT. Metaanalysis of cataract development after phakic intraocular lens surgery. *Journal of Cataract and Refractive Surgery*. 2008;**34**:1181-1200. DOI: 10.1016/j.jcrs.2008.03.029

[73] Menezo JL, Peris-Martínez C, Cisneros A, Martínez-Costa R. Posterior chamber phakic intraocular lenses to correct high myopia: A comparative study between Staar and Adatomed models. *Journal of Refractive Surgery*. 2001;**17**:32-42

[74] Gonvers M, Bornet C, Othenin-Girard P. Implantable contact lens for moderate to high myopia: Relationship

of vaulting to cataract formation.
Journal of Cataract and Refractive Surgery.
2003;**29**:918-924

[75] Sánchez-Galeana CA, Smith RJ, Sanders DR, Rodríguez FX, Litwak S, Montes M, et al. Lens opacities after posterior chamber phakic intraocular lens implantation. *Ophthalmology*. 2003;**110**:781-785

[76] Lackner B, Pieh S, Schmidinger G, Hanselmayer G, Dejaco-Ruhswurm I, Funovics MA, et al. Outcome after treatment of ametropia with implantable contact lenses. *Ophthalmology*. 2003;**110**:2153-2161. DOI: 10.1016/S0161-6420(03)00830-3

[77] Güell JL, Morral M, Gris O, Gaytan J, Sisquella M, Manero F. Five-year follow-up of 399 phakic Artisan-Verisyse implantation for myopia, hyperopia, and/or astigmatism. *Ophthalmology*. 2008;**115**:1002-1012. DOI: 10.1016/j.ophtha.2007.08.022

[78] Chung JK, Lee SJ. Streptococcus mitis/oralis endophthalmitis management without phakic intraocular lens removal in patient with iris-fixated phakic intraocular lens implantation. *BMC Ophthalmology*. 2014;**14**:92. DOI: 10.1186/1471-2415-14-92

[79] Couto C, Rossetti S, Schlaen A, Hurtado E, D'Alessandro L, Goldstein DA. Chronic postoperative *Mycobacterium gordonae* endophthalmitis in a patient with phakic intraocular lens. *Ocular Immunology and Inflammation*. 2013;**21**:491-494. DOI: 10.3109/09273948.2013.824104

[80] Srinivasan B, Leung HY, Cao H, Liu S, Chen L, Fan AH. Modern phacoemulsification and intraocular lens implantation (refractive lens exchange) is safe and effective in treating high myopia. *Asia-Pacific Journal of Ophthalmology*. 2016;**5**:438-444. DOI: 10.1097/APO.0000000000000241

[81] Lundström M, Manning S, Barry P, Stenevi U, Henry Y, Rosen P. The European registry of quality outcomes for cataract and refractive surgery (EUREQUO): A database study of trends in volumes, surgical techniques and outcomes of refractive surgery. *Eye Vision*. 2015;**2**:8. DOI: 10.1186/s40662-015-0019-1

[82] Alio JL, Grzybowski A, El Aswad A, Romaniuk D. Refractive lens exchange. *Survival Ophthalmology*. Nov-Dec 2014;**59**(6):579-98. DOI: 10.1016/j.survophthal.2014.04.004. Epub 2014 May 9

[83] Braga-Mele R, Chang D, Dewey S, Foster G, Henderson BA, Hill W, et al. Multifocal intraocular lenses: Relative indications and contraindications for implantation. *Journal of Cataract and Refractive Surgery*. 2014;**40**:313-322. DOI: 10.1016/j.jcrs.2013.12.011

[84] Kamiya K, Hayashi K, Shimizu K, Negishi K, Sato M, Bissen-Miyajima H, et al. Multifocal intraocular lens explantation: A case series of 50 eyes. *American Journal of Ophthalmology*. 2014;**158**:215-220.e1. DOI: 10.1016/j.ajo.2014.04.010

[85] McNeely RN, Pazo E, Millar Z, Richoz O, Nesbit A, Moore TCB, et al. Threshold limit of postoperative astigmatism for patient satisfaction after refractive lens exchange and multifocal intraocular lens implantation. *Journal of Cataract and Refractive Surgery*. 2016;**42**:1126-1134. DOI: 10.1016/j.jcrs.2016.05.007

[86] Chong EW, Mehta JS. High myopia and cataract surgery. *Current Opinion in Ophthalmology*. 2016;**27**:45-50. DOI: 10.1097/ICU.0000000000000217

[87] Results of the Endophthalmitis Vitrectomy Study. A randomized trial of immediate vitrectomy and of intravenous antibiotics for the treatment of postoperative bacterial endophthalmitis. *Endophthalmitis*

Vitrectomy Study Group. *Archives of Ophthalmology*. 1995;**113**:1479-1496.

after cataract surgery. *Japanese Journal of Ophthalmology*. 2006;**50**:345-348.
DOI: 10.1007/s10384-006-0335-z

[88] Haigis W. Intraocular lens calculation in extreme myopia. *Journal of Cataract and Refractive Surgery*. 2009;**35**:906-911. DOI: 10.1016/j.jcrs.2008.12.035

[89] Yokoi T, Moriyama M, Hayashi K, Shimada N, Ohno-Matsui K. Evaluation of refractive error after cataract surgery in highly myopic eyes. *International Ophthalmology*. 2013;**33**:343-348. DOI: 10.1007/s10792-012-9690-6

[90] Fernández-Buenaga R, Alio JL, Pérez-Ardoy AL, Larrosa-Quesada A, Pinilla-Cortés L, Barraquer R, et al. Late in-the-bag intraocular lens dislocation requiring explantation: Risk factors and outcomes. *Eye*. 2013;**27**:795-801; quiz 802. DOI: 10.1038/eye.2013.95

[91] Soda M, Yaguchi S. Effect of decentration on the optical performance in multifocal intraocular lenses. *Ophthalmologica*. 2012;**227**:197-204. DOI: 10.1159/000333820

[92] Alio JL, Ruiz-Moreno JM, Shabayek MH, Lugo FL, Abd El Rahman AM, Alicante D. The risk of retinal detachment in high myopia after small incision coaxial phacoemulsification. *American Journal of Ophthalmology*. 2007;**144**:93-98. DOI: 10.1016/j.ajo.2007.03.043

[93] Vukicevic M, Gin T, Al-Qureshi S. Prevalence of optical coherence tomography-diagnosed postoperative cystoid macular oedema in patients following uncomplicated phaco-emulsification cataract surgery. *Clinical & Experimental Ophthalmology*. 2012;**40**:282-287. DOI: 10.1111/j.1442-9071.2011.02638.x

[94] Hayashi K, Ohno-Matsui K, Futagami S, Ohno S, Tokoro T, Mochizuki M. Choroidal neovascularization in highly myopic eyes