

# Transrectal Sonography in Prostate Cancer Detection - Our 25 Years Experience of Implementation

---

**Maričić, Antun; Valenčić, Maksim; Sotošek, Stanislav; Oguić, Romano;  
Ivančić, Aldo; Ahel, Juraj**

*Source / Izvornik:* **Collegium antropologicum, 2010, 34 supplement 2, 239 - 242**

**Journal article, Published version**

**Rad u časopisu, Objavljena verzija rada (izdavačev PDF)**

*Permanent link / Trajna poveznica:* <https://um.nsk.hr/um:nbn:hr:184:072794>

*Rights / Prava:* [In copyright](#)/[Zaštićeno autorskim pravom.](#)

*Download date / Datum preuzimanja:* **2024-12-31**



*Repository / Repozitorij:*

[Repository of the University of Rijeka, Faculty of  
Medicine - FMRI Repository](#)



# Transrectal Sonography in Prostate Cancer Detection – Our 25 Years Experience of Implementation

Antun Maričić<sup>1</sup>, Maksim Valenčić<sup>1</sup>, Stanislav Sotošek<sup>1</sup>, Romano Oguić<sup>1</sup>, Aldo Ivančić<sup>2</sup> and Juraj Ahel<sup>1</sup>

<sup>1</sup> Department of Urology, University Hospital of Rijeka, Rijeka, Croatia

<sup>2</sup> Department of Surgery, University Hospital of Rijeka, Rijeka, Croatia

## ABSTRACT

*Prostate cancer is a leading public health problem of male population in developed countries. Gold standard for prostate cancer diagnosis is true cut biopsy guided by transrectal ultrasound<sup>1–5</sup>. Aim of this study was to determine sensitivity, specificity, accuracy, positive and negative predictive value of transrectal sonography (TRUS) in prostate cancer detection. The analysis was made for two time periods, before and after routine implementation of prostate specific antigen (PSA) in prostate cancer diagnostics. From 1984 to 1993 TRUS guided prostate biopsy was performed in 564, and from 1994 to 2008 in 5678 patients. In the second period PSA was routinely used in prostate cancer diagnostics. In the first period by TRUS we have made an exact diagnosis of prostate cancer in 18.97% of patients what was confirmed by biopsy. 4.61% were false positive and 11.34% were false negative. In the second period prostate cancer was recognized in 30.34% of patients, confirmed by biopsy. False positive cases were 6.11% and false negative 29.31%. Sensitivity of transrectal sonography in the first period was 62.57%, specificity 94.2%, accuracy 86.2%, positive predictive value 80.45% and negative predictive value 87.72%. In the second period sensitivity was 50.87%, specificity 91.93%, accuracy 73.84%, positive predictive value 83.24% and negative predictive value 70.39%. Based on our experience we can conclude that prostate cancer is mostly found in the peripheral zone. Smaller tumors are hypoechoic and bigger tumors are hyperechoic. Prostate cancer lesions are impossible to differentiate from chronic prostatitis only by TRUS. Implementation of PSA has significantly decrease sensitivity, accuracy and negative predictive value of TRUS in prostate cancer detection. TRUS guided true cut biopsy is a gold standard in prostate cancer diagnostics.*

**Key words:** prostate cancer, sonography, biopsy

## Introduction

Prostate cancer is a major public health problem facing man today in all the developed countries<sup>1,2</sup>. Prostate cancer now outnumbers the lung cancer as the most common cancer in American men<sup>1,2</sup>. The incidence of prostate cancer is rapidly increasing in the Primorsko-Goranska County of Croatia<sup>2,3</sup>. Transrectal sonography (TRUS) guided true cut biopsy is a gold standard in prostate cancer diagnostics<sup>2,4–10</sup>. Ultrasound criteria to detect and characterize suspicious lesions for prostate cancer are controversial<sup>5,6</sup>. Sensitivity of TRUS in prostate cancer recognition is from 60–85%<sup>5–10</sup>. Retrospective studies have shown that in 24–30% of pathohistologically proven prostate cancer the ultrasonographic finding was not

uniform<sup>5–10</sup>. Most authors concord that the percentage of false positive and false negative findings is too high<sup>5–10</sup>. In 30% of cases there is an overlap between benign and malignant lesions of the prostate<sup>5</sup>.

Low positive predictive value for the presence of prostate cancer is the main weakness of TRUS<sup>5–10</sup>. To improve the capability of TRUS to find prostate cancer lesions an implementation of color Doppler, contrast enhancement and elastography was suggested<sup>5,6</sup>. The results are not encouraging<sup>5,6</sup>. Several studies have shown that taking the endosonographic morphology of the prostate into consideration for biopsy strategies may improve

the quality of the prostate biopsy<sup>5-10</sup>. Also, patients with suspicious lesions detected by TRUS have a higher risk of being diagnosed with prostate cancer<sup>5</sup>. A recent Korean study has shown that a scoring system for malignancy prediction developed for the characteristics of focal suspicious lesions as depicted on TRUS can help predict the outcome of TRUS guided biopsies<sup>5</sup>.

The aim of our study was to determine sensitivity, specificity, accuracy, positive and negative predictive value of transrectal sonography (TRUS) in prostate cancer detection at our Clinic in 25 years period.

### Patients and Methods

This retrospective study was approved by our Institutional Ethical Committee.

A total of 6,242 patients with or without prostate cancer who underwent systemic and targeted biopsies for suspicious lesions were included in this study. Biopsies were made by true cut method under transrectal sonography guidance. The TRUS guided biopsies were performed by urologists with more than 10 years of experience in the field. During 25 years we used several ultrasound scanners for TRUS but they were all equipped with a 4–9 MHz broadband curved array endocavitary transducer. Tissue samples were pathohistologically analyzed to confirm or exclude the diagnosis of prostate cancer. Patients were divided in two groups according to two time periods, before and after routine implementation of prostate specific antigen (PSA) in prostate cancer diagnostics. From 1984 to 1993 TRUS guided prostate biopsy was performed in 564, and from 1994 to 2008 in 5,678 patients. In the second period PSA was routinely used in prostate cancer diagnostics.

### Data Analysis

The data was elaborated and analyzed using Statistica 6.1 software package (StatSoft.Inc., Tulsa, OK, USA). For each time period the sensitivity, specificity, accuracy, positive and negative predictive value of transrectal sonography was calculated using standard statistical formulas. Statistic significance was calculated using

chi-squared test and  $p < 0.05$  was considered significant.

### Results

In the first period by TRUS we have made an exact diagnosis of prostate cancer (Figure 1) in 18.97% (107) of patients what was confirmed by biopsy. 4.61% (26) were false positive (Figure 2) and 11.34% (64) were false negative. In the second period prostate cancer was recognized in 30.34% (1723) of patients, confirmed by biopsy. False positive cases were 6.11% (347) and false negative 29.31% (1664). Sensitivity of transrectal sonography in the first period was 62.57%, specificity 94.2%, accuracy 86.2%, positive predictive value 80.45% and negative predictive value 87.72%. In the second period sensitivity was 50.87%, specificity 91.93%, accuracy 73.84%, positive predictive value 83.24% and negative predictive value 70.39%. Based on our experience prostate cancer is mostly found in the peripheral zone (Figure 3). Smaller tumors are hypoechoic and bigger tumors are hyperechoic.

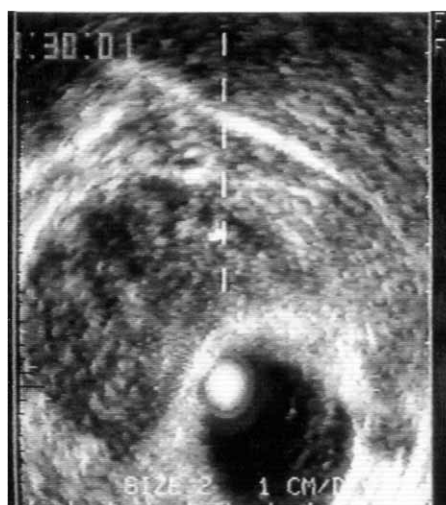

Fig. 2. Transrectal sonography showing a false positive finding in chronic prostatitis.

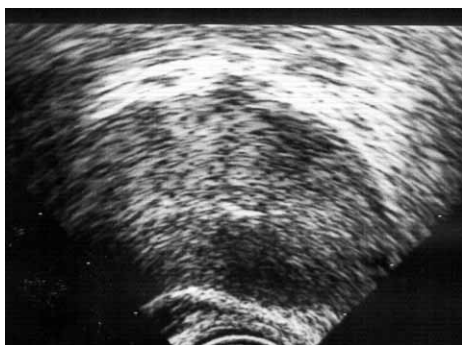

Fig. 1. Transrectal sonography showing two hypoechoic prostate cancer lesions in the left prostatic lobe

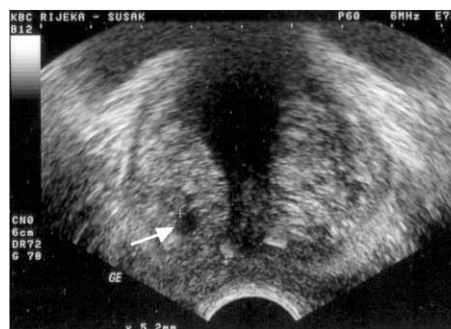


Fig. 3. Transrectal sonography showing a hypoechoic prostate cancer lesion (arrow) in the peripheral zone of the right prostatic lobe

Prostate cancer lesions are impossible to differentiate from chronic prostatitis only by TRUS. Implementation of PSA has significantly ( $p < 0.05$ ) decreased the sensitivity, accuracy and negative predictive value of TRUS in prostate cancer detection.

## Discussion and Conclusion

Our study has demonstrated that the sensitivity of transrectal sonography in the first period was 62.57%, specificity 94.2%, accuracy 86.2%, positive predictive value 80.45% and negative predictive value 87.72%. In the second period sensitivity was 50.87%, specificity 91.93%, accuracy 73.84%, positive predictive value 83.24% and negative predictive value 70.39%. The results from our study are consistent with findings of previous research. Sensitivity of TRUS in prostate cancer recognition is from 60–85 %<sup>5–10</sup>. Retrospective studies have shown that in 24–30% of pathohistologically proven prostate cancer the ultrasonographic finding was not uniform<sup>5–10</sup>. Most authors concord that the percentage of false positive and false negative findings is too high<sup>5–10</sup>. In 30% of cases

there is an overlap between benign and malignant lesions of the prostate<sup>5</sup>.

Low positive predictive value for the presence of prostate cancer is the main weakness of TRUS<sup>5–10</sup>. Our findings show that the implementation of PSA has significantly ( $p < 0.05$ ) decreased the sensitivity, accuracy and negative predictive value of TRUS in prostate cancer detection, probably do to more TRUS examinations in subclinical prostate cancers. In the first period PSA was not implemented in routine urological practice, so the majority of patients had a clinically manifested, advanced prostate cancer par example: positive digitorectal examination, pelvic pain, hematuria etc.

We also concluded that in most cases smaller tumors are hypoechoic and bigger tumors are hyperechoic. Prostate cancer lesions are impossible to differentiate from chronic prostatitis only by TRUS.

In conclusion transrectal sonography guided true cut biopsy is a gold standard in prostate cancer diagnostics. Only TRUS findings are not enough to make an accurate diagnosis of prostate cancer.

## REFERENCES

1. BOBINAC D, MARIC I, ZORIC S, SPANJOL J, DJORDJEVIC G, FUCKAR Z, Croat Med J, 46(3) (2004) 389. — 2. SPANJOL J, MARICIC A, CICVARIC T, VALENCIC M, OGUIC R, TADIN T, FUCKAR D, BOBINAC M, Coll Antropol, 31(1) (2007) 235. — 3. SPANJOL J, MARICIC A, VALENCIC M, OGUIC R, KRPINA K, PROTIC A, IVANCIC A, BOBINAC M, FUCKAR D, VOJNIKOVIC B, Coll Antropol, 32(Suppl 2) (2008) 79. — 4. BOCZKO J, MESSING E, DOGRA V, Rad Clinics of N Am, 44(5) (2006) 679. — 5. LEE HY, LEE HJ, BYUN SS, LEE SE, HONG SK, KIM

SH, Korean J Radiol, 10(3) 2009 244. — 6. OEHR P, BOUCHELOUCHE K, Curr Opinion in Oncol, 19 (2007) 259. — 7. FUCKAR Z, DIMEC D, CURUVIJA D, An Klin Bol »Dr.M.Stojanović«, 58 (Supl) (1991) 23. — 8. TANG J, YANG JC, LI YM, LI JL, SHI HY, J Ultrasound, 26(12) (2007) 1671. — 9. SEN J, CHOUDHARY L, MARWAH S, GODARA R, MARWAH N, SEN R, Asian J Surg, 31(1) (2008) 16. — 10. AIGNER F, PALLWEIN L, MITTERBERGER M, PINGGERA GM, MIKUZ G, HORNINGER W, FRAUSCHER F, BJU Inter, 103(4) (2009) 458.

A Maricic

Department of Urology, University Hospital of Rijeka, T. Strizica 3, 51000 Rijeka, Croatia  
e-mail: antun.maricic@ri.t-com.hr

## TRANSREKTALNI ULTRAZVUK U OTKRIVANJU KARCINOMA PROSTATE – NAŠE 25-GODIŠNJE ISKUSTVO U KORIŠTENJU

### SAŽETAK

Karcinom prostate je vodeći javno-zdravstveni problem muške populacije u razvijenim zemljama. Ključna dijagnostička metoda u postavljanju konačne dijagnoze je biopsija prostate pod kontrolom transektalnog ultrazvuka. Cilj ove studije bio je utvrđivanje senzitivnosti, specifičnosti, sigurnosti te pozitivne i negativne prediktivne vrijednosti transektalne sonografije u detekciji karcinoma prostate. Analiza je rađena u dva razdoblja ovisno o primjeni prostata specifičnog antigena u dijagnostici karcinoma prostate. Od 1984. do 1993 godine biopsija prostate vođena transektalnim ultrazvukom učinjena je u 564, a od 1994. do 2008. godine u 5678 bolesnika. Od 1994. kao rutinska dijagnostička metoda korištena je i serumska koncentracija prostata specifičnog antigena (PSA). U prvom razdoblju u 18.97% bolesnika transektalnom sonografijom postavili smo dijagnozu karcinoma prostate što je potvrđeno biopsijom. Lažno pozitivnih bilo je 4.61%, a lažno negativnih 11.34%. U drugom razdoblju karcinom prostate prepoznat je u 30.34% bolesnika što je potvrđeno biopsijom. Lažno pozitivnih bilo je 6.11%, a lažno negativnih 29.31%. Senzitivnost transektalne sonografije u prvom razdoblju bila je 62.57%, specifičnost 94.2%, sigurnost 86.2%, pozitivna prediktivna vrijednost 80.45% te negativna prediktivna vrijednost 87.72%. U drugom razdoblju senzitivnost je bila 50.87%, specifičnost

91.93%, sigurnost 73.84%, pozitivna prediktivna vrijednost 83.24% te negativna prediktivna vrijednost 70.39%. Temeljem našeg iskustva možemo zaključiti kako se karcinom prostate otkriva uglavnom uz kapsulu. Mali tumori su hipoehogeni dok su veći, uznapredovali hiperehogeni. Karcinom prostate nemoguće je transrektalnom sonografijom razlikovati od kroničnog prostatitisa. Uporaba PSA smanjila je značajno senzitivnost, sigurnost i negativnu prediktivnu vrijednost transrektalne sonografije u otkrivanju karcinoma prostate. Ultrazvučno vođena transrektalna biopsija prostate zlatni je standard u dijagnostici karcinoma prostate.