

Primary Non-Hodgkin's Lymphoma of the Humerus Presenting as Osteomyelitis

Bralić, Marina; Stemberga, Valter; Cuculić, Dražen; Čoklo, Miran; Bulić, Oriano; Grgurević, Emina; Bosnar, Alan

Source / Izvornik: **Collegium antropologicum, 2008, 32 - Supplement 2, 229 - 231**

Journal article, Published version

Rad u časopisu, Objavljena verzija rada (izdavačev PDF)

Permanent link / Trajna poveznica: <https://um.nsk.hr/um:nbn:hr:184:885880>

Rights / Prava: [In copyright](#)/[Zaštićeno autorskim pravom.](#)

Download date / Datum preuzimanja: **2025-02-07**



Repository / Repozitorij:

[Repository of the University of Rijeka, Faculty of Medicine - FMRI Repository](#)



Primary Non-Hodgkin's Lymphoma of the Humerus Presenting as Osteomyelitis

Marina Bralić¹, Valter Stemberga², Dražen Cuculić², Miran Čoklo², Oriano Bulić³, Emina Grgurević⁴ and Alan Bosnar²

¹ Department of Neurology, University Hospital »Rijeka«, Rijeka, Croatia

² Department of Forensic Medicine, School of Medicine, University of Rijeka, Rijeka, Croatia

³ General Hospital »Pula«, Pula, Croatia

⁴ Department of Radiology, University Hospital »Rijeka«, Rijeka, Croatia

ABSTRACT

We report a case of primary non-Hodgkin's lymphoma of the humerus that occurred in a 21-year-old male patient. A previously healthy man presented with the history of severe pain and a differential diagnosis from osteomyelitis to malignant lesion was suspected. A biopsy was performed and the final pathologic diagnosis was a diffuse large B-cell lymphoma. The patient was treated for lymphoma only with radiotherapy. To date, the patient remains tumor free 10 years after the onset of the disease.

Key words: primary bone lymphoma, osteomyelitis, radiotherapy

Introduction

Primary lymphoma of the bone is a rare condition that has been described as a malignant neoplasm formed of lymphoid and myelopoietic tissues¹. In most series, it is responsible for approximately 3% of primary bone tumors. It has predilection for long bones: the femur is the most common site (especially the metadiaphysis) and is affected in 25% of cases. Other sites include the pelvis, humerus, head and neck, and tibia². Primary bone lymphoma occurs in a broad range of patients, aged 1 year to 86 years (median range, 36–52 years), with a peak prevalence among patients in the 6th to 7th decades of life^{3,4}.

We report a case of malignant lymphoma of the bone that was initially misdiagnosed and treated as chronic osteomyelitis, but was finally proven to be diffuse large B-cell lymphoma.

Case Report

A 21-year-old man presented with pain in the shoulder which had lasted for approximately 8 months, becoming severe over the past 3 to 4 months. Clinically the pa-

tient was well with no history of fevers, sweats, weight loss or fatigue. On examination he was normotensive and had no palpable hepatosplenomegaly or lymphadenopathy. Chest radiograph was normal as was full blood count and biochemical profiles. The only medications being taken at the time of presentation were non-steroid anti-inflammatory drugs (NSAID). He was not known to have any other significant disorder. A screening X-ray of his right shoulder was interpreted as osteomyelitis and the patient was treated accordingly (Figure 1). When he reported to our Hospital, he had already been treated for osteomyelitis without any response. Subsequent radiography studies were considered not to be plausible for osteomyelitis: X-ray revealed osteolysis of the proximal part of the humerus (Figure 2). Malignant lesion was suspected and open bone biopsy was performed. Examination of the biopsy specimen identified diffuse replacement of bone marrow elements by large atypical lymphocytes with large nuclei and a small amount of eosinophilic cytoplasm (Figure 3). Immunohistochemistry showed CD20 and CD79a positivity. The final pathologic diagnosis was a diffuse large B-cell lymphoma of the humerus.

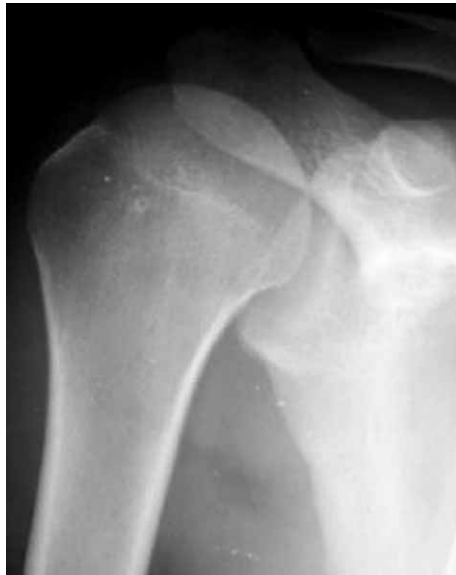

Fig. 1. Standard x-ray of the right shoulder reveals normal radiographic structure of the proximal humerus.

PCR revealed a monoclonal B-lymphocyte population. The patient was treated successfully with radiotherapy alone.

The patient has been doing well without any medication and he remains tumor-free 10 years after the diagnosis and treatment.

Discussion

Primary lymphoma of the bone is responsible for approximately 3% of primary bone tumors and 5% of all cases of extra-nodal non-Hodgkin's lymphomas. Moreover, less than 10% of patients presenting with bone lymphomas have a solitary lesion^{1,5}.

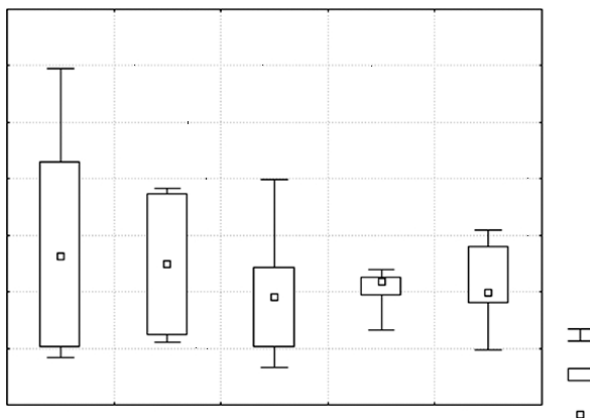


Fig. 2. X-ray shows patchy ill-defined bone destruction in the proximal metaphysis of the humerus with wide zone of transition suggesting aggressive nature of the lesion. Note discrete periosteal new bone formation.

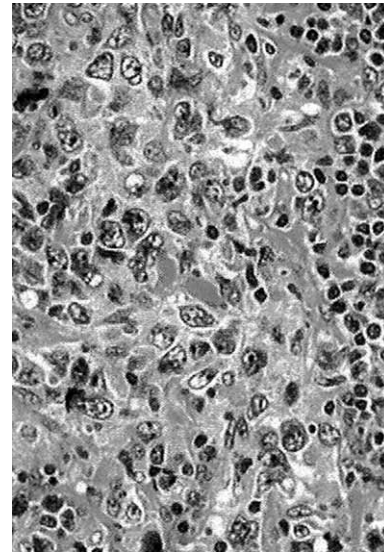


Fig. 3. Microscopically (H & E staining, x400), malignant lymphoma demonstrates area of large neoplastic cells with polymorphic nucleus mixed with reactive small lymphocytes.

According to studies, primary non-Hodgkin's lymphoma of the bone has a predilection for long bones and the femur is the most common site. Most often they were located in the long bones (48%), of which seven localizations (12%) presented in the upper limb. The data demonstrate that primary lymphoma involving the bone has an excellent prognosis. Patients with PBL treated with combined modality versus single modality therapy were found to have a superior outcome, with a significantly better survival³.

In accordance with histological classification and immunohistochemistry, almost all lymphomas (92%) were large B-cell lymphomas according to the Revised European-American Lymphoma (REAL) classification².

Although pain represents the leading symptom, it can mislead during diagnose settings, as in our patient. In order to set the right diagnosis, extensive evaluation is required for the patients presenting with pain⁶⁻⁹. Thus, persistent pain of the bone has to be managed in the context of a broad differential diagnosis.

Features of the primary lymphoma of the bone may be identified as inflammatory, neuropathic, infectious, or other conditions of the extremities. Since radiographic features are nonspecific, the diagnosis cannot be determined based on radiographic findings alone. In this report, the early characterization of the mass-like features is emphasized, helping to raise the suspicion of a neoplastic disease.

To establish a diagnosis, biopsy has to be performed along with MR imaging. On T1- weighted images the high signal intensity of bone marrow contrasts with the areas of low signal intensity corresponding to the lesion, allowing an early diagnosis and accurate staging¹⁰. T1-weighted pulse sequences are the best (compared with other sequences) for demonstrating marrow changes, as

T1-weighted images reveal areas of low signal intensity within the marrow. Osteolytic lesions and pathological fractures were reported in an approximately one quarter of the cases, pathologically related to weakened replace cortex^{10,11}. Most patients have a normal blood picture in the early stage of the disease. None of the above conditions existed in our patient^{2,10,12}.

Although its incidence peaks in patients in their fifth decade, primary lymphoma of the bone can occur in younger patients, as in our patient¹.

Non-Hodgkin's lymphoma of the bone is slightly more common in men than women and prognosis depends on the grade of the tumor at the time of diagnosis. Reported 5-year survival rates are better than 90%². The case we

present is consistent with the literature, as our patient has no signs of disease more than 10 years after the diagnosis and treatment.

This case confirms that although quite uncommon, primary lymphoma of the bone must be included in the list of differential diagnoses.

Conclusion

Physicians should be aware that lymphoma could rarely present as a bone tumor, and that the absence of signs of systemic disease does not exclude the diagnosis of lymphoma.

REFERENCES

1. OSTROWSKI ML, UNNI KK, BANKS PM, SHIVES TC, EVANS RG, O'CONNELL MJ, *Cancer*, 58 (1986) 2646. — 2. RAMADAN KM, SHENKIER T, SEHN LH, GASCOYNE RD, CONNORS JM, *Ann Oncol*, 18 (2007) 129. — 3. BEAL K, ALLEN L, YAHALOM J, *Cancer*, 106 (2006) 2652. — 4. HORSMAN JM, THOMAS J, HOUGH R, HANCOCK B, *Int J neol*, 28 (2006) 1571. — 5. KOCLJANČIĆ K, KOCLJANČIĆ I, *Coll Antropolo*, 30 (2006) 925. — 6. BREKALO Z, KVESIĆ A, GALIĆ G, KUKIĆ-BRUSIĆ S, MARTINOVIĆ V, JONOVSKA S, *Coll Antropol*, 31 (2007) 1183. — 7. AJDUK M, MIKULIĆ D, SEBECIĆ B, GASPAROV S, PATRLJ L,

ERDELEZ L, SKOPLJANAC A, STARESINIĆ M, DESKOVIĆ S, SOSA T, SITIĆ S, *Coll Antropol*, 28 (2004) 937. — 8. HORZIĆ M, SALAMON A, KOPLJAR M, SKUPNJAK M, CUPURDIJA K, VANJAK D, *Coll Antropol*, 29 (2005) 133. — 9. Božić B, Rotim K, Houra K, *Coll Antropol*, 32 (2008) 195. — 10. BARBIERI E, CAMMELLI S, MAURO F, PERINI F, CAZZOLA A, NERI S, *Int J Radiat Oncol Biol Phys*, 59 (2004) 760. — 11. MULLIGAN ME, MCRAE GA, MURPHEY MD, *Am J Roentgenol*, 173 (1999) 1691. — 12. VINCENT JM, NG YY, NORTON AJ, ARMSTRONG P, *Clin Radiol*, 45 (1992) 407.

M. Bralić

*Department of Neurology, University Hospital »Rijeka«, Krešimirova 42, 51000 Rijeka, Croatia
e-mail: bralic_marina@yahoo.com*

PRIMARNI NON-HODGKIN LIMFOM HUMERUSA PREZENTIRAN KAO OSTEOMIJELITIS

SAŽETAK

Prikazan je slučaj primarnog non-Hodgkin limfoma humerusa koji se pojavio kod 21-godišnjeg muškarca. Radilo se o prethodno zdravom čovjeku s anamnezom jake boli i postavljenom diferencijalnom dijagnozom od osteomijelitisa do maligne lezije. Učinjena je biopsija, s konačnom patohistološkom dijagnozom difuznog velikostaničnog B limfoma. Pacijent je liječen isključivo radioterapijom, te je do danas, 10 godina nakon pojave bolesti, bez znakova maligne bolesti.