

Spontaneous fetal skull fractures - an unsolved issue?

Petrović, Oleg; Despot, Đuro; Bilić Čače, Iva; Cuculić, Dražen

Source / Izvornik: **Archives of Obstetrics and Gynecology, 2020, 1, 20 - 23**

Journal article, Published version

Rad u časopisu, Objavljena verzija rada (izdavačev PDF)

<https://doi.org/10.36879/AOG.20.000120>

Permanent link / Trajna poveznica: <https://um.nsk.hr/um:nbn:hr:184:492991>

Rights / Prava: [Attribution-NonCommercial-NoDerivatives 4.0 International/Imenovanje-Nekomercijalno-Bez prerada 4.0 međunarodna](#)

Download date / Datum preuzimanja: **2025-03-02**



Repository / Repozitorij:

[Repository of the University of Rijeka, Faculty of Medicine - FMRI Repository](#)



Spontaneous fetal skull fractures – An unsolved issue?

Oleg Petrović^{1*}, Đuro Despot¹, Iva Bilić-Čaće² and Dražen Cuculić³

¹Department of Gynecology and Obstetrics, Clinical Hospital Center RIJEKA, Croatia

²Department of Pediatrics, Clinical Hospital Center RIJEKA, Croatia

³Department of Forensic Medicine and Criminalistics, University of Rijeka, Faculty of Medicine, Croatia

Abstract

Background: Spontaneous skull fractures are particularly interesting due to the vague circumstances of their occurrence. number of risk factors and several hypothetical pathophysiological mechanisms of fetal skull fractures are considered by different authors. Obstetric providers are generally unable to convincingly explain occurrence of the spontaneous fetal skull injuries. Apart from scientific and professional significance, fetal fractures may have medico-legal implications for obstetricians and midwives because their spontaneous occurrence in the majority of cases is exceedingly difficult to prove. The aim of the article is to investigate some new risk factors and mechanisms of spontaneous fetal skull fracture occurrence and to recommend measures for their prevention.

Discussion: Based on two case reports of spontaneous depressed fetal skull fractures under different circumstances authors have discussed potential new risk factors and relevant pathophysiological mechanisms of spontaneous skull fractures. An understanding of risk factors and the mechanism(s) contributing to spontaneous skull injuries, may provide medical professionals with significant knowledge in assisting both the prevention of new cases and in court proceedings. The purpose is to assist those obstetric practitioners accused of potential malpractice, in addition to medical experts involved in adjudicating any potential cases for malpractice. The main reasons why the real causes of birth injuries in a certain number of cases cannot be detected, are identified.

Conclusion: The authors anticipate that with new evidence and additional practical recommendations (a timely written and carefully detailed medical history, the strict indications for medical interventions, and an introduction of video surveillance in delivery rooms) will initiate a broad professional discussion which might help many obstetric providers to pay attention to risk factors and mechanisms, so that potential fetal/neonatal skull fractures could be avoided. Additionally, the benefits for obstetric practitioners who are accused of potential malpractice and for medical experts who may adjudicate it, cannot be understated.

Keywords: fetal skull fractures, fetus, vaginal birth, birth trauma, obstetric trauma, risk factors, obstetric providers

Introduction

Fetal skull fractures are usually divided into fractures associated with instrumental deliveries and spontaneous occurrences [1]. Spontaneous fractures are much less common than the former and particularly interesting due to vague circumstances of their occurrence. Undoubtedly, even spontaneous fractures are caused by some kind of force, but they are called “spontaneous”, as they are evidently not related to any doctor’s or midwife’s action before birth. From the clinicians perspective, three types of skull fractures can be distinguished: linear, depressed, and occipital osteodistasis [2]. Depressed skull fracture should be differentiated from the depression of the skull bone without a fracture, which is known as “ping pong fracture” [3]. The parietal bones are the most commonly affected site, followed by the frontal bones and very rarely the occipital ones. Spontaneous depressed skull fractures in neonates are very rare and the incidence is estimated at 4-10 per 100 000 live births in western countries [1,4]. It can be assumed that there is not a single obstetrician in the entire world who would be spared from seeing birth injuries including skull fractures. We were motivated to write this article by a very recent case of fetal skull fracture after spontaneous term vaginal birth in our department. The aim of this paper is to clarify potential mechanisms of spontaneous fracture occurrence by using data from literature and individual case reports and to urge obstetric providers to pay attention to risk factors, so that potential fetal skull fractures can be avoided. .

Case Presentations

The first case was a very recent case of a 37-year old multiparous woman, G4P3, who was referred to our maternity ward after an uneventful term pregnancy, reporting regular contractions for the previous three hours. Obstetric examination revealed fully dilated cervix with bulging membranes and anterior asynclitic position of the fetal head. A rupture of membranes was performed. There was a small amount of meconium stained amniotic fluid. Without any additional force, pushing was encouraged and a female baby with “nuchal cord”, weighing 3180 grams, was delivered spontaneously after 20 minutes. Apgar scores were 4 and 7 at 1 and 5 minutes, respectively. There was no evidence of bruising or fetal scalp edema. The newborn was gasping, pale, hypotonic, with a heart rate below 100/min. Following inflation breaths and a couple of ventilation breaths via T-piece resuscitator, the newborn cried, heart rate increased and she turned pink. Cord venous blood gasses were pH 7.28, HCO₃ 16.7 mEq/L, BE -8.9 mmol/L, lactate level unknown. She was admitted to the Neonatal Intensive Care Unit. Her vital signs were normal, as well as physical and neurological examinations. Capillary blood gasses two hours after birth showed compensated metabolic acidosis with lactate level increased to 10.5 mmol/L. Repeated blood gasses two hours afterwards were normal (lactate level 4.5 mmol/L). In the ninth hour of life, seizures appeared in a form of left arm clonic movements with autonomic signs - flushing, salivation and alterations in heart rate.

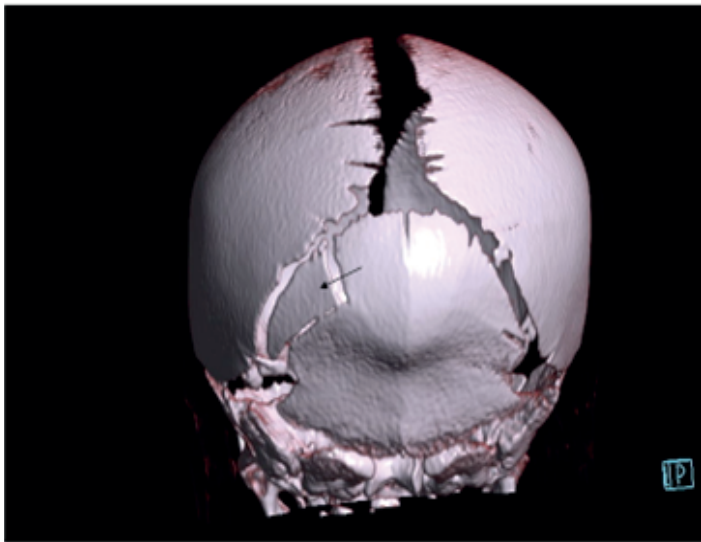


Figure 1. Head CT scan demonstrates very clearly a depressed fracture of the left side of the newborn's occipital bone (arrow)

Loading dose of *Phenobarbitone* was administered, amplitude-integrated EEG (aEEG) monitoring and diagnostic evaluation was commenced. An urgent CT scan of the cranium revealed no signs of ischemia or intracranial bleeding. However, a depressed fracture of the left side of the occipital bone was found (Figure 1). An initial cranial ultrasound was normal. Continuous monitoring revealed normal trace, with no signs of seizures. There was no need for immediate neurosurgical treatment. Multi-channel video EEG monitoring was done on the fifth day of life and demonstrated asymmetries with paroxysmal epileptiform discharges on the anterior right area. Control CT scan showed no changes within intracranial structures, with occipital fracture remaining unchanged. She was discharged from the hospital on the 10th day without any treatment. A controlled neuropediatric examination, EEG monitoring and a cranial MRI after one month were normal.

The second childbearing woman, a 31-year old primigravida at 32 gestational weeks, was injured in a traffic accident as a co-driver. Immediately after the incident, her right upper arm was noticed to be broken. She denied a blow to the abdomen and did not complain of pain or bleeding. She was ceased to feel any fetal movements after the car accident. A few hours later, the abdominal ultrasound scan revealed a live female fetus in good condition with biometry parameters corresponding to 32 weeks of gestation. Placenta was inserted on the posterolateral wall of the uterus and no signs which would indicate its abruption could be noticed. Amniotic fluid was normal. Obstetric examination was unremarkable. The following day, a repeated ultrasound scan revealed intrauterine fetal demise. Vaginal birth was induced and a dead female fetus was delivered, weighing 1760 grams. Autopsy demonstrated left parietal bone fracture, severe brain edema and intracranial hemorrhage.

Discussion

Spontaneous depressed fetal skull fractures are exceedingly rare events in delivery rooms. In a retrospective case-control study of nearly 2 000 000 newborns, the authors reported 68 cases of depressed skull fractures, which gives an incidence of 1 per 29 400 live births. Among these cases, only 18 (26.4%) were spontaneous fractures, of which 8 newborns were delivered vaginally and 10 by cesarean section [4]. Bhat et al. found only 4 (11.4%) depressed skull fractures among 35 neonatal fractures in a group of 34 946 live deliveries [5]. We presented two such cases among 64 718 live

births (1 per 32 360) during a 23-year period, from January 1998 to August 2020.

Based on these case reports of depressed fetal skull fractures, we have tried to present a comprehensive knowledge about spontaneous skull fractures and explain the possible pathophysiological mechanisms of their occurrence. Though it may seem like an easy task, it certainly is not, primarily due to their very low incidence, which makes it difficult to draw reliable conclusions. Furthermore, obstetric providers who are actively involved in such deliveries, are generally unable to convincingly explain the causes of subsequently confirmed skull fractures. Therefore, it is widely considered, particularly among non-professionals, that in these obstetric cases doctors and/or midwives attempt to disguise or hide their mistakes due to fear of prosecution and court penalties.

Although all kinds of fetal skull fractures are rare, professionals who have witnessed them, remember these tragic events for a long time. These can happen prenatally before contractions, at elective/urgent cesarean deliveries, or more frequently during advanced stages of the birth process. If there is a clinical doubt, a diagnosis of the fracture can be made relatively easily by imaging methods [6]. Thus, in our first case, a head CT revealed an unrecognized occipital bone fracture after the first onset of neurological symptoms. However, radiological imaging cannot differentiate “instrument - associated” skull fractures from the spontaneous ones. A clear absence of bruises, superficial wounds, and subcutaneous edema supports a reasonable assumption, that the injury has occurred without anyone's involvement. Hence, the most interesting and important questions when it comes to spontaneous skull fractures, relates to the causes and underlying mechanisms of these uncommon clinical situations which are not completely understood. To date, all knowledge about this perinatalogic issue is based mostly on published case reports or small groups of patients. Logically, in the absence of larger studies, any new information is useful and welcome.

It should be emphasized that the need for the right answers arises not only from scientific and academic significance but also from practical ones. Namely, fetal fractures may have medico-legal implications for obstetricians, despite their spontaneous occurrence in the majority of cases, which is very difficult to prove. Actually, after the lawsuit was filed due to evident damage, doctors, midwives, and medical institutions have an obligation to find out appropriate evidence that could absolve them of criminal and financial liabilities. In these circumstances, reliable knowledge of the mechanism(s) of injury could be of greatest help in both court proceedings as well as in the prevention of new cases. It could also help the medical experts, who are given the opportunity to be more objective and more skilled to evaluate such cases, without a naive belief that all birth injuries are the result of purely inappropriate force applied by a doctor or midwife. It is good to know that common clinical characteristics of spontaneous depressed skull fractures show undamaged skin and subcutaneous tissue, absence of intracranial bleeding, and an intact fetal/neonatal brain. The first neurological symptoms are caused by the pressure of broken skull bone on brain tissue and brain edema, as highlighted in our first case.

Several hypothetical pathophysiological mechanisms of fetal skull fractures are considered. Many reports indicate that pregnant women are most injured in traffic accidents as drivers or co-drivers [7,8]. It has to be emphasized that external mechanical force is crucial for the great majority of intrauterine fetal fractures, and particularly skull fractures, except in cases of some genetic syndromes and congenital disorders [9]. Accordingly, a car accident was the direct cause of fetal skull fracture, brain damage,

and placental abruption in our second case with late fetal demise. While placental abruption can be explained by strong pressure of the seat belt on a focal area of the maternal abdomen and gravid uterus, the acceleration – deceleration movements of fetal head in amniotic fluid caused by sudden impact, as in this case, could be an assumed mechanism of intrauterine skull injury. Namely, a relatively large and heavy fetal head continues moving after a sudden stop of the mother's body because of its inertia, hitting the wall of the uterus. Predisposing factors are weak calvarial bones due to immature ossification and a thick uterine wall in early gestational ages, most commonly before 34 weeks.

In a comparative study the authors reported that depressed skull fractures are associated only with obstetrician's maneuvers and the application of forceps [10]. In some later investigations authors advocate, in the absence of instrument application, prolonged and gradually accentuated mechanical forces, actually increase uterine contractions during birthing process, and perform an excessive and direct pressure upon the soft fetal skull bones (parietal, frontal or occipital) against the rigid mother's pelvic bones (pubic symphysis, sacral promontory, ischial spines, abnormal pelvis), rather than an isolated and strong impact [4,6,11,12]. The local pressure should exceed the strength of the fetal skull bone with a consequence of spontaneous bone fracture. In this group of potential causes, uterine fibromyomas and some parts of fetal organism are also mentioned [6,13]. In our opinion, no less likely is a theory of careless and violent digital examination with a purpose to correct malrotation or deflexion of fetal head at the bottom of birth canal resulting in a strong pressure applied to a small area of skull bone which could fracture. Most probably, a similar mechanism exists during elective and/or emergency cesareans when an obstetrician is trying to extract a deeply engaged fetal head through the narrow uterotomy by pressing fetal parietal bone with only one or two fingers separated from each other. Such a case was presented by Brittain et al. who found a depressed fracture of the right parietal bone without bruising in term newborn after emergency cesarean [14]. There is also a possibility to break fetal skull bone during midwife's or obstetrician's inappropriate effort to deliver fetal head by forced external deflexion with an excessive pressure by using the occipital bone instead of suboccipital fossa as a hypomochlion. In view of this, it is highly likely that at least in some cases of the fetal/neonatal skull injuries, which are classified as spontaneous ones, a doctor's or midwife's responsibility might exist. We think that a lack of detailed and correct descriptions of the course of labor, applied obstetric interventions and their complications in medical documentations is one of the main reasons why the real causes of birth injuries in a certain number of cases could not be identified.

Apart from understanding the pathophysiological mechanism(s) of fetal skull fractures, the best strategy is to try to prevent them. Spontaneous fetal/neonatal skull fractures are a special perinatal issue that occurs in significantly different conditions. There are number of risk factors that are commonly reported by different authors: macrosomia, cephalopelvic disproportion, fetal hypotrophy, preterm birth, vaginal breech birth, multiparity, prolonged second stage of labor, persistent occipito-posterior fetal position [2,8,15,16]. In our opinion, some other factors should be added to the list of risk factors. Due to a well-known pathologic birth mechanism, an unrecognized asynclitism associated with labor stimulation worsens the conditions which could result in parietal [17] or occipital bones fracture, as in our case. In some cases of shoulder dystocia, manual pressure on the skull bones can exceed their resistance, resulting in localized bone depression with or without fracture. [6,18,19].

The real question is whether skull fractures can be prevented at all. This refers primarily to fractures caused by external trauma to the pregnant woman's abdomen and during instrumentally assisted vaginal births. Pregnant women should behave rationally and avoid potentially dangerous situations of blows to the abdomen. Women who sustain abdominal trauma, should undergo a detailed ultrasound evaluation of the fetus and placenta. Considering obstetric operations with a purpose to end vaginal births, particularly the use of forceps, it has to be requested from all obstetricians to be more professional in defining the strict indications for medical interventions and to be more careful during its technical performance. Timely and carefully detailed medical histories are of paramount importance. Obstetricians and midwives should be aware of the relevant risk factors in order to prevent adverse health consequences. No less important is an immediate postnatal examination, if there is any clinical suspicion of possible injury. An introduction of video surveillance in delivery rooms with accompanying strict and clear rules for its professional use may allow more objective evaluation of the assumed mechanisms of the spontaneous fetal skull injuries.

Fortunately, in contrast to instrumentally caused fractures, spontaneous depressed skull fractures usually have a very good prognosis and no long-term neurological sequelae are expected [20]. A conservative approach is the first line of management. In the great majority of cases, only clinical observation and repeat radiological examinations are required. In our case, such conservative treatment was quite sufficient which was soon followed by full resolution. On the contrary, in select cases of associated serious bone depression and/or underlying intracranial injury, there is a need for neurosurgical consultation and adequate therapeutic interventions [21].

Conclusion

We anticipate that with evidence of potentially new risk factors (f.e. asynclitism, shoulder dystocia), relevant pathophysiological mechanisms and additional practical recommendations (a timely written and carefully detailed medical history, the strict indications for medical interventions, and an introduction of video surveillance in delivery rooms) will initiate a broad professional discussion which may help many obstetric providers give attention to risk factors, so that potential fetal/neonatal skull fractures can be avoided. Additionally, the benefits for obstetric practitioners who are accused of potential malpractice and for medical experts who may adjudicate it, cannot be understated.

References

1. Preston D, Jackson S, Gandhi S. Non-traumatic depressed skull fracture in a neonate or "ping pong" fracture. *BMJ Case Reports*. 2015
2. Doumouchtosis SK, Arulkamran S. Head injuries after instrumental vaginal deliveries. *Curr Opin Obstet Gynecol*. 2006; 18: 129-134.
3. Fantacci C, Massimi L, Capozzi D, Romano V, Ferrara P, Chiaretti A. "Spontaneous" ping-pong fracture in newborns: case report and review of the literature. *Signa Vitae*. 2015; 10: 103-109.
4. Dupuis O, Silveira R, Dupont C, Mottolese C, Kahn P, et al. Comparison of "instrument-associated" and "spontaneous" obstetric depressed skull fractures in a cohort of 68 neonates. *Am J Obstet Gynecol*. 2005; 192: 165-170.
5. Bhat BV, Kumar A, Oumachigui A. Bone injuries during delivery. *Indian J Pediatr*. 1994; 61: 401-405.
6. Arifin MZ, Gill AS, Anwar AD, Djuwantono T, Faried A. Spontaneous depressed skull fracture during vaginal delivery: A report of two cases and literature review. *Indian J Neurotrauma*. 2013; 10: 33-37.
7. Hartl R, Ko K. In utero skull fracture: case report. *J Trauma - Injury, Infection & Critical Care*. 1996; 41: 549-552.
8. Chaturvedi A, Chaturvedi A, Stanescu AL, Blickman JG, Meyers

- SP. Mechanical birth-related trauma to the neonate: an imaging perspective. *Insights Imaging*. 2018; 9: 103-118.
9. Morgan JA, Marcus PS. Prenatal diagnosis and management of intrauterine fracture. *Obstet Gynecol Survey*. 2010; 65: 249-259.
 10. Nadas S, Gudinchet F, Capasso P, Reinberg O. Predisposing factors in obstetrical fractures. *Skeletal Radiol*. 1993; 22: 195-198.
 11. Oh CK, Yoon SH. The significance of incomplete skull fracture in the birth injury. *Med Hypothesis*. 2010; 74: 898-900.
 12. Suneja U, Prokhorov S, Kandi S, Rajegowda B. Depressed skull fracture in a term newborn infant. *Pediatr Therapeut*. 2015;5:i.109; doi: 10.4172/2161-0665.1000i109
 13. Tovar-Spinoza ZS, Kim PD. Congenital depressed skull fracture in the absence of trauma: case report and literature review. *Resp Rep Neonatol*. 2012; 2: 11-14.
 14. Brittain C, Muthukumar P, Job S, Sanka S. "Ping pong" fracture in a term infant. *BMJ Case Reports*. 2012; doi: 10.1136/bcr.01.2012.5631
 15. Nadas S, Reinberg O. Obstetric fractures. *Eur J Pediatr Surg*. 1992; 2: 165-168.
 16. Cheng YW, Shaffer BL, Caughey AB. The association between persistent occiput posterior position and neonatal outcomes. *Obstet Gynecol*. 2006; 107: 837-844.
 17. Ghi T, Dall'Asta A, Kiener A, Volpe N, Suprani A, Frusca T. Intrapartum diagnosis of posterior asynclitism using two-dimensional transperineal ultrasound. *Ultrasound Obstet Gynecol*. 2017; 49: 803-808.
 18. Hansen A, Chauhan SP. Shoulder dystocia: definitions and incidence. *Semin Perinatol*. 2014; 38: 184-188.
 19. Dahlberg J, Nelson M, Dahlgren MA. Ten years of simulation-based shoulder dystocia training - impact on obstetric outcome, clinical management, staff confidence, and the pedagogical practice - a time series study. *BMC Pregnancy Childbirth*. 2018; 18: 361-368.
 20. McKee-Garrett TM. Neonatal birth injuries. *UpToDate*. 2020; www.uptodate.com
 21. Sherman CS. The Evolution of modern treatment for depressed skull fractures. *World Neurosurgery*. 2019; 121: 186-192.

Correspondence: Oleg Petrović, PhD, Professor, Department of Gynecology and Obstetrics, Perinatal Unit Clinical Hospital Center RIJEKA, Krešimirova 42, 51000 Rijeka, Croatia, Tel: +385 51 658 203, Fax: +385 51 338 555, E-mail: oleg@kbc-rijeka.hr

Rec: 21 Oct 2020; **Acc:** 10 Nov 2020; **Pub:** 14 Nov 2020

Arch Obs Gyn. 2020;1(4):120
DOI: [gsl.aog.2020.000120](https://doi.org/10.24015/2020.000120)

Copyright © 2020 The Author(s). This is an open-access article distributed under the terms of the Creative Commons Attribution 4.0 International License (CCBY).