

Rapid fatal acute peripheral T-cell lymphoma associated with IgG plasma cell leukemia and IgA hypergammaglobulinemia : case report

Jonjić, Nives; Seili-Bekafigo, Irena; Fučkar Čupić, Dora; Lučin, Ksenija; Duletić- Načinović, Antica; Valković, Toni

Source / Izvornik: **Applied immunohistochemistry & molecular morphology**, 2016, 24, e89 - e93

Journal article, Submitted version

Rad u časopisu, Rukopis poslan na recenzijski postupak (preprint)

<https://doi.org/10.1097/PAI.0000000000000361>

Permanent link / Trajna poveznica: <https://um.nsk.hr/um:nbn:hr:184:846403>

Rights / Prava: [Attribution-NonCommercial-NoDerivatives 4.0 International/Imenovanje-Nekomercijalno-Bez prerada 4.0 međunarodna](#)

Download date / Datum preuzimanja: **2024-08-07**



Repository / Repozitorij:

[Repository of the University of Rijeka, Faculty of Medicine - FMRI Repository](#)



**Rapid fatal acute peripheral T-cell lymphoma associated with IgG plasma cell leukemia and IgA
hypergammaglobulinemia**

Case report

Jonjić N¹, Seili Bekafigo I², Fučkar Čupić D¹, Lučin K¹, Duletić Načinović A³, Valković T³

¹Department of Pathology, Faculty of Medicine, University of Rijeka, Rijeka, Croatia

²Department of Cytology, Clinical Hospital Centre, Rijeka, Croatia

³Department of Hematology, Clinical Hospital Centre, Rijeka, Croatia

Corresponding author:

Prof. Ksenija Lucin, M.D., PhD

Department of Pathology

Medical Faculty

University of Rijeka

B. Branchetta 20

51000 Rijeka

Croatia

Telephone: 0038551325805

Fax: 0038551325810

e-mail: ksenija.lucin@medri.uniri.hr

Abstract

Simultaneous occurrence of T-cell and B-cell neoplasms is rare and etiologic relationships between these two malignancies are poorly understood. We describe a case of 66-year-old woman who was admitted to the hospital because of fever, hemoptysis, lymphadenopathy, and skin rash. Enlarged lymph nodes in the axillary, pectoral, paratracheal and periportal regions, as well as slight hepato- and splenomegaly were confirmed. Peripheral blood smear revealed rouleaux formation and numerous circulating plasma cells, with plasmacytoid lymphocytes. Immunofixation-electrophoresis detected a monoclonal band defined as IgG-lambda light chains with broad band polyclonal IgA. The patient died from abrupt splenic rupture before diagnostic work-up was finished. Postmortem examination revealed infiltration of atypical lymphoid cells exhibiting high proliferative activity admixed with typical and atypical plasma cells in several organs. Thus plasma cell leukemia (IgG-lambda) as a rare and aggressive variant of plasma cell myeloma in present case was associated with aggressive peripheral T cell lymphoma and polyclonal (IgA) plasmacytosis.

Keywords: Leukemia, plasma cell; Lymphoma, T cell, Hypergammaglobulinemia

Introduction

Simultaneous occurrence of T-cell and B-cell neoplasms is rare and etiologic relationships between these two malignancies are poorly understood. Most of the reported cases included cutaneous T-cell lymphoma (mycosis fungoides) with B-cell small lymphocytic lymphoma/chronic lymphocytic leukemia, either lymphoma type antedating the other (1, 2). Besides cutaneous T-cell lymphoma, cases of concurrent angiocentric T-cell lymphoma, peripheral T-cell lymphoma not otherwise specified (PTCL-NOS) and other peripheral T-cell non-Hodgkin's lymphomas (NHLs) with diffuse large B-cell lymphoma (DLBCL) or low grade B-cell NHLs have also been reported (3-5). Furthermore, cases of cutaneous T-cell lymphomas in association with clonal plasma cell proliferation have been described (6-9).

We describe a very unusual and until now unreported case of simultaneous occurrence of PTCL-NOS, primary IgG plasma cell leukemia (PCL) and polyclonal IgA hypergammaglobulinemia. Leukemia is

classified as primary when it is the initial presenting manifestation of plasma cell neoplasm, or secondary when it is seen in the context of refractory or relapsing disease of multiple myeloma. The diagnosis is based on the presence of clonal plasma cells in peripheral blood exceeding $2 \times 10^9/L$ or more than 20% of the nucleated peripheral blood cells count. In addition to peripheral blood and bone marrow, neoplastic plasma cells may be found in extramedullary tissue, such as spleen and liver, in pleural effusions and in peritoneal and cerebrospinal fluid (10). Thus, clinically, patients with primary PCL have a greater incidence of hepatosplenomegaly and lymphadenopathy, and fewer lytic bone lesions compared with multiple myeloma. PCL is an aggressive disease associated with poor prognosis and shorter survival than those in patients affected by typical multiple myeloma (11, 12).

Case report

A 66-year-old woman was admitted to the hospital because of fever, hemoptysis, lymphadenopathy, and skin rash. Her past medical history included therapy with lisinopril-hydrochlorothiazide and rosuvastatin due to arterial hypertension and hyperlipidemia. She denied any hematological diseases in the past. On examination, she was febrile, her blood pressure was 110/80 mm Hg, and pulse 100/min, with enlarged cervical and axillary lymph nodes not tender to palpation. The abdomen was not tender, the liver and spleen were not palpable with certainty. Multi-slice computed tomography of the thorax and abdomen revealed enlarged lymph nodes in the axillary, pectoral, paratracheal and periportal regions. Splenomegaly with a subcapsular wedge-shaped hypodense lesion measuring 15x10 mm was seen and the liver was slightly enlarged. Abdominal ultrasonography findings confirmed slight hepato - and splenomegaly, while abdominal lymph nodes were not seen due to meteorism. Radiological skeletal survey did not find evidence of osteolytic lesions.

Laboratory findings revealed normocytic anemia (Hb 84 g/L) and decreased platelet count ($26 \times 10^9/L$). Peripheral blood smear revealed rouleaux formations and numerous circulating plasma cells, accounting for 26% of all nucleated cells, as well as some proplasma and lymphoplasmacytoid cells (Fig. 1a). Serum electrophoresis showed M-peak, but also polyclonal hypergammaglobulinemia in the background. Immunofixation - electrophoresis detected a monoclonal band defined as IgG-lambda

light chains (IgG level, 37.2 g/L; normal range, 7.0-16.0 g/L) with broad band polyclonal IgA (IgA level, 29.4 g/L; normal range, 0.7-4.0 g/L) (Fig. 1b). The most important laboratory findings are shown in Table 1.

Bone marrow aspirate showed excess of plasma cells (35%), partly atypical. Bone marrow biopsy showed hypercellularity with focal and diffuse increase in CD138-positive cells (57%) (Fig. 1c), and lambda light chain restriction in plasma cells (Fig. 1d). There was no evidence of osteolytic lesions. Neck lymph node fine-needle aspiration biopsy (FNA) was suggestive of hematologic malignancy possibly originating from plasma cells. Some large lymphoid cells with lobulated nuclei, though, were negative for CD138 and CD20. Additional immunocytochemistry was not performed due to insufficient material.

All the time the patient was completely disabled, febrile, totally confined to bed. The patient died 18 days after hospital admission from abrupt splenic rupture before diagnostic work-up was finished.

Except for corticosteroids and supportive therapy, other specific treatment was not initiated.

Postmortem examination revealed pathologic findings in several organs. Lymph nodes were enlarged with affected architecture. Diffuse infiltrates were composed of polymorphous medium-sized and large lymphoid cells with irregular, pleomorphic nuclei exhibiting high proliferative activity, admixed with typical and atypical plasma cells (Fig. 2). Immunophenotyping revealed CD3 and CD4 positivity in atypical lymphocytes, while CD8, BCL-6, CD10 and PD-1 were negative. Scattered expression of CD30 was also present on large lymphocytes, while atypical plasma cells in lymph nodes were CD38 positive and mostly CD138 negative. In situ hybridization of Epstein-Barr virus (EBV) encoded RNA 1 detected EBV transcripts in rare lymphoid cells (Fig. 2). The spleen, liver and kidney were also infiltrated with atypical lymphocytes and plasma cells. Skin biopsy showed superficial and deep dermal infiltrate consisting of medium- to large-sized atypical cells with irregular nuclei, occasionally prominent nucleoli, variable chromatin pattern, and high mitotic activity. Atypical cells were mostly CD3 and CD4 positive, while CD30 revealed scattered large CD30 positive lymphocytes in the background of lymphocytes and rare neutrophils and eosinophils.

Bone marrow aspirate showed excess of plasma cells (35%), partly atypical. Bone marrow biopsy showed hypercellularity with focal and diffuse increase in CD138-positive cells (57%) (Fig. 1c), and

lambda light chain restriction in plasma cells (Fig. 1d). There was no evidence of osteolytic lesions. Neck lymph node fine-needle aspiration biopsy (FNA) was suggestive of hematologic malignancy possibly originating from plasma cells. Some large lymphoid cells with lobulated nuclei, though, were negative for CD138 and CD20. Additional immunocytochemistry was not performed due to insufficient material.

Postmortem examination revealed pathologic findings in several organs. Lymph nodes were enlarged with affected architecture. Diffuse infiltrates were composed of polymorphous medium-sized and large lymphoid cells with irregular, pleomorphic nuclei exhibiting high proliferative activity, admixed with typical and atypical plasma cells (Fig. 2). Immunophenotyping revealed CD3 and CD4 positivity in atypical lymphocytes, while CD8, BCL-6, CD10 and PD-1 were negative. Scattered expression of CD30 was also present on large lymphocytes, while atypical plasma cells in lymph nodes were CD38 positive and mostly CD138 negative. In situ hybridization of Epstein-Barr virus (EBV) encoded RNA 1 detected EBV transcripts in rare lymphoid cells (Fig. 2). The spleen, liver and kidney were also infiltrated with atypical lymphocytes and plasma cells. Skin biopsy showed superficial and deep dermal infiltrate consisting of medium- to large-sized atypical cells with irregular nuclei, occasionally prominent nucleoli, variable chromatin pattern, and high mitotic activity. Atypical cells were mostly CD3 and CD4 positive, while CD30 revealed scattered large CD30 positive lymphocytes in the background of lymphocytes and rare neutrophils and eosinophils.

Discussion

This case is presented for the rare concurrence of IgG PCL, PTCL-NOS and IgA hypergammaglobulinemia. Plasma cell neoplasm may coexist with other lymphoid malignancies, most commonly chronic lymphocytic leukemia and monoclonal B-cell lymphocytosis. Simultaneous occurrence with T-cell neoplasm is rare. When the development of malignancies is metachronous, they are usually diagnosed straightforward. On the other hand, synchronous detection of plasma cell neoplasm and lymphoid malignancy brings up a broad differential diagnosis.

In the present case, the first differential diagnostic challenge was the increased number of plasma cells in peripheral blood. Generally, the presence of plasma cells, plasmacytoid lymphocytes and

immunoblasts in the peripheral blood smear is suggestive of a reactive process. The latter may include bacterial or viral infections and autoimmune diseases. It is more rarely associated with a neoplastic process, as in angioimmunoblastic T-cell lymphoma (AITL) (13). These plasma cells are polyclonal in nature and should be distinguished from clonal proliferation. However, in our patient, serum immunofixation detected both polyclonal IgA plasma cell proliferation and clonal IgG. AITL is frequently associated with polyclonal B-cell or plasma cell proliferation, while clonal proliferation has been rarely reported (14-16). The B-cell expansion observed in AITL has been proposed to be related to the function of neoplastic follicular helper T cells.

In the case described, lymph nodes, spleen, bone marrow, liver, skin and other organs were infiltrated with typical and atypical plasma cells masking underlying lymphoma composed of atypical T lymphocytes. Thus, our second differential diagnosis included AITL as one of the most common subtypes of peripheral T-cell lymphoma commonly accompanied with polyclonal hypergammaglobulinemia, circulating plasma cells, plasmacytoid lymphocytes and immunoblasts. Even exuberant reactive plasmacytosis mimicking plasma cell leukemia (17-19) or simultaneous occurrence of AITL and plasma cell leukemia has been reported (20).

Morphologically, AITL is characterized by polymorphous infiltrates, atypical neoplastic T-cells, clear cells, and the presence of high endothelial and extrafollicular proliferation of follicular dendritic cellular meshwork. It is a systemic disease clinically characterized by lymphadenopathy, hepatosplenomegaly, skin rash, constitutional symptoms, bone marrow plasmacytosis in 50% of cases, polyclonal hypergammaglobulinemia and hematologic abnormalities. In the present case, many of these symptoms were present. However, histological and immunohistochemical findings were more consistent with PTCL-NOS rather than AITL.

The mechanism of polyclonal proliferation of plasma cells in peripheral blood of T-cell lymphoma patients is probably multifactorial. According to some authors, the EBV infection of B-cells in AITL may contribute to reactive plasma cell proliferation (17). Namely, increased release of cytokines, such as IL-6 or IL-10, which are known to stimulate plasma cell generation, may contribute to this process. Probably, this mechanism could have also been involved in our case, since EBV encoded RNA 1 transcripts were detected in rare lymphoid cells. However, the relationship between T-cell and plasma

cell neoplasms is unclear, as various studies have described different possible mechanisms of tumorigenesis. Yet, some authors hypothesize that the clonal plasma cell population is unrelated to T-cell lymphoma (20).

To the best of our knowledge, the case presented is the first report of PTCL-NOS associated with marked proliferation of monoclonal and polyclonal plasma cells, thereby potentially masking underlying T cell lymphoma. It is clinically important to be aware of this possible effect when determining treatment strategies and prognostic stratification. Despite the fact that lymphadenopathy is expected finding, the presence of enlarged lymph nodes in plasma cell leukemia requires additional morphological analysis. Furthermore, this case emphasizes the importance of serious interpretation of serum electrophoresis when monoclonal and polyclonal gammopathy simultaneously exist. In the present case, the patient developed more than one histological type of lymphoproliferative disease, i.e. PTCL-NOS and aggressive plasma cell leukemia, which were associated with poor prognosis.

Compliance with ethical standards This article does not contain any studies with human participants performed by any of the authors. All the procedures performed and described in this case report were done due to diagnostic purposes.

Conflict of interest: The authors declare that they have no conflict of interest.

References

1. Volk AL, Vannucci SA, Cook W, et al. Composite mycosis fungoides and B cell chronic lymphocytic leukemia. *Ann Diag Pathol.* 2002;6:172-182.
2. Whitling NA, Shanesmith RP, Jacob L, et al. Composite lymphoma of mycosis fungoides and cutaneous small B cell lymphoma in a 73-year-old male patient. *Hum Pathol* 2013;44:670-675.

3. Cotter FE, Young BD, Ilister TA. Simultaneous presentation of T and B cell malignant lymphoma with bcl 2 gene involvement. *Blood* 1989;73:1387-1388.
4. Ioachim HL, Medeiros LJ. Composite lymphoma. In: Ioachim HL, Medeiros LJ, eds. *Ioachim's Lymph node pathology*, 4th Edition. Philadelphia: Lippincott Williams & Wilkins, 2009:452-459.
5. Kim HK, Park CJ, Jang S, et al. The first case report of composite bone marrow involvement by simultaneously developed peripheral T cell lymphoma, not otherwise specified, and diffuse large B cell lymphoma. *Ann Lab Med* 2015;35:152-154.
6. Cartron G, Roingeard P, Benboubker L, et al. Sezary syndrome in a patient with multiple myeloma: demonstration of a clonally distinct second malignancy. *Eur J Haematol* 1999;63(5):354-357.
7. Wickenhauser C, Borchmann P, Diehl V, et al. Development of IgG lambda multiple myeloma in a patient with cutaneous CD30+ anaplastic T cell lymphoma. *Leukemia Lymphoma* 1999;35:201-206.
8. Tangour M, Chelly I, Haouet S, et al. Multiple myeloma and cutaneous anaplastic large T cell lymphoma in the same patients: is there a causal relation? *J Cutan Pathol* 2011;38(3):298-300.
9. Nassif S, El Majzoub N, Abbas O, et al. Simultaneous occurrence of a CD30 positive/ALK negative high grade T cell lymphoma and plasma cell myeloma: report of a case. *Hematol Oncol Stem Cell* 2015;8:40-42.
10. Lorscheich RB, His ED, Dogan A, et al. Plasma cell myeloma and related neoplasms. *Am J Clin Pathol* 2011;136:168-182.
11. Gertz MA, Buadi FK. Plasma cell leukemia. *Haematologica* 2010;95:705-707.

12. Naseem S, Kaur S, Gupta R, et al. Plasma cell leukemia: case series from a tertiary center with review of literature. *Indian J Hematol Blood Transfus* 2012;28:10 14.
13. Lachenal F, Berger F, Ghesquieres H, et al. Angioimmunoblastic T cell lymphoma: clinical and laboratory features at diagnosis in 77 patients. *Medicine (Baltimore)* 2007;86:282 292.
14. Grogg KL, Morice WG, Macon WR. Spectrum of bone marrow findings in patients with angioimmunoblastic T cell lymphoma. *Br J Haematol* 2007;137:416 22.
15. Willenbrock K, Brauninger A, Hansmann ML. Frequent occurrence of B cell lymphomas in angioimmunoblastic T cell lymphoma and proliferation of Epstein Barr virus infected cells in early cases. *Br J Haematol* 2007;138:733 739.
16. Huppmann AR, Rouillet MR, Raffeld M, et al. Angioimmunoblastic T cell lymphoma partially obscured by an Epstein Barr virus negative clonal plasma cell proliferation. *J Clin Oncol* 2013;31:28 30.
17. Ahsanuddin AN, Brynes RK, Li S. Peripheral blood polyclonal plasmacytosis mimicking plasma cell leukemia in patients with angioimmunoblastic T cell lymphoma: report of 3 cases and review of the literature. *Int J Clin Exp Pathol* 2011;4:416 420.
18. Yamane A, Awaya N, Shimizu T, et al. Angioimmunoblastic T cell lymphoma with polyclonal proliferation of plasma cells in peripheral blood and marrow. *Acta Haematol* 2007;117:74 77.
19. Saki H, Tanaka H, Katsurada T, et al. Angioimmunoblastic T cell lymphoma initially presenting with replacement of bone marrow and peripheral plasmacytosis. *Intern Med* 2007;46:419 424.

20. Jang MA, Lee ST, Kim HJ, et al. Simultaneous occurrence of angioimmunoblastic T cell lymphoma and plasma cell leukemia. *Ann Lab Med* 2015;35:149-151.

Figure Legends

Fig 1 Increased number of typical and atypical plasma cells in bone marrow smears (a).

Immunofixation electrophoresis detected a monoclonal band defined as IgG-lambda light chains, with broad band polyclonal IgA (b). Hypercellular marrow with increased plasma cells detected with CD138 (c) and restriction of lambda light chain immunoglobulin (d).

Fig 2 Diffuse infiltrates with effacement of the normal lymph node architecture. Among

polymorphous small, medium-sized and large lymphoid cells with irregular, pleomorphic nuclei of high proliferative activity (Ki67), typical and atypical plasma cells are also present (CD138).

Immunophenotyping revealed CD3+/CD4+/CD8-/BCL-6 -/+ /CD10- and scattered expression of CD30 on lymphoid cells and CD38+/CD138- expression on atypical plasma cells. In situ hybridization of EBV encoded RNA 1 detected EBV transcripts in rare cells.

Table 1 The patient's most important laboratory findings

LABORATORY FINDINGS	VALUE
Erythrocyte sedimentation rate	140 mm/h (normal range 5-28)
Erythrocyte count	3.01 x 10 ¹² /L (normal range 3.86-5.08 x 10 ¹² /L)
Hemoglobin	84 g/L (normal range 119-157 g/L)
Hematocrit	0.253 (normal range 0.356-0.470)
White blood count	11.6 x 10 ⁹ /L (normal range 3.4-9.7 x 10 ⁹ /L)
Neutrophils	62%

Lymphocytes	4%
Eosinophils	3%
Basophils	0%
Monocytes	4%
Plasma cells	26%
Proplasma cells	1%
Lymphoplasmacytes	1%
Platelet count	26 x 10 ⁹ /L (normal range 158-424 x 10 ⁹ /L)
Creatinine	78 µmol/L (normal range 49-90 µmol/L)
Aspartate aminotransferase	22 U/L (normal range 8-30 U/L)
Alanine aminotransferase	24 U/L (normal range 10-36 U/L)
Lactate dehydrogenase	352 U/L (normal range <241 U/L)
C-reactive protein	26.6 mg/L (normal range <5 mg/L)
IgG	37.2 g/L (normal range 7.0-16.0 g/L)
IgA	29.4 g/L (normal range 0.7-4.0 g/L)
IgM	1.5 g/L (normal range 0.4-2.3 g/L)
Serum calcium	2.16 mmol/L (normal range 2.14-2.53 mmol/L)
Serum protein electrophoresis with Immunofixation	M-peak with polyclonal hypergammaglobulinemia; monoclonal IgG- lambda band with broad polyclonal IgA band
- serum free light Ig kappa	220.0 mg/L (normal range 6.7-22.4 mg/L)
- serum free light Ig lambda	232.0 mg/L (normal range 8.3-27.0 mg/L)
- serum free light chain ratio (kappa/lambda)	0.95 (0.31-1.56)
Serum albumin	16.2 g/L (normal range 40.6-51.4 g/L)
Serum β2-microglobulin	12.7 mg/L (normal range 1.09-2.53 mg/L)

Figure 1

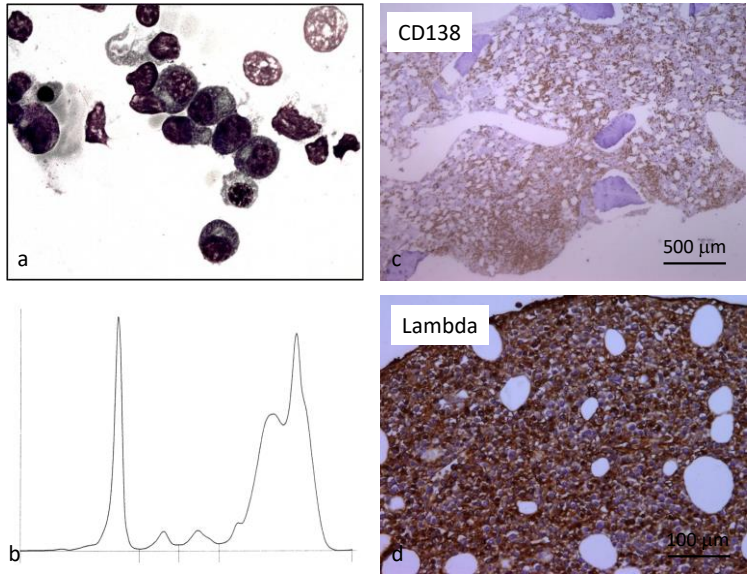


Figure 2

