

Dilemma of Antiepileptic Drugs Withdrawal in Symptomatic Epilepsy

Šepić Grahovac, Dubravka; Bajek, Goran; Vitezić, Dinko; Tuškan Mohar, Lidija; Ružić Baršić, Antonija; Grahovac, Tanja; Bajek, Snježana

Source / Izvornik: **Collegium antropologicum, 2011, 35, 1291 - 1294**

Journal article, Published version

Rad u časopisu, Objavljena verzija rada (izdavačev PDF)

Permanent link / Trajna poveznica: <https://um.nsk.hr/um:nbn:hr:184:160721>

Rights / Prava: [Attribution 4.0 International](#)/[Imenovanje 4.0 međunarodna](#)

Download date / Datum preuzimanja: **2025-01-25**



Repository / Repozitorij:

[Repository of the University of Rijeka, Faculty of Medicine - FMRI Repository](#)



Dilemma of Antiepileptic Drugs Withdrawal in Symptomatic Epilepsy

Dubravka Šepić Grahovac¹, Goran Bajek¹, Dinko Vitezić¹, Lidija Tuškan Mohar¹, Antonija Ružić Baršić², Tanja Grahovac¹ and Snježana Bajek¹

¹ University of Rijeka, School of Medicine, Rijeka, Croatia

² University of Rijeka, Rijeka University Hospital Center, Department of Radiology, Rijeka, Croatia

ABSTRACT

A successful treatment of epilepsy depends on numerous factors such as etiology, genetics and environmental impact. An exact diagnosis, treatment and an adequate selection of antiepileptic drugs (AED) are important from the very beginning. The patient with symptomatic epilepsy caused by the brain tumor (low-grade astrocytoma in the left parietal lobe, surgically removed 17 years after the first manifestation of illness) is presented in this study. He has been seizure free for 6 years. The represented case study deals with the risk-benefit analysis of the discontinuation of the prescribed anti-epileptic treatment that has lasted for 23 years.

Key words: epilepsy, brain tumor, antiepileptic drugs, withdrawal

Introduction

The aim of this report is to discuss the withdrawal of AEDs in a patient with a good clinical outcome and the well-known etiological factor of seizures, i.e., low-grade astrocytoma. Symptomatic epilepsy is caused by variable pathology. Between 3 and 5% of epileptic seizures can be attributed to the central nervous system (CNS) neoplasm^{1,2}. Most AEDs suppress the seizure occurrence but do not prevent the epileptogenesis. Etiology is one of the most important determinants for the outcome of the decision to discontinue AEDs³. Many physicians meet the dilemma of AEDs withdrawal in patients but their experiences have rarely been reported in literature. Although the prevalency of epilepsy is very high among world population (one percent)⁴, the definitive guidelines for the discontinuation of AEDs still do not exist.

Case Report

We present a 58-year-old right-handed male clerk, who had a brief loss of consciousness without seizures at the age of 35, while he was playing football. Five months later, he had a partial motor seizure in his right arm with the secondary generalization, without aura. His wife reported his postictal changes of mood during the half an hour. A sleepless night, mild alcohol consumption and

physical fatigue preceded the seizure. In the family history, there were no members with epilepsy. Disrhythmia was recorded on electroencephalogram (EEG) and the treatment with AED (methyphenobarbital 200 mg *per os*) was started. The performed brain computed tomography (CT) showed the extensive damage of cortical and subcortical tissues in the area of left parietal lobe, which was interpreted as gliosis (Figure 1).

The patient refused the proposed brain biopsy. The control neuroimaging techniques (CT/MRI) were performed once a year during the next eight years. The therapy with methyphenobarbital 200 mg and carbamazepin 400 mg, twice daily *per os*, was continued regularly and he became seizure free. Between the age 43 and 50, seizures of the same origin started to reappear once or twice a year, in spite of his taking the therapy regularly. The magnetic resonance scan (MRI) of the brain repeatedly showed the wide damage of the left frontal and parietal lobe. At the age of 51, during an enterovirus infection accompanied by high fever, he had a series of focal seizures with secondary generalization. The MRI confirmed the previous findings that had shown additional expansive cystic formation, with no pressure on the surrounding tissue at the same localization (Figure 2). The stereotactic biopsy verified the astrocytoma II / III grade in the area of de-

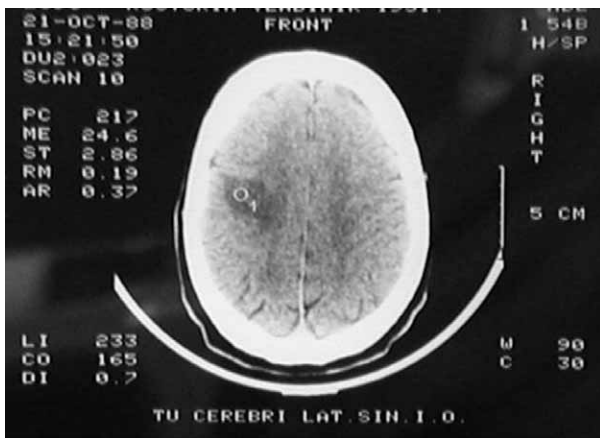

Fig. 1. Brain CT in 1988 showed extensive damage in the left parietal lobe.

scribed lesions. A year later, at the age of 52, the tumor was neurosurgically removed. In the early postoperative stage, during the first week, an isolated partial seizure with secondary generalization occurred. The neurological examination showed a moderate right side hemiparesis and a sensomotor paraphasia. A massive AED polytherapy was prescribed: phenobarbiton 500 mg, carbamazepin 1200 mg, phenitoin 300 mg, lamotrigin 300 mg orally and 30 brachytherapy treatments. The right side hemiparesis of central type and sensomotor paraphasia withdrew greatly through neurorehabilitation procedures. Psychomotor slowness and excessive sedation as the side effects of AEDs were corrected during the following 3 months. 5 years after the surgery, a control MRI of the brain showed a post-operational gliosis without the residual tumor (Figure 3). The MRI spectroscopy of the selected areas of the left precentral area detected the correct relationship between the basic metabolites cholin

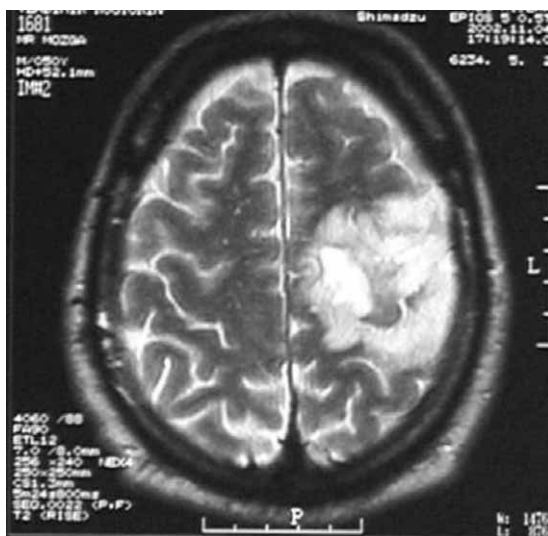


Fig. 2. MRI in 2002 showed the expansive cystic formation at the same localization.

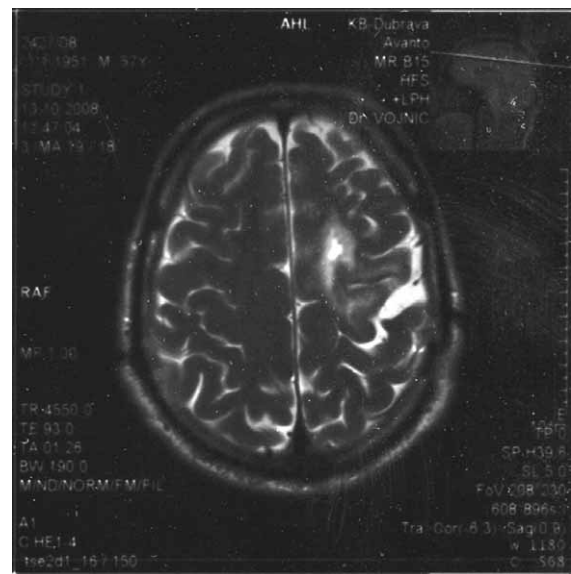


Fig. 3. MRI in 2008 (5 years after the surgery) showed gliosis without the residual tumor.

and sodium–acetylaspartat. Presently, the patient is doing well, despite the presence of discrete right central hemiparesis. His mental functions and professional abilities have been preserved. He has continued with AEDs: lamotrigin 100 mg and phenobarbital 50 mg. He has had no seizures in last 6 years. Routine laboratory tests are within the normal range.

Discussion

The late onset epilepsy traditionally leads us to consider the presence of brain tumors. About one third of brain tumors have seizures as a presenting symptom¹, but only in 10 to 15%, epileptic seizures are the first manifestation of the intracranial expansive process. Seizures that follow the development of tumors do not have the same significance as those that occur at the beginning of the process. That corresponds to the classic definition of the late onset epilepsy, which could be the manifestation and the only symptom of the intracranial expansive process that can evolve or remain isolated during months, even years⁵.

The use of neuroimaging techniques (brain CT, conventional and unconventional MRI scans), which enabled an early diagnosis, today significantly modify that term. The risk is dependent on the age; because almost three quarters of epileptic seizures, which are caused by CNS tumors, appear between the age of 20 and 50. That usually includes supratentorially located tumors. The studies have shown that most epileptogenic tumors are in greatest part benign, or have a low evolutive potential, such as oligodendroglioma, astrocytoma and meningioma¹.

Our patient is an example for these statements. He lived with an astrocytoma (II/III grade) for 17 years, which is very well described in clinical neurological pra-

ctice⁶. Malignant gliomas and metastases are significantly less epileptogenic. Arachnoidal cysts generally do not have any connection with the epileptic focus and surgical treatment is always questionable⁷. A clinical epileptic expression primarily depends on the localization and the size of the tumor. Partial epileptic seizures, especially somato-motoric ones are predominant over the secondary generalized seizures⁴. The electroencephalographic semiology may be absent, and then be falsely comforting. The most common finding is a focally changed EEG that shows the localization of the process.

Neuroradiological findings are those that confirm the diagnosis. Mostly primary partial seizures are rarely presented as secondary generalized seizures, they aggravate the clinical picture and can cause a possible decompensation of the present tumor, especially in low-grade astrocytoma. A long-term AED treatment is indicated in the preoperational and in the post-operational stage, as in the case of symptomatic epilepsy. Such prophylactic treatment is not indicated if efficiency is not proved and with regard to the numerous side-effects, especially cognitive, as well as the potential interactions between AEDs and other drugs, such as chemotherapeutics⁸. Large retrospective studies have reported that patients with brain tumors are more likely to be controlled with AEDs than those with malformations of cortical development, hippocampal sclerosis or post-traumatic epilepsy⁹.

Causes of seizures are the most important factor for the outcome of the treatment¹⁰. A possible and/or successful removal of the main cause of epilepsy (brain tumor in our case) can have an influence on its favorable evolution¹¹.

On the other hand, approximately 60 to 70% of patients accomplish a good control of seizures, even their disappearance, by the regular taking of AEDs, during a long period of treatment^{12,13}. If we exclude an epileptic seizure that followed the day after surgery, our patient's epilepsy became well controlled by taking AEDs, and the patient has been seizure free for 6 years.

The issue of the withdrawal of AEDs in this case is very plausible. A Cochrane review concluded that the optimal period for the discontinuation of AEDs in adults remains uncertain and unspecified¹⁴. However, according to 2nd UCB Global Epilepsy Summit most patients with epilepsy should have an attempted treatment withdrawal if they have been seizure free for 2–3 years¹⁵. The period of discontinuation varies. The recent Cochrane review did not come to any reliable conclusion on the optimal taper rate¹⁶. The results of the MRC study indicate that a shorter period without epileptic seizures before the discontinuation of AEDs significantly increases the risk for recurrences¹⁷. A gradual withdrawal, choosing a suitable period in a patient's life and creating a protected environment, are conditions for starting the discontinuation¹⁵. Some studies have shown that the discontinuation needs to be performed slowly, because if a relapse occurs during the taper, the seizure may be less severe than after the full withdrawal¹⁸. According to the recent data, the treatment should be discontinued gradually over a period of 6 months to 1 year¹⁵. Subclinical

(subtoxic) AEDs' side effects, absent in our patient, may also be a reason for the withdrawal.

An absolute answer for AED discontinuation does not exist^{19,20}. The benefits and risks associated with the AED withdrawal need to be balanced¹⁸. Benefits, besides savings, are the disappearance of secondary mental side effects, the elimination of teratogenesis (in pregnant women with epilepsy)¹⁸, subjective effects in the patient and the stigmatization of the illness. Some risks for recurrences are: a patient's disrespect for the way of living with the epilepsy, ignoring the advices of physicians; a desire for full inclusion in the social and professional life and a desire for keeping driving ability^{20,21} and for practicing sports. A sudden appearance of the status epilepticus is rare if the withdrawal is performed gradually. Some authors state that over 40% of patients who terminated the treatment with AEDs have relapses, while only 2% of those who continue with the therapy also continue with seizures²². Before the interruption of the treatment, it is necessary to obtain the informed consent, with the obligatory warning about possible relapses but also benefits of such a decision²³. In our case, preferable factors for the AED withdrawal are: a normal electroencephalogram²³ and the surgical removal of the tumor that caused the epileptic focus. Doubts about this decision result from the inability to prove completely the effectiveness of a surgical treatment. Several years after the absence of epileptic seizures, we cannot know if the absence is really a consequence of successful treatment or if the natural development of the disease has been favorable. The ictal and interictal EEG registration²³ is not an absolute criterion, but can be very useful. A discontinuation of AEDs must be presented to the patient as an attempt, and the process must be performed gradually. Our experience has shown that it is necessary to gradually initiate the monotherapy, and then slowly reduce the dosage (25% every three months). Some AEDs (e.g. barbiturates) can produce a complex syndrome of abstinence. After ten or more years of the treatment with such AEDs, some authors prefer to continue with minimal doses of barbiturates, rather than have a withdrawal.

Conclusion

The decision to withdraw AEDs is not simple, and cannot be infinitely delayed. In any case, the discontinuation of AEDs must be strictly individualized^{3,20} and based on several important factors that include the history of the disease (the age at the onset, the type and severity of seizures, particular neurological findings, absence of epilepsy and mental illness/disorder in family history)²¹, involvement in socio-professional life²⁰, as well as the decision and willingness of the patient.

The experiences of AED withdrawal are still limited, especially in patients with symptomatic epilepsy (brain tumor in our case). There is a need for conducting prospective studies where the withdrawal of AEDs can be well monitored and then to cumulate the knowledge for the development of guidelines for the discontinuation of AEDs.

REFERENCES

1. HAUSER WA, Abstract book. 27th Internat Epilepsy Cong Singapore (2007) 166. — 2. HAUSER WA, ANNEGERS JF, KURLAND LT, *Epilepsia*, 34 (1993) 453. — 3. BIELEN I, SRUK A, PLANJAR-PRVAN M, CVITANOVIĆ-ŠOJAT LJ, KOŠIČEK M, BERGMAN-MARKOVIĆ B, BARABA R, BUTKOVIĆ-SOLDO S, *Coll Antropol*, 33 (2009) 2. — 4. GRISAR T, BOTTIN P, DE BORCHGRAVE D'ALTENA V, BRICHART C, DELCOURT C, DUBRU JM, FOULON M, GHARIANI S, HOTERMANS C, LEGROS B, OSSEMANN M, SADZOT B, TUGENDHAFT P, VAN BOGAERT P, VAN RIJCKEVORSEL K, VERHEULPEN D, *Acta Neurol Belg*, 105 (2005) 5. — 5. LANG FF, GILBERT MR, *J Clin Oncol*, 24 (2006) 1236. — 6. ROSSETTI AO, VILLEMURE JG, SEECK M, PRILIPKO O, DESPLAND PA, JALLON P, *Rev Med Suisse*, 1 (2005) 1220. — 7. DAM AM, FUGLSANG-FREDERIKSEN A, SVARRE-OLSEN U, DAM M, *Epilepsia*, 26 (2007) 227. — 8. GLANTZ MJ, COLE BF, FORSYTH PA, RECHT LD, WEN PY, CHAMBERLAIN MC, GROSSMAN SA, CAIRNCROSS JG, *Neurology*, 54 (2000) 1886. — 9. RYVLIN P, Abstract book. 27th International Epilepsy Congress Singapore (2007) 167. — 10. BOON P, ENGELBORGH S, HAUMAN H, JANSEN A, LAGAE L, LEGROS B, OSSEMANN M, SADZOT B, URBAIN E, VAN RIJCKEVORSEL K, *Acta Neurol Belg*, 108 (2008) 118. — 11. ŠEPIĆ-GRAHOVAC D, VITEZIĆ D, TUŠKAN MOHAR L, JURJEVIĆ A, *Neurol Croat*, 57 (2008) 25. — 12. KWAN P, BRODIE MJ, *N Engl J Med* 342 (2003) 314. — 13. SILANPAA M, *Epilepsia*, 34 (1993) 930. — 14. SIRVEN JI, SPERLING M, WINGERCHUK DM, *Cochrane Database Syst Rev*, 3 (2001) CD001902. — 15. LÓPEZ-TERRADAS COVISA JM, *Rev Neurol*, 37 (2003) 287. — 16. RANGANATHAN LN, RAMARATNAM S, *Cochrane Database Syst Rev*, 2 (2006) 19. — 17. Medical Research Council (no authors listed), *Lancet*, 337 (1991) 1175. — 18. MEADOR KJ, *Epilepsy Curr*, 8 (2008) 90. — 19. HAJNŠEK S, *Neurol Croat*, 57 (2008) 14. — 20. BONNETT LJ, TUDUR-SMITH C, WILLIAMSON PR, MARSON AG, *BMJ*, 341 (2010) 6477. — 21. SCHMIDT D, *J Neural Transm*, 118 (2011) 183. — 22. SPECCHIO LM, TRAMACERE L, LA NEVE A, BEGHI E, *J Neurol Neurosurg Psychiatry*, 72 (2002) 22. — 23. RATHORE C, PANDA C, SANKARA SARMA P, RADHAKRISHNAN K, *Epilepsia*, 52 (2011) 627.

D. Šepić-Grahovac

University of Rijeka, School of Medicine, Braće Branchetta 20, 51000 Rijeka, Croatia
e-mail: poliklinika.interneuron@ri.t-com.hr

DILEMA O UKIDANJU ANTIEPILEPTIČKIH LIJEKOVA U SIMPTOMATSKOJ EPILEPSIJI

SAŽETAK

Uspješno liječenje epilepsije ovisi o brojnim čimbenicima kao što su etiologija, genetika i utjecaj okoliša. Točna dijagnoza, liječenje i odgovarajući odabir antiepileptičkih lijekova presudni su od samog početka za prestanak napadaja i postizanje što bolje kvalitete života bolesnika sa epilepsijom. Prikazujemo bolesnika sa simptomatskom epilepsijom uzrokovanom tumorom mozga (astroцитom niskog stupnja) u lijevom tjemenu reznju, kirurški odstranjenog 17 godina nakon pojave prvog epileptičkog napadaja kao inicijalnog simptoma bolesti. Bolesnik je bez napadaja 6 godina nakon operacije, uz diskretni neurološki ispad i na minimalnoj dozi antiepileptika. Ovaj prikaz slučaja predstavlja analizu rizika i dobrobiti ukidanja antiepileptika nakon 23 godine.