

Colon carcinoma syndrome in a family

Štimac, Davor; Rubinić, M.; Diklić, Ž.; Ivaniš, M.

Source / Izvornik: **Libri Oncologici : Croatian Journal of Oncology, 1992, 21, 189 - 191**

Journal article, Published version

Rad u časopisu, Objavljena verzija rada (izdavačev PDF)

Permanent link / Trajna poveznica: <https://um.nsk.hr/um:nbn:hr:184:374524>

Rights / Prava: [Attribution-NonCommercial-NoDerivatives 4.0 International/Imenovanje-Nekomercijalno-Bez prerada 4.0 međunarodna](#)

Download date / Datum preuzimanja: **2024-07-07**



Repository / Repozitorij:

[Repository of the University of Rijeka, Faculty of Medicine - FMRI Repository](#)



COLON CARCINOMA SYNDROME IN A FAMILY

ŠTIMAC D., RUBINIĆ M., DOBRILA R., DIKLIĆ Ž., IVANIŠ N.

Department of Internal Medicine, Gastroenterology Division,
University Medical Center, Rijeka, Croatia

SUMMARY

The increased incidence of malignant diseases of the colon in some families had been observed as early as the beginning of this century. Later on the phenomenon was described as an autosomal dominant mode of transmission, termed the Cancer Family Syndrome (CFS). A family in which six relatives are affected by colonic cancer is presented in the paper. In these patients the disease is characterized by an early age of onset, and a very progressive course with a poor outlook for treatment. Regular screening for early signs of cancer in families affected by colonic cancer by the usual laboratory tests and clinical examinations, in which procedure colonoscopy occupies a place of special importance, with scrupulous pathohistological analysis of any suspicious lesion, suggests itself as an imperative necessity.

KEY WORDS: colon carcinoma, syndrome, family.

KOLON KARCINOMA SINDROM U PORODICI

SAŽETAK

Još početkom ovog stoljeća uočena je povećana incidencija malignih bolesti kolona u nekih obiteljima. Kasnije je utvrđeno da se radi o autosomno dominantno nasljednom fenomenu koji je nazvan Cancer Family Syndrome. U našem radu je prikazana porodica u kojoj je šest srodnika oboljelo od karcinoma kolona. Bolest se u naših bolesnika pojavljuje u mladoj životnoj dobi uz vrlo progresivan tok i malim mogućnostima liječenja. Nameće se potreba redovite kontrole porodica oboljelih od karcinoma kolona i to uobičajenim laboratorijsko-kliničkim pregledima gdje posebno mjesto zauzima kolonoskopija uz točnu patohistološku analizu sumnjivih lezija.

KLJUČNE RIJEČI: karcinom kolona, sindrom, porodica.

Cancer Family Syndrome (CFS) was first reported in 1913 cit. Metzmaker (10). This investigation was updated by Hauser and Weller in 1935, and by Lynch and Krush in 1971 (1,7,8,9,10). The syndrome is characterized by the occurrence of colorectal or endometrium adenocarcinoma in a number of first-degree relatives. It occurs at an early age and is considered autosomal dominant mode of transmission (7).

Our intention is to introduce a family with the syndrome of carcinoma of the colon with the purpose of further substantiating the occurrence of this rare malignant disease.

REPORT OF THE CASES

In the reported family there are three generations of six relatives suffering from the same disease. Fig. 1.

1. In a 58-year-old male patient evaluated for anaemia, colonoscopy revealed a tumorous formation of caecum. Pathoanatomic diagnosis confirmed adenocarcinoma and surgery was performed. Besides the said carcinoma 20 cm of Valvula Bauhini, i.e. at the terminal ileum the same intervention revealed another tumor, pathohistologically also of the adenocarcinoma

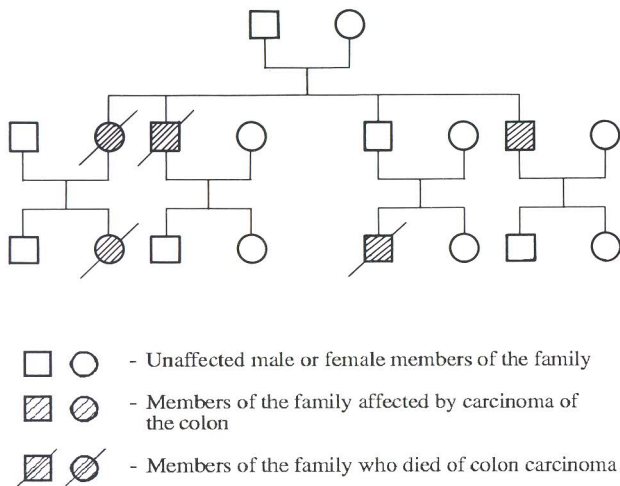


Figure 1. Three generations with colon carcinoma syndrome in the family

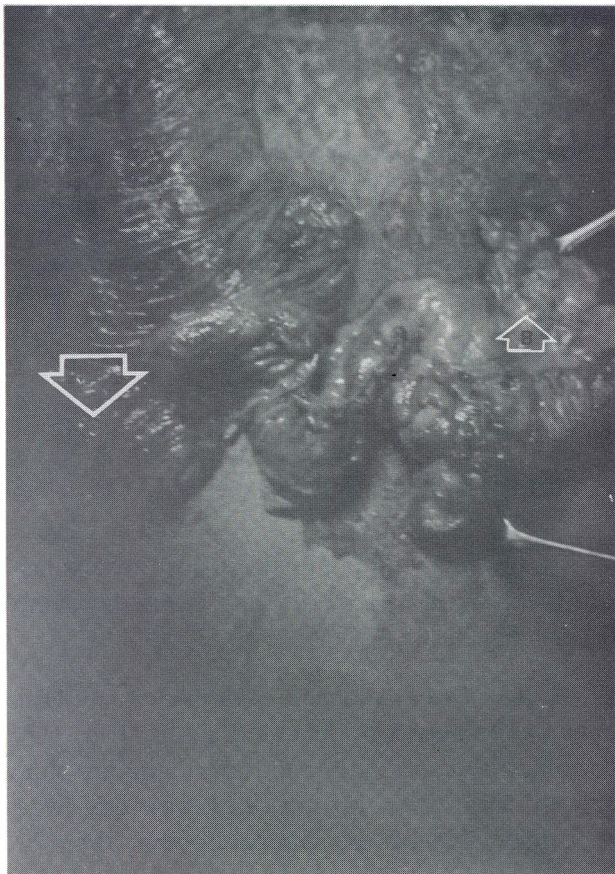


Figure 2. Colon carcinoma — caecum (A) terminal ileum (B)

nature. Fig. 2. Two years after surgery the patient had no complaints or relapse of the complaint.

2. A 40-year-old female patient, niece of the above mentioned patient, was also examined because of marked anaemia. Further workup revealed an expansive process in the caecum, a pathohistological adenocarcinoma, extending to adjacent structures. The patient died five years after palliative surgery.

3. A 32-year-old male first cousin of the mentioned female patient also died of carcinoma of the colon, a hepatal flexure diagnosed and treated in another institution.

4. As it can be seen in Fig. 1, besides the mentioned members of the family, carcinoma of the colon was the cause of death of the mother and the grandmother of the female patient, and an uncle and a brother of the patient reported in the first case.

DISCUSSION

Cancer family syndrome refers to families with a high incidence of development of adenocarcinoma of the colon and endometry in younger age groups.

With all patients in the reported family the onset of the symptoms occurred at a statistically lower age than that usually expected for colorectal carcinoma. With all of these patients the development of the disease was very rapid, and the response to therapy poor. This is consistent with the descriptions of other authors (1,5,6,7,10).

The family tree shows that of the four first generation relatives (three brothers and one sister) three were affected (two brothers and a sister). In the second generation, besides the 40-year-old female patient whose mother contracted the disease, the illness also struck her first cousin, whose father is now the only member of his generation in the family unaffected by the disease.

Malignant colonic neoplasms as found in some families had been thought to be a degeneration of hereditary colonic polyps. In recent times, however, it has been observed that colonic carcinoma in cancer families does not develop from existing polyps, and thus the real nature of the cellular transformation is unknown and it is not

possible to determine precisely which member of the family will be affected by carcinoma.

Besides the genetic predisposition, the presence of secondary biliary acids, especially the lithocolic acid, is also considered an important factor in the neoplastic transformation of the colonic tissue (11,12).

From the preceding we can see that it is of the utmost importance to monitor the progeny of affected families. Any high risk relatives have to be examined at nine to twelve month intervals for signs of cancer by clinical examination, laboratory

tests, colonoscopy, barium-enema x-rays, and histological and cytological analysis of any suspicious lesion (1,5,8,10,16). In case of a developed carcinoma the method of choice is total colectomy with ileorectal anastomosis and obligatory monitoring of the rest of the ileum not less than once in twelve months (10,13). With women, regular gynaecological screening is indispensable as the malignant disease of the colon may often be accompanied with a similar complaint in the endometrium.

LITERATURE

1. Arndt R.D., Kositchek R.J., Boasberg P.D.: Colon carcinoma and the Cancer Family Syndrome. *JAMA* 237/26: 2847-2848, 1977.
2. Burt R.W., Bishop D.T., Cannon L.A., Dowdle M.A., Lee R.G., Skolnick M.H.: Dominant inheritance of adenomatous colonic polyps and colorectal cancer. *N. Engl. J. Med.* 312/24: 1540-1543, 1985.
3. Chiang V.H., Lewis J.H., Fleischer D.E., Cattau E.L., Benjamin S.B.: Segmental non-familial colonic polyposis. *Gastrointestinal Endoscopy*. 38/1: 78-80. 1992.
4. Eddy d.M., Nugent F.W., Eddy J.F., Coller J., Gilbersten V., Gottlieb L.S., Rice R., Scherlock P., Winawer S.: Screening for colorectal cancer in a high risk population - results of a mathematic model. *Gastroenterology* 92: 682-692. 1987.
5. Kee F., Collins B.J., Patterson C.C.: Prognosis in familial non-polyposis colorectal cancer. *Gut*. 32: 513-516. 1991.
6. Leppert M., Burt R., Hughes J.P., Samowitz W., Nakamura Y., Woodward S., Gardner E., Lalouel J.M., White R.: Genetic analysis of an inherited predisposition to colon cancer in family with a variable number of adenomatous polyps. *N. Engl. J. Med.* 322/13: 904-908. 1990.
7. Lynch H.T., Harris R.E., Organ C.H.: The surgeon, genetics and cancer control: The cancer family syndrom. *Ann. Surg.* 185: 435-440.
8. Lynch H.T., Lynch J., Harris R.E.: Minimal genetic findings and their cancer control implications. *JAMA*. 240/6: 535-538. 1978.
9. Lynch H.T., Swartz M., Lynch J., Krush A.J.: A family study of adenocarcinoma of the colo and multiple primary cancer. *Surgery, Gynecology, Obstetrics*. 134: 871-766. 1972.
10. Metzmaker C.O., Sheehan M.P.: Report of a family with cancer family syndrome. *Dis. Col. Rect.* 12: 523-525. 1981.
11. Moskowitz M., White C., Barnett R.N.: Diet, fecal bile acids and neutral steroids in patients with familiar polyposis. *Cancer*. 38: 1694-1698. 1976.
12. Nair P., Turjman N.: Role of bile acids and neutral sterols in familial cancer syndromes of the colon. *Dis. Colon Rectum*. 26/9: 629-632. 1983.
13. Silverberg E., Lubera J.: Cancer statistics. *Cancer*. 37: 2-19. 1987.
14. Simon J.B.: Occult blood screening for colorectal carcinoma - a critical review. 88:820-837.1985.
15. Vogelstein B., Fearon E.R., Hamilton S.R.: Genetic alterations during colorectal tumor development. *N. Engl. J. Med.* 319: 525-532. 1988.

Author's address: Doc. dr. Milivoj Rubinić, Interna klinika - Gastroenterologija, Krešimirova 42, 51000 Rijeka

Received for publication: August 20, 1992