

Supplementary Diagnostic Landmarks of Left Ventricular Non-Compaction on Magnetic Resonance Imaging

Boban, Marko; Pesa, Vladimir; Beck, Natko; Manola, Sime; Žulj, Marinko; Rotim, Ante; Včev, Aleksandar

Source / Izvornik: **Yonsei medical journal, 2018, 59, 63 - 71**

Journal article, Published version

Rad u časopisu, Objavljena verzija rada (izdavačev PDF)

<https://doi.org/10.3349/ymj.2018.59.1.63>

Permanent link / Trajna poveznica: <https://um.nsk.hr/um:nbn:hr:184:503768>

Rights / Prava: [Attribution-NonCommercial 4.0 International/Imenovanje-Nekomercijalno 4.0 međunarodna](#)

Download date / Datum preuzimanja: **2024-12-31**



Repository / Repozitorij:

[Repository of the University of Rijeka, Faculty of Medicine - FMRI Repository](#)





Supplementary Diagnostic Landmarks of Left Ventricular Non-Compaction on Magnetic Resonance Imaging

Marko Boban^{1,2,3}, Vladimir Pesa^{1,3}, Natko Beck^{1,3}, Sime Manola⁴,
Marinko Zulj², Ante Rotim¹, and Aleksandar Vcev²

¹Department of Cardiology, University Hospital "Thalassotherapia Opatija," Medical Faculty University of Rijeka, Opatija;

²Department of Internal Medicine, Medical Faculty "J.J. Strossmayer" University of Osijek, Osijek;

³Department of Radiology, University Hospital "Thalassotherapia Opatija," Opatija;

⁴Department of Cardiology-Arrhythmology and Electrophysiology, University Hospital "Sestre Milosrdnice," Zagreb, Croatia.

Purpose: Diagnostic criteria for left ventricular non-compaction (LVNC) are still a matter of dispute. The aim of our present study was to test the diagnostic value of two novel diagnostic cardiac magnetic resonance (CMR) parameters: proof of non-compact (NC) myocardium blood flow using T2 sequences and changes in geometry of the left ventricle.

Materials and Methods: The study included cases with LVNC and controls, from a data base formed in a period of 3.5 years (n=1890 exams), in which CMR protocol included T2 sequences. Measurement of perpendicular maximal and minimal end diastolic dimensions in the region with NC myocardium from short axis plane was recorded, and calculated as a ratio (MaxMinEDDR), while flow through trabecula was proven by intracavitary T2-weighted hyperintensity (ICT2HI). LVNC diagnosis met the following three criteria: thickening of compact (C) layer, NC:C>2.3:1 and NC>20%LV.

Results: The study included 200 patients; 71 with LVNC (35.5%; i.e., 3.76% of CMRs) and 129 (64.5%) controls. MaxMinEDDR in patients with LVNC was significantly different from that in controls (1.17±0.08 vs. 1.06±0.04, respectively; $p<0.001$). MaxMinEDDR >1.10 had sensitivity of 91.6% [95% confidence intervals (CI) 82.5–96.8], specificity of 85.3% (95% CI 78.0–90.0), and area under curve (AUC) 0.919 (95% CI 0.872–0.953; $p<0.001$) for LVNC. Existence of ICT2HI had sensitivity of 100.0% (95% CI 94.9–100.0), specificity of 91.5% (95% CI 85.3–95.7), and AUC 0.957 (95% CI 0.919–0.981; $p<0.001$) for LVNC.

Conclusion: Two additional diagnostic parameters for LVNC were identified in this study. ICT2HI and geometric eccentricity of the ventricle both had relatively high sensitivity and specificity for diagnosing LVNC.

Key Words: Left ventricle non-compaction, cardiac magnetic resonance imaging, diagnostic criteria, T2-sequences, maximal to minimal end diastolic diameters ratio

Received: July 11, 2017 **Revised:** September 9, 2017

Accepted: September 12, 2017

Corresponding author: Dr. Marko Boban, Department of Cardiology, University Hospital "Thalassotherapia Opatija," Medical Faculty University of Rijeka, Medical Faculty "J.J. Strossmayer" University of Osijek, M. Tita 188/1, Opatija 51 440, Croatia.

Tel: 385-98-414-281, Fax: 385-51-271-424, E-mail: marcoboban@yahoo.com

•The authors have no financial conflicts of interest.

© Copyright: Yonsei University College of Medicine 2018

This is an Open Access article distributed under the terms of the Creative Commons Attribution Non-Commercial License (<http://creativecommons.org/licenses/by-nc/4.0>) which permits unrestricted non-commercial use, distribution, and reproduction in any medium, provided the original work is properly cited.

INTRODUCTION

Left ventricle non-compaction (LVNC) is not frequently prevalent among cardiomyopathies. However, it is known to have serious consequences such as arrhythmias, sudden cardiac death, intracavitary and systemic thrombosis, as well as heart failure, eventually requiring systolic support or heart transplantation.¹⁻³ There is a complex genetic background responsible for LVNC development, which is in part shared with hypertrophic and dilative cardiomyopathy (DCM).^{4,5} Genetic studies show that LVNC develops from changes in structure or function of the proteins for sarcomere, cytoskeleton and mitochon-

dria.^{2,6} Fetal development of myocardium includes distinct phases in terms of time and morphology.⁷ Sequential process of maturation starts with early heart tube in gestational weeks 0–4, followed by surfacing of trabeculations in gestational weeks 4–8, and trabecular remodeling after the 8th week, where trabeculations start to fill with compact myocardial layer, finishing with maturation of multilayer spiral system.⁸ In this manner, the extent and severity of LVNC are determined by the timeline of process activity, genetic conditions and other surrounding factors.⁷ Postnatal development of trabeculations is somewhat more controversial, and could be seen in numerous conditions such as congenital heart disease, myocarditis, endocarditis, heart surgery and others.⁸

Due to complex and perplexing mechanisms involved in the development, expression and clinical course of LVNC, imaging diagnostic criteria are still a matter of dispute.⁹ Prominent LVNC characteristics include thinning of the compact (C) myocardial layer, eminent non-compact (NC) trabeculated layer, which is thickened at least 2 to 2.3 times, and proof of blood flow through trabecula and crypts by Doppler.^{9–11} Diagnostic yields increased with the use of cardiac magnetic resonance (CMR) imaging, due to excellent characteristics in time and space resolutions, tissue characterization, multiplanarity reach independent from chest wall anatomy, and MR being the reference standard for non-invasive volumetrics.^{10,12,13}

Several studies, using different imaging modalities, found non-standardized changes in left ventricle geometry, connected with LVNC.¹⁴ In addition, numerous groups of investigators found relationship between the left ventricle geometry, clinical course and prognosis for several heart diseases.¹⁵ Our preliminary clinical experience, based on a large volume of patients, frequently found existent geometric alternations in patients with LVNC. Also, we frequently found expressed intracavitary hyperintensity of non-contrast T2-weighted sequences, which occurs due to blood flow through the non-compact layer and myocardial recesses. The aim of our study was to systematically analyze geometrical changes in the region of non-compact myocardium and intracavitary T2 hyperintensity (ICT2HI) in a series of LVNC patients, those with clinical suspicion of LVNC, and controls. LVNC diagnosis was established using the currently agreed-upon imaging criteria, occasionally supplemented by the clinical criteria.^{10,11,16}

MATERIALS AND METHODS

Study was conducted in accordance with the Declaration of Helsinki and good clinical practice principles. All the patients were included after signing an informed consent form. Study was approved by the Hospital's ethical board. Imaging data for the patients fulfilling the LVNC diagnostic criteria were recruited from the CMR computer data base, for a period of 3.5 years (1890 exams). LVNC diagnosis included the CMR criteria cu-

mulative consisting of: 1) thinning of compact myocardium stratum in end diastole, 2) non-compact to compact myocardium ratio in end diastole (NC:C) of $>2.3:1$, and 3) trabeculations affecting $>20\%$ of the left ventricle myocardium mass.^{9,10,17} There were 4 (5.63%) cases with clinically confirmed LVNC that did not fulfill one of the three previously mentioned criteria. The latter group included 2 cases not reaching $NC:C > 2.3:1$, and 2 other cases not reaching $NC > 20\%LV$.

Matching case control group was made up from healthy individuals or patients, all of whom had T2-weighted sequences within standard protocol (described further on). Control group included individuals referred to CMR for diagnostics of structural heart disease in athletes, suspected or confirmed hypertrophic and DCM, suspicion of intracardial thrombus, significant arrhythmias without ischemic heart disease, myocarditis and pericarditis. Cases with suspicion of LVNC had either non-thinned compact stratum compared to the remaining part of the myocardium in the same short axes slice, increased non-compact layer with NC:C ratio of 1.9–2.2 and/or NC existing on 10–19% of the left ventricle mass and were part of the control group. For the purpose of subanalysis, the suspecting LVNC group was compared with the other patients in the control group. Additional subgroup analysis was also performed for patients with ICT2HI, and all the control group patients in this assessment were the ones without ICT2HI.

Study did not include patients with significant chest wall deformities, cardiac tumors, sarcoidosis, congenital heart disease, previous heart surgery, ischemic heart disease [known coronary artery disease with at least one vessel having atherosclerotic lesion $>30\%$, non-negative adenosine stress testing or with existent ischemic type of late gadolinium enhancement (LGE)], or those who had different imaging protocol (not including T2 sequences).

CMR exams were performed on 1.5T Magnetom Avanto, Siemens® (Erlangen, Germany), using ECG gating and respiratory control, Body Matrix chest and spine coil. CMR imaging protocol used in this study consisted of setting localizers, half-Fourier acquisition single-shot turbo spin echo sequences, steady state free precession (SSFP) of standard heart 2-, 4-, and 3-chamber planes and 6 mm stack of short axial slices, with adding of the right ventricle and its outflow tract in case of any clinical questions. Those were followed by short tau inversion recovery or turbo spin echo T1 and T2 sequences dark blood, and, fat saturation sequences in most cases. The latter was taken on a 4-chamber view and, in case of suboptimal representation of trabecula, additional T2 sequences were done on dedicated short axis slices, which was indicated during the exam and depended on the case. Gadolinium contrast was applied in a 0.2 mL/kg (0.1 mmol/kg) dose. An intravenous bolus of Omnican® (Gadodiamide, GE Healthcare, Carrigtwohill, Ireland) or Dotarem® (gadoterate meglumine, Guerbet Group, Villepinte, France) was used in the studied exams, followed by inversion time recovery scout, with acquisition of the LGE sequences

20–30 minutes after the contrast application.

Imaging studies were conducted by two experienced technicians, performing over 700 CMRs per year. Postprocessing analyses were done on a standard software, Siemens AG-NU-MARIS/4, Syngo MR B17[®] (Erlangen, Germany), and volumetric measurements were done using Siemens AG-Syngo Console VA 30 Argus[®], by two high throughput cardiologists (over 400 exams per year) and a radiologist.

Population and studied groups were analyzed with descriptive statistic and presented as means with standard deviations. Group data analyses were done using chi-square. Numeric variables were analyzed for differences by the Mann-Whitney U-test and, in testing of geometry, ratio to studied etiologies of controls was analyzed with Kruskal Wallis. Connections between the studied CMR parameters and clinical data were done by Spearman Rho. Diagnostic potential of T2 hyperintensity and maximal to minimal end diastolic diameter ratio (MaxMinEDDR) for diagnosing LVNC were estimated using a polynomial regression model and receiver operating characteristic (ROC) curve analysis. *p* value less than 0.05 was considered significant. Statistical analyses were done by an experienced statistician using IBM-SPSS12[®] ver. 20 (IBM Corp., Armonk, NY, USA), MedCalc ver. 12.2[®] for Windows (MedCalc Software Co., Ostend, Belgium), and Statistica 10[®] for Windows (StatSoft Inc., Tulsa, OK, USA).

RESULTS

Studied sample

Patients scheduled for magnetic resonance were from our institution and five tertiary medical centers from different parts of the country, including local catchment area of 500000 inhabitants and 1.5–2.0×10⁶ from around the country. The study included 200 patients referred to CMR diagnostic during a 3.5-year period (n=1890 exams). Their age was 46.0±16.3 years [range 15.2–80.4; 95% confidence intervals (CI) 18.7–69.9] and female and male population were 78 (39.0%):122 (61.0%), respectively. LVNC meeting the previously mentioned criteria was found in 71 studied patients (35.5%). Control group was made up from 129 (64.5%) matching cases, as follows: CMR excluded structural heart disease (athletes, suspected cardiomyopathy, myocarditis and other) in 68 (52.7%) cases, DCM in 26 (20.2%) cases, arrhythmogenic right ventricle dysplasia (ARVD) in 5 (3.9%) cases, hypertrophic cardiomyopathy (HCM) in 16 (16.3%) cases, subacute myocarditis in 5 (3.9%) cases and hypertensive heart disease in 4 (3.1%) cases. ICT2HI was tested by enhancing visualization of trabeculations and trabecular blood flow from the cavity. ICT2HI was found in 82 (41%) of the studied cases, including all the patients with LVNC (n=71; 100%), along with 11 (8.5%) cases from the control group. Cases from the control group with increased left ventricle trabeculations, in the range not sufficient to be diagnosed as LVNC, or cases with

trabeculations and other types of cardiomyopathy being predominantly morphological, made up a subgroup of patients with suspicion of LVNC (n=46). Of cases with suspicion of LVNC, 21 cases (45.7%) did not have structural heart disease or cardiomyopathy, 13 cases (28.3%) were with DCM, 8 (17.4%) with HCM, 3 (6.5%) with subacute myocarditis and 1 (2.2%) had hypertensive heart disease (*p*=0.198). Group of cases with suspicion of LVNC (n=46) was compared to the rest of the control patients (control 2; n=83).

Principal differences between 71 patients with LVNC and 129 matched controls, as well as between those suspected of LVNC (n=46) and their controls (control 2) are shown in Table 1.

Existence and type of LGE correlated with impaired systolic function (Rho-CC=0.356; *p*<0.001), left ventricle end diastolic dimension (LVEDD) (Rho-CC=0.140; *p*=0.049), interventricular septum thickness (Rho-CC=0.160; *p*=0.024), right ventricle end diastolic dimension (Rho-CC=-0.157; *p*=0.026), left ventricle end systolic volume (Rho-CC=0.160; *p*=0.024), left ventricle stroke volume (Rho-CC=-0.175; *p*=0.014) and the patients' age (Rho-CC=0.145; *p*=0.040). LGE correlated with some of the LVNC characteristics, as follows: NC:C>2.3:1 (Rho-CC=0.236; *p*<0.001), NC>20%LV (Rho-CC=0.164; *p*=0.020) and ICT2HI (Rho-CC=0.206; *p*=0.004), whilst there was no significant correlation of LGE with clinical suspicion of LVNC (Rho-CC=0.049; *p*=0.581).

LVNC diagnostic parameters

There were 71 patients with LVNC (prevalence 3.8% in the total sample), with the age of 42.6±17.0 years, (95% CI 18.0–73.5), LVEDD was 5.62±0.72 cm (4.65–7.00) and left ventricle ejection fraction (LVEF) 48.7±12.3% (23.5–63.7). Males predominated with 42 (59.2%) to 29 (40.8%). As for the principal diagnostic criteria, the NC:C ratio >2.3:1 was found in 69 (97.2%) and NC>20%LV was also found in 69 (97.2%), while solid layer thickness was 0.45±0.13 cm in end diastole vs. 0.78±0.18 cm (*p*<0.001), for patients with LVNC vs. controls, respectively. Four patients (2 from each group) did not fulfill two principal CMR criteria (NC:C>2.3:1 and NC>20%LV), but their clinical data confirmed LVNC. The latter were available at the time of CMR (3 patients) and one after the CMR (due to marginally highly suspicious report the patient was scheduled for a control CMR. However, implantable cardiac defibrillator was implanted prior to the second exam).

LVEF correlated with parameters of specific diagnostic criteria for LVNC, such as diagnosis of LVNC (Rho-CC=-0.332; *p*<0.001), the ratio of >2.3:1 (Rho-CC=-0.317; *p*<0.001) and share of non-compact myocardium >20% of LV (Rho-CC=-0.331; *p*=0.044). Systolic function also correlated with other characteristics of LVNC, such as C-layer thickness (Rho-CC=0.186; *p*=0.009), NC-layer thickness (Rho-CC=-0.379; *p*<0.001), maximal mid apical diameter (Rho-CC=-0.553; *p*<0.001) and minimal diameter (Rho-CC=-0.453; *p*<0.001), but not significantly (within range of statistical tendency; 0.05–0.09) with

Table 1. Group Characteristics and Differences of Patients with LVNC and Controls, as Well as of Cases Suspected of LVNC and Their Controls (Control 2)

	Controls (n=129)	LVNC (n=71)	Chi-square	Controls 2 (n=83)	Suspected LVNC (n=46)	Chi-square
	n (%)	n (%)		n (%)	n (%)	
Male	80 (62.0)	42 (59.2)	0.691	53 (63.9)	27 (58.7)	0.536
Female	49 (38.0)	29 (40.8)	0.691	30 (36.1)	19 (41.3)	0.536
LVEF<50%	29 (22.5)	33 (46.5)	<0.001*	15 (18.1)	14 (30.4)	0.107
NC:C>2.3:1	6 (4.7)	69 (97.2)	<0.001*	3 (3.5)	5 (10.9)	0.094
NC>20%LV	0 (0.0)	69 (97.2)	<0.001*	1 (1.2)	0 (0.0)	0.294
ICT2HI	11 (8.5)	71 (100.0)	<0.001*	3 (3.6)	8 (17.4)	0.035*
Late gadolinium enhancement			<0.001*			0.908
No	69 (53.9)	30 (42.3)		46 (54.8)	23 (50.0)	
Focal	22 (17.2)	2 (2.8)		14 (16.7)	8 (17.4)	
Linear	27 (21.1)	36 (50.7)		16 (19.5)	11 (23.9)	
Diffuse	10 (7.8)	3 (4.2)		6 (7.1)	4 (8.7)	

	Controls (n=129)	LVNC (n=71)	Mann Whitney U	Controls (n=83)	Suspected LVNC (n=46)	Mann Whitney U
	Mean±SD	Mean±SD		Mean±SD	Mean±SD	
Age (years)	47.8±15.7	42.6±17.0	0.031*	47.8±16.4	47.5±14.7	0.849
LVEDD (cm)	5.45±0.98	5.62±0.72	0.039*	5.34±0.99	5.63±0.91	0.061
IVS (cm)	1.14±0.36	0.95±0.17	<0.001*	1.15±0.38	1.10±0.32	0.528
RV (cm)	3.76±0.76	3.51±0.77	0.016*	3.82±0.78	3.64±0.70	0.274
LA (cm ²)	27.2±9.1	24.3±5.4	0.081	28.0±10.1	25.7±6.7	0.631
RA (cm ²)	24.7±7.8	22.9±6.2	0.195	25.2±8.5	23.8±6.3	0.748
LVEF (%)	55.5±15.0	48.7±12.3	<0.001*	56.4±15.2	53.4±14.5	0.214
EDV (mL)	163.8±83.6	165.2±52.6	0.235	161.1±87.1	168.3±75.7	0.483
ESV (mL)	81.6±81.2	93.3±68.2	<0.001*	79.0±85.2	86.4±71.9	0.319
SV (mL)	86.7±49.0	78.6±26.5	0.110	89.1±58.0	81.5±22.9	0.537
MM (gram)	122.4±49.6	104.7±36.0	0.009*	121.0±49.4	123.9±49.6	0.730
LV trabeculations (%)	7.1±4.85	27.4±5.7	<0.001*	4.8±4.3	11.8±3.8	<0.001*
Compact thickness (cm)	0.78±0.18	0.45±0.13	<0.001*	0.81±0.19	0.71±0.15	0.003*
Non-compact thickness (cm)	0.92±0.45	1.42±0.29	<0.001*	0.78±0.46	1.21±0.29	<0.001*
NC:C ratio	1.26±0.66	3.32±0.95	<0.001*	1.0±0.6	1.8±0.5	<0.001*
Minimal MA EDD (cm)	5.40±0.90	5.20±0.83	<0.001*	5.41±0.95	5.43±0.88	0.811
Maximal MA EDD (cm)	5.71±1.01	5.99±0.85	<0.001*	5.73±1.05	5.78±0.94	0.588
Max to min EDD ratio	1.06±0.04	1.16±0.09	<0.001*	1.06±0.06	1.06±0.04	0.163

ICT2HI, intracavitary T-2-weighted hyperintensity; LVNC, left ventricular non-compaction; LVEF<50%, impairment of left ventricle systolic function; NC:C, non-compact to compact myocardial layer thickness; NC>20%LV, percentage of trabeculations over 20% in total left ventricle mass; LVEDD, left ventricle end diastolic dimension in 4-chamber view; IVS, interventricular septum thickness in 4-chamber view; RV, right ventricle end diastolic dimension in 4-chamber view; LA & RA, left and right atrial area in square centimeters in 4-chamber view; LVEF, left ventricle ejection fraction; EDV, end diastolic volume; ESV, end systolic volume; SV, stroke volume; MM, myocardial mass in end-diastole; MA, mid to apical slices in 6-mm pile stack of short axes; EDD, end diastolic dimension; Max, maximal; Min, minimal. Data shown as numbers and percentages or mean with standard deviations.

*Statistically significant values ($p<0.05$).

MaxMinEDDR (Rho-CC=-0.129; $p=0.069$). There was no significant correlation of LVEF with cases with suspicion of LVNC (Rho-CC=0.109; $p=0.215$).

Geometry of the left ventricle in LVNC

Geometric changes in the sphericity of the left ventricle obtained from short axis slices of the NC-affected part of the left ventricle pointed toward the left ventricle eccentricity in cases

of LVNC. The maximal to minimal (perpendicular) end diastolic dimension ratio acquired in mid to apical (trabeculated myocardium section) was 1.17±0.08 in patients with LVNC, which was significantly different from the control group 1.06±0.04 ($p<0.001$). MaxMinEDDR for LVNC was also different from all the other studied etiologies of controls, as follows: LVNC (1.17±0.08), ruled out structural heart diseases or cardiomyopathy (1.06±0.04), HCM (1.07±0.05), DCM (1.05±0.04), ARVD (1.04±

Table 2. Characteristics of Patients with ICT2HI vs. the Control Group without ICT2HI (Control 3)

	Controls 3 (n=118)	ICT2HI (n=82)	Chi-square
	n (%)	n (%)	
No structural heart disease/cardiomyopathy	65 (55.1)	3 (3.7)	<0.001*
Left ventricular non-compaction	0 (0.0)	71 (86.6)	
Hypertrophic cardiomyopathy	17 (14.4)	4 (4.9)	
Dilative cardiomyopathy	23 (19.5)	3 (3.7)	
Arrhythmogenic right ventricle disease	5 (4.2)	0 (0.0)	
Myocarditis (subacute)	4 (3.4)	1 (1.2)	
Hypertensive heart disease	4 (3.4)	0 (0.0)	

ICT2HI, intracavitary T2 hyperintensity.

*Statistically significant values ($p < 0.05$).

0.04), subacute myocarditis (1.05 ± 0.01), and hypertensive heart disease (1.07 ± 0.02 ; $p < 0.001$). Other differences of LVNC specific characteristics and LV geometry in patients with LVNC and controls, and in the group of suspected LVNCs and their controls (controls 2) are shown in Table 1.

MaxMinEDDR correlated more powerfully with LVNC diagnostic parameters, attaining greater synergism, than its constituents with LVNC diagnosis (Rho-CC=0.695; $p < 0.001$), C-layer thickness (Rho-CC=-0.499; $p < 0.001$), NC:C>2.3:1 (Rho-CC=0.659; $p < 0.001$), and NC>20%LV (Rho-CC=0.675; $p < 0.001$).

T2-weighted characterization of studied cases

ICT2HI originates from blood flow through the trabeculated meshwork of the left ventricle, therefore, it has been the most convenient sign available in CMR imaging. ICT2HI was shown in all cases of LVNC ($n=71$; 100%) and small fraction of the control group patients ($n=11$; 8.5%). When subanalysis of cases was made according to different types of morphology, ICT2HI was found in 69/71 (88.5%) patients with LVNC, 4/20 (20.0%) patients with HCM, 3/25 (12%) of DCM, 1/5 (20%) of myocarditis, and none in ARVD (0/5) or hypertensive heart disease (0/4). None of the patients from the LVNC group had LV-intramycardial T2 hyperintensity. Characteristics of patients with ICT2HI ($n=82$; 41%) and control group without ICT2HI (group control 3; $n=118$; 59%) are shown in Table 2.

ICT2HI correlated significantly with diagnosis of LVNC (Rho-CC=0.890; $p < 0.001$) and established diagnostic parameters such as NC:C>2.3:1 (Rho-CC=0.824; $p < 0.001$), NC>20%LV (Rho-CC=0.871; $p < 0.001$) and C-myocardial layer thickness (Rho-CC=-0.611; $p < 0.001$). ICT2HI correlated with MaxMinEDDR (Rho-CC=0.618; $p < 0.001$), whilst its constituents showed weaker correlation; MaxEDD (Rho-CC=0.211; $p=0.003$) and MinEDD (Rho-CC=-0.091; $p=0.202$).

ICTHI correlated with parameters of the left ventricle geometry and function as follows; LVEF (Rho-CC=-0.348; $p < 0.001$), end systolic volume (Rho-CC=0.258; $p < 0.001$), stroke volume (Rho-CC=0.258; $p < 0.001$), LVEDD (Rho-CC=0.176; $p=0.012$), interventricular septum (Rho-CC=-0.174; $p=0.014$), right ventricle (Rho-CC=-0.156; $p=0.028$) and existence of LGE (Rho-CC=0.206; $p=0.004$).

Imaging studies on two cases with LVNC and studied diagnostic parameters are shown in Figs. 1 and 2.

Receiver operating characteristic curve analysis of LVNC diagnostic parameters

ROC curve analyses for assessment of diagnostic potential and cutoff values, estimated by the highest Youden index value, were done to establish a LVNC diagnosis with new supplementary parameters tested, as well as with the established diagnostic parameters.

MaxMinEDDR > 1.1009 had sensitivity of 91.6 (82.5–96.8), specificity 85.3 (78.0–90.9), positive likelihood ratio (+LR) 6.2 (5.6–6.9), and -LR 0.10 (0.04–0.2). Area under curve (AUC) was 0.919 (0.872–0.953), $p < 0.001$. ICT2HI > 0 (i.e., existing ICT2HI) had sensitivity of 100.0 (94.9–100.0), specificity 91.5 (85.3–95.7), +LR 11.7 (11.1–12.4), -LR (0.0), and AUC 0.957 (0.919–0.981), $p < 0.001$.

NC:C>2.2 had sensitivity of 98.6 (92.4–100.0), specificity 95.4 (90.2–98.3), and +LR 21.2 (20.2–22.2), -LR 0.02 (0.002–0.1). AUC 0.986 (0.958–0.997), $p < 0.001$. NC>20%LV had sensitivity of 97.2 (90.2–99.7), specificity 100.0 (97.2–100.0), and +LR of ∞ , -LR 0.028. AUC 0.986 (0.958–0.997), $p < 0.001$. C-layer thickness ≤ 0.63 cm had sensitivity of 94.4 (86.2–98.4), specificity 76.0 (67.7–83.1), and +LR 3.9 (3.5–4.4), -LR 0.07 (0.03–0.2). AUC 0.931 (0.887–0.962), $p < 0.001$. LVNC diagnostic parameters studied in ROC curve are presented cumulatively in Fig. 3.

Late gadolinium enhancement of LVNC and controls

The most common pattern in LVNC was linear LGE 36 (50.7%) or none LGE 30 (42.3%), which was significantly different from controls ($p < 0.001$) (Table 1). Conversely, patients with suspicion of LVNC did not have different LGE distributions from their controls [i.e. control 2 ($p=0.908$)]. LGE correlated with LVNC diagnosis (Rho-CC=0.156; $p=0.028$), NC:C>2.3:1 (Rho-CC=0.236; $p < 0.001$), NC>20%LV (Rho-CC=0.164; $p=0.020$), NC-layer thickness (Rho-CC=0.140; $p=0.049$), NC:C (Rho-CC=0.170; $p=0.016$) and MaxMinEDDR (Rho-CC=0.143; $p=0.044$). LGE did not correlate significantly with C-layer thickness (Rho-CC=-0.128; $p=0.071$).

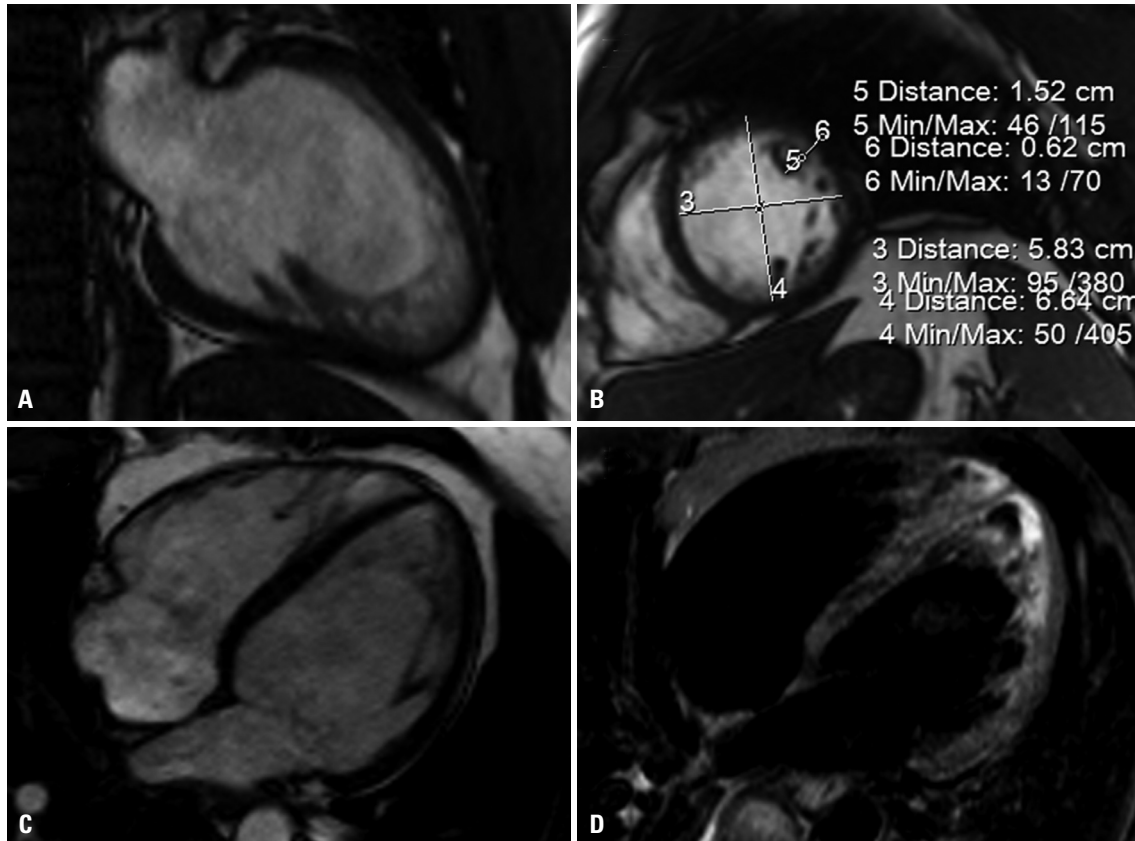


Fig. 1. Case of patient with LVNC. Case of LVNC with trabeculations existing on 23.5% of the left ventricle, left ventricle EDD of 6.29 cm, ejection fraction of 40% and confirmed non-compaction. (A) 2-chamber view, cine SSFP. (B) Short axis cine at end diastolic, marked white line showing: 3) Minimal EDD 5.83 cm, 4) Maximal EDD 6.64 cm, giving MaxMinEDDR=1.14; 5) NC-layer thickness 1.63 cm, and 6) C-layer thickness 0.42 cm, with NC:C=3.9; 4-chamber, cine SSFP. (C) 4-chamber, cine SSFP; showing trabeculations in apical region and lateral wall. (D) 4-chamber, turbo spin echo dark blood T2 fat saturation. Blood flow through non-compact layer is shown as hyperintense T2 signal, or the intracavitary T-2 weighted hyperintensity, which is of high spontaneous contrast to the compact part of the myocardium and to endocavitary space. LVNC, left ventricular non-compaction; EDD, end diastolic dimension; SSFP, steady state free precession.

DISCUSSION

Current guidelines on the LVNC, with regard to imaging, are still open to debate.^{9,18} Even though it may happen due to various clinical expressions of the disease, there is a great clinical challenge in everyday practice, in which the prevalence of trabeculations found on imaging studies is not negligible, and numerous cases become marginal or clinically suspicious.^{1,19,20} In the last decade, only a limited number of breakthrough novelties pertaining to LVNC imaging has been reported in literature. The present study, therefore, tested diagnostic potential of two diagnostic parameters that were not previously reported by other groups: CMR proof of blood flow through non-compact layer, similar to conceptualization in echocardiography, and changes in the geometry of the left ventricle affected by trabeculations.²¹

In the present study, different types of T2 sequences were found to be a very simple and convenient tool for clearly displaying intracavitary blood flow through the trabeculated zone of myocardium. ICT2HI was found to have very high sensitivity for LVNC, with all the cases being ICT2HI positive. Specificity

was quite good, since it was found in only 11 (8.5%) patients from the control group, and LVNC was excluded in all those suspicion cases based on confirmation in cine-SSFP sequences and an insufficient number of segments affected. ICT2HI was positive in cases with increased trabeculations of the left ventricle, which in our settings were patients with hypertrophic or DCM, those with excluded structural heart disease or insufficient criteria for cardiomyopathy, as well as subacute myocarditis in one case. Conventional fast/turbo spin echo sequences with dark blood preparation and inversion recovery sequences showed higher intensity signal in the region of the trabeculated myocardium, originating from muzziness of regional blood flow, than in the remaining part of the left ventricle cavity.²²⁻²⁴ This highly intense and spontaneous contrast to intracavitary blood flow, as well as to compact layer of myocardium, was also of fairly good visibility in cases with arrhythmia. Particular intracavitary localization of T2 hyperintensity is an advantage in cases with intramyocardial T2 alternated intensities, and also in cases of ischemic heart disease, myocarditis, and infiltrations such as sarcoidosis or malignancies.²⁵⁻²⁸ Since left ventricular trabeculations are unequally distributed

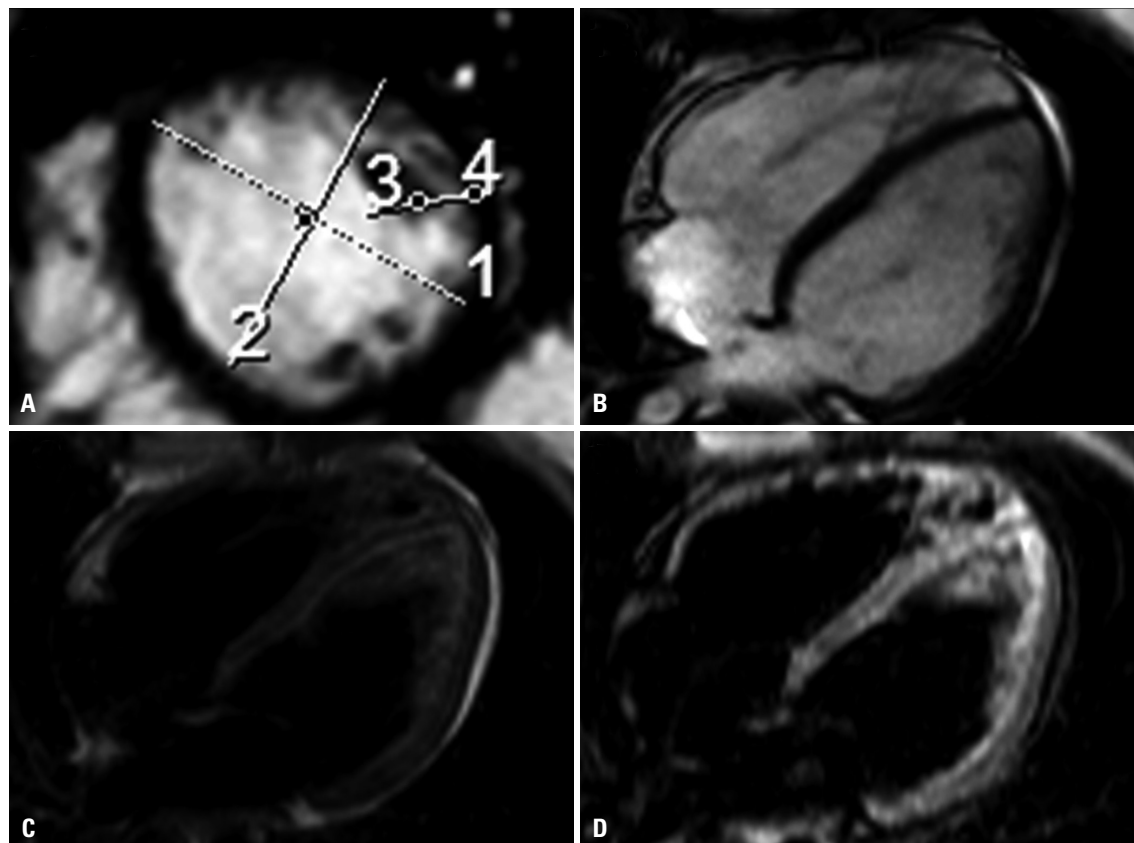


Fig. 2. Case two of LVNC. Case of LVNC with trabeculations existing on 23.5% of the left ventricle, ejection fraction of 50% and confirmed non-compaction. (A) short axis cine at end diastole, marked white line showing: 1) Maximal EDD 5.33 cm, 2) Minimal EDD 4.79 cm, giving MaxMinEDDR=1.11; 3) NC-layer thickness 1.63 cm, and 4) C-layer thickness 0.42 cm, with NC:C=3.9. (B) 4-chamber, cine steady state free precession, showing non-compact myocardium in apical and lateral wall. (C) 4-chamber turbo spin echo dark blood T2, showing intracavitary hyperintense T2 signal. (D) 4-chamber, inversion recovery dark blood T2, showing intracavitary hyperintense T2 signal. Blood flow through non-compact myocardium is shown as hyperintense T2 signal, i.e. ICT2HI, which is of high spontaneous contrast to the compact part of the myocardium and to endocavitary space. ICT2HI, intracavitary T2-weighted hyperintensity; MaxMinEDDR, maximal to minimal (perpendicular) end diastolic dimension ratio acquired in mid to apical short axis slices; NC:C, non-compact to compact myocardial layer thickness; NC>20%LV, percentage of trabeculations over 20% of total mass of the left ventricle. LVNC, left ventricular non-compaction; EDD, end diastolic dimension.

in different parts of the left ventricle cavity, it is possible that non-compact myocardium is undershot or missed due to sequential line of acquisition of particular chamber view in cine SSFP, especially in case of occurrence of the irregularities of the heart rhythms during that particular sequence.²⁹ In patients with arrhythmias, we occasionally found different degree of NC:C ratio in the same patient, when the particular SSFP sequence was repeated due to arrhythmia, or the ECG gating was switched to retrospective. In most of those circumstances, and those with arrhythmogenic decrease of spatial resolution, zones of ICT2HI were of rather fair visibility. In some cases, this was the reason to repeat the sequences of dedicated myocardium regions and to increase the diagnostic accuracy of trabeculations assessment, as in the patient shown in Fig. 2. ICT2HI showed high grade of correlations with diagnostic parameters for LVNC such as NC:C>2.3 and NC>20%LV, and correlated negatively with systolic function of the left ventricle. Most of the conventional parameters, such as left ventricle dimensions and volumetrics, showed weak to intermediate

level of correlation with ICT2HI.

Changes in the left ventricle geometry within the dedicated region affected with non-compact myocardium were also found to be connected with LVNC. Both maximal and minimal perpendicular end diastolic dimensions showed significant, be it mild or intermediate, grade of correlation with important diagnostic parameters of LVNC (compact layer thickness, NC:C>2.3:1 and NC>20%LV).^{9,17} On the other hand, their ratio (the MaxMinEDDR) attained additional synergism and was more powerfully connected, and indicated intermediate to high grade correlation with LVNC diagnostic criteria as well as ICT2HI. MaxMinEDDR for the patients was in the range of 95% CI 1.01–1.25, with LVNC being significantly different than in controls (1.17±0.08 vs. 1.06±0.04, respectively; $p<0.001$). In addition, MaxMinEDDR of LVNC was significantly different in all the heart disease etiologies studied such as dilative or HCM, arrhythmogenic right ventricle cardiomyopathy, subacute myocarditis, hypertensive heart disease and as well as “healthy” controls, in whom the structural heart disease and cardiomy-

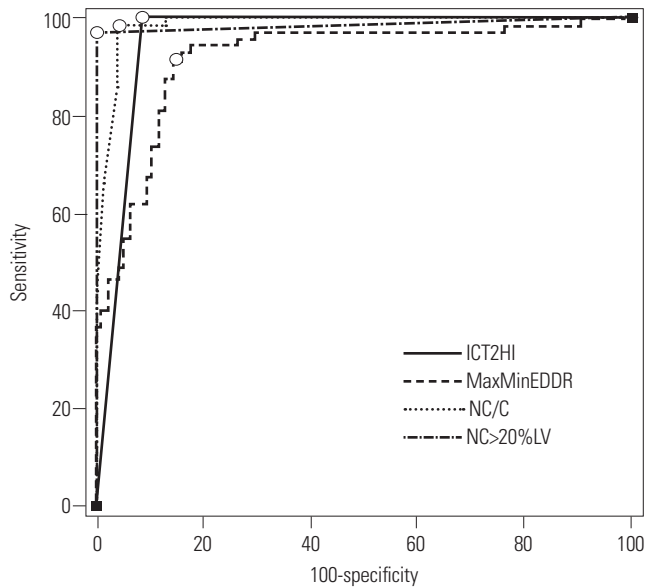


Fig. 3. Multiple receiver operating characteristic curve analysis for studied left ventricular non-compaction diagnostic parameters. ICT2HI, intracavitary T-2 weighted hyperintensity; MaxMinEDDR, maximal to minimal end diastolic dimension ratio; NC/C, non-compact to compact myocardial layer thickness; NC<20%LV, percentage of trabeculations over 20% in total left ventricle mass. ○ - ROC curve values with the highest Youden's Index.

opathy were ruled out. Clinically, even more significant differences were found in the cases with clinical suspicion of LVNC, pointing MaxMinEDDR as a diagnostic tool to make clear distinction between the cases with LVNC and those that are clinically suspicious.³⁰ The latter was also confirmed by a lack of significant correlations between suspicious LVNC and MaxMinEDDR, as well as its constituents.

In conclusion, two additional or supplementary diagnostic parameters for LVNC were identified in this study. ICT2HI was found to have relatively high specificity and high sensitivity for LVNC, with all the cases being ICT2HI positive. On the other hand, geometric eccentricity of the region with non-compacted myocardium was also found to be highly sensitive and specific for diagnosing LVNC. Furthermore, maximal to minimal end diastolic ratio of the patients with LVNC was significantly different from the group of cases with clinical suspicion of LVNC, which are commonly found in CMR imaging studies. CMR is probably among the best imaging diagnostics for patients with LVNC. Further studies on reassessment of novel parameters in different populations and settings would improve its reproducibility. In addition, studies on LVNC with clinical outcomes and patient follow up would be in relation to ICT2HI and MaxMinEDDR of an interest.^{15,31}

ACKNOWLEDGEMENTS

Authors would like to thank to Dr. Viktor Persic for technical support.

ORCID

Marko Boban <https://orcid.org/0000-0002-6129-575X>

REFERENCES

- Lofiego C, Biagini E, Pasquale F, Ferlito M, Rocchi G, Perugini E, et al. Wide spectrum of presentation and variable outcomes of isolated left ventricular non-compaction. *Heart* 2007;93:65-71.
- Bhatia NL, Tajik AJ, Wilansky S, Steidley DE, Mookadam F. Isolated noncompaction of the left ventricular myocardium in adults: a systematic overview. *J Card Fail* 2011;17:771-8.
- Oechslin EN, Attenhofer Jost CH, Rojas JR, Kaufmann PA, Jenni R. Long-term follow-up of 34 adults with isolated left ventricular noncompaction: a distinct cardiomyopathy with poor prognosis. *J Am Coll Cardiol* 2000;36:493-500.
- Luxán G, Casanova JC, Martínez-Poveda B, Prados B, D'Amato G, MacGrogan D, et al. Mutations in the NOTCH pathway regulator MIB1 cause left ventricular noncompaction cardiomyopathy. *Nat Med* 2013;19:193-201.
- Olivetto I, d'Amati G, Basso C, Van Rossum A, Patten M, Ermdin M, et al. Defining phenotypes and disease progression in sarcomeric cardiomyopathies: contemporary role of clinical investigations. *Cardiovasc Res* 2015;105:409-23.
- Xing Y, Ichida F, Matsuoka T, Isobe T, Ikemoto Y, Higaki T, et al. Genetic analysis in patients with left ventricular noncompaction and evidence for genetic heterogeneity. *Mol Genet Metab* 2006;88:71-7.
- Samsa LA, Yang B, Liu J. Embryonic cardiac chamber maturation: Trabeculation, conduction, and cardiomyocyte proliferation. *Am J Med Genet C Semin Med Genet* 2013;163C:157-68.
- Oechslin E, Jenni R. Left ventricular non-compaction revisited: a distinct phenotype with genetic heterogeneity? *Eur Heart J* 2011; 32:1446-56.
- Arbustini E, Weidemann F, Hall JL. Left ventricular noncompaction: a distinct cardiomyopathy or a trait shared by different cardiac diseases? *J Am Coll Cardiol* 2014;64:1840-50.
- Petersen SE, Selvanayagam JB, Wiesmann F, Robson MD, Francis JM, Anderson RH, et al. Left ventricular non-compaction: insights from cardiovascular magnetic resonance imaging. *J Am Coll Cardiol* 2005;46:101-5.
- Jenni R, Oechslin E, Schneider J, Attenhofer Jost C, Kaufmann PA. Echocardiographic and pathoanatomical characteristics of isolated left ventricular non-compaction: a step towards classification as a distinct cardiomyopathy. *Heart* 2001;86:666-71.
- Grothoff M, Pachowsky M, Hoffmann J, Posch M, Klaassen S, Lehmkuhl L, et al. Value of cardiovascular MR in diagnosing left ventricular non-compaction cardiomyopathy and in discriminating between other cardiomyopathies. *Eur Radiol* 2012;22:2699-709.
- Olivas-Chacon CI, Mullins C, Stewart K, Akle N, Calleros JE, Ramos-Duran LR. Magnetic resonance imaging of non-ischemic cardiomyopathies: a pictorial essay. *J Clin Imaging Sci* 2015;5:37.
- Marchal P, Lairez O, Cognet T, Chabbert V, Barrier P, Berry M, et al. Relationship between left ventricular sphericity and trabeculation indexes in patients with dilated cardiomyopathy: a cardiac magnetic resonance study. *Eur Heart J Cardiovasc Imaging* 2013;14: 914-20.
- Lieb W, Gona P, Larson MG, Aragam J, Zile MR, Cheng S, et al. The natural history of left ventricular geometry in the community: clinical correlates and prognostic significance of change in LV geometric pattern. *JACC Cardiovasc Imaging* 2014;7:870-8.
- Elliott P, Andersson B, Arbustini E, Bilinska Z, Cecchi F, Charron P, et al. Classification of the cardiomyopathies: a position statement

- from the European Society Of Cardiology Working Group on Myocardial and Pericardial Diseases. *Eur Heart J* 2008;29:270-6.
17. Jacquier A, Thuny F, Jop B, Giorgi R, Cohen F, Gaubert JY, et al. Measurement of trabeculated left ventricular mass using cardiac magnetic resonance imaging in the diagnosis of left ventricular non-compaction. *Eur Heart J* 2010;31:1098-104.
 18. Fazio G, Novo G, D'Angelo L, Visconti C, Sutera L, Grassedonio E, et al. Magnetic resonance in isolated noncompaction of the ventricular myocardium. *Int J Cardiol* 2010;140:367-9.
 19. Gati S, Chandra N, Bennett RL, Reed M, Kervio G, Panoulas VF, et al. Increased left ventricular trabeculation in highly trained athletes: do we need more stringent criteria for the diagnosis of left ventricular non-compaction in athletes? *Heart* 2013;99:401-8.
 20. Choudhary P, Hsu CJ, Grieve S, Smillie C, Singarayar S, Semsarian C, et al. Improving the diagnosis of LV non-compaction with cardiac magnetic resonance imaging. *Int J Cardiol* 2015;181:430-6.
 21. Stöllberger C, Finsterer J, Blazek G. Left ventricular hypertrabeculation/noncompaction and association with additional cardiac abnormalities and neuromuscular disorders. *Am J Cardiol* 2002;90:899-902.
 22. Partovi S, Fram EK, Karis JP. Fast spin echo MR imaging. *Neuroimaging Clin N Am* 1999;9:553-76.
 23. Naganawa S, Jenner G, Cooper TG, Potchen EJ, Ishigaki T. Rapid MR imaging of the liver: comparison of twelve techniques for single breath-hold whole volume acquisition. *Radiat Med* 1994;12:255-61.
 24. Pui MH, Chang SK. Comparison of inversion recovery fast spin-echo (FSE) with T2-weighted fat-saturated FSE and T1-weighted MR imaging in bone marrow lesion detection. *Skeletal Radiol* 1996;25:149-52.
 25. Kim HW, Van Assche L, Jennings RB, Wince WB, Jensen CJ, Rehwald WG, et al. Relationship of T2-weighted MRI myocardial hyperintensity and the ischemic area-at-risk. *Circ Res* 2015;117:254-65.
 26. Lurz P, Luecke C, Eitel I, Föhrenbach F, Frank C, Grothoff M, et al. Comprehensive cardiac magnetic resonance imaging in patients with suspected myocarditis: The MyoRacer-Trial. *J Am Coll Cardiol* 2016;67:1800-11.
 27. Yang Y, Safka K, Graham JJ, Roifman I, Zia MI, Wright GA, et al. Correlation of late gadolinium enhancement MRI and quantitative T2 measurement in cardiac sarcoidosis. *J Magn Reson Imaging* 2014;39:609-16.
 28. Allen BC, Mohammed TL, Tan CD, Miller DV, Williamson EE, Kirsch JS. Metastatic melanoma to the heart. *Curr Probl Diagn Radiol* 2012;41:159-64.
 29. Lachhab A, Doghmi N, Elfakir Y, Taoussi O, Benyass A, Haddour L, et al. Insights from magnetic resonance imaging of left ventricular non-compaction in adults of North African descent. *Int Arch Med* 2012;5:10.
 30. Choi Y, Kim SM, Lee SC, Chang SA, Jang SY, Choe YH. Quantification of left ventricular trabeculae using cardiovascular magnetic resonance for the diagnosis of left ventricular non-compaction: evaluation of trabecular volume and refined semi-quantitative criteria. *J Cardiovasc Magn Reson* 2016;18:24.
 31. Krämer J, Bijnens B, Störk S, Ritter CO, Liu D, Ertl G, et al. Left ventricular geometry and blood pressure as predictors of adverse progression of Fabry cardiomyopathy. *PLoS One* 2015;10:e0140627.