

# Diagnostic challenge of anti-GQ1b syndrome: differential diagnosis between Miller Fischer syndrome and Bickerstaff 's brainstem encephalitis

---

Sonnenschein, Ivan; Tomić, Zoran; Perković, Olivio; Zadković, Barbara; Bučuk, Mira

Source / Izvornik: **Neurologia Croatica, 2014, 63, 83 - 86**

Journal article, Published version

Rad u časopisu, Objavljena verzija rada (izdavačev PDF)

Permanent link / Trajna poveznica: <https://urn.nsk.hr/urn:nbn:hr:184:877861>

Rights / Prava: [In copyright](#) / [Zaštićeno autorskim pravom.](#)

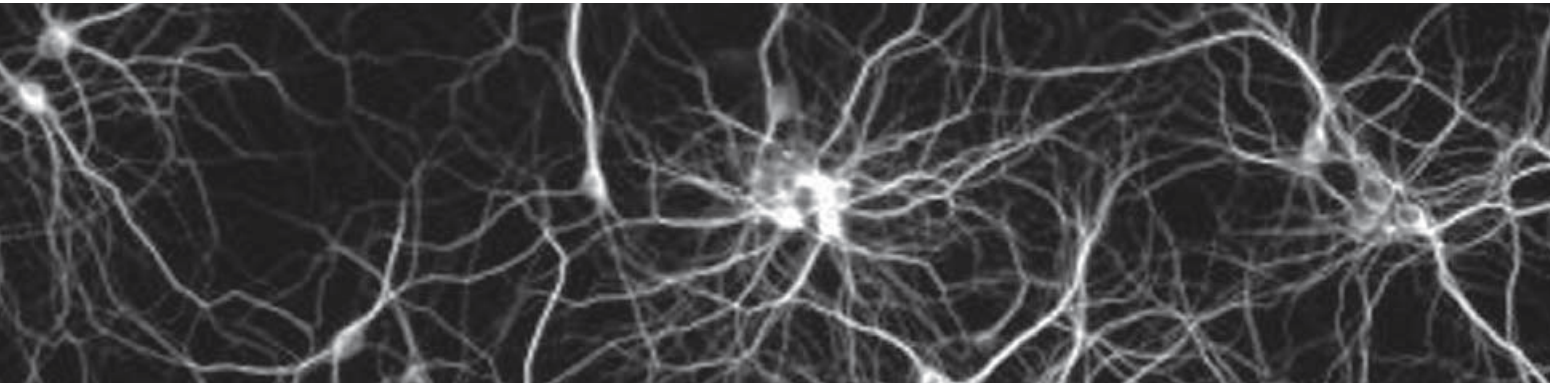
Download date / Datum preuzimanja: **2024-08-29**



Repository / Repozitorij:

[Repository of the University of Rijeka, Faculty of Medicine - FMRI Repository](#)





# Diagnostic challenge of anti-GQ1b syndrome: differential diagnosis between Miller Fischer syndrome and Bickerstaff's brainstem encephalitis

Ivan Sonnenschein<sup>1</sup>, Zoran Tomić<sup>1</sup>, Olivio Perković<sup>1,2</sup>, Barbara Zadković<sup>1</sup>, Mira Bučuk<sup>1,2</sup>

**ABSTRACT** – Miller Fisher syndrome (MFS) may be considered as a rare variant of Guillain-Barré syndrome (GBS). Together with GBS, Bickerstaff's brainstem encephalitis and acute ophthalmoparesis without ataxia, MFS is in the group of anti-GQ1b syndrome disorders (anti-GQ1b Sy). Among all GBS variants, MFS is distinctive, presenting with acute symptoms of ophthalmoparesis, ataxia and areflexia, but without progressive limb weakness as the most characteristic symptom of GBS. MFS is a clinical entity based on typical clinical presentation and defined symptoms, and the finding of specific anti-GQ1b antibodies is not sufficient for MFS diagnosis. The objective of this case report is to demonstrate the diversity of anti-GQ1b Sy clinical presentation. Here we describe a case of a male patient with acute bilateral ophthalmoparesis, mydriasis and unilateral right infranuclear facial nerve palsy, in whom muscle tendon reflexes were preserved and no ataxia was present. Serum antiganglioside antibody test was positive for anti-GQ1b antibody, confirming the presupposed diagnosis of MFS. Although MFS is rare, it should be considered in patients with acute development of ophthalmoplegia. In rare cases of MFS with uncommon presentation, as it was in our case, positive serum antiganglioside antibody test will lead to the right diagnosis.

**Key words:** antiganglioside antibody, anti-GQ1b syndrome, Bickerstaff's encephalitis, Guillain-Barré syndrome, Miller Fisher syndrome

## INTRODUCTION

Miller Fisher syndrome (MFS) is a rare acquired autoimmune polyneuropathy, a clinical variant of

<sup>1</sup>Rijeka University Hospital Center, Clinical Department of Neurology, Rijeka, Croatia

<sup>2</sup>School of Medicine, University of Rijeka, Rijeka, Croatia

Guillain-Barré syndrome (GBS) that was described in 1956 (1). It accounts for 5%-10% of all GBS cases. Symptoms that make MFS different from other GBS variants are acute ophthalmoplegia, ataxia and areflexia, but without limb weakness. MFS is a clinical entity based on typical clinical presentation and defined symptoms and the finding of specific anti-GQ1b antibodies is not sufficient for MFS diagnosis. MFS is usually preceded by infection of gastrointestinal tract, manifesting in most cases with diarrhea. Even though not specific to MFS, anti-GQ1b antibodies are present in serum of more than 85% of patients with MFS (2,3). In 2001, Odaoka coined the term anti-GQ1b syndrome (anti-GQ1b Sy) performing a large study on 194 patients (4) and proving the presence of anti-GQ1b antibody not only in MFS patients, but also in those GBS patients with ophthalmoplegia, Bickerstaff's brainstem encephalitis (BBE), acute ophthalmoparesis (AO) without ataxia, and those in whom the symptoms of MFS/GBS and BBE/GBS overlapped suggesting a common autoimmune mechanism in the pathogenesis of these illnesses. In the clinical presentation they found that every patient in whom the symptoms of MFS and GBS (MFS/GBS) and symptoms of BBE and GBS (BBE/GBS) overlapped had external ophthalmoplegia; every patient with MFS/GBS had hyporeflexia or areflexia; every patient with MFS and BBE had ataxia; 68% of the patients with MFS/GBS and 45% of those with BBE/GBS had ataxia; 91% of the patients with BBE/GBS, 67% with BBE, and 53% with AO had decreased or absent tendon reflexes. This work confirmed, clinically and by immunological findings, the close relation between MFS, GBS, BBE and AO. The course of MFS as well as that of BBE can be favorable, but it can be ameliorated with intravenous immunoglobulin (IVIg) treatment or plasmapheresis (5,6). In one reported case of severe plasmapheresis and immunoglobulin therapy resistant BBE, treatment with rituximab was applied (7).

## CASE REPORT

A 19-year-old male student was admitted to our department complaining of double and blurred vision that had occurred three days prior to admission. Moderate headache and unsteadiness while walking were present during the first two days. Seven days before the onset of symptoms, he had diarrhea for one day, but otherwise his medical history was unremarkable. On neurological examination, ocular movements were impaired with prom-

inent limitation of abduction, moderate limitation of supraduction bilaterally, and his pupils were dilated with poor reaction to light. He had no limb weakness, no sensory impairment, and his gait was normal. He was alert, no ataxia was present, his tendon reflexes were normal and the plantar response was flexor at the onset and during the course of the disease. His physical examination and blood pressure were normal. Three days after admission, he developed right infranuclear facial palsy. He could not whistle or wrinkle his forehead on the right side and he could not close his right eye. These findings after admission, normal tendon reflexes and absence of ataxia made the diagnosis of MFS uncertain.

The results of blood tests including erythrocyte sedimentation rate, blood cell count, blood glucose, liver and kidney enzyme analysis, thyroid enzyme analysis, as well as urine analysis revealed no abnormality. Testing for neurotropic viruses (herpes simplex, varicella-zoster, cytomegalovirus, Epstein-Barr virus and human immunodeficiency virus) as well as the results of Western blot analysis to exclude Lyme borreliosis were negative. Cerebrospinal fluid (CSF) analysis performed on day 7 of symptom onset demonstrated albuminocytologic dissociation with protein level up to 0.9 g/L. The analysis of antiganglioside antibody in serum was positive for anti-GQ1b antibody in the first week. Nerve conduction studies of the facial nerves showed slowing of conduction velocities on the right side with normal compound action potential amplitude and absent blink reflex on the right side and normal on the left side. Peripheral motor and sensory nerve conduction studies in the upper and lower limbs (ulnar, median, peroneal, tibial and sural nerve bilaterally) were normal, as well as F-wave studies (ulnar, peroneal and tibial nerve bilaterally). Magnetic resonance imaging of the brain was unremarkable.

According to history data, neurological examination, peripheral nerve conduction studies, results of CSF analysis, and additional result of positive antiganglioside anti-GQ1b antibodies, a variant of anti-GQ1b Sy was presupposed (probably BBE or MFS/BBE overlap) and IVIg therapy was started immediately. The patient gradually improved over the following month and achieved complete recovery within two months.

## DISCUSSION

Miller Fisher syndrome is well distinguished from classical GBS by its characteristic triad of symp-

toms: ataxia, areflexia and ophthalmoplegia. Sometimes it can be difficult to differentiate MFS from BBE. BBE is considered to affect central nervous system, but decreased or absent tendon reflexes, ataxia, ophthalmoplegia as well as ptosis, mydriasis and facial palsy may be present in BBE and MFS. Albuminocytological dissociation in CSF may be present in both BBE and MFS (8). Anti-GQ1b antibodies can be seen in both of these entities (8). There are cases of BBE with atypical neurological symptoms (9). Because of the similarities in the clinical presentation of MFS and BBE, there is an opinion that they form a continuous spectrum with variable central and peripheral nervous system involvement (10). Altered sensorium in BBE, if present, can make a distinction between these two entities. Among patients with MFS, some differences in clinical presentation can be seen. Bae *et al.* report on a case of a woman with internal ophthalmoplegia as the first symptom of MFS (11). Fleury *et al.* describe five MFS patients with bilateral acute mydriasis with or without external ophthalmoplegia (12). Sometimes it can be difficult to presuppose the diagnosis of MFS when ophthalmoplegia is the sole symptom, but if ataxia and areflexia are present from the onset, or when they subsequently develop, reaching the diagnosis is much easier. In both circumstances, the nerve conduction studies and the results of CSF analysis can be very helpful, but a positive result of antiganglioside anti-GQ1b antibody test is usually needed to confirm the diagnosis. In a series of 100 patients with isolated bilateral or unilateral abducens nerve palsy, the diagnosis of atypical mild form of MFS was confirmed in 25 patients who were anti-GQ1b antibody positive (13). Our patient developed unilateral infranuclear facial nerve palsy that is not quite common presentation of MFS, and to our knowledge, it is mainly bilateral. Doo-Hyuk *et al.* describe four patients with MFS who developed facial palsy from day 8 to day 16 after initial symptom onset and from day 5 to day 9 after IVIG treatment (14).

In our case, the signs of unilateral infranuclear right facial palsy developed six days after the initial symptoms of external and internal ophthalmoplegia occurred, and before the treatment with IVIG. On neurological examination and during the disease course, neither ataxia nor areflexia were present. Cases of MFS without ataxia have been previously reported, but they are rare (15). Clinical features, the results of blink reflex analysis and the albuminocytologic dissociation in CSF led us to presume the presence of atypical MFS, which was

confirmed by the positive findings of serum anti-ganglioside anti-GQ1b antibodies.

## CONCLUSION

Both BBE and MFS are considered to form the same and continuous clinical spectrum of the anti-GQ1b Sy, as there is good evidence that both disorders have similar clinical and laboratory features. We present our case in order to emphasize the diversity of anti-GQ1b Sy clinical presentation and to stress the importance of antiganglioside antibody testing in all, but even more in atypical forms, where this testing is important to confirm the diagnosis.

## REFERENCES

1. Fisher M. An unusual variant of acute idiopathic polyneuritis (syndrome of ophthalmoplegia, ataxia and areflexia). *N Engl J Med* 1956; 255: 57-65.
2. Chiba A, Kusunoki S, Shimizu T *et al.* Serum IgG antibody to ganglioside GQ1b is a possible marker of Miller Fisher syndrome. *Ann Neurol* 1992; 31: 677-9.
3. Kanzaki M, Kaida K, Ueda M, *et al.* Ganglioside complexes containing GQ1b as targets in Miller Fisher and Guillain-Barré syndromes. *J Neurol Neurosurg Psychiatry* 2008; 79: 1148-52.
4. Odaka M. AntiGq1b IgG antibody syndrome: clinical and immunological range. *J Neurol Neurosurg Psychiatry* 2001; 70: 50-5.
5. Mori M, Kuwabara S, Fukutake T *et al.* Intravenous immunoglobulin therapy for Miller Fisher syndrome. *Neurology* 2007; 68: 1144-6.
6. Overell JR, Willison HJ. Recent developments in Miller Fisher syndrome and related disorders. *Curr Opin Neurol* 2005; 18: 562-6.
7. Hardy TA, Barnett MH, Mohamed A, Garsia RJ, Davies L. Severe Bickerstaff's encephalitis treated with rituximab: serum and CSF GQ1b antibodies. *J Neuroimmunol* 2012; 251: 107-9.
8. Ito M. Bickerstaff's brainstem encephalitis and Fisher syndrome form a continuous spectrum: clinical analysis of 581 cases. *J Neurol* 2008; 255: 674-82.
9. Koga M. Nationwide survey of patients in Japan with Bickerstaff's brainstem encephalitis: epidemiological and clinical characteristics. *J Neurol Neurosurg Psychiatry* 2012; 83: 1210-5.



10. Yuki N. Fisher syndrome and Bickerstaff brainstem encephalitis (Fisher-Bickerstaff syndrome). *J Neuroimmunol* 2009; 215: 1-9.
11. Bae JS, Kim JK, Kim SH *et al.* Bilateral internal ophthalmoplegia as an initial sole manifestation of Miller Fisher syndrome. *J Clin Neurosci* 2009; 16: 963-4.
12. Fleury V, Aqallal A, Lagrange E, *et al.* Acute bilateral mydriasis associated with anti-GQ1b antibody. *J Clin Neurosci* 2010; 17: 514-5.
13. Tatsumoto M, Odaka M, Hirata K *et al.* Isolated abducens nerve palsy as a regional variant of Guillain-Barré syndrome. *J Neurol Sci* 2006; 243: 35-8.
14. Doo-Hyuk K, Jung IS, Woo HH, *et al.* Clinical and electrophysiological characteristics of delayed facial palsy in Miller-Fisher syndrome. *Korean J Clin Neurophysiol* 2011; 13: 44-7.
15. Yuki N, Odaka M, Hirata K. Acute ophthalmoparesis (without ataxia) associated with anti-GQ1b IgG antibody: clinical features. *Ophthalmology* 2001; 108: 196-200.

**Address for correspondence:** Ivan Sonnenschein, MD, Rijeka University Hospital Center, Clinical Department of Neurology, Krešimirova 42, HR-51000 Rijeka, Croatia; E-mail: ivansonnenschein@gmail.com

## Dijagnostički izazov sindroma anti-GQ1b: diferencijalna dijagnoza između Miller-Fischerova sindroma i Bickerstaffova encefalitisa moždanog debla

SAŽETAK – Miller Fisherov sindrom (MFS) može se smatrati rijetkom varijantom Guillain-Barréova sindroma (GBS). MFS, zajedno s GBS, Bickerstaffovim encefalitisom moždanog debla (BBE) i akutnom oftalmoparezom (AO) bez ataksije, pripada skupini poremećaja unutar anti-GQ1b sindroma (anti-GQ1b Sy). Između svih varijanta GBS, MFS se manifestira na specifičan način akutnim razvojem oftalmoplegije, ataksije i arefleksije, no bez progresivne slabosti mišića ekstremiteta kao karakterističnog znaka GBS. MFS je klinički entitet temeljen na tipičnoj kliničkoj slici i određenim simptomima, no nalaz specifičnih anti-GQ1b protutijela nije dovoljan za dijagnozu MFS. Cilj je ovoga članka prikazati različitosti kliničke prezentacije anti-GQ1b sindroma. Opisujemo slučaj bolesnika s naglim razvojem obostrane oftalmoplegije, midrijaze i unilateralne desnostrane infranuklearne pareze ličnog živca, bez ataksije te urednih miotatskih refleksa. S obzirom na kliničku sliku i razvoj simptoma postavljena je sumnja na MFS, što je potvrđeno i pozitivnim nalazom serumskih anti-GQ1b protutijela. U zaključku, premda se rijetko pojavljuje, na MFS treba pomisliti u diferencijalnoj dijagnozi kod bolesnika s naglim razvojem oftalmoplegije. U rijetkim slučajevima neuobičajene prezentacije MFS-a, kao u našem slučaju, pozitivan nalaz antigangliozidnih protutijela omogućava postavljanje točne dijagnoze.

**Ključne riječi:** antigangliozidna protutijela, anti-GQ1b sindrom, Bickerstaffov encefalitis, Guillain-Barréov sindrom, Miller Fisherov sindrom