

# Detection of Coxarthrosis in Femoral Head Radiographic Images Seems Limited Mainly to Vertically Oriented Pattern Features

---

Rapan, Sasa; Jovanovic, Savo; Gulan, Gordan; Kurbel, Sven

Source / Izvornik: *Collegium antropologicum*, 2013, 37, 175 - 181

Journal article, Published version

Rad u časopisu, Objavljena verzija rada (izdavačev PDF)

Permanent link / Trajna poveznica: <https://urn.nsk.hr/urn:nbn:hr:184:435501>

Rights / Prava: [In copyright](#)/[Zaštićeno autorskim pravom.](#)

Download date / Datum preuzimanja: **2024-12-02**



Repository / Repozitorij:

[Repository of the University of Rijeka, Faculty of Medicine - FMRI Repository](#)



# Detection of Coxarthrosis in Femoral Head Radiographic Images Seems Limited Mainly to Vertically Oriented Pattern Features

Saša Rapan<sup>1</sup>, Savo Jovanović<sup>1</sup>, Gordan Gulan<sup>2</sup> and Sven Kurbel<sup>3</sup>

<sup>1</sup> »J. J. Strossmayer« University, School of Medicine, Department of Orthopedics, Osijek, Croatia

<sup>2</sup> University of Rijeka, School of Medicine, Department of Orthopedics, Rijeka, Croatia

<sup>3</sup> »J. J. Strossmayer« University, School of Medicine, Department of Physiology, Osijek, Croatia

## ABSTRACT

*Out of 120 conventional hip joint X-rays, two independent examiners have chosen 27 healthy and 62 coxarthrotic joints. Central parts of femoral head images were digitalized (300 points/inch) and pixel density values analysed. Two methods were applied separately to horizontal rows and to vertical columns: variance coefficient calculation and power coefficients of Fourier harmonics. The arithmetic mean and median of variance coefficient for 256 pixel columns were both significantly higher in data of osteoarthrotic femurs (Mann-Whitney U-test,  $p=0.0046$  and  $p=0.0011$ , respectively), while no difference was found for horizontal rows. The arithmetic mean and median of variance coefficient for 128 pixels long columns were significantly lower in data of osteoarthrotic femurs ( $p<0.001$ ) with wider standard deviation ( $p=0.0274$ ), while standard deviation was significantly lower in rows of coxarthrotic heads ( $p<0.001$ ). Fourier analysis of 128 pixel vertical columns showed significantly higher values in coxarthrotic femoral heads (from 1<sup>st</sup> harmonic, wave length of 10.8 mm to 33<sup>rd</sup> harmonic, wave length of 0.328 mm,  $p<0.05$ ). Fourier analysis of 128 pixel horizontal rows did not differ much between coxarthrotic and normal femoral heads. Only values for the 60<sup>th</sup> and 61<sup>st</sup> harmonic (wavelength near 0.2 mm) showed significantly lower power in coxarthrotic images than in controls ( $p<0.01$ ). Results suggest that in the analyzed set of digitalized x-ray femoral head images, information regarding osteoarthrotic changes in the central part of femoral head is detectable mainly through mathematic postprocessing of vertically oriented patterns.*

**Key words:** X-ray post processing, hip osteoarthritis, femoral head structure, Fourier analysis

## Introduction

Quantitative description of bone structure can help in explaining pathogenesis of various bone disorders. It is well known that trabecular structure is characterized by strong contrast in density between the bone trabeculae and tissue. The bone structure and its changes can be evaluated and presented by mathematical models. Textures are pattern features repeating themselves within a certain part of image<sup>1</sup>. Many mathematical methods for pattern recognition are used for image post processing. The Fourier method is one of the basic statistical methods used in extraction for sample significance. In analysis of osteoporosis in the mandibular and maxillary bone radiographs this method showed specificity of 96%, sensitivity of 92%, with error up to 22%<sup>3</sup>. Since the trabecular shape is determined by the force trajectories,

trabecular bone is expected to be among few fractal structures in our body. When analyzing fractal structures, exact values of all relevant indicators are crucial in data collecting. Fractal analysis was used in detection of osteoporosis and other bone disorders. Sensitivity of fractal analysis of trabecular structure has been considered in the overview by Geraets and van der Stelt<sup>4</sup> in which authors clearly specify all risks of errors when such analysis is applied to the complex bone structure. It seems certain that for the bone, the future might belong to using 3D micro CT data of trabecular structures. Until then, standardization of X-ray imaging is required if the goal is to detect the initial phase of osteoporosis, when bone trabeculae are only negligibly damaged. Since development of the hip osteoarthritis also involves alter-

ation of the femoral head architecture, here presented study is trying to identify features characteristic for the presence of osteoarthritis in image patterns of digitalized femoral head X-rays that belong to arthrotic and normal hips. The study is aiming to advance recognition of the altered femoral head architecture due to hip osteoarthritis.

### Materials and Methods

Here presented study involved 120 digitalized conventional X-ray images of femoral heads in osteoarthrotic and healthy hip joints, randomly chosen from the archived X-rays at the Department of Orthopaedics, Osijek, University Hospital Center, Croatia.

The initial requirement for inclusion of a patient into the study was that their hip replacement surgery had been completed more than two years ago so that performed examination of old images could not have any influence on their treatment. Patients that were operated on all had advanced primary hip osteoarthritis. This retrospective study design has been approved by the Ethical Committees of our hospital and of Osijek School of Medicine, since it was done as a part of research activities of both institutions. All patients entering our institution, before starting any kind of diagnostic or treatment sign an informal consent that also includes the statement that their data, images etc. can be used for educational and scientific purposes, under the condition that their privacy will be protected. This provision was strictly obeyed and all digitalized images were coded and all other data kept strictly confidential.

All hip X-ray images were independently evaluated by two orthopaedists either as healthy controls, or coxarthrotic. After the evaluation, 99 images that have been equally read off by both examiners, (63 from osteoarthrotic hips and 37 normal controls) were included in this study. The average age of patients included in the study was 62.3 years (the range from 54 to 73 years), with more women than men (hip X-rays belonged to 58 women and 41 men).

Central parts of femoral heads in selected X-ray images were scanned by Mycrotect film scanner, in a 16-bit grey scale, density of 300 pixels per inch (pixel width 0.0085 mm), with the image placed vertically into the scanner, so that the scanned area consisted of horizontal rows and vertical columns, in which the terms horizontal and vertical refer to the format of film being scanned and not to the exact position of the patient’s body during the X-ray exposure.

After a trial scan, the region of interest, size of 256x256 pixels, has been picked up from X-image, which corresponds to the femoral head avoiding edges (shown together in Figure 1).

Records in TIFF (Tagged Image File Format) obtained by scanning were converted to an 8-bit PCX (PC Paintbrush Exchange) format (256 levels of grey scale).




Fig. 1. Thumbnails of the analyzed set of femoral head images, based on two independent evaluators. By both of them, images with codes starting with a »B« letter were considered coxarthrotic, while those starting with a »Z« letter were considered normal control images.

Later, they were read by a custom written software as series of numbers of individual pixel density and stored in textual records for further analysis, as either a single 256 x256 matrix or divided in four matrices (128x128 pixels).

### Variance coefficient analysis

Variance coefficient analysis of horizontal and vertical series of pixels was deliberately chosen as a simple dimensionless statistical measure of data variability that is independent on absolute value of pixel density. It was deliberately done on two scales to allow detection of fine and coarse variations in pixel density. First, the large 256 x256 pixel matrices were analyzed as 256-pixel long sequences that form a horizontal row or a vertical column. The goal of this approach was to detect coarse patterns in pixel density not accessible in analysis of shorter series of pixels. The same procedure was applied to small 128 x 128 pixel matrices.

Based on an unexpected initial observation that within a single matrix, variance coefficient values for vertical columns, are of significantly different distribution in comparison to the horizontal rows, it was decided to analyze rows and columns separately. So, for each matrix, separate arithmetic means of variability coefficients were calculated for all rows and for all columns.

### Fourier analysis of linear pixel sequences

Fourier analysis was done in small 128x128 matrices. The average power specter of harmonics was calculated separately for 128 rows and for 128 columns. As the

power of harmonics was expressed in the grey scale units (ranging from 0 to 127), to obtain non-dimensional and thus better comparability of various images, the average harmonic power values were divided by the average pixel density of that matrix. Calculation was done by a short program written in MS-DOS QBasic.

## Results

### Results of the variance coefficient analysis

Figure 2 shows results of dispersion of the variance coefficient values calculated from 256 long columns and rows. The arithmetic means and medians of variance coefficients for columns were significantly higher in data of osteoarthrotic hips (Mann-Whitney U test,  $p=0.00456$  and  $p=0.00117$ , respectively). No significant difference between osteoarthrotic and control images was found in indicators of the arithmetic mean and median of variance coefficient for horizontal rows ( $p=0.136525$  and  $p=0.44760$ , respectively).

If only controls are considered, there is a difference in the arithmetic mean and median of variance coefficient values between rows and columns (Wilcoxon matched pairs test  $p=0.0049$  and  $p=0.0065$ , respectively). Described results suggest that analyzed images of normal femoral heads showed smaller arithmetic mean and median values of variance coefficients for vertical columns when compared with horizontal rows. In images of coxarthrotic femur heads, no such difference between columns and rows has been found (for arithmetic mean  $p=0.1771$ , for median  $p=0.2238$ ), suggesting that the cox-

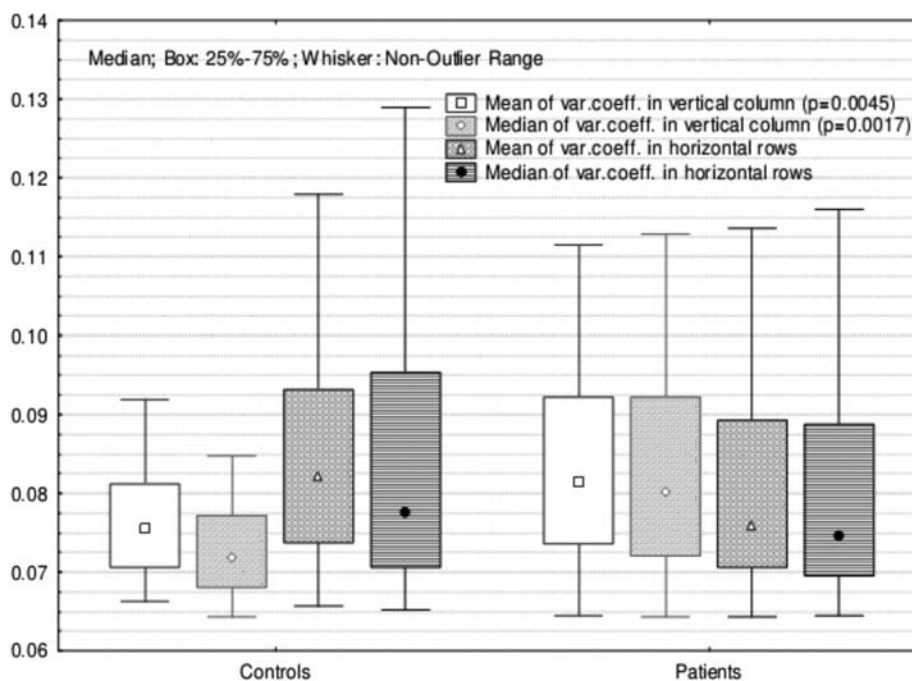


Fig. 2. Results of the variance coefficient analysis using 99 large matrices (256x256 pixels). Comparison is done between images from normal (labelled »Controls«) and coxarthrotic joints (labelled »Patients«).

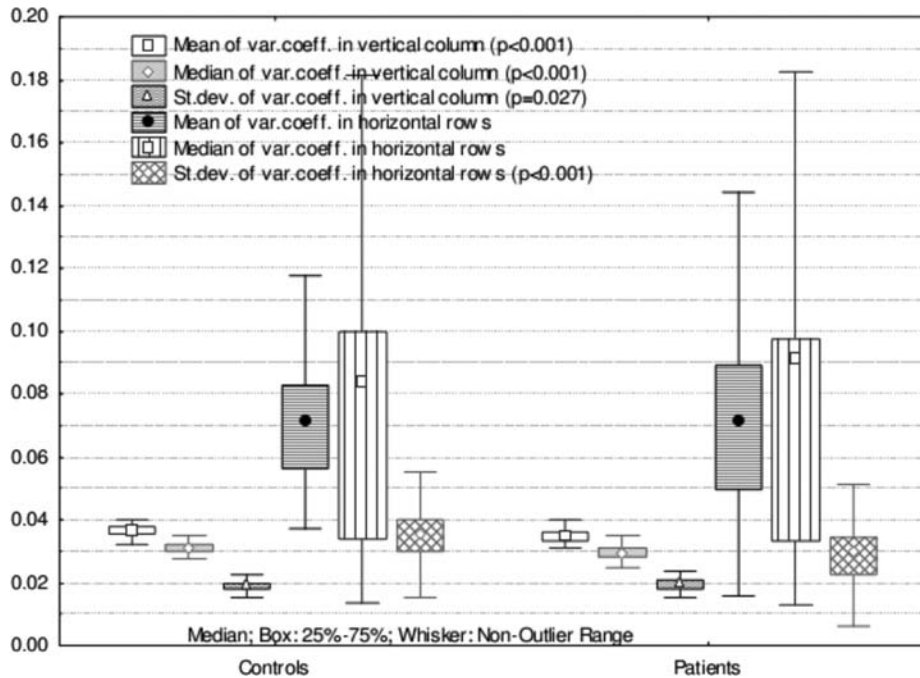


Fig. 3. Results of the variance coefficient analysis using 396 small (128x128 pixels) matrices. Comparison is done between matrices from normal (labeled »Controls«) and coxarthrotic joints (labelled »Patients«).

arthrotic process in our patients has increased values of arithmetic mean of variance coefficients only in vertical 256 pixel long columns.

Results of a similar analysis on 396 small matrices of 128x128 pixels are shown in Figure 3. At this smaller scale, the distribution of variance coefficients for vertical columns of coxarthrotic femoral heads, compared with controls, was characterized by the lower median value and arithmetic mean (Mann-Whitney U-test,  $p < 0.001$ ) and wider standard deviation ( $p = 0.0274$ ). Median and the arithmetic mean of variance coefficients for horizontal rows were similar in coxarthrotic femur heads and controls, ( $p = 0.5258$  and  $p = 0.8502$ ), while their standard deviation was significantly lower in coxarthrotic heads ( $p < 0.001$ ).

When comparing distribution of variance values of rows with columns in the same matrix, at this smaller scale, polarity of pattern features was significant in coxarthrotic and in control matrices (Wilcoxon matched pairs test for the arithmetic mean and median,  $p < 0.001$  in both groups).

Taken all these results together, a possible interpretation for variance coefficients of 256 pixels long columns and rows of 256 pixels is that the strain of a health femoral head reduces coarse variety in the bone structure along the vertical direction, while shear stress and enhanced oblique structures alter some features that are detectable when horizontal rows are analyzed. Reduced strain of damaged femoral heads allows such bone remodeling that the normally present difference in coarseness between vertical and horizontal long series of pixels

vanished and vertical columns become as coarse as their rows.

Results of analysis of short sequences of 128 pixels show that degenerative process showed significantly smaller impact on fine samples of the pixel variability, so the difference between rough rows and smooth columns was maintained in images of femoral heads from osteoarthrotic joints, as well, although column values of femoral heads from coxarthrotic joints showed reduced standard deviation, in comparison to the controls.

Described discrepancy between long and short pixel sequences shows that the length of the analyzed linear segment is important in detection of changes in the sample, i.e., it is a process dependable on physical dimensions of some structures being changed by progression of the illness, and here it is probably spatial arrangement and thickness of the bone trabeculae within the femoral head. This is a potential argument that the osteoarthrotic process diminishes fractal nature of the femoral head composition by introducing features that are obvious on the rough and invisible on the fine scale.

### Results of the Fourier analysis

Fourier analysis of 128 pixels long rows and columns resulted in non-dimensional power coefficients of harmonics that range from the 1<sup>st</sup> to the 64<sup>th</sup> harmonic (wave length from 10.8 to 0.15 mm). Power coefficients of many harmonics derived from vertical columns are significantly different for healthy and coxarthrotic femoral heads (from the 1<sup>st</sup> harmonic, wave length of 10.8 mm to the 33<sup>rd</sup> harmonic, wave length of 0.328 mm,  $p < 0.05$  by

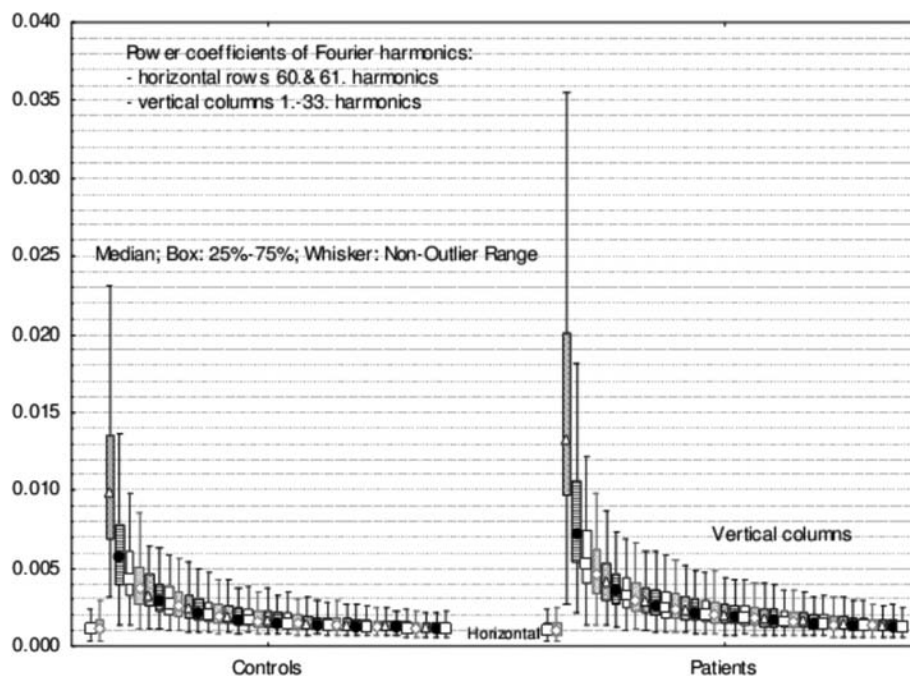


Fig. 4. Results of the Fourier analysis using 396 small (128x128 pixels) matrices. Comparison is done between matrices from normal (Controls) and coxarthrotic joints (Patients).

Mann-Whitney U-test). It was found that coxarthrotic heads showed significantly higher power values of these harmonics, as shown in Figure 4.

When considering results of horizontal rows, few harmonics showed distinguishing information. In coxarthrotic heads 60<sup>th</sup> and 61<sup>st</sup> harmonics showed significantly lower power than controls (Mann-Whitney U-test  $p < 0.01$ ). These two harmonics have very small wave length of about 0.2 mm, their power value reflects subtle changes that are only a couple pixels apart.

It could be concluded that coxarthrotic femoral heads in vertical column harmonics show increased coarse patterns of large wave lengths from 20 mm to approx. 1 mm while among harmonics calculated from horizontal rows show decrease of fine patterns of rows with wave length of about 0.2 mm. Results of the Fourier analysis suggest that degenerative changes in the central part of femoral head replaces fine bone structure with an altered trabecular pattern, detectable in standard femoral head radiographs as higher variability of vertical pixel sequences.

## Discussion

Reported studies have shown that remodeling of subchondral bone and increase of its hardness and strength lead to the change in bone absorbing characteristics, transferring higher force toward adjacent cartilage. This causes the change in the chondrocyte matrix and metabolism, making it more vulnerable to additional strains<sup>5</sup>. Altered arthritic cartilage is inferior to the healthy one in mechanical and functional terms. It is important that the

subchondral bone remodeling can occur in presence of only minimum changes in articular cartilage, due to altered physiological balance between formation and resorption of subchondral bone, higher formation is not followed by appropriate resorption. Mentioned mechanisms support the argument that bone changes are among early changes in arthritis. Subchondral sclerosis does not result from the rise of fraction volume, or from reduced bone resorption only, but also from the change in trabecular structure in which trabeculae become more open, denser, and thicker<sup>6</sup>.

Increase in hardness results primarily from the trabecular verticalisation to the articular surface. In the animal model of hip osteoarthritis analyzed by micro-CT, Layton<sup>7</sup> reported that trabecular remodeling occurs in the depth of femur head. Long-term strains and inelasticity of subchondral bone cause reduction in strength of collagen fibers due to breaking of their links<sup>5</sup>. Locally increased, bone density can serve as a marker for early detection of higher risk of development of osteoarthritis, taking into account narrowing of the joint cavity<sup>8</sup>.

Caldwell et al.<sup>9</sup> tried to assess disturbance of trabecular bone in experimental inflammatory arthritis by calculation of fractal dimension from radiographs of the rabbit's knee bone. Authors concluded that calculated fractal dimension is a valuable method for differentiation of trabecular structure of a normal bone from the bone in accelerated remodeling due to inflammatory arthritis. Similarly, fractal measurements show better correlation with the spatial orientation of trabeculae and their number than with their thickness. By micro-CT evaluation of

femoral head after implanting endoprosthesis due to osteoarthritis and osteoporosis, Zhang et al.<sup>10</sup> found out that the index of bone volume fraction and trabecular density ratio is important for prognosis in determination of mechanical properties. This index is significantly higher in arthritic and lower in osteoporotic femoral heads. In studying of the bone structure in separated parts of the knee joint with osteoarthritis in 40 patients using the fractal analysis, Messent et al.<sup>11</sup> established the loss of all vertical and some horizontal trabeculae. Changes are more pronounced in an advanced stage of illness. It confirmed that arthritic bone is simultaneously osteoporotic one. It is in conformity with the research of Li et al.<sup>12</sup>, showing that in comparison with osteoporotic bones, an osteoarthrotic bone is beside having a reduced mineral content, also has an altered bone matrix composition, probably linked to the pathogenesis of osteoarthritis. Using the fractal analysis, Papaloucas et al.<sup>13</sup> evaluated changes in the center of femoral head in patients with developed hip osteoarthritis and concluded that no changes in horizontal trabeculae were noticed, while the largest, compressive vertical trabeculae, ranging from 0.96 to 1.02 mm, swelled significantly, while in those with small and medium thickness from 0.18 to 0.54 mm their total number reduced. Such sequence of events, combination of loss of thinner and swelling of larger trabeculae results from increased strain within subchondral bone that could explain the mechanism of the bone structure disorder and development of localized osteoporosis within the arthritic hip.

Using results obtained by analysis of trabecular structure of tibia cancellous bone with moderate and developed osteoarthritis and in patients without any radiological signs of degenerative joint illness by the method of fractal analysis, Buckland et al.<sup>14</sup> established that decrease of horizontal trabeculae typically occurs in early stages of disease, while narrowing of joint cavity below 3 mm was followed by increase of vertical trabeculae. In any single phase of osteoarthritis no changes in lateral joint part were observed.

Gregory et al.<sup>15</sup> investigated the structure of cancellous bone in 100 osteoarthrotic and osteoporotic femoral heads obtained in at implanting endoprosthesis. His results obtained by Fourier analysis show the importance of bone structure. They also showed that this analysis of detection of structural changes is a simple, cost efficient and powerful tool for detection of such alterations. Blain et al.<sup>16</sup>, using also Fourier method, found out that there is significant difference the bone structure in case of osteoporosis and osteoarthritis, respectively. Osteoporotic femoral heads had significantly thinner corticalis, while corticalis was more porous in case of osteoarthritis. Trabecular volume decreased by 50%, followed by reduction in number of trabeculae, their thickness and weaker bonds among them in osteoporotic bones. Bi et al.<sup>17</sup> induced changes in rabbit cartilage by ligament resection and medial meniscectomy and then he evaluated the ob-

tained results, using Fourier analysis and infrared spectroscopy (FT – IRIS) and MR microscopy. Both methods revealed changes in the cartilage composition, i.e., a decrease in proteoglycan in 2<sup>nd</sup> and 4<sup>th</sup> post-surgery week, changes in orientation of collagen fibers, but not in the collagen composition in the early phase of osteoarthritis.

Results of pattern features in X-ray images of osteoarthrotic and normal femoral heads, presented herein, show that the approach to an analysis is important. Information obtainable by analysis of linear segments picked out from the region of special interest depend on whether these were vertical or horizontal segments. Images of healthy femoral heads were characterized by a striking difference between vertical columns and horizontal rows, while pathologic process reduces such difference in images of femoral heads from osteoarthrotic joints. The consequence is that only results from vertical column differentiated coxarthrotic from control images. Dequeker et al.<sup>5</sup> obtained similar information by histological analysis, i.e., that sclerosation of subchondral bone does not result only from an increase of the fraction volume or reduced resorption of a bone, but also from change in trabecular structure, wherein trabeculae become more open, denser and thicker. Development of local osteoporosis, through swelling of large vertical trabeculae, and loss of thin ones, leads to reduction of the cancellous bone strength that, due to extended mechanical strain, causes microfractures and occurrence of pseudo-cystic formations<sup>18</sup> in structure of trabecular bone in degenerative and healthy joints.

Results of Fourier analysis show that many power coefficients of harmonics found in vertical columns successfully detects pathology of a femoral head. In images of osteoarthrotic hips, vertical column harmonics show increased coarse patterns of large wave lengths (from 20 mm to approx. 1 mm), with a simultaneous decrease of fine patterns in rows with wave length of about 0.2 mm. Kamibayashi<sup>18</sup> obtained similar results. He noticed that in degenerative knees sclerosation does not result from an increase in the bone volume, but also from changes in trabecular structure. Trabecular orientation in arthritic joints is more vertical in relation to the joint surface, especially in trabeculae closer to the joint surface.

Determined by two unrelated mathematic methods, results suggest that in the analyzed set of digitalized X-ray femoral head images, information regarding osteoarthrotic changes in the central part of femoral head is detectable through mathematic postprocessing of vertically oriented patterns.

## Acknowledgements

This paper was financed through the grant 219-219-2382-2426 from the Croatian Ministry of Science, Education and Sport.

## REFERENCES

1. DEQUEKER J, MOKASSA L, AERSSSENS J, J Rheumatol, 43 (1995) 98. — 2. LAYTON MK, GOLDSTEIN SA, GOULET RW, FELDKAMP LA, KUBINSKI DJ, BOLE GG, Arthritis and Rheumatism, 31 (1998) 1400. — 3. RUSZKOWSKI I, MUFTIĆ I, PEČINA M, Završni izvještaj znanstveno-istraživačkog Projekta, (1975). — 4. FREEMAN MAR, Clin Orthop, 34 (1978) 19. — 5. AMIR G, PIRI C J, RASHAD S, REVELL P A, J Clin Pathol, 45 (1992) 990. — 6. STEWART A, BLACK A, ROBINS SP, REID DM, J Rheumatol, 26(1999) 622. — 7. HUBER MB, CARBALLIDO-GAMIO J, FRITCHER K, SCHUBERT R, HAENNII M, HENGG C, MAJUMDAR S, LINK TM, Med Phys, 36 (2009) 5089. — 8. GERAETS WG, VAN DER STELT PF, Dentomaxillofac Radiol, 29 (2000) 144. — 9. MESSENT EA, WARD RJ, TONKIN CJ, BUCKLAND-WRIGHT C, Osteoarthritis Cartilage, 24 (2006) 1302. — 10. CALDWELL CB, MORAN EL, BOGOCH ER, J Bone Miner Res, 13 (1998) 978. — 11. ZHANG ZM, LI ZC, JIANG LS, JIANG SD, DAI LY, Osteoporos Int, 22 (2009). — 12. BAOUHA L, MARSHALL D, ROE M, ASPDEN RM, J. Anat, 195 (1999) 101. — 13. PAPALOUKAS CD, WARD RJ, TONKIN CJ, BUCKLAND-WRIGHT C, Osteoarthritis Cartilage, 13 (2005) 998. — 14. BUCKLAND-WRIGHT JC, LYNCH JA, MACFARLANE DG, Ann Rheum Dis, 55 (1996) 749. — 15. FABER TD, YOON DC, SERVICE SK, WHITE SC, Bone, 35 (2004) 403. — 16. WOLSKI M, PODSIADLO P, STACHOWIAK GW, Proc Inst Mech Eng H, 223 (2009) 211. — 17. BLAIN EJ, Int J Exp Pathol, 90 (2009) 1. — 18. BI X, YANG X, BOSTROM MP, BARTUSIK D, RAMASWAMY S, FIISHBEIN KW, SPENCER RG, CAMACHO NP, Anal Bioanal Chem, 387 (2007) 1601. — 19. KAMIBAYASHI L, WYSS UP, COOKE TD, ZEE B, Calcif Tissue Int, 57 (1995) 69. — 20. KRISTEK B, Doktorska disertacija, 2008.

S. Rapan

»J. J. Strossmayer« University, School of Medicine, Department of Orthopedics, J Huttlera 4, 31000 Osijek, Croatia  
e-mail: sasa.rapan@gmail.com

## OTKRIVANJE KOKSARTROZE PUTE MATEMATIČKIH MODELA UNUTAR RADIOLOŠKE SNIMKE GLAVE BEDRENE KOSTI OGRANIČENO JE NA VERTIKALNI UZORAK ZNAČAJKI

### SAŽETAK

Od 120 standardnih radioloških snimaka zgloba kuka, dva nezavisna ispitivača su izabrali 27 zdrava i 62 koksartrotična zgloba. Centralni dijelovi bedrenih glava slika su digitalizirano, a potom je analizirana gustoće piksela. Dvije su metode primjenjene za horizontalne redove i okomite stupce: analiza koeficijenta varijacija i snage koeficijentata Fourierovih harmonika. Aritmetička sredina i medijan varijance koeficijenta za 256 piksela stupova bili su značajno viši kod pacijenata s koksartrozom (Mann-Whitney U-test,  $p=0,0046$  odnosno  $p=0,0011$ , respektivno), dok nije pronađena razlika za horizontalne redove. Aritmetička sredina i medijan koeficijenta varijacije za 128 piksela duge kolone bile su značajno niži u podacima koksartroze ( $p<0,001$ ) sa širom standardnom devijacijom ( $p=0,0274$ ), dok je standardna devijacija bila značajno niža u redovima osteoartritičnih glava femura ( $p<0,001$ ). Fourierova analiza 128 piksela, za vertikalne stupce pokazala je značajno veće vrijednosti u koksartrotičnih glava (za 1. harmoniku, valna duljina od 10,8 mm do 33. harmonike, valne duljine od 0,328 mm,  $p<0,05$ ). Fourierova analiza 128 piksela, horizontalne redove za osteoartritične i zdrave kukove ne razlikuje značajno. Samo vrijednosti za 60. i 61. harmonik (valne duljine blizu 0,2 mm) pokazali su manju snagu kod osteoartritičnih glava slika nego u kontrolnoj skupini ( $p<0,01$ ). Rezultati upućuju na to da je u digitaliziranih rendgenskih slika glave bedrene kosti, informacije o artrotičnim promjenama u središnjem dijelu glave femura, prepoznatljiv uglavnom kroz matematičku obradu vertikalno orijentiranih uzoraka.