

Transforaminal Lumbar Interbody Fusion (TLIF) and Unilateral Transpedicular Fixation

Rapan, Saša; Jovanović, Savo; Gulan, Gordan

Source / Izvornik: **Collegium antropologicum, 2010, 34, 531 - 534**

Journal article, Published version

Rad u časopisu, Objavljena verzija rada (izdavačev PDF)

Permanent link / Trajna poveznica: <https://um.nsk.hr/um:nbn:hr:184:387100>

Rights / Prava: [In copyright](#)/[Zaštićeno autorskim pravom.](#)

Download date / Datum preuzimanja: **2024-09-26**



Repository / Repozitorij:

[Repository of the University of Rijeka, Faculty of Medicine - FMRI Repository](#)



Transforaminal Lumbar Interbody Fusion (TLIF) and Unilateral Transpedicular Fixation

Saša Rapan¹, Savo Jovanović¹ and Gordan Gulan²

¹ Department of Orthopaedic Surgery, Osijek University Hospital Center, Osijek, Croatia

² Clinic for Orthopaedic Surgery Lovran, School of Medicine, Rijeka University, Rijeka, Croatia

ABSTRACT

TLIF (transforaminal lumbar interbody fusion) is a method of interbody fusion, which is alternative to other vertebral fusion wherein, with an approach through intervertebral foramen, through lateral segment of intervertebral space, complications occurring with other methods are reduced. Today, there are numerous versions of this method in terms of implants and transplants. At our Department patients with axial pain resistant to conservative treatment of minimum six months underwent TLIF method with unilateral transpedicular fixation with polyaxial screws, CAGE filled with autologous transplant obtained by lamina resection, and posteromedial contralateral fusion. 22 procedures were performed at 22 levels, 10 for relapsing hernia, and 12 for disc herniation combined with degenerative changes on the same level. Pain reduction was significant; according to VAS score, lumbar pain was reduced from preoperative 8.5 ± 0.8 to 2.4 ± 0.85 (-72.63%) a year after, and leg pain was reduced significantly from preoperative 8.45 ± 0.91 to 2.072 ± 0.81 (71%) 12 months after surgery. The Wilcoxon paired test demonstrated a significant difference between preoperative VAS score and the value measured 12 months after surgery ($n=22$, $Z=4.1$, $p<0.001$) leg and back, respectively. In 15 (68.2%) patients fusion was evidenced on standard X-ray of lumbar spine, and in 4 patients, with aggravated clinical presentation, fusion in 2 patients and pseudoarthrosis in 2 patients were evidenced by CT. Total 17 patients (77.3%) showed signs of fusion. In our study we demonstrated that unilateral ipsilateral transpedicular fixation, with positioning of one CAGE filled with local autologous transplant represents a reliable and successful method of treatment of axial lumbar pain.

Key words: TLIF, unilateral transpedicular fixation, VAS pain scale

Introduction

Some success in treatment of axial lumbar pain and ischialgia can be attained by interbody fusion and posterior vertebral fixation¹⁻³. Today, owing to development of technology and surgical techniques, new minimally invasive surgical methods were created by which maximum success is achieved⁴⁻⁶. Combination of posterior transpedicular fixation and use of carbon or titanium CAGE, use of osteoinductive and osteoconductive implants increases structural stability and spondylolysis⁷. In comparison with posterior or lateral fusion, advantage of interbody fusion involves disc removal as potential cause of discogenic pain^{8,9}.

PLIF, posterior lumbar interbody fusion, originally described by Cloward, is limited to L3-S1 segments, characterised by epidural haemorrhage, adhesions in canal, neurological damages due to retraction, and possible in-

stability due to laminectomy^{10,11}, while ALIF, anterior fusion, is more expensive because it is performed in two parts, usually in presence of general surgeon and vascular surgeon. It is followed by serious complications, such as retrograde ejaculation and injuries of peritoneum and large blood vessels¹²⁻¹⁴.

Patients and Methods

22 patients, who underwent TLIF surgery on one level, were followed up 12 to 18 months after surgery. Average age was 50, 46 years (37–62). 12 men and 10 women participated in the study. In 14 patients L4-S level was involved, in 6 patients L5-S1, and 2 patients underwent surgery of L3-4 level. All patients underwent conservative treatment lasting minimum 6 months. Be-

fore surgery, they all made standard X-ray of lumbar spine, MR of lumbar spine, and some had EMNG of lower limbs. MR revealed signs of degeneration and/or intervertebral disc herniation. 13 patients underwent previous discectomy on the same level. Patients with affected discs on higher levels and previous surgeries of spondylolisthesis were not included in the study. Neither discography nor immobilisation of facet joints was made. In order to verify the method efficiency all patients completed VAS questionnaire, with the scale from 1 to 10 before surgery and after 12 months. At controls made 3, 6 and 12 months after surgery, in addition to clinical evaluation X-ray evaluation were also made. In 4 patients with distress progression CT was made to diagnose fusion or pseudoarthrosis. The following was applied as fusion criteria: bone continuity between the upper and lower surface, loss of radiolucent zone, anterior and posterior bone turnover between trunks. No dynamic, functional images were made. We followed up blood loss during surgery, surgery duration and complications during surgery. After surgery all patients were verticalised after 48 hours with LS orthosis. If L5-S1 level was involved, the orthosis had a leg extension.

Procedure

All surgeries were performed in general anaesthesia. After placing a patient in prone position, the area of surgery is cleaned and covered followed by the level identification by diascopy. Extensor muscles are removed laterally to the base of transverse process. Polyaxial titanium screws, diameter of 5 mm for women and 6 mm for men (Moss Miami, De Puy) are applied transpedicular, unilaterally on the relevant level from the side with dominant iscial disorder. After that, resection of facet joint is made by an osteotom to reveal the neuroforamen. Coagulation of epidural veins is performed followed by discectomy. Intervertebral space is gradually distracted by a distractor and ipsilateral positioned rod. After subtotal discectomy, cartilage surface tissue of is removed and then the anterior part of the space is filled with all-transplant from femur head or from bone bank. Carbon CAGE (Saber, De Puy) is filled with autologous transplant obtained by resection of lamina and small joint, and then inserted at the angle of approx. 45° into distracted intervertebral space. After application of CAGE distraction is reduced and intervertebral space is compresses through the rod. Contralaterally, posteromedia-

lly, decortication is performed on the opposite facet joint and remaining portion of the transplant is placed on posterior structures. It is followed by vacuum drainage and wound reconstruction per layers. Immediately after surgery X-ray of the treated segment was made (Figure 1). Postoperative therapy includes analgetics application, i.e. parenteral administration of Tramadolom, parhamotological pretreatment with antibiotics such as Cefazolinom (Zepilen, Medicuspharma) and one week thromboprophylaxis with Reviparinom Natricum (Clivarin, Abbott GmbH & Co, Germany).

Results

22 patients (10 women, 12 men, aged from 37 to 62) were tested before surgery and 12 months after surgery.

22 surgeries were performed on 22 levels, 10 for relapsing hernia, and 12 for primary disc hernia combined with degenerative changes on the same level (Figure 2). Pain reduction was significant; according to VAS score, lumbar pain was reduced from preoperative (Figure 2) 8.5 ± 0.8 to 2.4 ± 0.85 (-72.63%) after one year for low back pain, and leg pain was reduced significantly from preoperative 8.45 ± 0.91 to 2.072 ± 0.81 (71%) 12 months later. the Wilcoxon paired test demonstrated a significant difference between preoperative VAS score and the value measured 12 months after surgery ($n=22$, $Z=4.1$, $p<0.001$), for leg and for lower back, respectively.

From 22 patients, in 15 (68.2%) fusion was demonstrated on standard X-ray of lumbar spine. In 4 patients

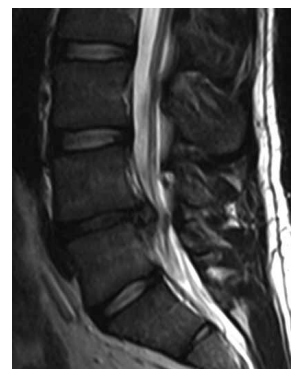


Fig 2. Preoperative MRI shows disc hernia with accompanying degenerative changes of intervertebral segment.

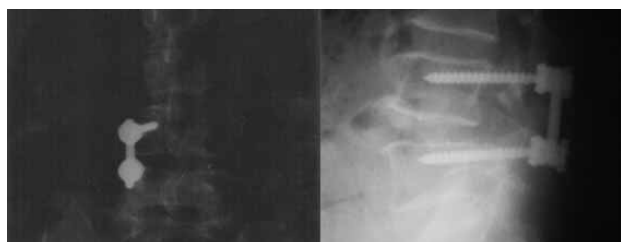

Fig 1. X-ray taken after the unilateral TLIF procedure.

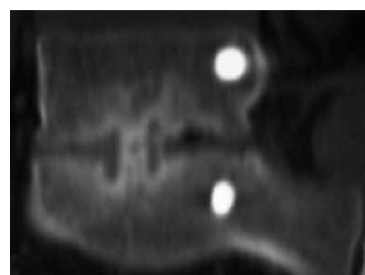

Fig 3. CT after 6 months reveals signs of fusion through CAGE.

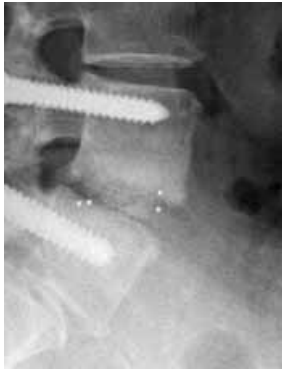

Fig 4. CT after 6 months reveals signs of pseudoarthrosis.

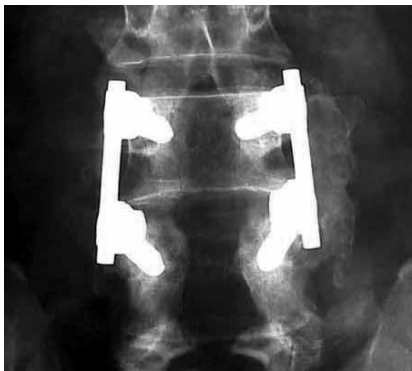

Fig 5. Bilateral transpedicular fixation and posterolateral fusion.

with deteriorating clinical presentation CT was made which showed signs of fusion in 2 cases (Figure 3), while in 2 others pseudoarthrosis was diagnosed (Figure 4), which was later settled by bilateral transpedicular fixation with larger diameter screws and posterolateral fusion (Figure 5). Signs of fusion were present in 17 (77.3%) patients. The average blood loss was 250 ml and there was no need for blood restitution, and average duration of the procedure was 135 minutes. There were no signs of lyquorrhoea or infection during or after surgery. In one patient signs of transient paresis of femoral nerve occurred which disappeared within several days.

Discussion

Low back pain represents huge health and socio-economic problem. It was tried to cope with in numerous non-surgical and surgical methods, however, only partly satisfying results have been achieved so far. The goal is to develop a surgical method which will give maximum good results for as many patients as possible, with minimal investments, shorter stay in hospital and reduce complications. The more surgeons use this technique, its availability and number of patients having benefits from it, the more desirable it will become. Intervertebral fusion *per* ALIF and PLIF methods has shown as good in management of axial pain in the back, primarily due to disc removal as the cause of discogenic pain, but with numerous

problems^{8,9}. TLIF, as a surgery technique, which involves all advantages of ALIF and PLIF methods, and simultaneously with much less complications, has been applied extensively in spinal surgery¹⁵.

Whitecloud¹⁶ has compared ALIF and TLIF procedures and found out that operation time, loss of blood and costs were significantly lower with TLIF method. Some other authors¹⁷ evidenced success of this spondylolisthesis method, without direct relation between fusion level and good clinical result.

Since its introduction in 1998, till today some modifications were developed. Our paper presents one such method wherein, in addition to diagonally positioned CAGE, we also used unilateral ipsilateral fixation. In our case, clinical success rate of this method is 81.81% which corresponds to works of some other authors, either related to ALIF or PLIF^{18–22}, or TLIF with bilateral fixation²³, or TLIF method with contralateral translamina fixation²⁴, unilateral fixation²⁵, minimal invasive transmuscular TLIF method with use of INFUSE preparation²⁶ or without it²⁷. Our results of reduction of leg pain by 21 % and in low back by 72% correlate with the work of Deuch²⁷ and Jang²⁸.

Biomechanical analysis made on cadavers demonstrated that the highest biomechanical stability, which is the closest to natural conditions, is provided by bilateral fixation, and also with unilateral fixation with translamina contralateral screw, while the lowest stability is provided by construction of unilateral transpedicular fixation. Harris²⁹ demonstrated that reconstruction with one diagonally positioned CAGE significantly increases flexibility of the L4-5 level in axial rotation. Unilaterally positioned transpedicular fixation increases stability in relation to unilateral translamina screw, but with bilateral fixation flexibility is the closest to the values of intact, healthy L4-5 level. In his research, Sethi²⁴ demonstrated that unilateral transpedicular fixation with contralateral translamina fixation by a cortical screw gives the same result, but it is half less expensive method of spinal fusion in case of one level fixation.

Slucky³⁰ demonstrated that after TLIF with unilateral fixation only half of total strength of bilateral fixation, especially in terms of rotation, which can have negative impact on stability and total outcome. Unilateral fixation with contralateral translamina screw eliminates this drawback. This supports the work of Jang who links excellent clinical and radiological outcomes with this method.

Screw application shortens operation time, reduces blood loss and infection risk as well as possible bad screw positioning which, in some studies, accounts for up to 5.4%³¹. In addition, costs related to implant price are also reduced.

Suk³, Zhao¹⁵, Kabins³² do not find and treatment success rate between unilateral or bilateral positioned transpedicular implant.

Conclusion

Use of unilateral transpedicular fixation with TLIF method is a reliable, fast, not expensive and safe option

which provides excellent clinical results and represents good alternative to fusion PLIF and ALIF.

REFERENCES

1. BRANTIGAN JW, STEFFEE AD, LEWIS ML, Spine, 25 (2000) 1437. — 2. SALEHI SA, TAWK R, GANJU A, Neurosurgery, 54 (2004) 368. — 3. SUK KS, LEE HM, KIM NH, Spine, 25 (2000) 1843. — 4. FOLEY KT, HOLLY LT, SCHWENDER JD, Spine, 28(Suppl 15) (2003) 26. — 5. VAMVANIJ V, FREDRICKSON BE, THORPE JM, J Spinal Disord, 11 (1998) 375. — 6. WANG ST, GOEL VK, FU CY, Spine, 30 (2005) 62. — 7. HANLEY EN, DAVID SM, JBJS, 5 (1999) 716. — 8. BARRICK WT, SCHOFFERMANN JA, REYNOLDS JB, GOLDTHWAITE ND, MC KEEHEN M, KEANAY D, WHITE AH, Spine, 25 (2000) 853. — 9. WEATHERLEY CR, PRICKED CF, O'BRIEN JP, JBJS, 68B (1986) 142. — 10. HUMPHREYS SC, HODGES SD, PATWARDHAN AG, ECK JC, MURPHY RB, COVINGTON LA, Spine, 26 (2001) 567. — 11. OKUYAMA K, ABE E, SUZUKI T, TAMURA Y, CHIBA M, SATO K, Acta Orthop Scand, 70 (1999) 329. — 12. CHRISTENSEN FB, BUNGER CE, Int Orthop, 21 (1997) 176. — 13. TIUSANEN H, SEITSALO S, OSTERMANN K, SOINI J, Eur Spine J, 4 (1995) 339. — 14. BAKER JK, REARDON PR, REARDON MJ, HEGGENESS MH, Spine, 18 (1993) 2227. — 15. HUMPHREYS SC, HODGES SD, PATWARDHAN AG, Spine, 26 (2001) 567. — 16. WHITECLOUD TS, ROESCH WW, RICCIARDI JE, J Spinal Disord, 14 (2001) 100. — 17. HACKENBERG L, HALM H, BULLMANN V, VIETH V, SCHNEIDER M, LILJENQVIST U, Eur Spine J, 14 (2005) 551. — 18. BRANTIGAN JW, STEFFEE AD, LEWIS ML, QUINN LM, PERSENAIRE JM, Spine, 25 (2000) 1437. — 19. ENKER P, STEE AD, Clin Orthop, 300 (1994) 90. — 20. FREEMAN BJ, LICINA P, MEHDIAN SH, Eur Spine J, 9 (2000) 42. — 21. LEUFVEN C, NORDWALL A, Spine, 24 (1999) 2042. — 22. WANG JM, KIM DJ, YUN YH, J Spinal Disord, 9 (1996) 83. — 23. LOWE TG, TAHERNIA AD, Clin Orthop Relat Res, 394 (2002) 64. — 24. ZHAO J, HOU T, WANG X, Eur Spine J, 12 (2003) 173. — 25. SETHI A, LEE S, VAIDYA R, 18(3) (2009) 430. — 26. DEUTCH H, MUSACCHIO MJ JR, Neurosurg Focus, 20(3) (2006) 10. — 27. DEUTSCH H, MUSACCHIO MJ JR, Neurosurg Focus, 20(3) (2006) 10. — 28. JANG JS, LEE SH, J Neurosurg Spine, 3(3) (2005) 218. — 29. HARRIS BM, HILIBRAND AS, SAVAS PE, PELLEGRINO A, VACCARO AR, SIEGLER S, ALBERT TJ, 29(4) (2004) 65. — 30. SLUCKY AV, BRODKE DS, BACHUS KN, DROGE JA, BRAUN JT, Spine, 6(1) (2006) 78. — 31. ESSES SI, SACHS BL, DREYZIN V, Spine, 18(15) (1993) 2231. — 32. KABINS MB, WEINSTEIN JN, SPRATT KF, J Spinal Disord, 5 (1992) 39.

S. Rapan

Department of Orthopaedic Surgery, Osijek University Hospital Center, J. Huttlera 4, Osijek, Croatia
e-mail: sasa.rapan@gmail.com

TLIF I UNILATERALNA TRANSPEDIKULARNA FIKSACIJA

SAŽETAK

TLIF (transforaminal lumbar interbody fusion) je metoda interkorporalne fuzije, koja je alternativa dugim metodama fuzije kralježaka, gdje se pristupom kod intravertebralni foramen, kroz lateralni segment intervertebralnog prostora smanjuju komplikacije vezane za druge metode. Danas postoje brojne varijacije ove metode s obzirom na vrstu implantata i transplantata. Na našem Odjelu pacijenti su zbog aksijalne boli, rezistentne na konzervativno liječenje najmanje 6 mjeseci, liječeni TLIF metodom uz jednostranu transpedikularnu fiksaciju poliaksijalnim vijcima, CAGE-om ispunjenim autolognim transplantatom dobivenog reseksijom lamina, te posteromedijalnom kontralateralnom fuzijom. 22 procedure je izvedeno na 22 nivoa, 10 zbog recidivirajuće hernije, a 12 zbog hernijacije diska udružene s degeneracijskim promjenama na istom nivou. Smanjenje bolova je bilo značajno, po VAS skoru od $8,5 \pm 0,8$ prijeoperacijski do $2,4 \pm 0,85$ ($-72,63\%$) nakon godinu dana za križobolju, a bol u nozi značajno je smanjena s $8,45 \pm 0,91$ prijeoperacije na $2,072 \pm 0,81$ (71%) nakon 12 mjeseci. Wilcoxonovim testom vezanih parova utvrđena je izrazito značajna razlika između prijeoperacijskog VAS skora i vrijednosti 12 mjeseci nakon operacije ($n=22$, $Z=4,1$, $p<0,001$), za nogu i za leđa. Fuzija je u 15 (68,2%) ispitanika evidentirana na konvencionalnoj radiološkoj snimci lumbalne kralježnice, a u 4 pacijenta koji su imali pogoršanje kliničke slike CT-om utvrđena je fuzija u 2 i pseudartroza u 2 slučaja. Ukupno su u 17 (77,3%) ispitanika postojali znaci fuzije. U našem istraživanju pokazali smo da je unilateralna ipsilateralna transpedikularna fiksacija uz postavljanje jednog CAGE-a ispunjenim lokalnim autolognim transplantatim pouzdana i uspješna metoda liječenja aksijalne lumbalne boli.