

The Canal Fill Ratio as a Factor Influencing the Aseptic Loosening of the Müller-Type Cemented Stem - Preliminary Report

Gulan, Gordan; Jurdana, Hari

Source / Izvornik: *Collegium antropologicum*, 2007, 31, 195 - 198

Journal article, Published version

Rad u časopisu, Objavljena verzija rada (izdavačev PDF)

Permanent link / Trajna poveznica: <https://urn.nsk.hr/urn:nbn:hr:184:270514>

Rights / Prava: [In copyright](#)/[Zaštićeno autorskim pravom.](#)

Download date / Datum preuzimanja: **2024-07-23**



Repository / Repozitorij:

[Repository of the University of Rijeka, Faculty of Medicine - FMRI Repository](#)



The Canal Fill Ratio as a Factor Influencing the Aseptic Loosening of the Müller-Type Cemented Stem – Preliminary Report

Gordan Gulan and Hari Jurdana

Clinic for Orthopaedic Surgery Lovran, Faculty of Medicine University of Rijeka, Croatia

ABSTRACT

The Müller type cemented hip prosthesis, also called self-locking prosthesis, is one of the most extensively copied and utilized hip prostheses. Considering the implantation of the cemented stem, the author originally suggested achieving a press fit between the stem and endostal cortex by implanting a prosthesis of the largest possible size. Analyzing our group of patients who undergo aseptic stem revision, we try to quantify the term „press fit“ by measuring the filling of the femoral canal by the metal stem, the so-called canal-fill ratio. Our preliminary results suggest that press-fit is achieved when the stem occupies more than 90% of the canal diameter in the anterior-posterior projection.

Key words: Müller; cemented stem, canal fill ratio

Introduction

In 1977, Müller introduced his cemented straight stem hip prosthesis. It was recommended that the stem be tapered using the largest possible size for a particular femur, achieving a press-fit between the medial and lateral walls of the femur and the prosthesis. The Müller prosthesis has been extensively copied and is still one of the most frequently used implants in some European countries.

In a follow-up study, this stem revealed promising clinical results, including a 10-year survival rate^{1-2, 4-11}.

Patients and Methods

Patients

Among all revised hip prostheses in the period between 2000 and 2005, we analyzed a homogenous group of 26 patients. All received a hip prosthesis between 65 and 70 years of age due to hip arthrosis.

The level of physical activity was similar in all patients and all were properly implanted with both components of the Müller type prosthesis, produced by Lima®. All patients had only one hip prosthesis. 18 patients were female and 8 were male. The survival rate of the ce-

mented stem was defined as the period between primary hip arthroplasty and the clinical sign of loosening. Criteria for revision required vital patients, pain, and if possible, radiological evidence indicating a loosening of the femoral component. We excluded patients with radiological indications alone, such as radiolucent lines or stem subsidence through the axial load because this is no longer considered to indicate definitive loosening, given that the stability of a tapered stem increases with subsidence, which explains the high survival rate of these types of stems².

Operative Technique

All operations on 15 patients were performed in our clinic, by the same surgical team. In 11 patients the primary implantation was done at other institutions. All were evaluated and controlled largely in our clinic. In all patients the transgluteal surgical approach to the hip was used without trochanteric osteotomy. After reaming the acetabulum, the polyethylene cup of corresponding size was cemented using the finger-packing technique. The femoral canal was prepared according to the manufacturer's instructions and rasped until cortical resis-

tance was felt. The stem had the same cross-sectional dimensions as the rasp. After reaming, the femoral canal was cleaned, dried and occluded with bone plaque. A stem of the same size as the rasp was introduced using Palacos® bone cement. All had a 28mm diameter head, and all were produced by the same manufacturer.

Plain Radiography Analysis

We analyzed plain x-rays taken after primary hip arthroplasty of all patients who underwent femoral stem revision surgery alone or in combination with acetabular revision due to aseptic loosening.

With the aim to observe the ratio between the femoral canal and the stem, we analyzed only the AP projection because proper stability and the proposed stem position should be achieved in this plane.

We identified the diameter of the canal-stem ratio as an important factor in the longevity of the cemented stem. The diameter of the canal was defined as the distance between the endosteal cortex, which is perpendicular to the long axis of the femoral canal. The stem diameter was defined as the distance between two peripheral points at a level perpendicular to the long axis of the femoral canal. We measured the canal fill ratio at the level at which the stem was nearest to the endosteal cortex, and according to the Green zones³.

We also analyzed stem alignment, measuring the deviation between the long axis of the stem and the femoral canal.

We divided the patients into two groups, according to the radiographic measurement of the stem/canal diameter ratio. The first group comprised patients in whom the stem occupied more than 90% of the femoral canal at either level. To the contrary, the second group comprised patients in whom the stem occupied less than 90%. We analyzed only the stem implanted in a neutral position or in a position less than 5 degrees of varus or valgus, which we determined to be the border beyond which there is a significantly higher risk of progressive loosening⁴.

Results

In the examined groups there were 8 male and 18 female patients. The gender distribution in the first group was 5 male and 11 female patients, while in the second group there were 3 male and 7 female patients. Using the gender representation test, a comparison of the two groups did not yield results of statistical significance.

In both groups intimate contact of the stem with the femoral wall was achieved, but in the first group the radiolucent line, which represents the residual layer of the cancellous bone, was somewhat larger. In this group the stem occupied 70–90% of the femoral canal at the level measured (Figure 1). In the second group the stem occupied 90%–100% of the femoral canal.

Configuration of the femoral canal determined the level and the length of the closest contact of the stem

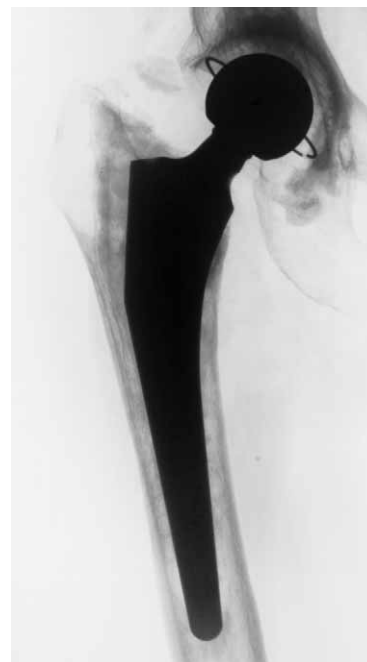
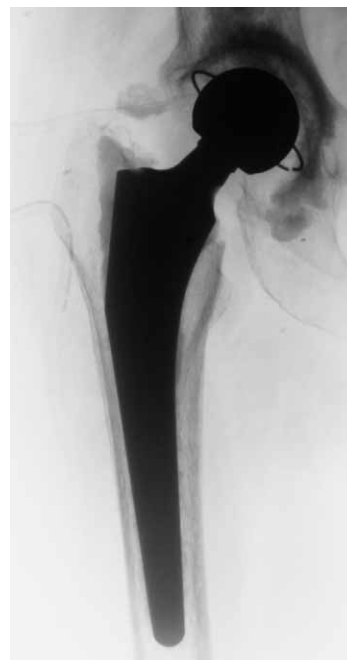
Fig. 1. X-ray of the Müller type cemented hip prosthesis with a stem occupying <90% of femoral canal diameter: A – directly after implantation; B – loosened 5 years later.

with the inner part of the femoral canal in the AP projection. In both groups this was in the lower part of the stem, which corresponds to the upper half of the Gruen zones 3 and 5. In the first group the most intimate contact was achieved with the lateral side of the femoral canal, while in the second group the distance between lateral and medial walls was equal.

The time of revision in the first group was 6.7 years (2.2 – 9.5). In the second group, the average time of revision was 8.5 years (6.5 – 12), due to aseptic loosening. Statistically (one way ANOVA), the survival rate in the second group was thus significantly longer compared to the first group.

Discussion

The Müller-type stem has dual fixation: self-interlocking, based on the anchoring principle, and by cement which fills the remaining space and acts only as a filter⁵. According to Morscher and Wirz, due to its fixation system, Müller's stem may be called a "hybrid stem"^{2,5}. The main disadvantage of this stem type is the large functional joint space that allows particles of any origin to reach almost every part of the prosthesis and initiate the loosening process^{2,5}.

Aseptic loosening is the main long-term reason for the failure of THA prostheses and accounts for 80% of revision cases⁶. Most of the literature describing the Müller-type hip prosthesis shows a satisfactory survival rate varying from 88.8%⁷ to 97%⁸ during a 10-year follow-up period.

The acetabular component made of polyethylene was recognized as the weakest link in the chain, especially in concurrence with a metal head of a 32mm diameter⁹. With regard to the acetabular component, aseptic loosening increases exponentially after the sixth or seventh postoperative year¹⁰. In contrast, femoral loosening appears to increase at a relatively constant rate¹⁰, and remains a significant cause of the early failure of total hip replacement⁸. Additionally, the survival rate was approximately 85% in a 10-year follow up period in the study obtained by Biemant¹.

Analyzing all our patients in both groups separately, based on the femoral canal fill ratio, the survival rate was statistically significant between groups. In the group where the stem occupied more than 90% of the femoral canal the average revision time was 8.5 years, while in the other group the average revision time was 6.3.

The mean time of revision due to aseptic loosening of the cemented hip prosthesis published by Havinga et al was 6.3 years¹¹. The same average revision time was observed in our first group, but with a somewhat narrow range. In this group we observed only the aseptic loosening of the stem. Havinga does not mention in his paper which component(s) was revised. If he significantly revised the femoral part, this could be another indirect evidence that the stem is responsible for early aseptic loosening of the cemented hip prosthesis.

In the second group, with longer average revision time, we observed the loosening of both prosthesis components in seven patients. Where both prosthesis components have been revised we could not determine which component started loosening first. The longevity of these seven prostheses, where both components had been revised, was higher than in any other. This observation is also in agreement with the observation that the stem is responsible for early loosening.

Our preliminary results suggest that if the stem occupies less than 90% of the femoral canal it can be fit, but not pressed enough against the inner part of the femoral wall, which appears to be critical in the development of early aseptic loosening in Müller-type cemented stem (Figure 2). Based on this finding, the femoral stem which occupies less than 90% of the femoral canal may be considered undersized.

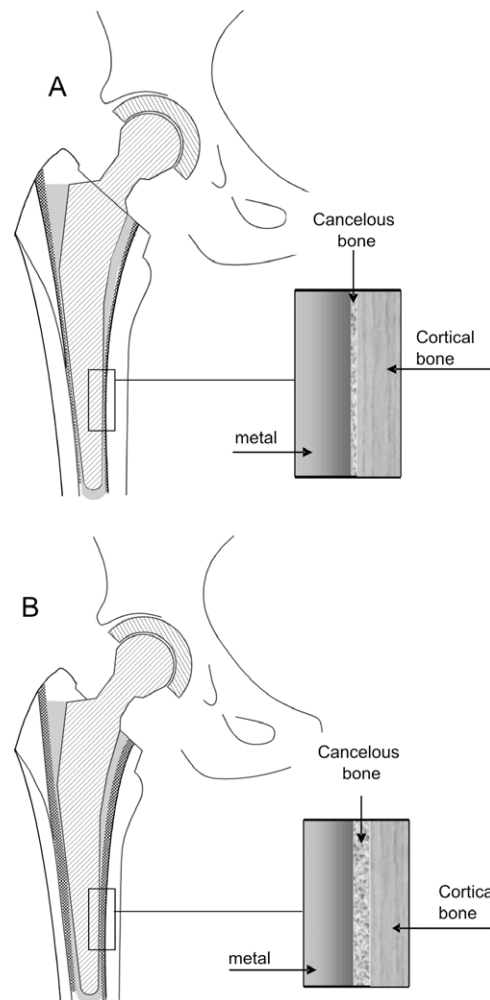


Fig. 2. Schematic illustration of the implanted cemented Müller-type femoral stem: A – press-fit implantation; B – fit implantation.

In conclusion, we would like to emphasize the challenge and importance of femoral canal preparation. One of the important steps in this process is preoperative planning. However, preoperative planning is not entirely reliable, due to potential mismatch between X-ray and *in vivo* findings. Surgeons must also rely on auscultators and tactile sensation during canal preparation, always aiming to implant the largest possible stem, and always keeping in mind that the stem should fit in the femoral canal and not vice-versa.

REFERENCES

1. BIEMANT JJ, Rev Chir Orthop Reparatrice Appar Mot, 81 (1995) 380. — 2. MORSCHER EW, WIRZ D, Acta Orthop Belgica, 68 (2002) 1. — 3. GRUEN TA, McNEICE GM, AMSTUTZ HC, Clin Orthop Relat Res, 141 (1979) 17. — 4. EBRAMZADEH E, SARMIENTO A, McKELOP HA, LLINAS A, GOGAN WJ, Bone Joint Surg, 76-A (1994) 77. — 5. WIRZ D, DANIELS AU, GOPFERT B, MORSCHER EW, Orthop Clin N Am, 36 (2005) 63. — 6. MALCHAU PH, HERBERTS P, AHNFELT L, Acta Orthop Scand, 64 (1993) 497. — 7. MOLLENHOFF, G, DAVID A, WALZ M, Zentralb Chir, 120 (1995) 716. — 8. WILSON-McDONALC J, MORSCHER EW, Arch Orthop Trauma Surg, 109 (1990) 14. — 9. , , B, , 72 (1990) 518. — 10. MORSHER EW, SCHMASSMANN A, Arch Orthop Trauma Surg, 101 (1983) 137. — 11. HAVINGA ME, SPRUIT M, ANDERSON PG, VAN DIJK-VAN DAM MS, PAVLOV PV, VAN LIMBEEK J, J Arthroplasty, 16 (2001) 33.

G. Gulan

*Clinic for Orthopaedic Surgery Lovran, Medical Faculty University of Rijeka, M. Tita 1, 51415 Lovran, Croatia
e-mail: gordan.gulan@medri.hr*

ISPUNJENOST FEMORALNOG KANALA STEMOM KAO ČIMBENIK U NASTANKU ASEPTIČKE NESTABILNOSTI MÜLLEROVOG TIPA CEMENTIRANE PROTEZE KUKA – PRETHODNO PRIOPĆENJE

SAŽETAK

Mullerov tip cementirane endoproteze zgloba kuka jedna je od najčešće korištenih endoproteza zgloba kuka u pojedinim Europskim zemljama. Originalna metoda implantacije cementiranog femoralnog dijela podrazumjeva postizanje dobrog kontakta između kosti i metalnog dijela proteze tijekom njenog implantiranja – »press fit«. To se postiže na način da se implantira što je moguće veći femoralni dio proteze. U našoj grupi bolesnika u kojih je zamjenjen cementirani femoralni dio proteze pokušali smo kvantificirati izraz »press fit« na način da smo mjerili ispunjenost femoralnog kanala stemom u bolesnika kod kojih je proteza zamijenjena zbog nastanka aseptičke nestabilnosti. Naši prvi rezultati ukazuju da se »press fit« postiže onda, ako je na nekoj od mjenjenih razina kanal više od 90% ispunjen femoralnom komponentom.