

Hemiarthroplasty is an Effective Surgical Method to Manage Unstable Trochanteric Fractures in Elderly People

Jotanović, Zdravko; Jurdana, Hari; Šestan, Branko; Rapan, Saša; Boschi, Vladimir; Gulan, Gordan

Source / Izvornik: *Collegium antropologicum*, 2011, 35, 427 - 431

Journal article, Published version

Rad u časopisu, Objavljena verzija rada (izdavačev PDF)

Permanent link / Trajna poveznica: <https://urn.nsk.hr/urn:nbn:hr:184:737568>

Rights / Prava: [In copyright](#) / [Zaštićeno autorskim pravom](#).

Download date / Datum preuzimanja: **2025-02-07**



Repository / Repozitorij:

[Repository of the University of Rijeka, Faculty of Medicine - FMRI Repository](#)



Hemiarthroplasty is an Effective Surgical Method to Manage Unstable Trochanteric Fractures in Elderly People

Zdravko Jotanović¹, Hari Jurdana¹, Branko Šestan¹, Saša Rapan², Vladimir Boschi³ and Gordan Gulan¹

¹ University of Rijeka, Lovran Clinic for Orthopaedic Surgery, Lovran, Croatia

² »J. J. Strossmayer« University, Osijek University Hospital Center, Department of Orthopaedic Surgery, Osijek, Croatia

³ University of Split, Split University Hospital Center, Department of Traumatology, Split, Croatia

ABSTRACT

Trochanteric femoral fractures are a major problem in the elderly because of higher bone fragility due to osteoporosis. Numerous chronic illnesses, which usually affect the elderly, aggravate and complicate their surgical treatment. Trochanteric femoral fractures results in high morbidity and mortality in elderly patients. The aim of our study is to evaluate the effectiveness of hemiarthroplasty in the treatment of unstable trochanteric femoral fractures in elderly patients. Between 2000 and 2005, 50 patients with unstable trochanteric femoral fractures (41 women) aged 75 to 92 years (mean 86 years) underwent cemented hemiarthroplasty. The surgical procedure was performed within first 48 hours after the fracture (out of which 14 in the first 12 hours, 27 in the first 24 hours and 9 in the first 48 hours), with minimal blood loss. Hemiarthroplasty was indicated in patients where stability was important to allow early mobilization. In forty patients (80%) early ambulation with full weight bearing was achieved during the short period of hospitalization (9–14 days). Given that the affected population is predominantly the elderly, who are less mobile and demanding and thus put less strain on the endoprosthesis, we believe that this kind of treatment is the treatment of choice for unstable trochanteric femoral fractures in these patients. This assumption is corroborated by the fact that we did not have any endoprosthesis luxation, apparent acetabular protrusion or instability during the mean follow up period of 15 months (range 12–18 months).

Key words: trochanteric fractures, elderly, hemiarthroplasty

Introduction

Trochanteric femoral fractures are, by definition, fractures that involve the proximal region of the femur from the extracapsular part of the femoral neck to the transverse line at the level of the distal end of the lesser trochanter, which defines the inferior limit of the trochanteric region¹. Trochanteric femoral fractures are rising in incidence. In two retrospective studies, Finsen et al. found an increase in the proportion of trochanteric femoral fractures from 32% in 1972–1984 to 68% in 1997–1998^{2,3}. These fractures predominantly occur in the population over 60 years of age and are 3–4 times more frequent in women than in men⁴. Although they could unite with conservative treatment but with a high

rate of complications, stable reduction and rigid internal fixation is the method of choice in the treatment of unstable trochanteric femoral fractures⁵, because internal fixation of these fractures is a life-saving measure in elderly people⁶. Restoration of function is the most important goal in the treatment of these fractures in the elderly⁷. Implants which can be used in the treatment of this kind of fractures include: fixed angle devices, e.g. AO angle blade plate¹; sliding compression screw assemblies, e.g. dynamic hip screw (DHS) and dynamic condylar screw (DCS); intramedullary nails, e.g. the gamma nail^{7,8} and proximal femoral nail (PFN)¹; and endoprosthesis, partial⁹ or bipolar^{10–12}. According to Gruss and Traut, af-

ter internal fixation of these fractures, unrestricted full weight bearing should be postponed for a few weeks¹³. In contrast, unrestricted full weight bearing can be initiated within 2–3 days after implantation of a cemented hip endoprosthesis⁷. In this study we retrospectively evaluate the effectiveness of cemented hemiarthroplasty in the treatment of unstable trochanteric femoral fractures in elderly patients.

Patients and Methods

Patients

Between 2000 and 2005, 50 patients with unstable trochanteric femoral fractures (41 women) aged 75 to 92 years (mean, 86 years) underwent cemented hemiarthroplasty involving the Austin-Moore endoprosthesis design. Out of them, 21 had left and 29 right unstable trochanteric femoral fracture. They were all able to walk independently before the fracture only with the help of a walking stick or crutches. Patients who were highly mobile or immobile before the fracture, those with a malignant disease, hip osteoarthritis grade II, III or IV according to the Kellgren-Lawrence grading scale¹⁴ (Figure 1), a subtrochanteric fracture or with propagation of the fracture in the diaphysis of the femur were excluded from the study. All of them suffer from some concomitant disease and are under therapy for a certain cardiovascular disease, and 78% of them have a history and therapy of osteoporosis. Other concomitant diseases included diabetes mellitus (9%), epilepsy (6%), cholelithiasis (6%) and hepatic cirrhosis (6%). Some of them had a combination of several different diseases (e.g. hypertension, heart failure and diabetes mellitus). We classified unstable trochanteric femoral fractures in our patients according to the Jensen modification of the Evans classification of

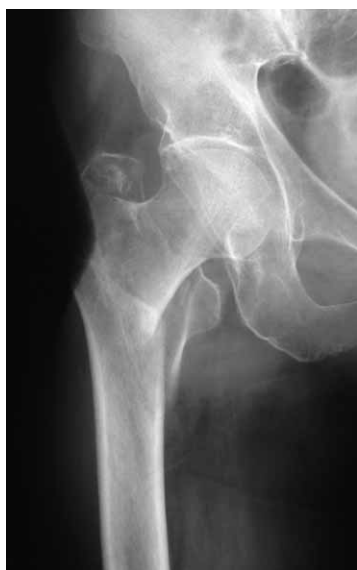

Fig. 1. Preoperative AP radiograph of the hip shows unstable trochanteric femoral fracture with grade I osteoarthritis of the hip according to Kellgren-Lawrence grading scale.

trochanteric femoral fractures¹⁵. According to this classification, all 50 patients were grouped in class II, which includes unstable, three-part trochanteric femoral fractures with loss of posterolateral (type III) or medial support (type IV). Twenty-three patients had type III and 27 patients had type IV trochanteric femoral fracture. Low-molecular-weight heparin (enoxaparin) was injected to avoid deep venous thrombosis 8 hours after the operation and continued for 35 days in daily doses of 40 mg. The second generation cephalosporin was given in doses of 2 grams, 30–60 minutes before surgery and continued for 48 hours postoperatively, three times daily in doses of 1 gram. In cases of a concomitant disease, antibiotic therapy was prolonged over 5 days, while in a case of infection, antibiotic therapy was prolonged over 7 days. Non-steroidal anti-inflammatory medication was administered when there was no contraindication.

Surgical technique

Hemiarthroplasty was performed using the transgluteal Bauer approach¹⁶ in supine position. After meticulous capsulotomy, the femoral neck was removed with preservation of the lesser and the greater trochanter. The medullary canal of the femur was then reamed and the stem length measured. After that, endoprosthesis was cemented with a second generation cementing technique. In the event of a fracture of the greater trochanter, we fixed this part by wire or screw (Figure 2a and b). If the fracture involves a break up in the region of the lesser trochanter (calcar) with loss of the medial arch, we reconstructed this part with wire cerclage, screw, or just cement (Figure 3a and b). The wound was closed by layers.

Postoperative rehabilitation protocol and assessment of the functional status

Patients were encouraged to perform active rehabilitation in bed on postoperative day 1 with the help of a physical therapist, avoiding extensive adduction and rotation. Moderate flexion of both hips and knees, with a pillow between the legs, was recommended in positioning the patient. On the second day after surgery they were able to sit on the bed. On the third day they tried to stand up with the help of a walker. Weight bearing as tolerated was allowed in the hospital and, if the postoperative period proceeded without any complications, the patients were discharged on postoperative day 9–14. The patients were followed up at 6-week intervals in the first six months and then every 3 months. Preoperative and postoperative ambulation was classified in 4 stages, as in a study of Vahl et al.¹⁷: stage I – excellent function; stage II – intermittent pain, sometime using a cane; stage III – walking ability diminished because of pain; and stage IV – poor hip function with total dependency.

Results

We initially treated 56 patients with unstable trochanteric femoral fractures. Six patients were lost from

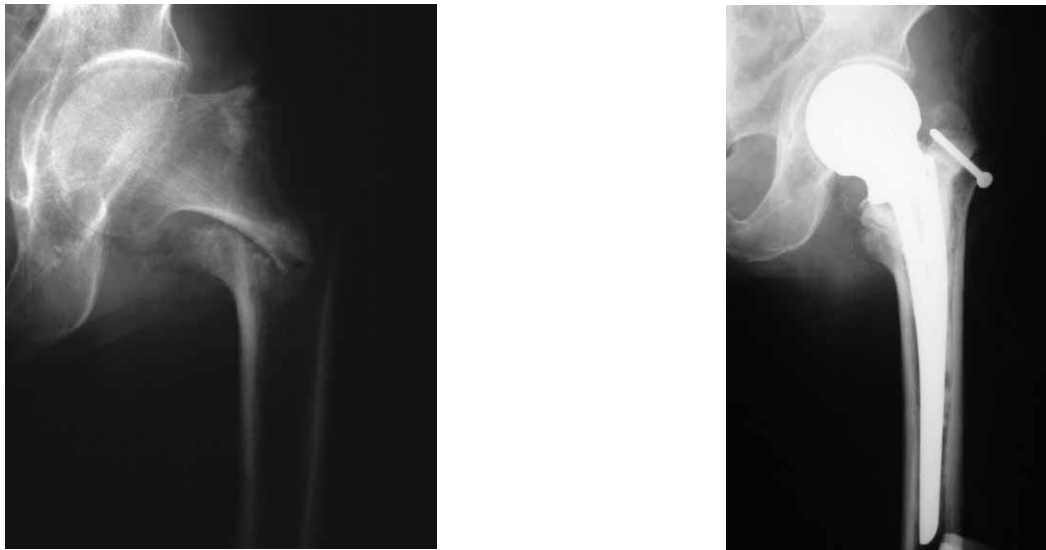


Fig. 2 a) Preoperative AP radiograph of the hip shows unstable trochanteric femoral fracture with fracture of greater trochanter, and b) Postoperative AP radiograph of the same hip after implantation of the partial endoprosthesis and fixation of the greater trochanter with a screw.

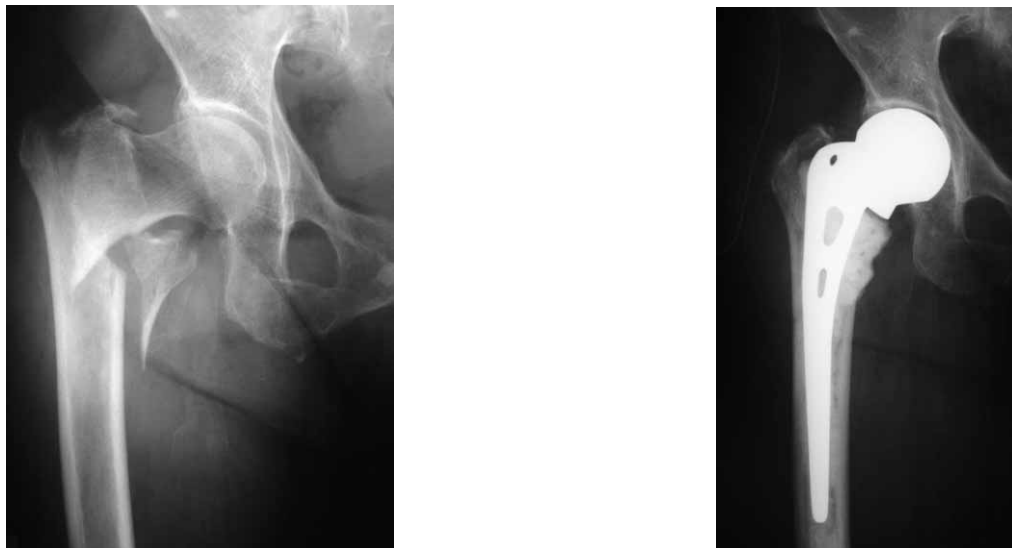


Fig. 3 a) Preoperative AP radiograph of the hip shows unstable trochanteric femoral fracture with partial fracture of greater trochanter and a break up in the region of lesser trochanter (calcar) with loss of the medial arch, and b) Postoperative AP radiograph of the same hip after implantation of the partial endoprosthesis and reconstruction of the lesser trochanter with bone cement.

the study after the second postoperative control examination without any known reason, so we had no relevant data about the mortality rate. Of the 50 treated patients that were included in our study (41 women), aged 75 to 92 years (mean, 86 years), 23 patients had type III and 27 patients type IV trochanteric femoral fracture, according to the Jensen modification of the Evans classification of these fractures¹⁵. Surgery was performed in regional anaesthesia (spinal block L3-L4 region) within 24–48 hours after the fracture (14 of them in the first 12 hours, 27 in the first 24 hours and 9 in the first 48 hours). Mean anaesthesia duration was 120 minutes. The operating time was 35–80 minutes with average blood loss of 600 mL.

The mean follow-up period was 15 months (range 12–18 months). Early complications included one superficial wound infection (treated with wound care and antibiotics), 3 patients had thrombophlebitis and 4 heart failure. Leg shortening was present in 4 patients.

Preoperatively, we grouped all 50 patients in stages according to their ambulation. Forty-three patients (86%) were grouped in stage II and 7 patients (14%) in stage III. Stage I and IV patients were excluded from the study. All 50 patients had a satisfactory range of movement postoperatively (flexion, extension, internal and external rotation of the hip joint). Forty patients (80%) were able to walk with full weight bearing, out of whom 36 (85%) be-

gan to walk in the first and 4 (15 %) in the second postoperative week. Ten patients (20%) were able only to sit on the bed until discharge from hospital. Postoperatively, 22 patients (44%) were grouped in stage II according to their ambulation level, 18 (34%) in stage III and 10 (20%) in stage IV. The 22 patients grouped in stage II have regained their prefracture ambulation level. Eleven patients (22%) lost one stage and 10 (20%) two stages. There was no dislocation, apparent acetabular protrusion or instability of endoprosthesis.

Discussion

Surgical outcomes of unstable trochanteric femoral fractures in elderly people are very doubtful and often unsatisfactory, their contributing factors comprising medical illness, osteoporosis and fracture instability⁹. Early mobilisation is crucial for decreasing the mortality and morbidity risks. Nevertheless, very old patients are unable to walk well and they are only capable of partial weight bearing in the postoperative period^{10,18}.

The choice of an ideal implant for treatment of unstable trochanteric femoral fractures in elderly people is still tentative¹⁹. Problems associated with internal fixation of these fractures in elderly patients with osteoporotic bones are excessive collapse, loss of fixation and cut-out of the lag screw (up to 20 %) ^{20,21}. Some authors have recommended endoprosthetic replacement for the treatment of unstable trochanteric femoral fractures because of earlier postoperative weight bearing and avoidance of excessive collapse at the fracture site^{10,11,22–26}. They used endoprosthetic replacement for trochanteric femoral fractures and reported 75–94% satisfactory results in the early period^{10,11,23,24,26}. Broos et al.²² reported about treatment of pertrochanteric fractures in 94 elderly patients with a bipolar Vandeputte endoprosthesis. The functional results were better in the group treated with bipolar hemiarthroplasty than in groups treated with Ender nailing, an angled blade-plate or a dynamic hip screw.

Although some articles do not recommend hemiarthroplasty as a treatment of choice for unstable trochanteric femoral fractures in the elderly (because of significant blood loss, mechanical difficulties due to the replacement of a large segment of the proximal femur and a high risk of infection which can lead to endoprosthesis removal)^{27,28}, we believe that it is the preferable method of treatment for this kind of fractures in the elderly. These patients usually have advanced osteoporosis with poor bone quality, which can imperil internal fixation. Moreover, elderly people are usually burdened with comorbidities, which may result in additional morbidity and mortality. Because of that, the surgical procedure must be done without delay and with minimal blood loss. Another important issue is early mobilisation of patients after surgery. Some biomechanical studies concluded that the intramedullary implants, when perfectly inserted, enable immediate and uncompromised postoperative full weight bearing^{29,30}. We believe that in sele-

cted very old patients, with comorbidities and obvious osteoporosis, hemiarthroplasty is much safer than internal fixation which can be compromised with poor bone stock.

Because of the high cost of intramedullary implants in comparison to hemiarthroplasty, lack of a C-arm and technical support, we treated unstable trochanteric femoral fractures in elderly people with cemented hemiarthroplasty whenever possible. Since such fractures involve a break up in the region of the lesser trochanter (calcar) with loss of the medial arch, we reconstructed this part with cerclage, screw or just cement. Taking into consideration that these fractures usually occur in the elderly, who are less mobile and less demanding and therefore put less strain on the endoprosthesis, we believe that this kind of treatment is the treatment of choice for unstable trochanteric femoral fractures in these patients. We corroborate this with the fact that we did not have any endoprosthesis luxation or instability; the surgical procedure was done as soon as possible and with minimal blood loss. We did not observe any difference between the type of trochanteric femoral fracture and the results achieved. Moreover, early ambulation with full weight bearing mobilization was achieved in most patients during the short period of hospitalization. The rate of mortality in elderly patients with unstable trochanteric femoral fractures within the first postoperative year is generally high (18.4–33%)³¹. Therefore, the goal of surgical treatment, as the »life-saving procedure« for these patients, is to achieve the preoperative activity level with fast mobilization, which implies satisfactory hip function.

Finally, it is necessary to emphasise that approximately 50% of these patients returned to the preoperative ambulation level, without any correlation to the implant used³². This finding agrees with the results from several retrospective studies^{33–35}. They also observed restoration of preoperative mobility in approximately 40% to 50% of the patients with unstable trochanteric femoral fractures treated with a proximal femoral nail (PFN). Similar results were obtained with the use of a dynamic hip screw (DHS) and a Gamma nail in this kind of patients^{36,37}. Consequently, it seems reasonable to expect approximately half the patients with a trochanteric femoral fracture to regain preoperative ambulation level at the time of fracture healing, regardless of the method of treatment used³². Our results of the 22 patients (44%) who have regained their prefracture ambulation level fit in above-mentioned expectations of returning to the preoperative ambulation level.

Conclusion

We believe that in selected very old patients, with comorbidities and obvious osteoporosis (which can imperil internal fixation), hemiarthroplasty is much safer than internal fixation which can be compromised with poor bone stock. Given that that these fractures usually occur in the elderly, who are less mobile and less demanding and therefore put less strain on the endoprosthesis, we believe that this kind of treatment is the treatment of

choice for unstable trochanteric femoral fractures in these patients. The goal of surgical treatment, as the »life saving procedure« for these patients, is to enable

preoperative activity level with fast mobilization, which imply satisfactory hip function.

REFERENCES

- HOFFMANN R, HASS NP, Trochanteric fractures. In: RÛEDI TP, MURPHY WM (Eds) AO Principles of Fracture Management (Georg Thieme Verlag, Stuttgart, Germany, 2000).
- FINSEN V, BENUM P, Clin Orthop Relat Res, 218 (1987) 104.
- FINSEN V, JOHNSEN LG, TRANO G, HANSEN B, SNEVE KS, Clin Orthop Relat Res, 419 (2004) 173.
- KYLE RF, GUSTILO RB, PREMIER RF, J Bone Joint Surg Am, 61 (1979) 216.
- SINGH AK, THONG G, LALOO N, SINGH AM, SINGH SN, Indian J Orthop, 40 (2006) 100.
- GANZ R, THOMAS RJ, HAMMERLE CP, Clin Orthop, 138 (1979) 30.
- BROOS PLO, FOURNEAU I, Acta Orthop Belg, 66 (2000) 34.
- OSTOJIĆ Z, MORO G, KVESIĆ A, ROTH S, BEKAVAC J, MANOJLOVIĆ S, Coll Antropol, 34 (2010) 243.
- KAYALI C, AGUS H, OZLUK S, SANL C, J Orthop Surg, 14 (2006) 240.
- GREEN S, MOORE T, PROANO F, Clin Orthop Relat Res, 224 (1987) 169.
- HAENTJENS P, CASTELEYN PP, DE BOECK H, HANDELBERG F, OPDECAM P, J Bone Joint Surg Am, 71 (1989) 1214.
- SMRKE D, BIŠČEVIĆ M, SMRKE B, ZUPAN B, Coll Antropol, 34 (2010) 931.
- GRUSS M, TRAUT R, Aktuelle Traumatol, 22 (1992) 144.
- KELLGREN J, LAWRENCE J, Ann Rheum Dis, 16 (1957) 494.
- JENSEN JS, Acta Orthop Scand, 51 (1980) 803.
- R BAUER, F KERSCHBAUMER, S POISEL, W OBERHALER, Arch Orthop Traumat Surg, 95 (1979) 47.
- VAHL AC, DUNKI JACOBS PB, PATKA P, HAARMAN HJ, Acta Orthop Belg, 60 (1994) 274.
- LEUNG KS, SO WS, SHEN WY, HUI PW, J Bone Joint Surg Br, 74 (1992) 345.
- CICVARIĆ T, BENČEVIĆ-STRIEHL H, JURETIĆ I, MARINOVIĆ M, GRŽA-LJA N, OŠTRIĆ M, Coll Antropol, 34 (2010) 199.
- CHAN KC, GILL GS, Clin Orthop Relat Res, 371 (2000) 206.
- FOGAGNOLO F, KFURI M JR, PACCOLA CA, Arch Orthop Trauma Surg, 124 (2004) 31.
- BROOS PLO, ROMMENS PM, GEENS VR, STAPPAERTS KH, Acta Chir Belg, 91 (1991) 242.
- HARWIN SF, STERN RE, KULICK RG, Orthopedics, 13 (1990) 1131.
- RODOP O, KIRAL A, KAPLAN H, AKMAZ I, Int Orthop, 26 (2002) 233.
- ROSENFELD RT, SCHWARTZ DR, ALTER AH, J Bone Joint Surg Am, 55 (1973) 420.
- STERN MB, ANGERMAN A, Clin Orthop, 218 (1987) 75.
- POSTEL M, Rev Chir Orthop, 63 (1977) 133.
- LORD G, MAROTTE KH, BLANCHARD JP, GUILLAMON JL, HANNOUN L, Rev Chir Orthop, 63 (1977) 135.
- FRIEDL W, CLAUSEN J, Chirurg, 72 (2001) 1344.
- GOTZE B, BONNAIRE F, WEISE K, FRIEDL HP, Akt Traumatol, 28 (1998) 197.
- GEIGER F, ZIMMERMANN-STENZEL M, HEISEL C, LEHNER B, DAECKE W, Arch Orthop Trauma Surg, 127 (2007) 959.
- PAJARINEN J, LINDAHL J, MICHELSSON O, SAVOLAINEN V, HIRVEN-SALO E, J Bone Joint Surg Br, 87 (2005) 76.
- BANAN H, AL-SABTI A, JIMULIA T, HART AJ, Injury, 33 (2002) 401.
- AL-YASSARI G, LANGSTAFF RJ, JONES JWM, AL-LAMI M, Injury, 33 (2002) 395.
- SIMMERMACHER RKJ, BOSCH AM, VEN DER WERKEN C, Injury, 30 (1999) 327.
- BUTT MS, KRIKLER SJ, NAFIE S, ALI MS, Injury, 26 (1995) 615.
- MADSEN JE, NAESS L, AUNE AK, ALHO A, EKE-LAND A, STRØMSØE K, J Orthop Trauma, 12 (1998) 241.

G. Gulan

University of Rijeka, Lovran Clinic for Orthopaedic Surgery, Maršala Tita 1, 51415 Lovran, Croatia
e-mail: gordang@medri.hr

PARCIJALNA ENDOPROTEZA ZGLOBA KUKA JE UČINKOVITA METODA LIJEČENJA NESTABILNIH TROHANTERNIH PRIJELOMA U STARIJIH OSOBA

SAŽETAK

Trohanterni prijelomi bedrene kosti u starijih osoba predstavljaju značajan problem za liječenje poradi povećane lomljivosti (fragilnosti) kostiju kao posljedice uznapredovale osteoporoze. Brojne kronične bolesti, koje su obično prisutne u starijih osoba, pogoršavaju i kompliciraju operativno liječenje. Trohanterni prijelomi bedrene kosti u starijih osoba rezultiraju povećanim obolijevanjem i smrtnošću. Cilj ove studije je vrednovati učinkovitost ugradnje parcijalne endoproteze zgloba kuka kao metode liječenja nestabilnih trohanternih prijeloma bedrene kosti u starijih osoba. Između 2000. i 2005. godine, kod 50 bolesnika (41 žena) s nestabilnim trohanternim prijelomom bedrene kosti u dobi između 75 i 92 godine (prosječno 86 godina) ugrađena je cementna parcijalna endoproteza zgloba kuka. Operativni zahvat je učinjen unutar prvih 48 sati od nastalog prijeloma (kod 14 bolesnika u prvih 12 sati, kod 27 bolesnika u prvih 24 sata i kod 9 u prvih 48 sati), s minimalnim gubitkom krvi. Ugradnja parcijalne endoproteze zgloba kuka je bila indicirana u bolesnika kod kojih je bilo važno osigurati stabilnost kako bi se omogućila rana pokretljivost. Kod 40 bolesnika (80%) rana pokretljivost s punim opterećenjem operirane noge postignuta je tijekom kratkog perioda hospitalizacije (9–14 dana). S obzirom na činjenicu da se većinom radi o vrlo staroj populaciji, koja je manje pokretljiva i zahtjevna te time vrši manje opterećenje na ugrađenu parcijalnu endoprotezu zgloba kuka, vjerujemo da je takav način liječenja metoda izbora kod nestabilnih trohanternih prijeloma bedrene kosti u ovih bolesnika. Ovu tvrdnju podupiremo činjenicom da nismo imali niti jednu luksaciju endoproteze, acetabularnu protruziju ili instabilitet endoproteze tijekom perioda praćenja od 15 mjeseci (prosječno 12–18 mjeseci).