

# Undifferentiated pleomorphic breast sarcoma in a male patient

---

**Grebić, Damir; Oštrić, Marin; Radoš, Laura; Radošević, Mia; Gospić, Marko**

*Source / Izvornik:* **Libri Oncologici : Croatian Journal of Oncology, 2024, 52, 146 - 150**

**Journal article, Published version**

**Rad u časopisu, Objavljena verzija rada (izdavačev PDF)**

<https://doi.org/10.20471/LO.2024.52.02-03.21>

*Permanent link / Trajna poveznica:* <https://urn.nsk.hr/urn:nbn:hr:184:907103>

*Rights / Prava:* [Attribution-NonCommercial-NoDerivatives 4.0 International/Imenovanje-Nekomercijalno-Bez prerada 4.0 međunarodna](#)

*Download date / Datum preuzimanja:* **2025-03-17**



*Repository / Repozitorij:*

[Repository of the University of Rijeka, Faculty of Medicine - FMRI Repository](#)





## UNDIFFERENTIATED PLEOMORPHIC BREAST SARCOMA IN A MALE PATIENT

DAMIR GREBIĆ<sup>1</sup>, MARIN OŠTRIC<sup>2</sup>, LAURA RADOŠ<sup>3</sup>,  
MIA RADOŠEVIĆ<sup>3</sup> and MARKO GOSPIC<sup>2</sup>

<sup>1</sup>Department of General and Oncologic Surgery, Clinical Hospital Center Rijeka, Rijeka, Croatia

<sup>2</sup>Department of Cardiothoracic Surgery, Clinical Hospital Center Rijeka, Rijeka, Croatia

<sup>3</sup>Faculty of Medicine, University of Rijeka, Rijeka, Croatia

### Summary

**Objective:** The objective of this case report is to present a rare case of inflammatory undifferentiated pleomorphic sarcoma in a male breast. **Case report:** a 64-year-old man palpated a painless nodule on the left breast. Core needle biopsy did not reveal the final diagnosis as it was classified as B3 so an excisional biopsy of the tissue was performed, which revealed an undifferentiated pleomorphic sarcoma with a diameter of 4.5 cm, infiltrated with inflammatory cells. After we confirmed the sarcoma operation therapy was indicated. Stewart incision was performed and mastectomy was done. Pathohistological analysis confirmed negative surgical resection margins. After one month PET CT scan revealed lungs metastases and the patient underwent 6 chemotherapy cycles of doxorubicin with good response and contribution of lungs metastases remission. Three years later, the tumor recurred and infiltrated the thoracic wall. The patient underwent again to surgical procedure. We did the extirpation of tumor, resection of thoracic wall with large pectoral muscle and within fifth, sixth and seventh ribs resection and thoracoplasty with core matrix and bio-net was performed for reconstruction of the defect. On pathohistology findings distal resection margin was infiltrated by tumor cells so radiotherapy was performed. Larger thoracic resection was not possible as it would affect breathing mechanics. The postoperative course was normal, without paradoxical breathing. The patient has been in remission according to PET-CT examination for four years after the treatment. **Conclusion:** We have presented a rare case of undifferentiated pleomorphic sarcoma in the breast, its potential for recurrence and distant metastases, the possibilities of treatment, the importance and limitations of operative treatment as well as benefit of oncological procedures and unpredictable clinical course of disease.

**KEY WORDS:** *breast sarcoma; metastases; thoracic resection; thoracoplasty*

### INTRODUCTION

Undifferentiated pleomorphic sarcoma (UPS), previously known as Malignant Fibrous Histiocytoma, is an aggressive, high-grade soft tissue sarcoma that is believed to originate from mesenchymal stem cells(1). The classification and diagnosis of UPS have been the subject of ongoing debate for over five decades, with prior subclassifications now considered obsolete(1). Clinically, UPS manifests as a rapidly growing nodule, typically on the limbs or trunk of patients aged be-

tween 50 and 70 years old(2). Breast sarcomas are exceedingly rare, constituting less than 1% of all breast malignancies and less than 5% of all soft tissue sarcomas. The primary treatment for breast sarcomas is surgical resection with clear margins, which is a key determinant of long-term surviv-

Damir Grebić<sup>1</sup> and Marin Oštrić<sup>2</sup> contributed equally for this manuscript

**Corresponding author:** Damir Grebić, Department of General and Oncological Surgery, Clinical Hospital Center Rijeka, Krešimirova 42, 51000, Rijeka, Croatia. E-mail: damir.grebic@medri.uniri.hr

al(3). Axillary lymph node dissection is warranted only in cases with palpable lymph nodes(4). The role of adjuvant chemotherapy remains uncertain and can be used in patients with negative prognosis with distant metastases, while adjuvant radiotherapy is recommended, especially in patients with large or high-grade tumors or positive margin of surgical resection(3). In this report, we present an exceptional case of thoracic UPS in a male patient, characterized by extensive local spread with infiltration of three ribs. The rarity of this case lies not only in the infrequency of UPS in the breast, but also in the atypical clinical course marked by extensive local invasion of thoracic wall and distant metastasis. This atypical presentation underscores the challenging nature of UPS diagnosis and emphasizes the importance of meticulous histological examination to establish a definitive diagnosis. This case serves as a poignant reminder of the complex diagnostic considerations associated with UPS, particularly in the context of its infrequent occurrence in males. Furthermore, the extent of local invasion and distant metastasis in this instance highlights the aggressive nature of UPS and underscores the imperative for a multidisciplinary approach in its management. This case report seeks to contribute to the knowledge surrounding the clinical course and management of UPS, emphasizing the need for heightened vigilance in diagnosing and treating this rare and aggressive soft tissue sarcoma. Additionally, it highlights the importance of considering UPS in the differential diagnosis of thoracic lesions, even in cases where the clinical presentation deviates from established norms. UPS is a new disease according to the World Health Organization WHO classification of soft tissue and bone tumors published in 2013(4).

## CASE REPORT

A 64-year-old male patient was admitted to our hospital with a painless, enlarging mass in his left breast over the preceding months. No cutaneous alterations overlying the mass were noted. As core needle biopsy did not reveal the final diagnosis and was classified as B3, subsequently the patient underwent surgical intervention for tumor extirpation followed by histopathological evaluation. The analysis identified features consistent

with inflammatory Undifferentiated Pleomorphic Sarcoma (UPS). Notable histological findings included spindle, round, and multinucleated CD68-positive osteoclast-like cells accompanied by pronounced neutrophilic and mononuclear cell infiltrates and a high mitotic index. Extensive necrosis and hemorrhagic areas were also evident within the tumor. The excised tumor tissue measured 4.5 cm in diameter. Due to such pathological findings we indicated radical operative treatment so mastectomy was done with Stewart's incision for approach resulting in complete removal of the left breast and underlying major pectoral muscle fascia. Pathohistological assessment revealed residual necrotic tumor remnants from the previous operation; however, the resection margins exhibited no evidence of malignant cells. Subsequent to this intervention, the patient underwent a PET CT scan that reveal the multiple lungs metastases. In response, oncological intervention was recommended and pursued at an alternate clinical facility. The patient received six cycles of doxorubicin chemotherapeutic treatment with successful response upon which the metastases have receded. Three years after the initial surgical intervention a CT scan indicated local recurrence of the tumor within the left thoracic wall, but without distal metastases. This recurrence was characterized by two dis-

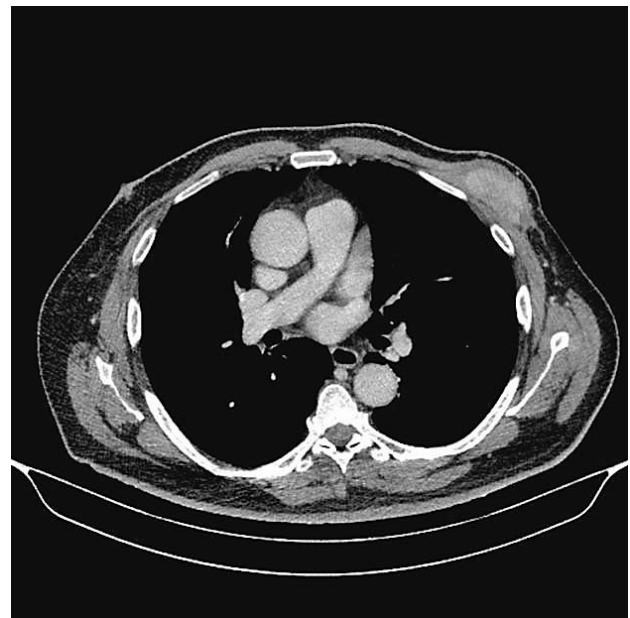

Figure 1. CT scan showing extensive relapse that infiltrates the large pectoral muscle and ribs, indicated by a blue arrow.

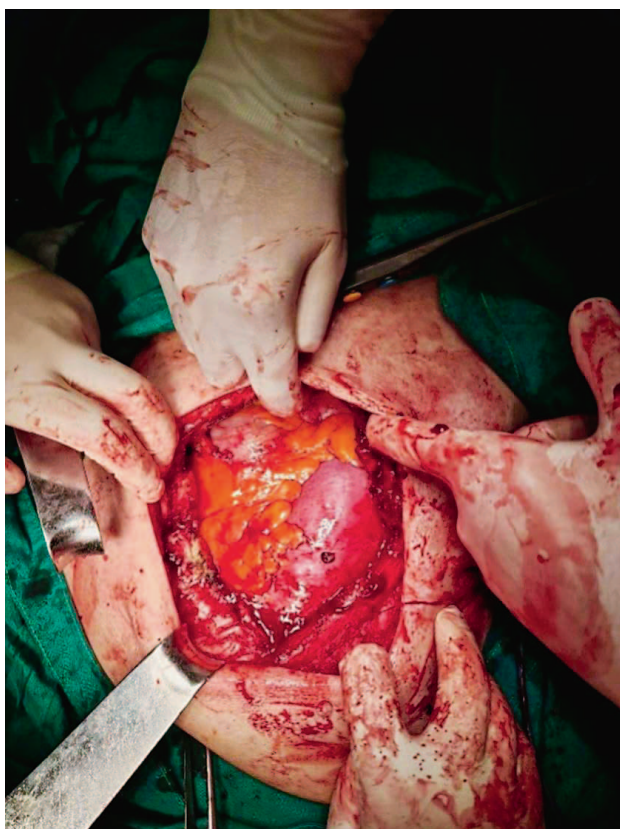

Figure 2. The condition after resection of the thoracic wall. Lung tissue and an orderly intrathoracic finding can be seen.

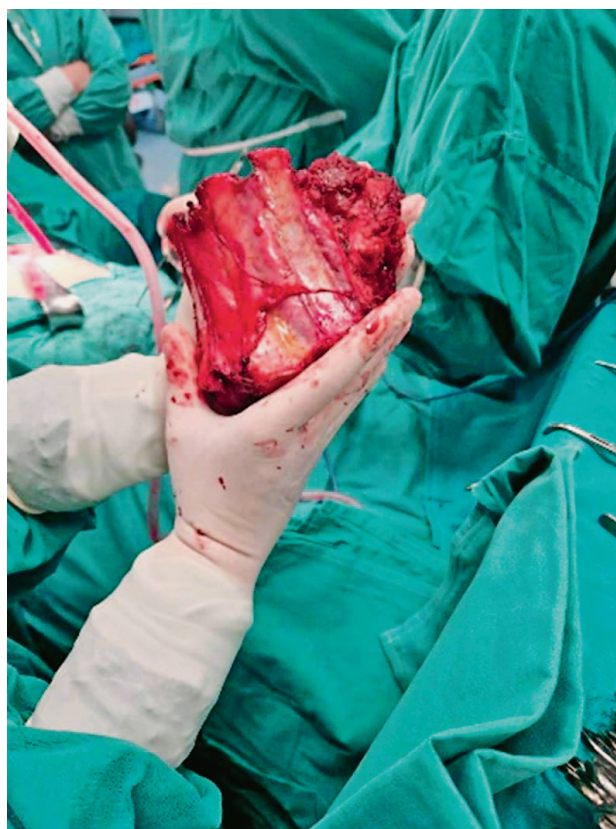


Figure 3. The resected thoracic wall together with sarcoma.

tinct lesions, with one infiltrating the intercostal musculature (Figure 1.). In the ensuing month, a surgical procedure was undertaken, necessitating resection of the fifth, sixth and seventh ribs (Figure 2., Figure 3.), followed by reconstruction of thoracic defect through thoracoplasty, including a core matrix and bio-net (Figure 4.). The wound was closed after setting up a drain (Figure 5.) and the extirpated sample was pathohistological examined (Figure 3.) which revealed malignant cell infiltration at the distal resection margin. Further resection of thoracic wall was deemed unfeasible, as it would disrupt the pulmonary-thoracic pressure equilibrium, potentially compromising respiration and elevating the risk of thoracic organ failure. We indicated radiotherapy as further treatment option and it was performed (total dose 6000cGy/30fraction). Following hospital discharge, the patient was provided with scheduled follow-up appointments along with a prescribed regimen of respiratory and expectorant exercises. The patient

has been in remission according to PET-CT examination for four years after the treatment.

## DISCUSSION

There is no clear origin for histogenesis of UPS; therefore, this histological entity represents a unique diagnostic and therapeutic challenge(5). Our case represents a rarity, since less than 1% of sarcomas are found in the breast and less than 5% of breast tumors are sarcomas. Therefore, there are limited resources available for clinicians to use in order to provide the patient with the best possible care. It seems that the best treatment for breast UPS is quality surgical resection with clean edges, but this does not guarantee full recovery as it is seen in this case, where despite successful surgical removal, there was a relapse and metastases in the lungs(3). Advanced age, large tumors and radiation-associated tumors have been associated with reduced survival rates in patients with UPS.

In a clinical research conducted in the USA, the median age of UPS diagnosis was 64 years, and 63% of the cohort comprised of males. In the USA research, the primary sites of origin are the extremities (73%), trunk or retroperitoneum (24%), and head and neck (3%). The median tumor size is 7.5 cm and the majority of the tumors are high-grade (76%)(5). Our patient had also high-grade tumor with unusually location in the breast.

Historically, sarcomas were the first tumor models for which immunotherapy was suggested as a relevant therapeutic strategy. The higher incidence of sarcoma in immunocompromised patients also supports the relevance of targeting the immune system to this disease(2). Our patient had multinucleated CD68-positive osteoclast-like cells accompanied by pronounced neutrophilic and mononuclear cell infiltrates, as well as a high mitotic index, indicating poor cell differentiation. Immune cells in the tumor microenvironment play a protumoral role in UPS. Tumor-associated macrophages (TAMs) produce significant cytokines, including TGF- $\beta$ , and IL6, which aberrantly activate downstream signaling and thus induce cell proliferation, migration and invasion in UPS(6).

Since the revision of the WHO classification in 2013, only four cases of primary mediastinal UPS have been reported, only one of the four cases had pleural effusion. The general prognosis of mediastinal UPS is poor because of its rapid progression and the difficulty of complete resection of the primary lesion in the mediastinum(7). Although the prognosis was poor, our patient successfully achieved remission and is currently in remission for four years after treatment. Surgery remains the mainstay treatment for all patients with localized UPS. However, the infiltrative growth pattern of UPS is a negative prognostic factor after surgery(8). Due infiltration of tissue is difficult to achieve the clear margin of resection. In such case with unclear resection margin the radiotherapy remains the treatment options as can be seen in this case report(9).

Welsch studied the negative association of infiltration patterns with local control and advised separate assessment of all tumor margins against residual infiltrative *tail*. Wide or radical excision involving the *tail* is required; otherwise, these sarcomas are prone to local recurrence and metastasis. Wide excision followed by radiotherapy is typically recommended for deep lesions; howev-

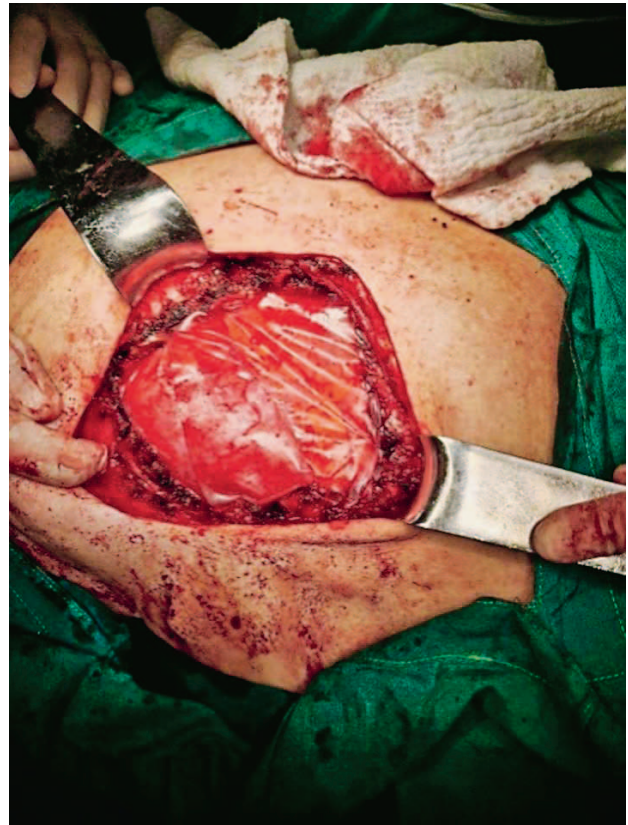


Figure 4. Thoracoplasty with core matrix and bio-net was performed for the reconstruction of the defect of thoracic wall

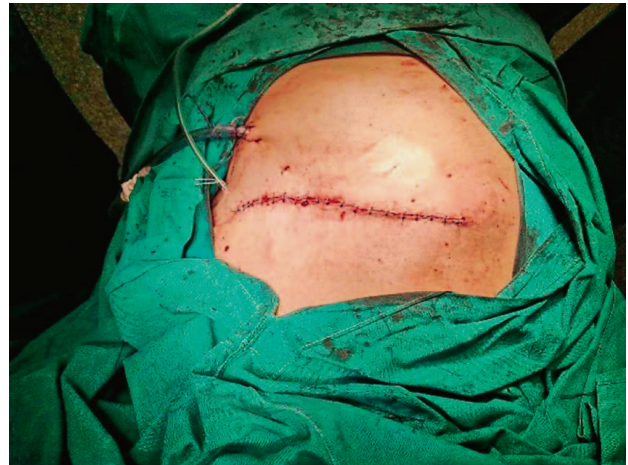

Figure 5. Primarily closed wound with a drain set up.

er, additional radiation might be limited for post-radiation UPS(9). Our patient was undergone to all of treatment options, including surgical and oncological procedure with successful results although he had one relapse of disease.

## CONCLUSION

In conclusion, UPS presents a unique diagnostic and therapeutic challenge due to its unclear origin and aggressive nature. This case study highlighted the rarity of UPS in the breast, its potential for local invasion and distant metastases and the importance of surgical resection as well as importance of subsequent oncological treatment procedures. However, the case also underscored the limitations of surgery as recurrence and metastases occurred despite successful initial removal. The role of immune cells in UPS progression was also noted, suggesting potential avenues for future research and oncological treatment strategies. This case underscores the need for a multidisciplinary approach and heightened vigilance in diagnosing and managing UPS.

## REFERENCES

1. Robles-Tenorio A, Solis-Ledesma G. Undifferentiated Pleomorphic Sarcoma. StatPearls Publishing 2023.
2. Widemann BC, Italiano A. Biology and Management of Undifferentiated Pleomorphic Sarcoma, Myxofibrosarcoma, and Malignant Peripheral Nerve Sheath Tumors: State of the Art and Perspectives. J Clin Oncol 2018;10;36(2):160-7. doi:10.1200/JCO.2017.75.3467
3. Kumar S, Sharma J, Ralli M, Singh G, Kalyan S, Sen R. Primary Stromal Sarcoma of Breast: A Rare Entity. Iran J Pathol 2016;11(5):469-73.
4. Anzali CB, Goli R, Faraji N, Torabzadeh A, Najafzad Z, Nikpey S. Invasion of undifferentiated pleomorphic sarcoma (UPS) in breast tissue; a case report study. Int J Surg Case Rep 2023;(107): 108307. doi:10.1016/j.ijscr.2023.108307.
5. Roland CL, May CD, Watson KL et al. Analysis of clinical and molecular factors affecting oncological outcomes in undifferentiated pleomorphic sarcoma. Ann Surg Oncol 2016; 23(7):2220-8. doi:10.1245/s10434-016-5115-5.
6. Sun H, Liu J, Hu F, Xu M, Leng A, Jiang F, Chen K. Current research and management of undifferentiated pleomorphic sarcoma/myofibrosarcoma. Front Genet 2023;14:1109491. doi:10.3389/fgene.2023.1109491.
7. Matsumoto K, Nakamura Y, Inagaki Y et al. Mediastinal undifferentiated pleomorphic sarcoma with pleural effusion cytopathologically misdiagnosed as epithelial malignant pleural mesothelioma: An autopsy case report. Thorac Cancer 2021;12(7):1137-40. doi:10.1111/1759-7714.13898.
8. Kang DK, Kang MK, Heo W, Hwang YH, Kim JY. Primary Pulmonary Undifferentiated Pleomorphic Sarcoma: A Rare Malignant Lung Tumor. J Investig Med High Impact Case Rep 2021;9:23247096211008593. doi:10.1177/23247096211008593.
9. Welsch, K, Breuninger, H, Metzler, G et al. Patterns of infiltration and local recurrence of various types of cutaneous sarcomas following three-dimensional histology. J. Dtsch Dermatol Ges 2018;16(12), 1434–42. doi:10.1111/ddg.13708.

## Sažetak

### NEDIFERENCIRANI PLEOMORFNI SARKOM DOJKE U MUŠKARCA

*D. Grebić, M. Oštrić, L. Radoš, M. Radošević, M. Gospić*

**Cilj:** Cilj je ovog rada prikazati rijedak slučaj inflamatornog nediferenciranog pleomorfno sarkoma u muškoj dojci.

**Prikaz slučaja:** 64-godišnji muškarac napipao je bezbolni čvor u lijevoj dojci. Širokoiglena biopsija nije razjasnila završnu dijagnozu te je klasificirana sa B3. Stoga se pristupilo operacijskom postupku. Učinjena je ekstirpacija tumora, a patohistološki nalaz potvrdio je nediferencirani pleomorfni sarkom promjera 4,5 cm, infiltriran upalnim stanicama. Nakon potvrde sarcoma indicirana je bila operacijska terapija. Pristupilo se inciziji po Stewartu te se učinila mastektomija. Patohistološkom analizom potvrđeni su negativni kirurški resekcijски rubovi. Mjesec dana kasnije PET CT pregledom otkrivene su plućne metastaze, zbog čega je pacijent prošao kroz 6 kemoterapijskih ciklusa doksorubicina sa dobrim odgovorom na terapiju te je postignuta kompletna remisija plućnih metastaza. Tri godine kasnije CT nalaz pokazao je recidiv tumora sa infiltracijom cijele debljine torakalne stijenke. Indicirano je bilo kirurško liječenje. Operacijom je uklonjen tumor i veliki pektoralni mišić u bloku sa šestim, sedmim i osmim rebrom te je učinjena torakoplastika core matrixom i biološkom mrežicom u svrhu rekonstrukcije defekta. U patohistološkom nalazu distalni resekcijски rub bio je pozitivan, infiltriran tumorskim stanicama, te je stoga bolesnik bio podvrgnut radioterapiji. Širi opseg operacije nije bio moguć zbog opasnosti utjecaja na mehaniku disanja. Postoperativni tijek je bio uredan, bez paradoksalnog disanja. Bolesnik je sljedeće četiri godine praćen jednom godišnje PET CT-om te do sada nije imao znakove ponovnog recidiva bolesti kao niti metastaza.

**Zaključak:** Prikazali smo rijedak slučaj nediferenciranog pleomorfno sarkoma u dojci, njegov potencijal za lokalnu invaziju i sklonost recidiviranju kao i metastaziranju, te važnost, ali i ograničenja operativnog liječenja kao i značaj sveobuhvatne onkološke terapije i nepredvidiv klinički tijek bolesti.

**KLJUČNE RIJEČI:** sarkom dojke; metastaze; resekcija rebra; torakoplastika