

# Perkutana aspiracijska trombektomija u Paget-Schroetterovu sindromu - prikaz bolesnika

---

**Antonić, Ana; Benko, Koraljka; Uglešić, Kristina; Nadarević, Tin; Tomulić, Vjekoslav**

*Source / Izvornik:* **Cardiologia Croatica, 2023, 18, 211 - 217**

**Journal article, Published version**

**Rad u časopisu, Objavljena verzija rada (izdavačev PDF)**

<https://doi.org/10.15836/ccar2023.211>

*Permanent link / Trajna poveznica:* <https://urn.nsk.hr/urn:nbn:hr:184:492619>

*Download date / Datum preuzimanja:* **2024-12-20**



*Repository / Repozitorij:*

[Repository of the University of Rijeka, Faculty of Medicine - FMRI Repository](#)



# Perkutana aspiracijska trombektomija u Paget-Schroetterovu sindromu – prikaz bolesnika

## Percutaneous Aspiration Thrombectomy in Paget-Schroetter Syndrome: A Case Report

 Ana Antonić\*,  
 Koraljka Benko,  
 Kristina Uglešić,  
 Tin Nadarević,  
 Vjekoslav Tomulić

Klinički bolnički centar Rijeka,  
Rijeka, Hrvatska  
University Hospital Centre  
Rijeka, Rijeka, Croatia

RECEIVED:

March 11, 2023

UPDATED:

March 26, 2023

ACCEPTED:

May 2, 2023



**SAŽETAK:** Prikazujemo slučaj mlađeg, fizički aktivnog bolesnika u kojemu su se pri hitnom prijemu manifestirali otekline, bolnost i plavičasta diskoloracija lijeve ruke te mu je obradom ustanovljena naporom inducirana duboka venska tromboza ruke (Paget-Schroetterov sindrom). Nakon neuspješna medikamentnog liječenja terapijskom dozom niskomolekularnog heparina liječen je endovaskularnim zahvatom – perkutanom aspiracijskom trombektomijom. Postupak je protekao uredno uz uspostavu rubnog protoka kroz potključnu, pazušnu te cefaličnu venu usprkos ostatnim trombotskim masama. Prije otpusta uvedena je peroralna antikoagulantna terapija rivaroksabanom. U sklopu obrade sindroma gornje torakalne aperture provedena je dodatna slikovna obrada kojom je dijagnoza potvrđena. Nalazi proširene laboratorijske obrade bili su u granicama normale. Na kontrolnim pregledima praćena je regresija tegoba. Color Doppler ultrazvukom te klinički verificiran je i dalje održan rubni protok kroz zahvaćene vene uz rezidualne male trombe te razvoj kolaterala. U bolesnika se razmatra dekompresijsko liječenje resekcijom prvog rebra kao konačno rješenje uzroka tegoba.

**SUMMARY:** We report the case of a younger, physically active patient who presented at the emergency department with swelling, pain, and bluish discoloration of the left arm, with clinical examination identifying effort-induced deep vein thrombosis of the arm (Paget-Schroetter syndrome). After unsuccessful medication treatment with a therapy dose of low-molecular-weight heparin, the patient was treated with an endovascular procedure – percutaneous aspiration thrombectomy. The procedure was successful, with the establishment of peripheral flow through the subclavian, axillary, and cephalic vein despite some thrombotic masses remaining. Before discharge, the patient was placed on peroral anticoagulation treatment with rivaroxaban. Additional imaging was performed during treatment of the superior thoracic aperture, confirming the diagnosis. Expanded laboratory testing showed values within normal limits. Follow-up showed regression of the symptoms. Color Doppler ultrasound and clinical examination verified maintenance of peripheral flow through the affected veins, with residual small thrombi and the development of collaterals. The patient was subsequently considered for decompression therapy by removing the first rib as a permanent solution for the symptoms.

**KLJUČNE RIJEČI:** tromboza potključne vene, perkutana trombektomija.

**KEYWORDS:** subclavian vein thrombosis, percutaneous thrombectomy.

**CITATION:** *Cardiol Croat.* 2023;18(7-8):211-7. | <https://doi.org/10.15836/ccar2023.211>

\***ADDRESS FOR CORRESPONDENCE:** Ana Antonić, Klinički bolnički centar Rijeka, Tome Stričića 3, HR-51000 Rijeka, Croatia. / Phone: +385-51-407-225 / E-mail: [aantonic326@gmail.com](mailto:aantonic326@gmail.com)

**ORCID:** Ana Antonić, <https://orcid.org/0000-0002-5767-1206> • Koraljka Benko, <https://orcid.org/0000-0001-7556-0860>  
Kristina Uglešić, <https://orcid.org/0000-0003-0869-3748> • Tin Nadarević, <https://orcid.org/0000-0002-1174-5281>  
Vjekoslav Tomulić, <https://orcid.org/0000-0002-3749-5559>

**TO CITE THIS ARTICLE:** Antonić A, Benko K, Uglešić K, Nadarević T, Tomulić V. Percutaneous Aspiration Thrombectomy in Paget-Schroetter Syndrome: A Case Report. *Cardiol Croat.* 2023;18(7-8):211-7. | <https://doi.org/10.15836/ccar2023.211>

**TO LINK TO THIS ARTICLE:** <https://doi.org/10.15836/ccar2023.211>

### Uvod

Duboka venska tromboza (DVT) gornjih ekstremiteta obuhvaća oko 10 % svih dubokih venskih tromboza s incidencijom od 4 do 10 bolesnika na 100 000 stanovnika<sup>1</sup>. Dva su tipa – primarna, inducirana naporom tj. Paget-Schroetterov sin-

### Introduction

Deep vein thrombosis (DVT) of the upper extremities comprises approximately 10% of all deep vein thromboses, with an incidence of 4 to 10 patients per 100 000 population<sup>1</sup>. There are two types – primary DVT induced by effort, i.e.,

drom na koji otpada oko 20 % svih DVT-a gornjih ekstremiteta, te mnogo češće, sekundarna DVT koja je povezana s primjenom centralnih venskih katetera, terapijskih ili dijaliznih (tuneliranih ili netuneliranih), elektroda elektrostimulatora srca te portova<sup>1,2</sup>.

Paget-Schroetterov sindrom (PSS) jest naporom (napreznjem) inducirana tromboza potključne vene, a često joj je pridružena i tromboza pazušne i cefalične vene. Opisala su je potkraj 19. stoljeća dva autora (Sir James Paget i Leopold von Schroetter) koji su primijetili naporom induciranu trombozu potključne vene većinom u mladih, inače zdravih muškaraca<sup>3</sup>. Riječ je o podvrsti venskog tipa sindroma gornje torakalne aperture (*thoracic outlet syndrome* – TOS)<sup>4</sup>. Sindrom gornje torakalne aperture obuhvaća spektar stanja koja nastaju zbog kompresijske ozljede ili iritacije struktura koje prolaze kroz gornju torakalnu aperturu; prostora u donjem dijelu vrata / gornjem dijelu prsnog koša, između ključne kosti i prvog rebra, kroz koji prolazi brahijalni plexus, te potključna vena i arterija. Medijalno od potključne vene nalazi se kostoklavikularni ligament, a lateralno prednji skalenski mišić. Najčešći tip TOS-a jest neurogeni, koji nastaje zbog kompresije na brahijalni plexus i očituje se boli i slabošću zahvaćene ruke<sup>2,4,5</sup>.

Venski tip TOS-a obuhvaća tri podvrste: primarnu DVT (PSS), sekundarnu DVT te pozicijsku opstrukciju vene<sup>4,5</sup>.

PSS je rijetko stanje, s incidencijom od 1 do 2 na 100 000 stanovnika, dvostruko je češći u muškaraca nego u žena te se češće pojavljuje na desnoj strani. Povezan je s repetitivnim kretnjama u zahvaćenom ramenu (bilo u pojedinim profesijama, kao i u profesionalnih ili amaterskih sportaša). U abdukciji ruke dolazi do kompresije potključne vene između ključne kosti i prvog rebra, što je podloga za Virchowljev trijas<sup>2</sup>. Druge anatomske inačice koje pridonose razvoju tromboze uključuju abnormalnu inserciju prvog rebra, kongenitalne tračke ili prisutnost vratnog rebra, a dodatno mogu utjecati i pridružena hematološka stanja<sup>2</sup>.

Kliničke manifestacije PSS-a jesu distenzija vena, otjecanje zahvaćene ruke, plavičasta diskoloracija te bol (pokatkad uz pogoršanje boli nakon vježbe). U dijagnostici nakon anamneze i kliničke slike te d-dimera (koji nema veliku kliničku važnost) metoda izbora u oslikavanju jest Color Doppler ultrazvuk. Od ostalih metoda provode se venografija te CT i MR vrata i gornje torakalne aperture<sup>1,2,4-6</sup>.

Strategije liječenja PSS-a – a obuhvaćaju antikoagulaciju u trajanju minimalno tri mjeseca (niskomolekularni heparin, novi oralni antikoagulansi, antagonisti vitamina K); uklanjanje tromba (kateterom vođena tromboliza ili farmakomehanička tromboliza) te kirurško liječenje – dekompresija torakalne aperture resekcijom prvog rebra.

## Prikaz bolesnika

Amaterski *body-builder* i boksač u dobi od 37 godina, prethodno zdrav, nepušač te negativne obiteljske anamneze na kardiovaskularne bolesti, koji ne uzima kroničnu terapiju, ali uzima suplemente testosterona (jednom tjedno te ih primjenjuje intramuskularno) javio se u Objedinjeni bolnički prijem Kliničkog bolničkog centra Rijeka zbog otjecanja lijeve ruke (**slika 1 i 2**). Tegobe su bile prisutne četiri dana prije prijema. Ultrazvučno mu je ustanovljena DVT lijeve potključne, pazušne i cefalične vene. U laboratorijskim je nalazima praćena blaga leukocitoza na račun neutrofila uz tek blago povišene vrijed-

Paget-Schroetter syndrome, comprising approximately 20% of all DVTs of the upper extremities, and the much more common secondary DVT, which is associated with the application of central venous catheters and therapy or dialysis (tunneled or non-tunneled) cardiac pacemaker leads and ports<sup>1,2</sup>.

Paget-Schroetter syndrome (PSS) is thrombosis of the subclavian vein induced by exertion, often concomitant with thrombosis of the axillary and cephalic vein. It was described near the end of the 19<sup>th</sup> century by two authors (Sir James Paget and Leopold von Schroetter), who observed effort-induced subclavian vein thrombosis mostly in young, otherwise healthy men<sup>3</sup>. It represents a subtype of the venous type of thoracic outlet syndrome (TOS)<sup>4</sup>. TOS refers to a spectrum of states that occur due to compression injury or irritation to structures passing through the superior thoracic aperture, the space in the lower part of the neck / upper part of thorax, between the collarbone and the first rib, containing the brachial plexus and the subclavian vein and artery. The costoclavicular ligament is located medially from the subclavian vein, and the anterior scalene muscle is located laterally. The most common type of TOS is neurogenic, developing due to compression of the brachial plexus and manifesting as pain and weakness in the affected arm<sup>2,4,5</sup>.

Venous TOS has three subtypes: primary DVT (PSS), secondary DVT, and positional venous obstruction<sup>4,5</sup>.

PSS is a rare condition, with an incidence of 1 to 2 per 100 000 population, is twice as common in men as in women, and is more common on the right side. It is associated with repetitive movements of the affected shoulder (a consequence of work in some professions, or in professional or amateur athletes). Arm abduction leads to compression of the subclavian vein between the clavicle and the first rib, which is the basis for Virchow's triad<sup>2</sup>. Other anatomic factors that contribute to the development of thrombosis include abnormal formation of the first rib, congenital bands, or the presence of a cervical rib, and can be additionally influenced by concomitant hematological states<sup>2</sup>.

Clinical manifestations of PSS are venous distension, swelling in the affected arm, bluish discoloration, and pain (sometimes with pain exacerbation after exercise). In addition to anamnesis, the clinical picture, and d-dimers (which do not have great clinical significance), the method of choice for imaging is Color Doppler ultrasound. Other diagnostic methods include venography as well as CT and MR of the neck and the superior thoracic aperture<sup>1,2,4-6</sup>.

Treatment strategies for PSS include anticoagulation treatment lasting a minimum of three months (low-molecular-weight heparin, new oral anticoagulants, vitamin K antagonists), thrombi removal (catheter-directed thrombolysis or pharmacomechanical thrombolysis), and surgical treatment – decompression of the thoracic aperture by resection of the first rib.

## Case report

A 37-year-old amateur body-builder and boxer, previously healthy, a non-smoker, with negative family history for cardiovascular diseases, who was not receiving any chronic treatment but was taking testosterone supplements (once per week applied intramuscularly), presented at the Joint Hospital Admission of the Rijeka Clinical Hospital Center due to swelling of the left arm (**Figure 1, Figure 2**). The symptoms had been present for four days before admission. Ultrasound examina-

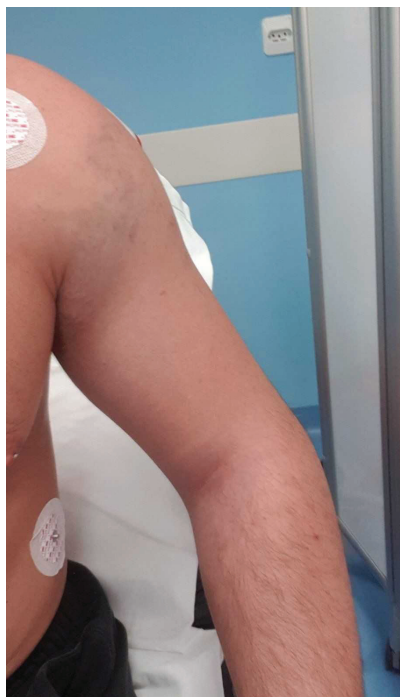

FIGURE 1. Swollen left arm with venous distension.

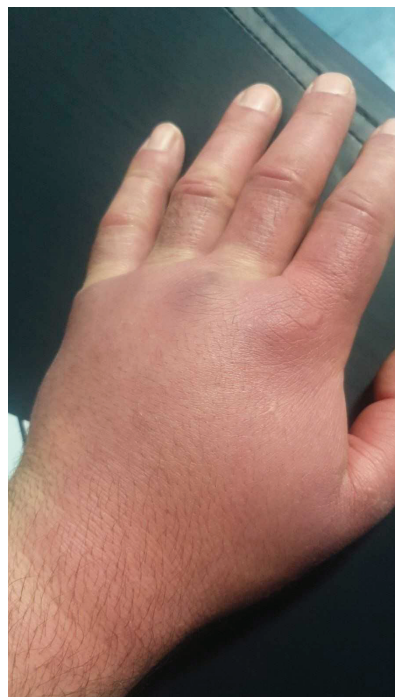

FIGURE 2. Swollen left arm.

nosti C-reaktivnog proteina (L  $10,3 \times 10^9/L$ , neutrofila 76,3 %, CRP 11 mg/L). Radiogram grudnih organa bio je uredan, a u 12-kanalnom elektrokardiogramu verificiran je sinusni ritam frekvencije klijetki 90/min uz aplanirane T-valove inferolateralno. Na Zavodu za vaskularnu kirurgiju započeto je liječenje terapijskom dozom niskomolekularnog heparina i ono je nastavljeno tijekom devet dana. Usprkos primijenjenoj terapiji nije bilo kliničkog poboljšanja. Devetog dana hospitalizacije prikazan je na konziliju vaskularnih kirurga i kardiologa te je indicirana perkutana aspiracijska trombektomija.

Nakon odgovarajuće pripreme bolesnika preko desne bedrene vene postavljena je uvodnica od 6 French (F) te je postavljen *multipurpose angiographic* (MPA) kateter u ishodište lijeve potključne vene. Žicom vodilicom *Gaia 3rd* prođe se proksimalna kapa okluzije i s pomoću balonskog katetera NC 4,5 x 15 mm uspije se proći do projekcije izlazišta cefalične vene, ali se žica vodilica ne uspije plasirati dalje prema pazušnoj veni. Potom se pod kontrolom ultrazvuka postavi uvodnica od 6 F u kubitarnu venu, te se hidrofilnom žicom vodilicom sada anterogradnim pristupom prođe mjesto okluzije, a žica se distalno postavi u donju šuplju venu. Izvede se višestruka reolitička trombektomija *Angiojet Omni* kateterom. Balonskim kateterima 8 x 40 mm i 12 x 40 mm dilatira se cijeli tijek okludiranog segmenta. Konačni venogram upućuje na restoraciju protoka u pazušnoj i potključnoj veni, uz i dalje vidljive trombotske mase potključno (**slike 3, 4, 5, 6 i 7**).

Drugog dana nakon intervencije praćena je regresija tegoba i kliničko poboljšanje (vidljiva regresija otekline ruke i povećana mobilnost). Obavljena je venografija (preko desne kubitarnu vene zbog još uvijek izražene otekline lijeve ruke) kojom su verificirane uredne dimenzije vena lijeve ruke uz djelomičnu trombotsku opstrukciju. Ultrazvuk vena ruke učinjen je drugog dana nakon intervencije, 14 dana nakon intervencije

tion found DVT of the left subclavian, axillary, and cephalic veins. Laboratory findings showed mild neutrophilic leukocytosis with only mildly elevated C-reactive protein levels (L  $10,3 \times 10^9/L$ , neutrophils 76.3 %, CRP 11 mg/L). The chest radiograph was normal, and 12-lead electrocardiogram examination verified sinus rhythm with a ventricular frequency of 90/min and inferolaterally flattened T-waves. Treatment was initiated at the Department for Vascular Surgery using a therapy dose of low-molecular-weight heparin, which was continued for nine days. Despite the treatment, no clinical improvement was observed. On the ninth day of hospitalization, the patient's case was presented at the vascular surgeon and cardiologist consilium, and percutaneous aspiration thrombectomy was indicated.

After appropriately preparing the patient, the femoral vein approach was used to place a 6 French (F) sheath and a multipurpose angiographic (MPA) catheter at the origin of the left subclavian vein. A *Gaia 3rd* guide wire was used to bypass the proximal cap of the occlusion, and the application of a NC 4.5 x 15 mm balloon catheter was used to successfully proceed to the projection of the origin of the cephalic vein, but the guidewire was unable to continue towards the axillary vein. Subsequently, ultrasound control was used to place a 6 F sheath into the cubital vein, and a hydrophilic guide wire as used to bypass the occlusion point, now using an antero-grade approach, and the guide wire was placed distally in the inferior vena cava. A rheolytic thrombectomy was performed using an *Angiojet Omni* catheter. Two 8 x 40 mm and 12 x 40 mm balloon catheters were used to dilate the entire occluded segment. The final venogram indicated restored flow in the axillary and subclavian vein, with still visible subclavicular thrombotic masses (**Figures 3-7**).

Regression of symptoms and clinical improvement (visible regression of the arm swelling and increased mobility) were



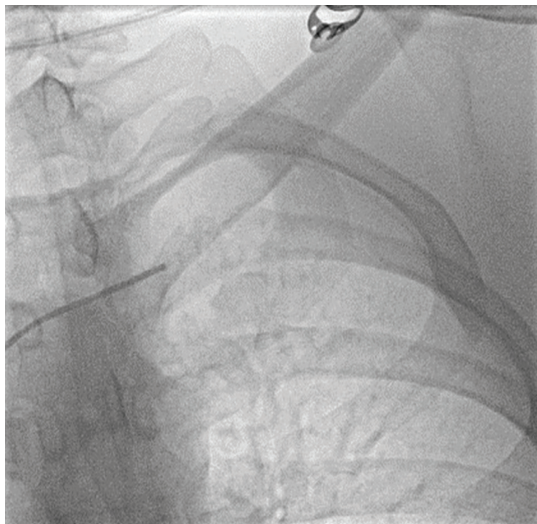


FIGURE 3. Multipurpose angiographic catheter in the left subclavian vein.

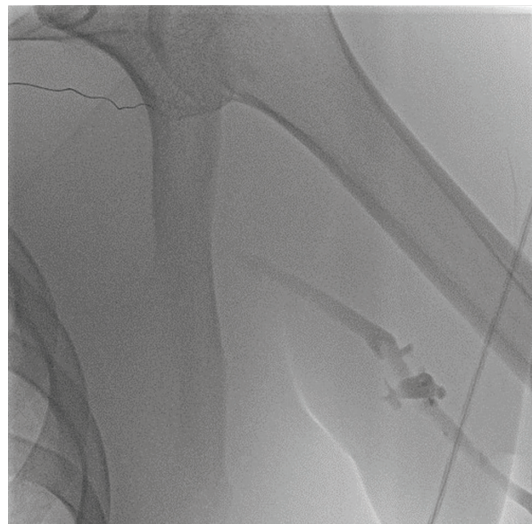

FIGURE 4. Filling defect of an axillary vein.

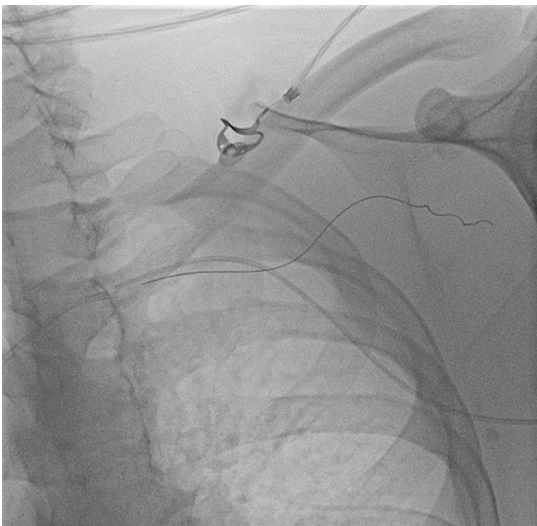


FIGURE 5. Two catheters in the veins and a guide wire.

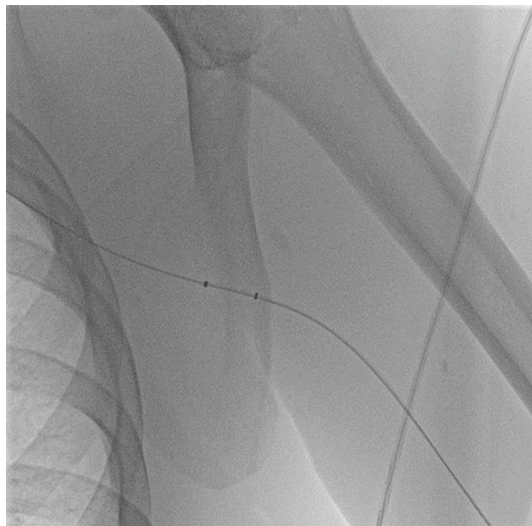


FIGURE 6. Angio Jet catheter.

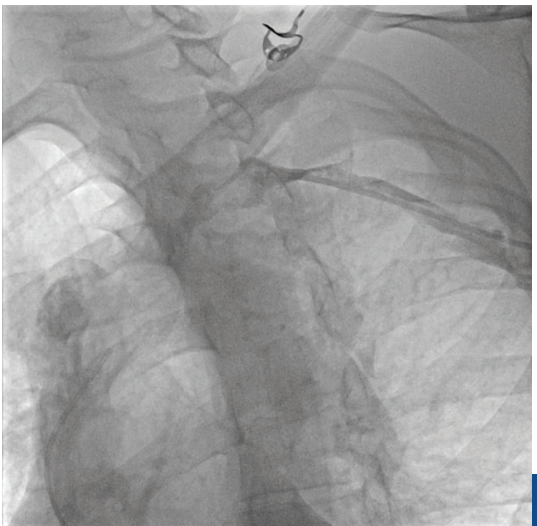


FIGURE 7. Restoration of the blood flow with residual thrombosis

te četiri mjeseca nakon toga. Njime je ustanovljen rezidualni tromb potključne vene, ali uz održani rubni protok (**slika 8**).

U vezi s dekompresijskim liječenjem obavljene su konzultacije torakalnim kirurgom koji nije indicirao kirurško liječenje, nego nastavak antikoagulantne terapije i magnetnu rezonanciju vrata i gornje torakalne aperture. Učinjenom pretragom ustanovljena je sužena lijeva potključna vena u području lijevogva kostoklavikularnog prostora s dvama sitnim rezidualnim trombima, duljeg promjera od 6 mm. Također je jasno uočeno da donja stijenka lijeve potključne vene dodiruje gornji rub lijevogva prvog rebra (**slika 9, 10, 11 i 12**).

Bolesnik je otpušten četvrtog dana nakon intervencije uz peroralnu antikoagulatnu terapiju rivaroksabanom. Molekularnom je analizom trombofilnih faktora ustanovljen normalan tip gena za faktor V Leiden te protrombin (II). Vrijednost antitrombina III bila je uredna, kao i proteina S, lupusni antikoagulant nije dokazan, dok je vrijednost proteina C bila blago snižena (0,61).

Na kontrolnom pregledu bolesnik je subjektivno boljšeg općeg stanja, redovito uzima preporučenu terapiju te je smanjio intezitet vježbi lijeve ruke. U kliničkome statusu dominira

observed on the second day after the intervention. Venography was performed (through the right cubital vein due to the still pronounced swelling of the left arm), which verified normal dimensions of the veins of the left arm, with partial thrombotic obstruction. Venous ultrasound of the arm was performed on the second day after the intervention, 14 days after the intervention, and four months after that. It found a residual thrombus in the subclavian vein, but with partial flow around the thrombus (**Figure 8**).

A thoracic surgeon was consulted regarding decompression treatment, who stated that surgical treatment was not indicated, but that anticoagulation treatment should be continued, along with magnetic resonance imaging of the neck and superior thoracic aperture. Imaging showed stenosis of the left subclavian vein in the area of the left costoclavicular space, with two tiny residual thrombi with a longer diameter of 6 mm. It was also clearly shown that the lower wall of the left subclavian vein was touching the upper edge of the left first rib (**Figures 9-12**).

The patient was discharged on the fourth day after the intervention, with peroral rivaroxaban anticoagulation therapy.

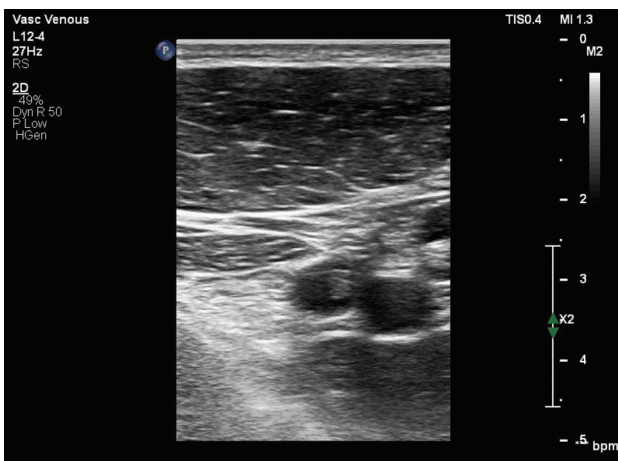


FIGURE 8. Venous ultrasound, residual thrombus.

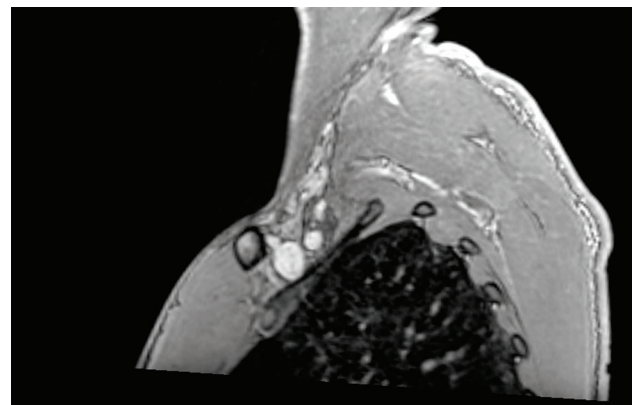


FIGURE 9. Magnetic resonance of the left side of the thoracic outlet: narrowing of the left subclavian vein with small residual thrombus.

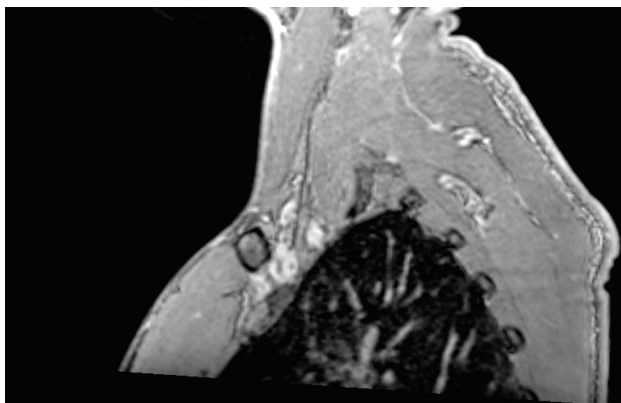


FIGURE 10. Magnetic resonance of the right side of the thoracic outlet: normal anatomical structures in the costoclavicular joint, no thrombosis.

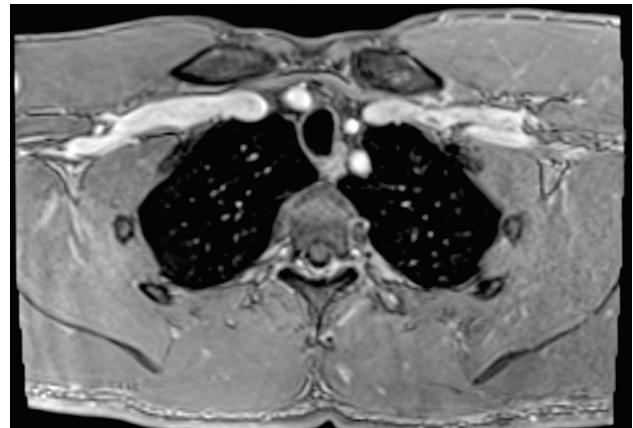


FIGURE 11. Magnetic resonance of the thoracic outlet: small thrombus in the left subclavian vein.



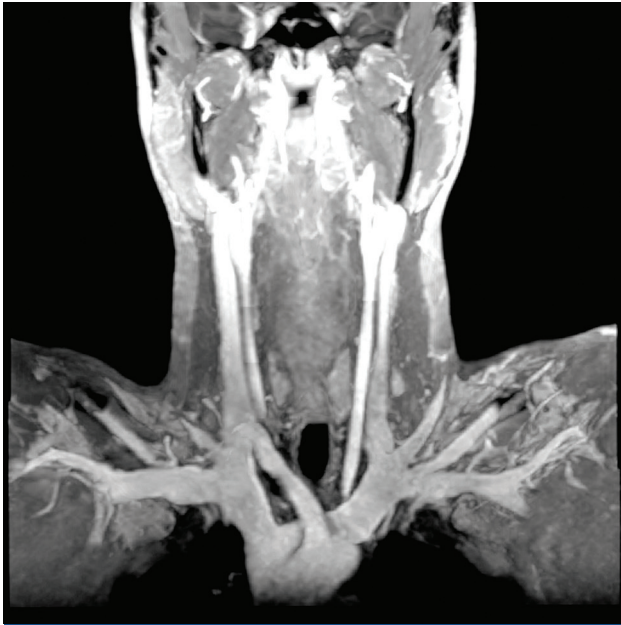


FIGURE 12. First rib touching the left subclavian vein.

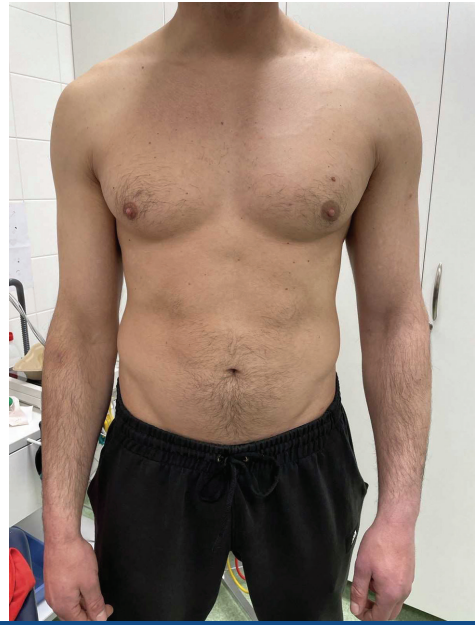

FIGURE 13. Patient on check-up – Urschel's sign.

razvoj venskih kolateralna na stijenci prsnog koša lijevo (tzv. Urschelov znak) (**slika 13**). Bolesnik navodi da nakon dulje vježbe i dalje primjećuje plavičastu obojenost kože ruke te blagu oteklinu. Bolesnikov slučaj bit će ponovno razmatran za konačno liječenje PSS-a –dekompresijom gornjega torakalnog otvora resekcijom prvog rebra.

## Rasprava

Iako se PSS relativno rijetko pojavljuje u općoj populaciji, ta je bolest važan klinički entitet te da ga je potrebno na vrijeme prepoznati i adekvatno liječiti. Naime, pojavljuje se u mladih, radno aktivnih ljudi, često se previdi i kasno dijagnosticira, što povećava vjerojatnost razvoja komplikacija i trajnih smetnji. U određenom postotku (7 – 20 %) uz DVT gornjih ekstremiteta nađe se i plućna tromboembolija<sup>5</sup>. Prema smjernicama, strategija uklanjanja tromba ima smisla u prva dva tjedna od početka simptoma jer kasnije dolazi do organizacije tromba i razvoja kolateralna<sup>1</sup>. Drugo, potrebno ga je razlikovati od sekundarne duboke venske tromboze gornjih ekstremiteta te uvijek voditi brigu o tome da idiopatske tromboze mogu biti prvi znak zloćudne bolesti. Nadalje, ovaj je bolesnik uzimao preparate testosterona čija je (zlo)upotreba u porastu. Postoje radovi koji su jasno utvrdili povezanost između njihove primjene i učestalosti duboke venske tromboze<sup>7</sup>.

Sljedeće jest pitanje trajanja primjene antikoagulantne terapije. Minimalna terapija traje tri mjeseca. Potrebno je dobro razmotriti vjerojatnost recidiva i pridružena stanja i bolesti i, prema tome, odabrati najbolji modalitet i duljinu primjene antikoagulantne terapije.

U bolesnika smo obavili i testiranje na nasljedne trombofilije, međutim, pri prvoj pojavi DVT-a (s prisutnim provocirajućim čimbenikom ili bez njega) ne preporučuje se rutinski probir na njih<sup>1</sup>.

Molecular analysis of thrombophilic factors showed a normal gene type for factor V Leiden and prothrombin (II). The value of antithrombin III was normal, as was protein S, and lupus anticoagulant was not found, whereas the value of protein C was mildly lowered (0.61).

On follow-up, the patient reported subjective improvement, regularly taking the recommend therapy, and reducing exercise intensity for the left arm. Clinical status was dominated by the development of superficial venous collaterals on the left side of the chest (i.e., Urschel's sign) (**Figure 13**). The patient stated that he still observed a bluish tinge on the skin of the arm and mild swelling after longer exercise sessions. The patient's case will be reviewed for treatment for PSS – decompression of the upper thoracic aperture by resection of the first rib.

## Discussion

Although PSS is relatively rare in the general population, the disease is an important clinical entity which must be occasionally recognized and treated adequately. It presents in the younger, professionally active population and is thus often overlooked or diagnosed late, which increases the likelihood of complications and permanent damage. In a certain percentage of cases (7-20%), DVT of the upper extremities is concomitant with pulmonary thromboembolism<sup>5</sup>. According to current guidelines, treatment strategy that includes thrombus removal is only viable during the first two weeks from symptom onset, since thrombus organization takes place after that period, along with the development of collaterals<sup>1</sup>. Secondly, PSS should be differentiated from secondary deep vein thrombosis of the upper extremities, always bearing in mind that idiopathic thromboses can be the first sign of malignant disease. Furthermore, the patient described herein

Iako većina bolesnika ima regresiju tegoba nakon liječenja antikoagulatnom terapijom ovaj je bolesnik zahtijevao intervencijsko liječenje. Sistemska se tromboliza zbog mogućih komplikacija ne preporučuje, ali postoje razni modaliteti intervencijskog liječenja (kateterom vođena tromboliza, farmakomehanička tromboliza), te kao u ovom slučaju perkutana aspiracijska trombektomija.

Konačno je liječenje PSS-a kirurško – dekompresija prostora resekcijom prvog rebra (postoji više pristupa; transaksilarni, supraklavikularni, intraklavikularni)<sup>8</sup>. Treba imati na umu da kirurško liječenje nije lišeno mogućih komplikacija (hematopneumotoraks, oštećenje struktura u torakalnom prostoru ili drugdje).

Zaključno, riječ je o kompleksnom sindromu koji zahtijeva rano prepoznavanje te multidisciplinarni pristup, a mogućnosti su liječenja široke.

was taking testosterone supplements, the (ab)use of which is a growing issue. A number of studies have clearly demonstrated the association between their application and the incidence of deep vein thrombosis<sup>7</sup>.

The next question at issue is the duration of the application of anticoagulation therapy. Minimal therapy lasts for three months. It is important to carefully consider the likelihood of recidivism as well as the concomitant states and diseases, and consequently decide on the best treatment modality and duration of anticoagulation therapy.

In our patient, we also performed tests for hereditary thrombophilia, but routine screening for it is not recommended on the first manifestation of DVT (with or without the presence of provoking factors)<sup>1</sup>.

Although most patients experience regression of symptoms after treatment with anticoagulation therapy, the present patient demanded interventional treatment. Systemic thrombolysis is not recommended due to possible complications, but there are various treatment modalities for interventional treatment (catheter-directed thrombolysis, pharmacomechanic thrombolysis), including percutaneous aspiration thrombectomy, as applied in the present case.

The ultimate treatment for PSS is surgery – decompression by resection of the first rib (with several possible approaches; transaxillary, supraclavian, intraclavian)<sup>8</sup>. Treatment choice should consider the fact that surgical treatment is not free of possible complications (hemopneumothorax, structural damage in the thoracic area and elsewhere).

In conclusion, PSS is a complex syndrome that requires early diagnosis and a multidisciplinary approach, with a variety of available treatment options.

## LITERATURE

1. Kakkos SK, Gohel M, Baekgaard N, Bauersachs R, Bellmunt-Montoya S, Black SA, et al. Editor's Choice - European Society for Vascular Surgery (ESVS) 2021 Clinical Practice Guidelines on the Management of Venous Thrombosis. *Eur J Vasc Endovasc Surg.* 2021 Jan;61(1):9-82. <https://doi.org/10.1016/j.ejvs.2020.09.023>
2. Jalota Sahota R, Lotfollahzadeh S, Soos MP. Subclavian Vein Thrombosis. [Updated 2023 Feb 24]. In: StatPearls [Internet]. Treasure Island (FL): StatPearls Publishing; 2023 Jan-. Available from: <https://www.ncbi.nlm.nih.gov/books/NBK559269/>.
3. Fazlić N. Paget-Schroetter sindrom U sportaša [Internet]. URN. Sveučilište u Zagrebu. Kineziološki fakultet.; 2021 [cited 2023 Mar22]. Available from: <https://urn.nsk.hr/urn:nbn:hr:117:642723>
4. Jacob V, Daley J, Coughlin RF. The diagnosis and management of Paget-Schroetter syndrome (primary effort thrombosis) in the emergency department. A case report. *Medicine Case Reports and Study Protocols* 2(6):p e0106, June 2021. <https://doi.org/10.1097/MD9.000000000000106>
5. Pekić P, Bekić D, Marić N, Mačković M. [Vascular Vibration Injury and Paget-Schroetter Syndrome]. *Acta Med Croatica.* 2016 Apr;70(2):143-6. Croatian. PubMed: <https://pubmed.ncbi.nlm.nih.gov/28722844/>
6. Ishizuka K, Katayama K, Kaji Y, Tawara J, Ohira Y. Paget-Schroetter syndrome. *QJM.* 2022 Jan 21;115(1):54-55. <https://doi.org/10.1093/qjmed/hcab293>
7. Walker RF, Zakai NA, MacLehose RF, Cowan LT, Adam TJ, Alonso A, Lutsey PL. Association of Testosterone Therapy With Risk of Venous Thromboembolism Among Men With and Without Hypogonadism. *JAMA Intern Med.* 2020 Feb 1;180(2):190-197. <https://doi.org/10.1001/jamainternmed.2019.5135>
8. Suzuki T, Kimura H, Matsumura N, Iwamoto T. Surgical Approaches for thoracic outlet syndrome: A review of the literature. *Journal of Hand Surgery Global Online.* 2022. <https://doi.org/10.1016/j.jhsg.2022.04.007>