

Ultrasound-guided central venous cannulation in patient with radical dissection on both sides of neck: case report

Šustić, Alan; Cerović, Robert; Juretić, Mirna

Source / Izvornik: **Radiology and Oncology, 2001, 35, 175 - 157**

Journal article, Published version

Rad u časopisu, Objavljena verzija rada (izdavačev PDF)

Permanent link / Trajna poveznica: <https://urn.nsk.hr/urn:nbn:hr:184:284344>

Rights / Prava: [Attribution 4.0 International](#)/[Imenovanje 4.0 međunarodna](#)

Download date / Datum preuzimanja: **2024-07-08**



Repository / Repozitorij:

[Repository of the University of Rijeka, Faculty of Medicine - FMRI Repository](#)



Case report

Ultrasound-guided central venous cannulation in patient with radical dissection on both sides of neck: case report

Alan Šustić¹, Robert Cerović², Mirna Juretić²

¹Department of Anesthesiology and ICU, ²Department of Maxillo-facial surgery, University Hospital Rijeka, Croatia

Background. Difficult and complicated surgical procedures in elective oncologic patients often require central venous (CV) catheterization. In certain number of cases, relevant anatomical changes, caused by basic disease, impede, or even prevent the use of standard "blind" CV cannulation. In such cases ultrasonography can be used successfully as an adjunctive method during the CV cannulation.

Case report. We present the patient with a radical dissection on both sides of neck and consequent important anatomical changes; the ultrasound-guided CV cannulation is successfully performed in this patient.

Conclusions. Ultrasound as a supporting method for CV catheterization in oncological patients has potential benefits. Sonography as an important adjunct method in central venous cannulation is recommended in difficult cases.

Key words: sonography; catheterization, central venous

Introduction

Difficult and complicated surgical procedures in elective patients require the central venous (CV) cannulation for monitoring and for par-enteral alimentation in the intraoperative and postoperative period. In certain number of cases relevant anatomical changes, caused by basic disease, impede, or even prevent the

use of the standard CV cannulation. In such cases ultrasonography can be used successfully as an adjunctive method during the CV cannulation.¹⁻³ We present the patient with a radical dissection on both sides of the neck and consequent important anatomical changes; the ultrasound guided CV cannulation is successfully performed in this patient.

Case report

In a 37 years old male patient, planocellular carcinoma of tongue was diagnosed six months before the present hospitalization. At that time the radical dissection on the right side of the neck was performed, as well as the

Received 14 July 2001

Accepted 31 July 2001

Correspondence to: Alan Šustić, M.D., Ph.D., Department of Anesthesiology and ICU, Clinical Hospital Rijeka, T. Stržića 3, Rijeka 51 000, Croatia. Phone: + 385 51 21 84 07; Fax: + 385 51 21 84 07; E-mail: Alan.Sustic@mamed.medri.hr

suprahyoid dissection on the left side, with the extirpation of a tumor and the resection of mandible. The plastic operation of the defect was done with a free skin-bone flap taken from the left leg. Now the patient was hospitalized due to multiple palpable lymph nodes on the left side of the neck.

The preoperative computerized tomography (CT) and the ultrasonography (US) detected multiple metastatic deposits on the left side of the neck with a complete obliteration and destruction of the left internal jugular vein in the middle part of the neck, and the displacement of the left carotid artery caused by metastatic processes. A somewhat smaller secondary deposit was found immediately above and beside the entrance of jugular vein into the subclavian vein.

By the above-mentioned technique an important segment of the right-sided subclavian artery and vein, displaced upwards craniodorsally, can be visualized.

As with subsequent diagnostic methods no other metastatic deposits were found, the radical dissection of the left side of the neck was indicated. The preanaesthetic examination informed us of the patient's relatively good state of health, with normal laboratory findings, ASA III. Because of the magnitude of surgical intervention and the necessity of the perioperative and the postoperative monitoring, as well as parenteral nutrition, the central venous catheterization was indicated. Because of important anatomical and pathoanatomical changes, the preoperative right-sided subclavial catheter, under sonographic monitoring, was decided upon. Ultrasonic apparatus Hitachi 405 EUB, with linear transducer (5 MHz) was used sterilized as recommended by the manufacturer. Immediately before the cannulation by supraclavial approach, the displaced subclavial vein was visualized with a few transverse and vertical scans. Finding the best vertical section through the vein, we located the direction, as well as the route of a puncture needle,

and so we could begin the cannulation with two lumens CV catheter (16 Gauge, Arrow Inc.) with the introducer obeying the rules of a Seldinger technique. Without displacing the transducer we monitored the whole procedure and after the completed cannulation, again visualized the vein with CV catheter in it, by a few transversal and vertical scans (Figure 1).

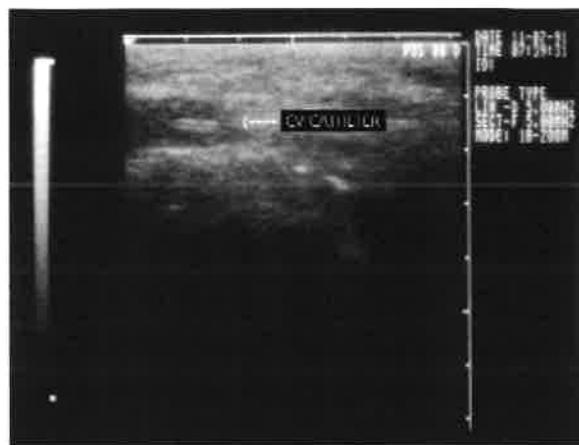


Figure 1. Ultrasonographic transversal presentation of v. subclavia (linear transducer; 5 MHz). Double echo in vein presents central venous catheter.

With the convex transducer (5 MHz) via suprajugular access, we visualized vena anonyma (Figure 2) and with the convex transducer (3 MHz) by a standard echocar-

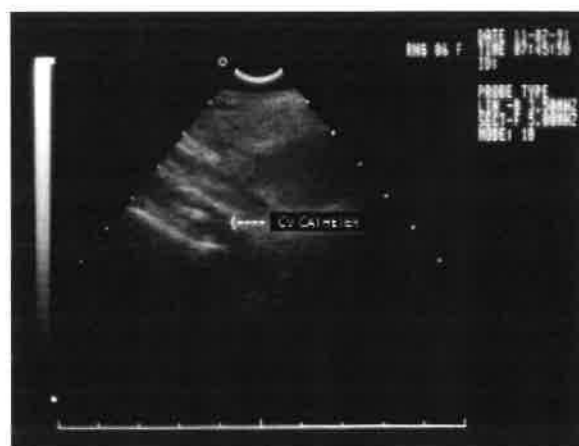

Figure 2. Ultrasonographic transversal presentation of v. anonyma (convex transducer; 5 MHz). Double echo in vein presents central venous catheter.

diographic approach, right heart, respectively. Subsequently, through a catheter, a bolus of 10 ml 0,9% NaCl was applicated; presented us with so-called "hand-made ultrasonic contrast" in the right atrium and we confirmed the right position of a central venous catheter.

Once the position of a catheter was determined, the affixation followed, without the need of radiologic control.

Discussion

The central venous catheterization in our patient was imperative because it permitted the intra- and postoperative monitoring of CVP, as well as the parenteral nutrition with highly caloric parenteral infusions and high-osmolality drugs. Blood samples for laboratory analysis could be taken from CV catheter as well.

Although brachial veins were in consideration for catheterization, due to the expected long-term need for the CV catheterization as well as potential thrombosis of the brachial or femoral vein, we decided for a standard subclavial route. In this very high-risk patient for "blind" (anatomically guided) cannulation we performed the CV cannulation by using the ultrasound guidance. With the ultrasound-guided technique an anesthesiologist (operator) can be oriented in anatomic relationships immediately before the cannulation.¹⁻⁴ He is able to monitor the position of the needle, guide-wire and catheter in the central vein during the procedure as well. By the described technique, the whole catheter, its loops or eventual knots, as well as the tip, can be visualized and there is no need for the postoperative confirmation by radiography. Besides, a real-time ultrasound guidance technique, which is cheap, quick and easy to perform, improves the success rate, reduces the number of passes and gives us the possibility of the early detection of some later complica-

tions in the CV cannulation (e.g. arterio-venous fistulas or pseudo-aneurysms).^{2,5}

This report highlights the potential benefits of ultrasound as a supporting method for the CV catheterization in oncological patients. Summing the personal experience and the data from relevant literature, we can recommend sonography as an important adjunct method in central venous cannulation in difficult cases.¹⁻⁴

References

1. Slama M, Novara A, Savafin A, Ossart M, Safar M, Fagon J.Y. Improvement of internal jugular vein cannulation using an ultrasound-guided technique. *Intensive Care Med* 1997; **23**: 916-9.
2. Hatfield A, Bodenham A. Portable ultrasound for difficult central venous access. *Br J Anaesth* 1999; **82**: 822-6.
3. Skonick ML. The role of sonography in the placement and management of jugular and subclavian central venous catheters. *AJR* 1994; **163**: 291-5.
4. Benter T, Teichgraber UK, Kluhs L, Papadopoulos S, Kohne CH, Felix R, et al. Anatomical variations in the internal jugular veins of cancer patients affecting central venous access. Anatomical variation of the internal jugular vein. *Ultraschall Med* 2001; **22**: 23-6.
5. Šustić A, Stančić M, Eškinja N, Matana A, Fučkar Ž. Iatrogenic pseudo-aneurysm of the axillary artery: the role of color Doppler sonography. *J Clin Ultrasound* 1996; **24**: 323-5.