

Expression of Bone Morphogenetic Proteins, Cartilage-Derived Morphogenetic Proteins and Related Receptors in Normal and Osteoarthritic Human Articular Cartilage

Bobinac, Dragica; Španjol, Josip; Marinović, Marin; Zoričić Cvek, Sanja; Marić, Ivana; Cicvarić, Tedi; Fučkar, Dora; Markić, Dean; Vojniković, Božidar

Source / Izvornik: **Collegium antropologicum, 2008, 32 - Supplement 2, 83 - 87**

Journal article, Published version

Rad u časopisu, Objavljena verzija rada (izdavačev PDF)

Permanent link / Trajna poveznica: <https://um.nsk.hr/um:nbn:hr:184:110558>

Rights / Prava: [Attribution 4.0 International](#)/[Imenovanje 4.0 međunarodna](#)

Download date / Datum preuzimanja: **2024-12-23**



Repository / Repozitorij:

[Repository of the University of Rijeka, Faculty of Medicine - FMRI Repository](#)



Expression of Bone Morphogenetic Proteins, Cartilage-Derived Morphogenetic Proteins and Related Receptors in Normal and Osteoarthritic Human Articular Cartilage

Dragica Bobinac¹, Josip Španjol², Marin Marinović³, Sanja Zoričić Cvek¹, Ivana Marić¹, Tedi Cicvarić³, Dora Fučkar⁴, Dean Markić² and Božidar Vojniković⁵

¹ Department of Anatomy, School of Medicine, University of Rijeka, Rijeka, Croatia

² Clinic of Urology, University Hospital of Rijeka, Rijeka, Croatia

³ Clinic of Surgery, University Hospital of Rijeka, Rijeka, Croatia

⁴ Department of Pathology, School of Medicine, University of Rijeka, Rijeka, Croatia

⁵ Eye Polyclinic »Dr. Vojniković«, Rijeka, Croatia

ABSTRACT

Newborn and adult articular cartilage expresses bone (BMPs) and cartilage derived morphogenetic proteins (CDMPs). These morphogenetic proteins act over membrane receptors (BMPRs). We examined the expression pattern of BMP-7, BMP-3, CDMP-1, CDMP-2 and their receptors in adult normal and osteoarthritic, articular, knee cartilage. Immunostaining was carried out using polyclonal antibodies. The expression of BMP-7,-3, CDMP-1,-2 was detected in all layers of normal articular cartilage with the strongest expression in chondrocytes of the transitional layer. BMP-7 and CDMPs expression decreased in osteoarthritic articular cartilage whereas BMP-3 expression was absent. BMPR-IA and BMPR-II were strongly expressed in both normal and osteoarthritic articular cartilage. BMPR-IB was not expressed in osteoarthritic (OA) cartilage. BMPs and CDMPs with intact signalling play an important role in articular cartilage homeostasis, preventing cartilage degeneration.

Key words: articular cartilage, bone morphogenetic proteins, cartilage derived morphogenetic proteins, osteoarthritis

Introduction

Bone morphogenetic proteins (BMPs) are a group of proteins found in demineralised bone matrix. They have the capacity to induce bone formation at ectopic sites^{1,2}. BMPs are members of the transforming growth factor- β (TGF- β) superfamily. More than a dozen members of the BMP family have been identified until today¹. The evidence that BMPs can induce endochondral bone formation in adult animals suggests that some BMPs are produced by chondrocytes³. Two novel members of the TGF- β superfamily were identified and named cartilage-derived morphogenetic protein-1 (CDMP-1) and -2 (CDMP-2)³. Despite their close homology with BMPs, CDMPs -1 and -2 are two distinct growth factors with apparently different biologic roles. These CDMPs are pre-

ferentially expressed in cartilaginous tissues and are involved in the long bones development but were not detectable in the axial skeleton during human embryonic development³. Further research has shown that CDMPs are detected in human healthy and osteoarthritic articular cartilage what has implicated their possible role in homeostasis of articular cartilage^{4,5}. The stimulation of proteoglycan synthesis may be a clue for maintenance and repair of articular cartilage. *In vitro* studies revealed that CDMPs and certain BMPs increase proteoglycan synthesis in cultured articular chondrocytes. It has been shown that synthesis of proteoglycans is increased by bone morphogenetic proteins -3, -4, -6 and -7⁶⁻¹². Chubinskaya et al. have demonstrated that BMP-7 is pro-

duced by human articular chondrocytes and has strong anabolic activity *in vivo*¹³. Additionally, BMP-3 inhibits the effects of osteogenic BMPs what provokes speculation that BMP-3 might be a modulator of the activity of osteogenic BMPs *in vivo*¹⁴.

Proteoglycans represent a major component of extracellular matrix of articular cartilage and are responsible for the resistance of such cartilage to compressive forces^{15,16}. The loss of proteoglycans is a sign of degenerative changes in osteoarthritis. Osteoarthritis (OA) is characterized by progressive loss of articular cartilage and remodelling and sclerosis of subchondral bone^{17–23}. The loss of cartilaginous matrix in OA might be the result of defective mechanisms for its repair.

BMPs and CDMPs bind and initiate a cellular signaling cascade via a complex of trans-membrane serine/threonine kinase receptors, termed type II and type I receptors^{24,25}. Type II receptors are constitutively active kinases, which transphosphorylate type I receptors. Type I receptors then activate intracellular substrates such as Smad proteins and thus determine the specificity of the intracellular signals²⁶. BMP-7 transduces the signal through BMP type II receptors and BMP type IA (BMPR-IA) and BMP type IB receptors (BMPR-IB)²⁷. CDMP-1 also binds to both BMPR-IA and IB²⁸. Since, CDMPs and BMPs may have a role as humoral regulatory mechanism in homeostasis of cartilaginous matrix, we investigated the expression pattern of CDMP-1, CDMP-2, BMP-7, BMP-3 and related receptors in healthy and OA articular cartilage.

Material and Methods

Tissue acquisition

Full thickness articular cartilage was dissected from load bearing regions of tibial plateaus. The tissue samples were taken post-mortem within 24 hours from female and male subjects whose age varied from 32 to 75 years. The research was done under the institutional approval of local ethic committee. We selected the subjects with no history of any joint disease and with normal morphology of the surface of articular cartilage determined by macroscopical examination. End-stage osteoarthritic articular cartilage (OA cartilage) was obtained from patients undergoing total knee joint replacement due to advanced OA. The age of patients varied from 55 to 76 years, both men and women. Informed written consent and approval was obtained.

Tissue preparation

Tissue samples were rinsed in saline, fixed in 4% paraformaldehyde and embedded in paraffin. Cartilage sample was cut longitudinally. The thickness of serial sections was 5 μ m.

Immunohistochemistry

For immunohistochemistry, tissue slices were collected on glass slides coated with 3-aminopropyltriethoxy

silane (APES, Sigma, St. Louis, MO, USA), air-dried, and stored at 4 °C until processing for indirect immunoperoxidase staining. Before incubation with primary antibodies, tissue sections were digested with hyaluronidase (H-2251, Sigma) to increase the penetration of antibodies into cartilage. Briefly, tissue slices were deparaffinised in xylene and rehydrated in ethanol. Endogenous peroxidase and non-specific binding were blocked by incubation in 0.3% H₂O₂ in methanol and 10% non-immune serum. The sections were incubated with primary antibody for 60 minutes at room temperature. Anti-BMP-3, -7, anti CDMP-1,-2, anti-BMPR-IA, -IB and -II were goat polyclonal antibodies purchased from Santa Cruz Biotechnology (Santa Cruz, CA, USA). After the incubation with a primary antibody, secondary biotinylated antibody was applied according to the manufacturer's protocol (DAKO, LSAB@+ Kit Peroxidase, Carpinteria, CA, USA). Peroxidase conjugated streptavidin was added and the site of antigen binding was visualized using AEC + Substrate Chromogen (DakoCytomation). Sections were counterstained with haematoxylin. Slides used as a control were processed either with PBS buffer or the secondary antibody alone.

Results

Normal adult articular cartilage

The surface of articular cartilage of younger people was macroscopically regular and without any evidence of damage or degenerative changes. Histological analysis showed typically stratified tissue with superficial, transitional and radial layers, and with characteristic cell morphology and distribution. The articular cartilage obtained from elderly people (60 to 75 years) had also quiet regular surface under eye inspection. But histological analysis showed some degenerative alterations. We found initial degree of surface fibrillation and chondrocyte clusters in the transitional layer. In adult articular cartilage it was found the expression of BMP-3, -7 and CDMP-1, -2. BMP-7 and BMP-3 expression was found in extracellular matrix of the superficial layer. Both bone morphogenetic proteins were expressed by chondrocytes mostly of the transitional layer and in lesser extent of the deep radial layer. The expression of CDMP-1 was found in chondrocytes of all three cartilage layers and in related pericellular matrix (Figure 1). Chondrocyte clusters present degenerative alteration of articular cartilage that corresponds to the ageing process and demonstrated stronger expression of BMP-7 in relation to surrounded chondrocytes. CDMP-2 expression showed very similar pattern of distribution but with lesser extent of expression. Except cell reactions CDMP-1 and CDMP 2 were positive in thin rim of chondrocytic lacunae. Both BMPR-IA and BMPR-II were highly expressed by chondrocytes in all cartilage layers, with the strongest expression in the cells of transitional layer. The immunostaining for BMPR-IB was low intensive and was found in some cells in all three layers of the cartilage.

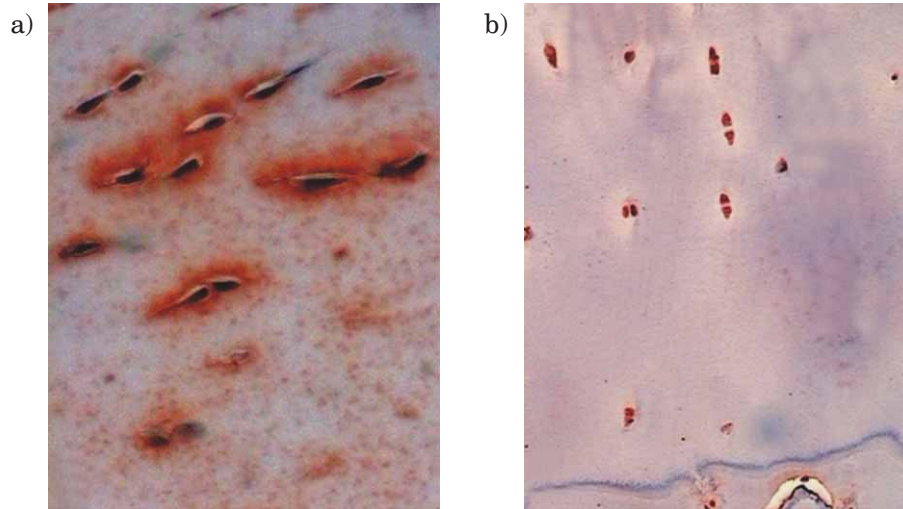


Fig. 1. CDMP-1 positive chondrocytes in superficial (a) and deep-radial layer (b) of normal, adult, knee, articular cartilage.

Osteoarthritic cartilage

Generally, the cartilage tissue was hypocellular and chondrocytes were dominantly organized in chondrocytes clusters throughout the whole section of end-stage osteoarthritic articular cartilage. We found the expression of BMP-7, CDMP-1 and CDMP-2 while BMP-3 expression was not present. The overall level of BMP-7, CDMP-1 and CDMP-2 staining in OA cartilage appeared to be less intensive than in normal adult cartilage. In osteoarthritic cartilage BMP-7 was expressed by chondrocytes in cell clusters that were presented throughout whole residual cartilage. The pericellular matrix was positive, too (Figure 2). Unlike the normal articular cartilage BMP-7 expression was found in deep-layer chondrocytes. CDMP-1 and CDMP-2 were expressed by chondrocytes clusters and lacuna walls in all cartilage layers. Concerning the expression of membrane receptors, we

found the expression of BMPR-IA and BMPR-II while BMPR-IB was not expressed. The level of expression for BMPR-IA and BMPR-II was not changed after osteoarthritis.

Discussion and Conclusion

By immunohistochemistry we have demonstrated the expression of BMP-3,-7, CDMP-1,-2 and their respective receptors in the human normal adult articular cartilage. The expression of BMP-7, and CDMP-1,-2 was decreased whereas BMP-3 expression was not detected in osteoarthritic articular cartilage. BMPR-IA and BMPR II were strongly expressed in both normal and osteoarthritic articular cartilage. BMPR-IB was not expressed in OA cartilage.

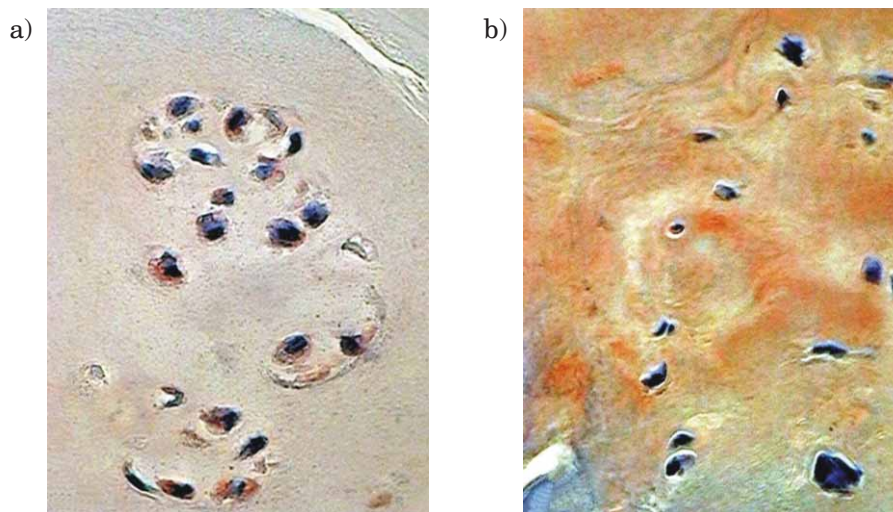


Fig. 2. BMP-7 positive chondrocytes in cell clusters (a) and BMP-7 positive pericellular matrix (b) of osteoarthritic, adult, knee, articular cartilage.

CDMP-1 and CDMP-2 are predominantly expressed in cartilaginous tissues both pre- and postnatally. Such tissue specificity suggests their intimate involvement in skeletal development and growth. CDMPs are preferentially expressed in the cartilaginous cores of long bones during early human limb development^{3,31}. In areas of active cartilage degradation and bone matrix formation, CDMP-1 expression was detected in hypertrophic chondrocytes³. Then, CDMP-1 was detected in areas of future joint spaces during embryonic development, implicating a role in the formation of the articular joint cavity⁴. Postnatally CDMPs were detected in newborn articular cartilage what suggests their possible role in growth and maintenance of cartilaginous tissue³. Erlacher et al. have demonstrated that CDMPs are not only present in early postnatal life but also in adult bovine and human healthy and OA articular cartilage^{4,5}. In healthy articular cartilage it was found discrete staining for CDMP-1 and CDMP-2 predominantly in the upper one-third layer of the cartilage sections with only few cells in the deeper layers. The staining pattern for CDMP-1 and CDMP-2 was overlapped as they have reported. More pronounced staining for both CDMPs they have found in OA cartilage i.e. in cell clusters and weak staining in the matrix. Chen et al. have found that CDMP-1 was expressed in similar manner in both fetal and adult (normal or osteoarthritic) cartilage. We have found the expression of both CDMPs in chondrocytes of all three layers in normal adult articular cartilage. These results confirmed that these morphogenetic proteins are important regulatory mechanism for cartilage homeostasis. The expression for both CDMPs decreased in OA cartilage.

BMP-7 is growth factor with strong osteoinductive activity. Furthermore, it was the first bone morphogenetic protein detected in normal and OA articular cartilage and expressed by chondrocytes¹⁴. Besides that, BMP-7 is able to induce the synthesis of extracellular matrix components of articular cartilage and newly synthesized proteoglycan in response to BMP-7 appears to be normal, functional proteoglycans^{12,29}. In normal adult cartilage BMP-7 expression was found predominantly in the cells and the surrounding pericellular matrix in the superficial and upper middle layers of the tissue¹¹. We have also found the expression of BMP-7 in the chondrocytes and pericellular matrix of the tangential and in chondrocytes of the transitional layers. On the contrary, Chen et al. have found that BMP-7 was consistently expressed in fetal but not in adult cartilage²⁹. With increasing age, Chubinskaya et al. has found that the content of endogenous BMP-7 protein significantly declined²⁹. Furthermore, with the progression of cartilage degeneration BMP-7 protein was down-regulated, too³¹. Thus, Merihew et al. have suggested that BMP-7 is responsible only for normal homeostasis and matrix integrity in cartilage.

Our results about OA cartilage have shown that BMP-7 was expressed by chondrocytes of cell clusters in all layers of residual cartilage with the staining of extracellular matrix. Deep-layer chondrocytes showed BMP-7 expression, too. Our results are in correlation with the data presented in the literature that revealed how with progression of cartilage degeneration process, what is hallmark of OA, the expression of BMP-7 is extended to the deeper layers of articular cartilage¹¹. On the other hand, Chen et al. have found no expression of BMP-7 mRNA in adult cartilage both normal and osteoarthritic. Anyway, in vitro investigation about the influence of BMP-7 treatment on chondrocytes Nishida et al. have reported enhanced accumulation of hyaluronan and proteoglycan within cartilage tissue³². So BMP-7 besides its osteoinductive activity induces proteoglycan synthesis in articular cartilage and acts as a factor responsible for normal homeostasis and cartilage matrix integrity.

We have detected BMP-3 expression in adult normal but not in osteoarthritic articular cartilage. This is in correlation with Chen who found that BMP-3 mRNA was expressed in fetal and normal adult but not in osteoarthritic articular cartilage.

BMP-3 is a major component of osteogenin, which has osteogenic activity while BMP-3 itself has no apparent osteogenic function. Moreover, BMP-3 is an inhibitor of osteogenic BMPs and may therefore play an essential role as a modulator of the activity of osteogenic BMPs *in vivo*. So, we assume that BMP-3 can prevent inappropriate BMP activity *in vivo*. Furthermore, our results may suggest that BMP-3 is like additional mechanism for normal cartilage protection and possible correction of BMP-7 osteogenic activity.

Bobacz et al. have found mRNA coding for CDMPs and their respective receptors in healthy and in OA cartilage³⁰. In normal articular cartilage three receptors for BMPs and CDMPs binding were detected³³. Muehleman et al. found very low expression of BMPR-IA and BMPR-II in the superficial layer and moderately expression in the middle and deep layers. BMPR-IB was moderately expressed in the superficial layer and maximally in the middle and deep layers. Our results show maximum expression for BMPR-IA and BMPR-II in the middle layer and moderately expression in the superficial and deep layers. BMPR-IB expression was very low in all three layers of normal cartilage. The expression of BMPR-IB we did not find in OA. In the contrary, the expression of BMPR-IA and BMPR-II was more pronounced in OA. These results are in correlation with Chen et al.³³. Whereas CDMPs and BMP-7 bind more efficiently to receptor IB, the loss of BMPR-IB receptor in OA may change the function of BMP-7 and CDMPs as growth factors in OA cartilage.

REFERENCES

1. ŠPANJOL J, MARIČIĆ A, CICVARIĆ T, VALENČIĆ M, OGUIĆ R, TADIN T, FUČKAR D, BOBINAC M, Coll Antropol, 31 (2007) 315. – 2. ALIBHAI SMH, RAHMAN S, WARDE PR, JEWETT MAS, JAFFER T, CHEUNG AM, Urology, 68 (2006) 126. – 3. SHAHINIAN VB, KUO YF, FREEMAN JL, Cancer, 103 (2005) 1615. – 4. RYAN CW, HUO D, STALLINGS JW, DAVIS R, BEER TM, McWHORTER LT, Urology, 70 (2007) 122. – 5. MITTAN D, LEE S, MILLER E, J Clin Endocrinol Metab, 87 (2002) 3656. – 6. GRUNTMANIS U, Am Med Sci, 333 (2007) 85. – 7. BAE DC, STEIN BS, J Urol, 172 (2004) 2137. – 8. ZHANG Y, KIEL DP, ELLISON RC, SCHATZKIN A, DORGAN JF, KREGER BE, CUPPLES LA, FELSON DT, Am J Med, 113 (2002) 734. – 9. ORWOLL ES, Calcif Tissue Int, 75 (2004) 114. – 10. GREENSPAN S, J Clin Endocrinol Metab, 93 (2008) 2. – 11. DAVIE MW, LAWSON DE, EMBERSON C, BARNES JL, ROBERTS GE, BARNES ND, Clin Sci, 63 (1982) 461. – 12. DOCIO S, RIANCHO JA, PEREZ A, OLMOS JM, AMADO JA, GONZALES-MACIAS J, J Bone Miner Res, 13 (1998) 544. – 13. PEHARDA V, GRUBER F, KAŠTELAN M, MASSARI PRPIĆ L, SAFTIĆ M, ČABRIJAN L, ZAMOLO G, Coll Antropol, 31 (2007) 87. – 14. KAŠTELAN D, KRALJEVIĆ I, KARDUM I, KASOVIĆ M, DUŠEK T, MAZALIN PROTULIPAC J, GILJEVIĆ Z, PERKOVIĆ Z, JELČIĆ J, AGANOVIĆ I, KORŠIĆ M, Coll Antropol, 31 (2007) 701. – 15. LUGOVIĆ L, ŠITUM M, OŽANIĆ-BULIĆ S, SJEROBABSKI-MASNEC I, Coll Antropol, 31 (2007) 63. – 16. VOJNIKOVIĆ B, NJIRIĆ S, ČOKLO M, TOTHI I, ŠPANJOL J, MARINOVIĆ M, Coll Antropol, 31 (2007) 61. – 17. VOJNIKOVIĆ B, NJIRIĆ S, ČOKLO M, ŠPANJOL J, Coll Antropol, 31 (2007) 43.

J. Španjol

*Clinic of Urology, University Hospital of Rijeka, T. Stržičica 3, 51000 Rijeka, Croatia
e-mail: jspanjol@vip.hr*

EKSPRESIJA KOŠTANIH I HRSKAVIČNIH MORFOGENETSKIH PROTEINA I NJIHOVIH RECEPTORA U NORMALNOJ I OSTEOARTRITIČNOJ LJUDSKOJ ZGLOBNOJ HRSKAVICI

SAŽETAK

Novorođenačka i odrasla zglobna hrskavica ekspirira koštane (BMP) i hrskavične (CDMP) morfogogenetske proteine. Spomenuti morfogogenetski proteini djeluju preko membranskih receptora (BMPR). U ovoj studiji proučili smo ekspresiju BMP-7, -3, CDMP-1 i -2 i njihovih receptora u odrasloj normalnoj i osteoartritičnoj hrskavici koljenog zgloba. Imunohistokemija učinjena je poliklonalnim antitijelima. Ekspresiju narečenih proteina uočili smo u svim slojevima normalne hrskavice, a najjaču u prijelaznom sloju. BMP-7 i CDMP ekspresija se smanjuje u osteoartritisu, dok BMP-3 nije uopće ekspimiran. BMPR-IA i BMPR-II su snažno ekspimirani u normalnoj i osteoartritičnoj zglobnoj hrskavici. BMPR-IB nije ekspimiran u osteoartritisu. Koštani i hrskavični morfogogenetski proteini s očuvanim signaliranjem imaju važnu ulogu u homeostazi zglobne hrskavice, sprječavajući degeneraciju.