

Ceftriaxone and Doxycycline induced Seroconversion in Previously Seronegative Patient with Clinically Suspected Disseminated Lyme Disease: Case Report

Blagojević Zagorac, Gordana; Grubić Kezele, Tanja

Source / Izvornik: **Infection & Chemotherapy, 2021, 53, 582 - 588**

Journal article, Published version

Rad u časopisu, Objavljena verzija rada (izdavačev PDF)

<https://doi.org/10.3947/ic.2021.0008>

Permanent link / Trajna poveznica: <https://um.nsk.hr/um:nbn:hr:184:079599>

Rights / Prava: [Attribution-NonCommercial-NoDerivatives 4.0 International/Imenovanje-Nekomercijalno-Bez prerada 4.0 međunarodna](#)

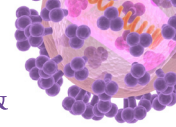
Download date / Datum preuzimanja: **2025-03-12**



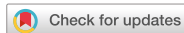Repository / Repozitorij:

[Repository of the University of Rijeka, Faculty of Medicine - FMRI Repository](#)





Case Report



Ceftriaxone and Doxycycline induced Seroconversion in Previously Seronegative Patient with Clinically Suspected Disseminated Lyme Disease: Case Report

Gordana Blagojević Zagorac ^{1,*} and Tanja Grubić Kezele ^{1,2,*}

¹Department of Physiology, Pathophysiology and Immunology, Faculty of Medicine, University of Rijeka, Rijeka, Croatia

²Clinical Department for Clinical Microbiology, Clinical Hospital Center Rijeka, Rijeka, Croatia



Received: Jan 19, 2021

Accepted: Mar 9, 2021

Corresponding Author:

Gordana Blagojević Zagorac, PhD, MD

Department of Physiology, Pathophysiology and Immunology, Faculty of Medicine, University of Rijeka, Braće Branchetta 20, 51 000 Rijeka, Croatia.

Tel: +385 51 651 186

E-mail: gordana.blagojevic@uniri.hr

*Authors contributed equally to this work.

Copyright © 2021 by The Korean Society of Infectious Diseases, Korean Society for Antimicrobial Therapy, and The Korean Society for AIDS

This is an Open Access article distributed under the terms of the Creative Commons Attribution Non-Commercial License (<https://creativecommons.org/licenses/by-nc/4.0/>) which permits unrestricted non-commercial use, distribution, and reproduction in any medium, provided the original work is properly cited.

ORCID iDs

Gordana Blagojević Zagorac

<https://orcid.org/0000-0003-1249-3802>

Tanja Grubić Kezele

<https://orcid.org/0000-0001-6769-5263>

Compliance with ethical standards

The patient signed a written consent form for the publishing purposes in the journal.

Conflict of Interest

No conflict of interest.

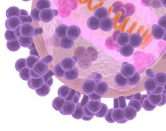
ABSTRACT

We present a case of middle-aged woman whose health problems began 3 months after a registered tick bite in endemic area of Lyme borreliosis. First symptoms included fatigue, chills, cervical lymphadenopathy, neck pain and stiffness. Patient was afebrile. Lyme disease was excluded due to lack of erythema migrans and negative enzyme immunoassay test results for anti-*Borrelia* antibodies. During the next few months, her condition was getting worse and symptoms were accompanied with brain fog, dizziness, palpitations, irregular menstrual cycles, insomnia, panic attacks, headaches, and muscle aches. This led to multiple medical tests and examinations, but the diagnosis failed to be established. Finally, after occurrence of paresthesia and weakness of leg muscles, clinical diagnosis of disseminated Lyme borreliosis with nervous system involvement was suspected and antibiotic therapy was initiated. After the second dose of ceftriaxone, patient got fever and her condition worsened. However, ceftriaxone therapy was continued for a total of 5 days and was followed by 4 weeks of doxycycline therapy. Upon completion of antibiotic therapy, high specific anti-*Borrelia* antibodies were detected by Western blot and SeraSpot. Appearance of anti-*Borrelia* antibodies, in contrast to negative test results performed immediately before the therapy started, indicated seroconversion. 18 months after the therapy, patient was completely without the symptoms. This paper emphasizes importance of clinical evaluation of Lyme disease and shows a unique case of seroconversion in patient with symptoms of disseminated Lyme disease. Seroconversion was likely triggered by release of lipoproteins and other immunogenic molecules from *Borrelia* once the bacterial die-off began due to antibiotic therapy.

Keywords: Ceftriaxone; Doxycycline; Jarisch-Herxheimer reaction; Lyme borreliosis; Seroconversion

INTRODUCTION

Lyme disease is caused by six species in the spirochete family *Borreliaceae* and humans get infected via a bite of infected ticks. Clinical manifestations of Lyme disease are generally divided into three stages. Sometimes is very difficult to make a strict line between the


Author Contributions

Conceptualization: GBZ, TGK. Data curation: GBZ, TGK. Formal analysis: GBZ, TGK. Funding acquisition: GBZ. Investigation: GBZ, TGK. Methodology: GBZ, TGK. Resources: GBZ. Supervision: GBZ. Validation: GBZ, TGK. Visualization: GBZ, TGK. Writing - original draft: GBZ, TGK. Writing - review & editing: GBZ. : Both authors contributed equally to the conception of the case report, to the interpretation of data, and to the writing of the manuscript. Both authors agreed with the content of the case report and have approved the submitted version.

stages and not all patients go through all three. Early localized stage is characterized by pathognomonic erythema migrans (EM) with or without influenza-like symptoms; early disseminated stage is characterized by multiple EM lesions and/or neurologic and/or cardiac symptoms; and late disseminated stage is associated with arthritis and/or neurologic problems [1, 2]. Diagnosis of Lyme disease is based on exposure history, clinical presentation and laboratory test results. In about 20 - 50% of patients that lack EM, clinical diagnosis is hard to make due to unspecific symptoms and in that case laboratory confirmation of infection by polymerase chain reaction (PCR), cultivation or determination of anti-*Borrelia* antibodies is required [3, 4]. Cultivation and PCR detection of *Borrelia* from blood samples have minor clinical value due to very low sensitivity and specificity, which vary around 20% and 40%, respectively. Therefore, serological assays are the main method used to diagnose extracutaneous Lyme disease [1, 2]. Serological assays have widely divergent sensitivity and specificity, depending on the manufacturer and the stage of the disease. Details about specificity and sensitivity of different enzyme immunoassays (EIAs) and WBs can be found in reference 4. Generally, EIAs are not high specific, but are sensitive serological tests. Sensitivity of EIAs varies from 35% in the early phase, up to 85% in the late phase of the disease [4]. Therefore, Center for Disease Control and Prevention (CDC) recommends laboratories to use a two-step serological testing algorithm, meaning that positive or equivocal EIA results in the first step have to be confirmed with high specific (~98%) Western blot (WB) to exclude false positive EIA results [1-4]. The development of detectable IgM or/and IgG anti-*Borrelia* antibodies in the patient's blood indicates seroconversion. Considering that up to 50% of patients in the first and second stage of the disease are seronegative (*i.e.*, negative IgM and IgG anti-*Borrelia* antibodies) [5-8], many authors believe that negative results on serologic tests should not exclude diagnosis of Lyme disease if it is clinically strongly supported.

Lyme disease is treated with different types of antibiotics, depending on the symptoms and the stage of the disease. Antibiotic treatment cause release of lipoproteins and other immunogenic molecules from the dying *Borrelia* that in 7 - 30% of patients leads to temporary worsening of the symptoms, known as Jarisch–Herxheimer reaction (JHR) [9, 10]. JHR was discovered by A. Jarisch and K. Herxheimer that observed reaction in patients with syphilis who were treated by mercury. This reaction was also reported in patients with leptospirosis, relapsing fever, Q fever, bartonellosis, brucellosis, trichinellosis and African trypanosomiasis. The reaction was noticed shortly after starting the antibiotic treatment. Usual symptoms include fever, nausea, chills, headache, tachycardia, hypotension, myalgia, hyperventilation and exacerbation of skin lesions and the reaction is in most cases self-limiting [9, 10].

Herein we report a unique case of seroconversion in a patient with symptoms of disseminated Lyme disease. Seroconversion was likely triggered by release of lipoproteins and other immunogenic molecules from *Borrelia* once the bacterial die-off began due to ceftriaxone and doxycycline therapy.

CASE REPORT

A middle-aged woman was bitten by a tick while she was hiking in Gorski kotar, Croatia. Gorski kotar is an endemic area for Lyme disease, with around 105 new cases per 100,000 persons per year. She removed the tick by herself, and in a consultation with an infectologist didn't take antibiotic since she didn't have any skin changes. However, about three months later she got sick with symptoms that included fatigue, chills, muscle pain and upper back and

neck pain and stiffness. She also noticed that her cervical lymph nodes are painful to touch and enlarged. She was afebrile all the time. Routine blood analysis showed high eosinophil count (13%) and decreased iron level (2 µmol/L). Other blood findings were within the normal range. Her symptoms were attributed to allergy and iron deficiency, and she started iron supplementation and antiallergic therapy as well. With time her condition did not improve, but rather worsened over the next few months. Dizziness, hypotension, tachycardia, brain fog, difficulty concentrating, headaches, chest tightness, palpitations, migrating pain in joints and muscles, sudden episodes of intense fear, nausea, shortness of breath, insomnia, night sweats, irregular menstrual cycles, loss of libido, as well as muscle twitching in legs, arms and face occurred in the order listed. Those symptoms significantly limited her daily activities, but despite extensive diagnostic proceeding (Table 1) exact diagnosis has not been made.

Approximately 10 months after the onset of the first symptoms, she started to feel numbness in her arms and feet. Mild leg muscle weakness also occurred. Disseminated Lyme disease with nervous system involvement was suspected, and cerebrospinal fluid (CSF) sample and blood samples were taken for complete analysis. Patient was serologically re-tested for *Borrelia* and Lyme disease-coinfections, including tick-born meningoencephalitis, Anaplasma and Bartonella. It was decided to start the antibiotic therapy with ceftriaxone (1 × 2 g i.v.) immediately, without waiting for the CSF and serological findings. Although the patient tolerated the antibiotic well at first, after the second dose she got fever, the lymph nodes were severely swollen and painful, and her general condition worsened. She could barely walk due to terrible fatigue, dizziness, headaches and shortness of the breath. She was tachycardic and

Table 1. Diagnostic tests performed between the appearance of the first symptoms and the beginning of antibiotic therapy with ceftriaxone

Diagnostic test	Finding														
Blood concentrations of thyroid hormones	The FT4 (16.1 pmol/L), FT3 (4.12 pmol/L), TSH (2.06 mIU/L) and AB-TPO microsomal antibodies (<10 IU/mL) were within the normal range														
Neck ultrasound	Normal thyroid appearance but also multiple enlarged submandibular and angular lymph nodes that were from 9.7 × 6.1 mm up to 19.3 × 7.6 mm in size and one enlarged left supraclavicular lymph node (9.6 × 6.1 mm). All lymph nodes shown ultrasound features that favor reactive/infective etiology.														
MRI of neck soft tissues	Except for enlarged lymph nodes the finding was normal														
Otorhinolaryngologist	Except for enlarged lymph nodes the finding was normal, including negative throat swab and Antistreptolysin O (ASO) test within the normal range (≤200 IU/ml).														
Serology testing for infective diseases by EIA	<table border="0"> <tr> <td>CMV</td> <td>IgM negative and IgG positive</td> </tr> <tr> <td>EBV</td> <td>IgM negative and IgG negative</td> </tr> <tr> <td><i>Helicobacter pylori</i></td> <td>IgG negative</td> </tr> <tr> <td><i>Toxoplasma gondii</i></td> <td>IgM negative, IgG positive; acute infection documented 5 years ago, during pregnancy</td> </tr> <tr> <td>HIV 1 and 2</td> <td>IgM negative and IgG negative</td> </tr> <tr> <td>HBV</td> <td>anti-HBs positive due to vaccination</td> </tr> <tr> <td><i>Borrelia burgdorferi</i></td> <td>IgM negative and IgG negative</td> </tr> </table>	CMV	IgM negative and IgG positive	EBV	IgM negative and IgG negative	<i>Helicobacter pylori</i>	IgG negative	<i>Toxoplasma gondii</i>	IgM negative, IgG positive; acute infection documented 5 years ago, during pregnancy	HIV 1 and 2	IgM negative and IgG negative	HBV	anti-HBs positive due to vaccination	<i>Borrelia burgdorferi</i>	IgM negative and IgG negative
CMV	IgM negative and IgG positive														
EBV	IgM negative and IgG negative														
<i>Helicobacter pylori</i>	IgG negative														
<i>Toxoplasma gondii</i>	IgM negative, IgG positive; acute infection documented 5 years ago, during pregnancy														
HIV 1 and 2	IgM negative and IgG negative														
HBV	anti-HBs positive due to vaccination														
<i>Borrelia burgdorferi</i>	IgM negative and IgG negative														
Immunological testing	ANA, RF, ENA screen, ANCA screen, anti Sm/RN, anti Sm, anti SS-A, anti SS-B, anti Sci-7, anti Jo1 were all negative. ds DNA (<10 IU/mL), CK (58 U/L), IgA (3.0 g/L), IgM (1.6 g/L), IgG (9.4 g/L), CRP (0.3 mg/L), C4 (0.17 g/L), C3 (0.95 g/L) and Ca ²⁺ (2.51 mmol/L) were within normal range.														
UTS of carotid and vertebral arteries and transcranial Doppler UTS	Normal finding														
Brain MRI	Normal finding, no signs of demyelination, sclerosis, tumors or mass effect														
Cervical spine MRI	Bulging of C5 - C6 interspinal disc but without significant reduction of subarachnoid space and without signs of compression of spinal cord or nerve roots														
Neurosurgeon and physiatrist	There are no indications for surgery, physical therapy indicated and done														
Psychiatrist	Anxiety diagnosed														
Gynecologist	Abdominal and pelvic ultrasound, PAP test, as well as all sex hormones and tumor marker CA-125 were within the normal range. 3rd day of menstrual cycle: estradiol (203.2 pmol/L), testosterone (0.519 nmol/L), FSH (8.84 IU/L), LH (2.73 IU/L); 21st day of menstrual cycle: progesterone (21 nmol/L). CA-125 (5 U/ml)														

FT, free thyroxine; TSH, thyroid stimulating hormone; AB-TPO, thyroid peroxidase antibodies; MRI, magnetic resonance imaging; ASO, antistreptolysin O; EIA, enzyme immunoassay; CMV, cytomegalovirus; EBV, Epstein-Barr virus; HIV, human immunodeficiency virus; HBV, hepatitis B virus; ANA, antinuclear antibody; RF, rheumatoid factor; ENA, extractable nuclear antigens; ANCA, antineutrophil cytoplasmic antibodies; SS, Sjögren Syndrome; DNA, deoxyribonucleic acid; CK, creatine kinase; CRP, C-reactive protein; UTS, ultrasound; C, complement; PAP, Papanicolaou test; FSH, follicle-stimulating hormone; LH, luteinizing hormone.

Table 2. Serology test results for anti-*Borrelia* antibodies just before the start of antibiotic therapy, and at the end of antibiotic therapy that included 5 days of ceftriaxone and 4 weeks of doxycycline

	Western blot ^a										Interpretation ^b
	Antigens tested										
	OspC	p62	p41	p31/OspA	p18	p21/22	p34/OspB	p39/BmpA	p83		
IgM <i>Pre-th</i>	-	-	-	-	-	-	-	-	-	-	Negative
IgM <i>Post-th</i>	+	+	-	-	-	-	-	-	-	-	Borderline positive
IgG <i>Pre-th</i>	-	+	+	-	-	-	-	-	-	-	Negative
IgG <i>Post-th</i>	-	+	+	+	-	-	-	-	-	-	Negative

	SeraSpot ^c										Interpretation ^b	
	Antigens tested											
	OspC Ba	OspC Bg	OspC Bb	dbpA Ba	dbpA Bg	dbpA Bb	VlsE Ba	p39 Ba	p58 Bg	p100 Bg		
IgM <i>Pre-th</i>	-	-	-	-	-	-	-	-	-	-	-	Negative
IgM <i>Post-th</i>	+	+	+	-	-	-	-	-	-	-	-	Positive
IgG <i>Pre-th</i>	-	-	-	-	-	-	-	-	-	-	-	Negative
IgG <i>Post-th</i>	-	-	-	-	-	-	-	-	-	-	-	Negative

“-“ = no signal; “+” = signal present.

^aAnti-*Borrelia burgdorferi* Western blot (IgG/IgM), Euroimmun, Lübeck, Germany. It uses whole antigen, SDS extract of *Borrelia burgdorferi sensu stricto*.

^bTest were performed and interpreted accordingly to the manufacturer's instructions.

^cSeraSpot[®] Anti-*Borrelia*-10 IgG / SeraSpot[®] Anti-*Borrelia*-10 IgM Tests, Seramun Diagnostica GmbH, Heidesee, Germany.

Ba, *Borrelia afzelii*; Bg, *Borrelia garinii*; Bb, *Borrelia burgdorferi sensu stricto*.

hypotensive. Despite that, ceftriaxone therapy was continued for 5 days in total and she soon began to feel better.

In the meantime, the results of CSF and blood tests, taken just before antibiotic therapy, were finalized. All serological findings for *Borrelia* co-infections were negative, as well as WB results for IgM and IgG anti-*Borrelia* antibodies (Table 2). All blood and CSF findings were within the normal range and anti-*Borrelia* antibodies were not detected in CSF. Anyway, ceftriaxone therapy was followed by 4 weeks of doxycycline (2 × 100 mg/day).

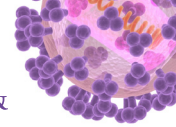
After completion of the antibiotic therapy (5 days of ceftriaxone and 4 weeks of doxycycline) patient's blood was re-tested for the anti-*Borrelia* antibodies. The detection of high specific anti-*Borrelia* antibodies by WB indicated seroconversion (Table 2).

To exclude the possibility of false-positive results, seroconversion was confirmed in a foreign laboratory by SeraSpot (ArminLabs, Augsburg, Germany), which showed the same results as the WB made in our laboratory (Table 2). Furthermore, positive results of *Borrelia* Fully-Antigen and *Borrelia* OSP-Mix (OSPA/OSPC/DbpA) ELISPOT indicated acute cellular activity against *Borrelia*. At the same time, *Borrelia* LFA-1 ELISPOT, that is often associated with autoimmune diseases, was negative.

The patient continued to be monitored and her condition improved significantly over time. About 3 months after the therapy was finished, paresthesia and muscle twitches almost completely disappeared, fatigue was less pronounced, panic attacks became less frequent, sleep improved, menstrual cycles became more regular, and after 1.5 year all the symptoms completely receded.

DISCUSSION

In patients who do not develop EM, the diagnosis of Lyme disease is sometimes very difficult to make due to nonspecific symptoms and possible false negative laboratory test results [3-7],



which was the case in the patient presented here. Patient's initial symptoms progressed over the time, and the patient underwent extensive diagnostic process (Table 1), which didn't result with exact diagnosis. Finally, occurrence of paresthesia and leg muscle weakness, together with documented tick bite in endemic area and all other persisting symptoms (headaches, migrating joint and muscle pain, extreme fatigue, lymphadenopathy, brain fog, dizziness, insomnia, panic attacks, palpitations, neck pain and stiffness and muscle twitches) were the basis for clinical diagnosis of disseminated Lyme disease with nervous system involvement [1, 2].

Antibiotic therapy with ceftriaxone (1×2 g/day i.v.) started immediately, and few hours after the second dose patient's condition worsened, probably due to JHR [9, 10]. However, ceftriaxone therapy was continued for 5 days in total. Despite the normal CSF findings, as well as negative WB results of IgM and IgG anti-*Borrelia* antibodies in the CSF and blood samples taken the day the antibiotic therapy was started, ceftriaxone therapy was followed by doxycycline for next 4 weeks (2×100 mg/day). The decision was based on studies which showed that CSF pleocytosis or other CSF abnormalities, including presence of anti-*Borrelia* antibodies, are not necessarily present in individuals with Lyme disease who have symptoms of central nervous system involvement, like headache, neck stiffness, memory or concentration problems [1,12]. Furthermore, only around 30% of patients with early localized, and around 60% of those with late disseminated Lyme disease, will show positive results for anti-*Borrelia* antibodies by two-step serological algorithm [4-7].

Immediately upon completion of ceftriaxone and doxycycline therapy, patient was serologically re-tested in the same laboratory with same reagents. WB showed IgM seroconversion, *i.e.* appearance of high specific IgM anti-*Borrelia* antibodies in contrast to the negative results from serum sampled on the day of initiation of the therapy (Table 2). Appearance of IgM anti-*Borrelia* antibodies together with IgG negativity implies acute immune response to *Borrelia*, although not necessarily acute infection [1, 2, 13]. Namely, possible scenarios include: 1) *de novo* infection, 2) a false positive result, or 3) unmasking and exposure of pre-existing *Borrelia* antigens to the host's immune system. First, the probability of *de novo* infection or reinfection is negligible because the patient has rarely left the house since the first symptoms appeared and has not been bitten by a tick since. The second scenario is hardly possible because the results were confirmed in foreign laboratory with high specific SeraSpot (Microarray) test (ArminLabs, Augsburg, Germany) (Table 2). Therefore, it is likely that patient was infected 3 months before the onset of the first symptoms, when was bitten by a tick in endemic area. For some reason *Borrelia* were not recognized by the host's immune system and consequently there was no production of anti-*Borrelia* antibodies at that time. One reason could be antihistamines taken by the patient at the time of the onset of the first symptoms, as they have been shown to have an immunosuppressive effect [14]. Furthermore, shortly after infection, *Borrelia* are shown to downregulate immunogenic surface proteins, inactivate effector mechanisms and hide in less accessible compartments like the extracellular matrix [15]. Hence, they could escape host's immune response for a long period of time. We presume that antibiotic therapy, received around 1 year after a tick bite, caused a death of *Borrelia* and release of the lipoproteins and other immunogenic molecules from dying bacteria. Subsequently, pre-existing *Borrelia* were exposed to the host's immune system, which led to accelerated phagocytosis of *Borrelia* by polymorphonuclears, activation of the complement and production of proinflammatory cytokines, especially IL-6 and TNF- α [16-18]. All this together could stimulate plasma cells to produce high specific anti-*Borrelia* IgM antibodies [19, 20]. It is not surprising that the OspC WB band was the

first to become reactive, since it is the most sensitive and at the same time the most specific when interpreting anti-*Borrelia* IgM WBs [1, 2]. The absence of IgG antibodies should not be unexpected, due to short period between the exposure of existing *Borrelia* to the host's immune system (beginning of antibiotic therapy) and the time of serological testing that revealed appearance of high specific IgM anti-*Borrelia* antibodies, *i.e.* seroconversion. Namely, it was shown that very few patients would develop IgG antibodies during that period [13]. Acute immune response to *Borrelia* was supported by positive results of ELISPOT assay. Moreover, complete absence of symptoms 18 months after completion of the antibiotic therapy, supports our theory that patient's health problems were indeed the result of *Borrelia* infection acquired 1 year before the specific anti-*Borrelia* antibodies became detectable due to antibiotic therapy.

This paper emphasizes the importance of the clinical assessment of Lyme disease, regardless of the negative serological findings and lack of EM. Moreover, it demonstrates a unique case of seroconversion in a previously seronegative patient with symptoms of disseminated Lyme disease that was likely triggered by the release of lipoproteins and other immunogenic molecules from *Borrelia* once the die-off began due to ceftriaxone and doxycycline therapy.

REFERENCES

1. Wormser GP, Dattwyler RJ, Shapiro ED, Halperin JJ, Steere AC, Klemmner MS, Krause PJ, Bakken JS, Strle F, Stanek G, Bockenstedt L, Fish D, Dumler JS, Nadelman RB. The clinical assessment, treatment, and prevention of Lyme disease, human granulocytic anaplasmosis, and babesiosis: clinical practice guidelines by the Infectious Diseases Society of America. *Clin Infect Dis* 2006;43:1089-134.
[PUBMED](#) | [CROSSREF](#)
2. Sanchez E, Vannier E, Wormser GP, Hu LT. Diagnosis, Treatment, and prevention of Lyme disease, human granulocytic anaplasmosis, and babesiosis: A Review. *JAMA* 2016;315:1767-77.
[PUBMED](#) | [CROSSREF](#)
3. Steere AC, Dhar A, Hernandez J, Fischer PA, Sikand VK, Schoen RT, Nowakowski J, McHugh G, Persing DH. Systemic symptoms without erythema migrans as the presenting picture of early Lyme disease. *Am J Med* 2003;114:58-62.
[PUBMED](#) | [CROSSREF](#)
4. Leeflang MM, Ang CW, Berkhout J, Bijlmer HA, Van Bortel W, Brandenburg AH, Van Burgel ND, Van Dam AP, Dessau RB, Fingerle V, Hovius JW, Jaulhac B, Meijer B, Van Pelt W, Schellekens JF, Spijker R, Stelma FF, Stanek G, Verduyn-Lunel F, Zeller H, Sprong H. The diagnostic accuracy of serological tests for Lyme borreliosis in Europe: a systematic review and meta-analysis. *BMC Infect Dis* 2016;16:140.
[PUBMED](#) | [CROSSREF](#)
5. Schutzer SE, Coyle PK, Belman AL, Golightly MG, Drulle J. Sequestration of antibody to *Borrelia burgdorferi* in immune complexes in seronegative Lyme disease. *Lancet* 1990;335:312-5.
[PUBMED](#) | [CROSSREF](#)
6. Wagemakers A, Visser MC, de Wever B, Hovius JW, van de Donk NWCJ, Hendriks EJ, Peferoen L, Muller FF, Ang CW. Case report: persistently seronegative neuroborreliosis in an immunocompromised patient. *BMC Infect Dis* 2018;18:362.
[PUBMED](#) | [CROSSREF](#)
7. Dattwyler RJ, Volkman DJ, Luft BJ, Halperin JJ, Thomas J, Golightly MG. Seronegative Lyme disease. Dissociation of specific T- and B-lymphocyte responses to *Borrelia burgdorferi*. *N Engl J Med* 1988;319:1441-6.
[PUBMED](#) | [CROSSREF](#)
8. Waddell LA, Greig J, Mascarenhas M, Harding S, Lindsay R, Ogden N. The accuracy of diagnostic tests for Lyme disease in humans, a systematic review and meta-analysis of North American research. *PLoS One* 2016;11:e0168613.
[PUBMED](#) | [CROSSREF](#)
9. Butler T. The Jarisch-Herxheimer reaction after antibiotic treatment of spirochetal infections: a review of recent cases and our understanding of pathogenesis. *Am J Trop Med Hyg* 2017;96:46-52.
[PUBMED](#) | [CROSSREF](#)

10. Haney C, Nahata MC. Unique expression of chronic Lyme disease and Jarisch-Herxheimer reaction to doxycycline therapy in a young adult. *BMJ Case Rep* 2016;2016:bcr2013009433.
[PUBMED](#) | [CROSSREF](#)
11. Ogrinc K, Lotric-Furlan S, Maraspin V, Cimperman J, Ruzić-Sabljić E, Strle F. Cerebrospinal fluid findings in patients with symptoms suggesting chronic Lyme borreliosis. *Wien Klin Wochenschr* 2002;114:535-8.
[PUBMED](#)
12. Ogrinc K, Lotrič-Furlan S, Maraspin V, Lusa L, Cerar T, Ružič-Sabljić E, Strle F. Suspected early Lyme neuroborreliosis in patients with erythema migrans. *Clin Infect Dis* 2013;57:501-9.
[PUBMED](#) | [CROSSREF](#)
13. Rebman AW, Crowder LA, Kirkpatrick A, Aucott JN. Characteristics of seroconversion and implications for diagnosis of post-treatment Lyme disease syndrome: acute and convalescent serology among a prospective cohort of early Lyme disease patients. *Clin Rheumatol* 2015;34:585-9.
[PUBMED](#) | [CROSSREF](#)
14. Johansen P, Weiss A, Bünter A, Waeckerle-Men Y, Fettelschoss A, Odermatt B, Kündig TM. Clemastine causes immune suppression through inhibition of extracellular signal-regulated kinase-dependent proinflammatory cytokines. *J Allergy Clin Immunol* 2011;128:1286-94.
[PUBMED](#) | [CROSSREF](#)
15. Rupprecht TA, Koedel U, Fingerle V, Pfister HW. The pathogenesis of Lyme neuroborreliosis: from infection to inflammation. *Mol Med* 2008;14:205-12.
[PUBMED](#) | [CROSSREF](#)
16. Negussie Y, Remick DG, DeForge LE, Kunkel SL, Eynon A, Griffin GE. Detection of plasma tumor necrosis factor, interleukins 6, and 8 during the Jarisch-Herxheimer Reaction of relapsing fever. *J Exp Med* 1992;175:1207-12.
[PUBMED](#) | [CROSSREF](#)
17. Galloway RE, Levin J, Butler T, Naff GB, Goldsmith GH, Saito H, Awoke S, Wallace CK. Activation of protein mediators of inflammation and evidence for endotoxemia in *Borrelia recurrentis* infection. *Am J Med* 1977;63:933-8.
[PUBMED](#) | [CROSSREF](#)
18. Cruz AR, Moore MW, La Vake CJ, Eggers CH, Salazar JC, Radolf JD. Phagocytosis of *Borrelia burgdorferi*, the Lyme disease spirochete, potentiates innate immune activation and induces apoptosis in human monocytes. *Infect Immun* 2008;76:56-70.
[PUBMED](#) | [CROSSREF](#)
19. Vijayaraghava A, Doreswamy V. Exercise and the cytokines-interleukin-6 (IL-6) and tumor necrosis factor- α (TNF- α): A review. *Ann Med Physiol* 2017;1:3-8.
[CROSSREF](#)
20. Carroll MC, Isenman DE. Regulation of humoral immunity by complement. *Immunity* 2012;37:199-207.
[PUBMED](#) | [CROSSREF](#)