

# Trigeminal Neuralgia Secondary to Meningioma of Petroclival Localization

---

**Jurjević, Ante; Bralić, Marina; Bučuk, Mira; Tuškan-Mohar, Lidija; Čoklo, Miran; Bosnar, Alan**

*Source / Izvornik:* **Collegium antropologicum, 2009, 33, 323 - 325**

**Journal article, Published version**

**Rad u časopisu, Objavljena verzija rada (izdavačev PDF)**

*Permanent link / Trajna poveznica:* <https://um.nsk.hr/um:nbn:hr:184:949048>

*Rights / Prava:* [In copyright](#)/[Zaštićeno autorskim pravom.](#)

*Download date / Datum preuzimanja:* **2024-07-22**



*Repository / Repozitorij:*

[Repository of the University of Rijeka, Faculty of Medicine - FMRI Repository](#)



# Trigeminal Neuralgia Secondary to Meningioma of Petroclival Localization

Ante Jurjević<sup>1</sup>, Marina Bralić<sup>1</sup>, Mira Bučuk<sup>1</sup>, Lidija Tuškan-Mohar<sup>1</sup>, Miran Čoklo<sup>2</sup> and Alan Bosnar<sup>2</sup>

<sup>1</sup> Department of Neurology, University Hospital Center »Rijeka«, Rijeka, Croatia

<sup>2</sup> Department of Forensic Medicine, School of Medicine, University of Rijeka, Rijeka, Croatia

## ABSTRACT

*Trigeminal neuralgia is characterized by paroxysmal episodes of facial pain in the distribution of the trigeminal nerve. It can occur in either sex but is most frequently seen in women aged 50–60 years. This article presents case of trigeminal neuralgia in a 55-year-old female patient caused by meningioma of petroclival localization. The article underscores the importance of neurologic and neuroradiologic examination in diagnosing and managing patients with facial pain conditions.*

**Key words:** trigeminal neuralgia, petroclival meningioma, root entry zone

## Introduction

Trigeminal neuralgia (TN) is a relatively common phenomenon. The rate of occurrence of TN in men and women is 2.5 and 5.7 per 100,000 per year, respectively<sup>1</sup>. TN is characterized by recurrent, brief, but intense, pain that may include more than one division of the trigeminal nerve. It can occur at any age and in either sex but is most frequently seen in women aged 50–60 years. Often a trigger point can be localized and the patient will vigorously resist attempts to elicit the pain<sup>1–3</sup>.

We report a case of petroclival meningioma that caused TN in a 55 year-old woman.

## Case Report

A 55 year-old woman had presented to our Clinic with trigeminal neuralgia involving the 2<sup>nd</sup> and 3<sup>rd</sup> divisions on the right side. She had experienced episodic, »electric shock« type pain on the right side of her face provoked by eating and talking nine months before admission. The paroxysms lasted 15 to 40 seconds at intervals of 20 minutes to a week. On admission, the patient was in good health, and hematological and biochemical studies were normal. Neurological examination was normal: the corneal reflex was present and there was no hypesthesia or hypalgesia over the face and forehead. There were no cerebellar or bulbar signs. An x-ray of the skull and temporomandibular joint, as well as transcranial Dopp-

ler ultrasonography (TCD) and brain computed tomography (CT) showed no abnormalities. The diagnosis of trigeminal neuralgia was set and treatment with carbamazepine was started.

However, eleven months later, after a favorable response to medication, the right trigeminal neuralgia recurred. The pain was not controlled with carbamazepine, it fluctuated, becoming more severe over a few days and then gradually decreasing, but never disappearing completely. On neurological examination moderate hypesthesia and hypalgesia in all 3 divisions of the right trigeminal nerve was found. Brain magnetic resonance imaging (MRI) was performed and a meningioma of the right petrous bone was diagnosed (Figure 1). Patient went to surgery and the tumor was found to originate from the dura of the posterior surface of the petrous apex and to compress the trigeminal nerve medially at its cisternal portion. The patient showed an excellent recovery. She was free of pain in the early postoperative period and at the last examination 16 months later.

## Discussion

Trigeminal neuralgia (TN) represents the most significant facial neuralgia, and is considered to be one of the most painful conditions to affect patients<sup>1–3</sup>. It can occur at any age but is most frequently seen in women

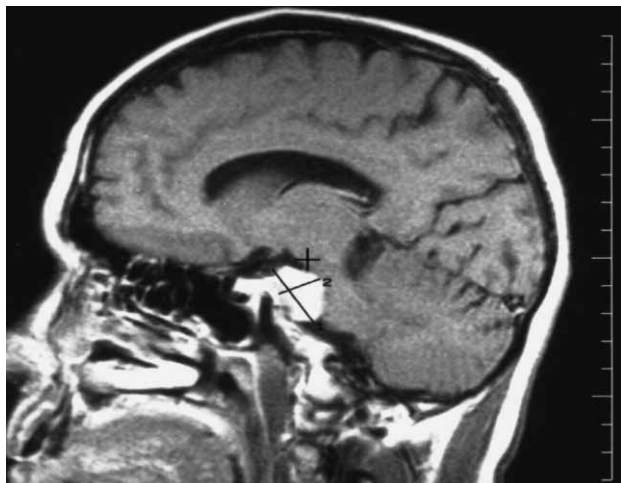


Fig. 1. Preoperative magnetic resonance image (MRI) following contrast injection shows a large tumor with homogenous enhancement.

aged 50–60 years. The rate of occurrence of TN in men and women is 2.5 and 5.7 per 100,000 per year, respectively<sup>1–3</sup>. TN is a sudden, episodic, usually unilateral facial pain that occurs most characteristically in one or more branches of the trigeminal nerve. In 10–12% of cases TN is bilateral<sup>2</sup>. In cases of TN the episodes of pain may occur paroxysmally. To describe the pain sensation, patients describe a trigger area on the face, so sensitive that touching can trigger an episode of pain. It affects lifestyle of affected person as it can be triggered by common activities in a patient's daily life, such as eating, talking, shaving and tooth brushing. The attacks are said to feel like stabbing electric shocks, burning, pressing or shooting pain that becomes intractable. Individual attacks affect one side of the face at a time, last several seconds, hours or longer, and repeat up to hundreds of times throughout the day. The pain also tends to occur in cycles with complete remissions lasting months or even years.

In most cases TN can be described as idiopathic, but in small proportion of cases TN can be associated with numerous disease entities. Symptomatic TN (STN) can be associated with the organic lesions such as tumors<sup>4</sup>, aneurysms<sup>5</sup>, or arteriovenous malformations (AVM)<sup>6</sup>. In these cases careful assessment is recommended to set proper diagnosis and to identify primary pathology.

The mechanism underlying TN remains unclear. TN is commonly caused by the compression of the trigeminal nerve at its entry zone by either an artery or a vein<sup>7</sup>. This was first recognized as a cause of TN by Jannetta and is now thought to account for 80–90% of cases<sup>8,9</sup>. Approximately 5–10% of TN have been attributed to a cerebello-pontine angle tumor<sup>10</sup>.

In cases of idiopathic TN neurological examination reveals no abnormalities: the corneal reflex is preserved, and no motor or sensitive abnormalities are present. By contrast, in symptomatic TN depression of the corneal reflex or masticatory muscle weakness may be detectable<sup>3</sup>. Thus, the presence of motor or sensory abnormalities should alert clinicians to the possibility of some underlying primary disorder.

Treatment of idiopathic TN can be medical or surgical<sup>11,12</sup>. According to recently published guidelines on trigeminal neuralgia management, carbamazepine is the drug of choice for the treatment of TN. However, baclofen, gabapentin, and other drugs may provide relief in refractory cases. Neurosurgical treatments may help patients in whom medical therapy is unsuccessful or poorly tolerated<sup>13,14</sup>.

As mentioned before, many cases of STN associated with tumors, aneurysms, or arteriovenous malformations have been reported. Also, STN can arise from neurological diseases such as multiple sclerosis<sup>15</sup>, which has to be taken into consideration especially if patients who present with the disease aged 20–40 years. Nasopharyngeal tumors, dental abscesses and temporomandibular joint dysfunction can also mimic TN<sup>16</sup>. Arachnoid cysts are sometimes associated with TN and cranial nerve palsies<sup>17</sup>.

It has been reported previously that petroclival meningiomas can compress the trigeminal nerve, resulting in trigeminal neuralgia or spasms of the facial muscles. In such cases symptoms are often subtle and meningioma is not diagnosed for a prolonged period of time. In cases of slow growing tumors, meningiomas – as in our case – change of the nature of the pain has to be alert that diagnosis of TN has to be revised. Isolated TN, especially if drug resistant may be due to tumor such as meningioma and it requires complete neurologic and radiologic imaging of the head and appropriate laboratory tests.

In our patient a petroclival meningioma was producing symptomatic TN almost identical to the essential one for a long period of time. Once brain MRI was performed the accurate diagnosis was set and the further treatment was carried out. The case we present is interesting since we had a patient and a case where the diagnosis appears clear, but everything nevertheless points to the need for brain MRI as of the basic examination. Brain MRI can help to distinguish secondary causes of TN from the idiopathic form<sup>18</sup>. It is indicated in patients presenting with the condition when younger than 60 years, principally to exclude tumor. However, angiography is still considered useful for the diagnosis of some vascular lesions.

In conclusion, neurologic and neuroradiologic examination is advised in all cases on TN to rule out possible underlying pathology.

## REFERENCES

1. CRUCCU G, LEANDRI M, FELICIANI M, MANFREDI M, J Neurosurg Psychiatry, 53 (1990) 1034. — 2. NOMURA T, IKEZAKI K, MATSUSHIMA T, FUKUI M, Neurosurg Rev, 17 (1994) 51. — 3. CRUCCU G, BIASIOTTA A, GALEOTTI F, IANNETTI GD, TRUINI A, GRONSETH G, Neurology, 60 (2006) 139. — 4. HESS B, OBERNDORFER S, URBANITS S, LAHRMANN H, HORVATH-MECHTLER B, GRISOLD W, Headache, 45 (2005) 1267. — 5. ILDAN F, GÖÇER AI, BAĞDATOĞLU H, UZ-UNEYÜPOĞLU Z, TUNA M, CETINALP E, Neurosurg Rev, 19 (1996) 43. — 6. RAHME R, ALI Y, SLABA S, SAMAHA E, Acta Neurochir (Wien), 149 (2007) 937. — 7. Anderson VC, Berryhill PC, Sandquist MA, Ciaverella DP, Nesbit GM, Burchiel KJ, Neurosurgery, 58 (2006) 666. — 8. JANNETTA PJ, J Neurosurg, 26 (1967) 159. — 9. MENDELOWITSCH A, RADUE EW, GRATZL O, Eur Neurol, 30 (1990) 338. — 10. NOMURA T, IKEZAKI K, MATSUSHIMA T, FUKUI M, Neurosurg Rev, 17 (1994) 51. — 11. SINDRUP SH, JENSEN TS, Clin J Pain, 18 (2002) 22. — 12. ERBAY SH, BHADNELIA RA, RIESENBURGER R, GUPTA P, O'CALLAGHAN M, YUN E, OLJESKI S, Neuroradiol, 48 (2006) 26. — 13. CRUCCU G, GRONSETH G, ALKSNE J, ARGOFF C, BRAININ M, BURCHIEL K, NURMIKKO T, ZAKRZEWSKA JM, J Neurol, 15 (2008) 1013. — 14. GRONSETH G, CRUCCU G, ALKSNE J, ARGOFF C, BRAININ M, BURCHIEL K, NURMIKKO T, ZAKRZEWSKA JM, Neurology, 71 (2008) 1183. — 15. HOOGE JP, REDEKOP WK, Neurology, 45 (1995) 1294. — 16. WANG CJ, HOWNG SL, Kaohsiung J Med Sci, 17 (2001) 630. — 17. BABU R, MURALI R, Neurosurgery, 28 (1991) 886. — 18. GOH BT, POON CY, PECK RH, Oral Surg Oral Med Oral Pathol Oral Radiol Endod, 92 (2001) 424.

*M. Bralić*

*Department of Neurology, Clinical Hospital Center Rijeka, Krešimirova 42, 51000 Rijeka, Croatia  
e-mail: bralic\_marina@yahoo.com*

## NEURALGIJA TRIGEMINUSA UZROKOVANA MENINGEOMOM PETROKLIVALNE REGIJE

### SAŽETAK

Neuralgija trigeminusa obilježena je napadima boli koji se periodično javljaju u inervacijskom području samog živca. Bolest se javlja u oba spola, češće u žena u dobi 50–60 godina. U radu je prikazan slučaj 55-godišnje bolesnice s neuralgijom trigeminusa čiji uzrok je bio meningeomom petroklivalne regije. Članak naglašava važnost neurološke i neuro-radiološke obrade kod dijagnostike i liječenja bolesnika s bolnim senzacijama u području lica.