

Three-dimensional reconstructed coronal plane in detection and differentiation of congenital uterine malformations

Zoričić, Davor; Despot, Albert; Tikvica Luetić, Ana; Belci, Dragan; Bečić, Dino; Dimitrijević, Aleksandra

Source / Izvornik: **Clinical and experimental obstetrics & gynecology, 2018, 45, 361 - 366**

Journal article, Published version

Rad u časopisu, Objavljena verzija rada (izdavačev PDF)

Permanent link / Trajna poveznica: <https://urn.nsk.hr/urn:nbn:hr:184:773315>

Rights / Prava: [Attribution-NonCommercial-NoDerivatives 4.0 International/Imenovanje-Nekomercijalno-Bez prerada 4.0 međunarodna](#)

Download date / Datum preuzimanja: **2024-07-16**



Repository / Repozitorij:

[Repository of the University of Rijeka, Faculty of Medicine - FMRI Repository](#)



Three-dimensional reconstructed coronal plane in detection and differentiation of congenital uterine malformations

D.I. Zoričić¹, A.L. Despot², A. Lj. Tikvica Luetić³, D.L. Belci¹, D.I. Bečić¹, Z.M. Protrka⁴,
P.S. Arsenijević⁴, A.B. Dimitrijević⁴

¹Department of Gynecology and Obstetrics, Pula County General Hospital, Pula

²University Department of Gynecology and Obstetrics, Zagreb University Hospital Center, Zagreb

³Department of Obstetrics and Gynecology, School of Medicine, University of Zagreb, General Hospital "Sveti Duh", Zagreb (Croatia)

⁴Clinic of Gynecology and Obstetrics, Clinical Centre Kragujevac, Faculty of Medical Sciences, University of Kragujevac (Serbia)

Summary

Background: Congenital uterine malformations develop during early embryogenesis, and their possible impact on female reproduction often represent a diagnostic and therapeutic challenge. In this study, the authors aimed to evaluate the possibility of detection and differentiation of Müllerian uterine anomalies on the basis of coronal plane obtained by three-dimensional transvaginal ultrasonography. **Materials and Methods:** The authors investigated 310 non-pregnant women who underwent three-dimensional ultrasound (3-D US) examination followed by the reconstructed three-dimensional images in the coronal plane. The patients were divided into two groups: infertile and unselected women. **Results:** Müllerian duct anomalies were diagnosed in 25 patients (8%). In the group of infertile patients the number of assessed anomalies was higher (16; 14.4%) as compared to the unselected patients (9; 4.6%). The prevalence of uterine anomalies was increased in the group of infertile patients. In the group of infertile patients, the length of uterine cavity was decreased compared to the unselected women ($p = 0.0021$). This difference was also visible in the case of nulliparous women from both groups ($p = 0.0070$). On the other hand, the thickness of fundal myometrium and the distance between the two internal tubal ostia did not vary among patients ($p > 0.05$). **Conclusions:** 3-D US represents a feasible and accurate technique for the detection and differentiation of congenital uterine malformations. Three-dimensional reconstructed coronal view could be used for the additional measurement of different uterine dimensions which were shown to differ between infertile patients and the control group, and according to the parity.

Key words: Uterine anomalies; Gynecology; Female infertility; Three-dimensional imaging; Ultrasonography.

Introduction

Congenital uterine malformations develop during early embryogenesis as a result of different interruptions in process of formation, vertical or lateral fusion, and resorption of Müllerian ducts. The prevalence of congenital uterine anomalies varies according to the authors with an estimated prevalence of 5.5 % in the general population and higher in selected group of women such as those with recurrent abortions [1, 2]. Highest prevalence of female tract anomalies of 24.5% was reported in patients with miscarriage and infertility [1]. Different occurrence of uterine anomalies could be associated with different clinical symptoms, varying between serious health complications in the adolescence and reproductive problems in childbearing age, although in great proportion they are asymptomatic [1, 3]. Due to the relatively high prevalence of congenital uterine malformations and their possible impact on female reproduction, they often represent a diagnostic and therapeutic challenge for the professionals. This process is further complicated by the numerous treatment options available for

their management and several classification systems existing for congenital uterine anomalies nomenclature and categorization. Since recent years the most widely used system for classification of female congenital anomalies was that of the American Fertility Society (AFS), now called American Society of Reproductive Medicine [4]. Although this system provides us with the opportunity to standardize and compare the results of surgical treatment and reproductive outcome, it has various limitations as considered the criteria and methods that are used in effective categorization and therapeutic decision-making process of these anomalies. European Society of Human Reproduction and Embryology (ESHRE) and European Society for Gynecological Endoscopy (ESGE) recognized the need for new, more reliable evidence-based updated classification of female genital tract malformations, and created the new system under the working name CONUTA (CONgenital UTERine Anomalies) [5]. The ESHRE/ESGE classification system is based on female genital development and anatomy with mainly clinical orientation as a basis to

Revised manuscript accepted for publication December 13, 2017

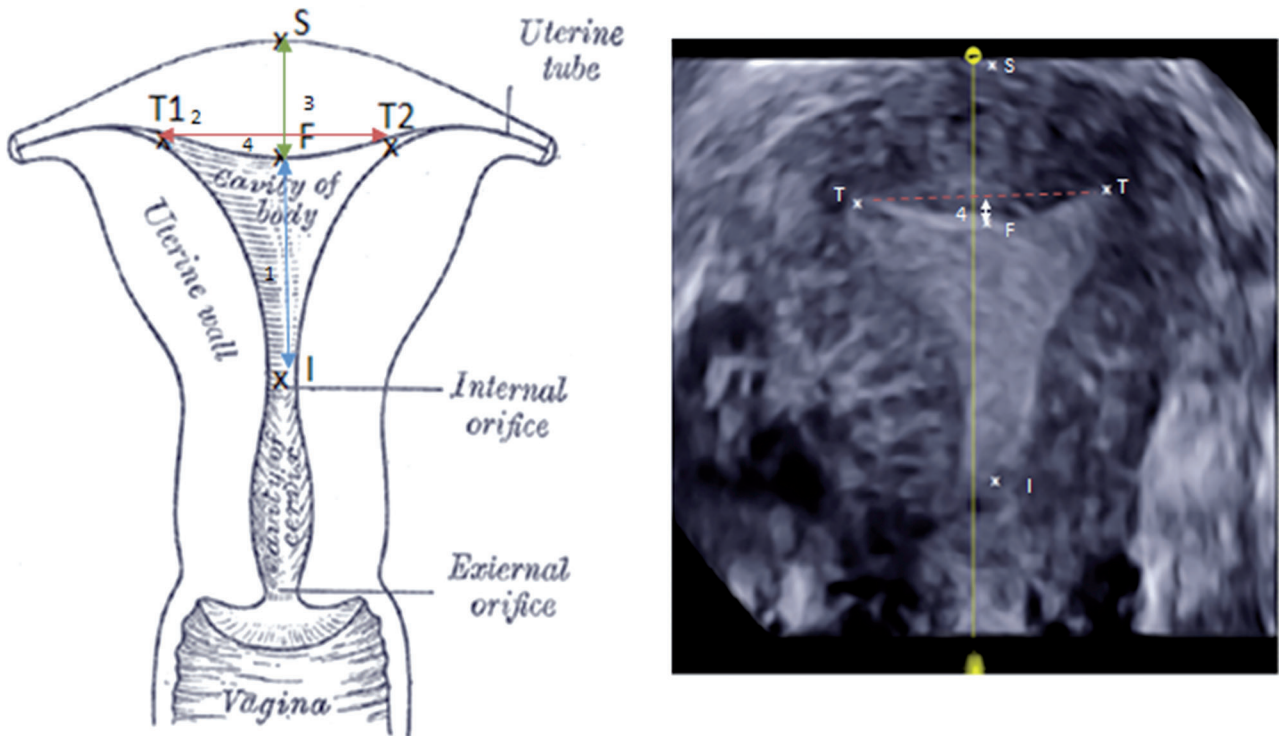


Figure 1. — Scheme of measurements of uterine cavity dimensions on the three-dimensional reconstructed coronal plane. 1 – the length of uterine cavity as a distance from the level of the internal os (I) to the fundus (F), 2 – distance between the two internal tubal ostia (T) 3 – fundal wall thickness as a distance from uterine serosal line (S) to fundal endometrial line (F) 4 – thickness of fundal concavity in relation to interostial line resulting in depth of fundal cavity indentation.

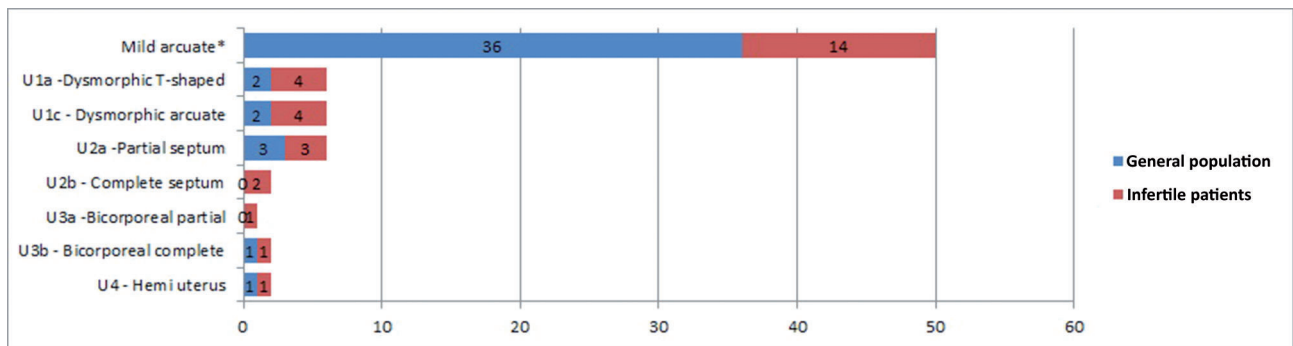


Figure 2. — The prevalence of congenital uterine malformations in the group of infertile patients and controls.

*fundal myometrium indentation from 10% to 20% of intratubal distance.

achieve the goal of for more effective diagnosis and treatment of female genital tract congenital anomalies.

The new ESHRE/ESGE consensus does not specify the diagnostic tool for the assessment and interpretation of the genital anomaly. Although there is a wide variety of diagnostic tests that are available for the examination of female genital anatomy, there is a growing pool of evidence that

three-dimensional ultrasound (3-D US) could be the most ideal technique due to its possibility to provide the information on the cervix, the uterine cavity, and the uterine wall in the same prospective [6, 7]. The great advantage of 3-D US is the possibility of the simultaneous analysis of the uterine cavity shape and the external contour of the uterus by reconstruction of the coronal view. It is important to

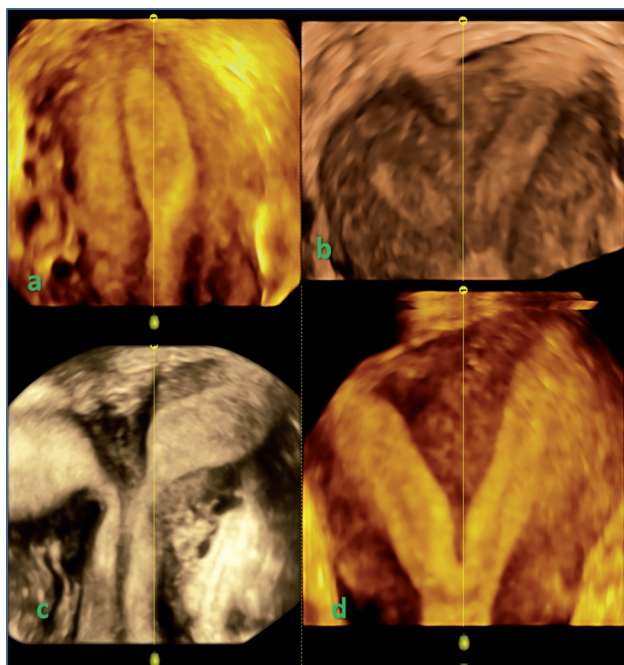


Figure 3. — Three-dimensional ultrasound reconstructed coronal plane of major congenital uterine malformations. a: Hemi-uterus (Class U4); b: Bicorporeal partial uterus (Class u3a); c: Bicorporeal complete uterus (U3b); d: Completely septated uterus (Class U2b).

mention that 3-D US is a non-invasive method that does not require liquid instillation in uterine cavity, and consecutive increase of uterine intraluminal pressure which occurs is the case of hysteroscopy and hysterosalpingography. Moreover, the use of new 3-D modalities such as OmniView and volume contrast imaging (VCI) provide us with the valuable information on the shape and dimensions of uterine cavity and its borders that were shown to be very accurate, even as compared to MRI which is limited depending on the higher costs and availability [8]. The primary aim of the study was to evaluate the possibility of diagnosis and differentiation of congenital uterine anomalies, by type, in infertile women, and in control group. This was done by the analysis of different measurements extrapolated from the coronal view of the uterus made by 3-D US.

Materials and Methods

The clinical study enrolled 310 non-pregnant women of reproductive age who did not meet any of the exclusion criteria that included all the conditions that might have an influence on the uterine size and shape such as: pregnancy, benign lesions in the myometrium and endometrium, malignant neoplasms of the reproductive organs, previous surgeries that might affect the original shape of the uterine cavity, and intrauterine devices. The participants were divided into two groups. First group consisted of women referred to a tertiary centre for the assessment and treat-

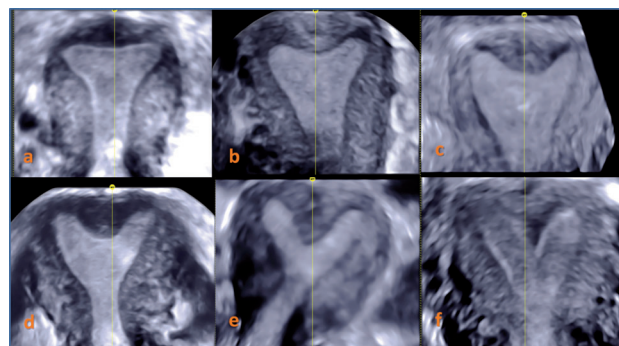


Figure 4. — Three-dimensional ultrasound reconstructed coronal plane of minor congenital uterine malformations. a, b: normal – Class U0 uterus; c: dysmorphic uterus Class U1c – arcuate; d, e and f: partial septate uterus – Class U2a.

ment of infertility (n=114) was examined at Ultrasound Unit of Clinical Hospital Centre Zagreb. Second group of unselected patients (n=196) was examined at Ultrasound Unit of General Hospital Pula.

The study was approved by Ethics Committee of the Clinical Hospital Centre Zagreb and General Hospital Pula. Prior entering the study, all women were explained in detail the purpose and objectives of the study.

Patients underwent transvaginal 3-D US examinations with volumetric transvaginal probe (4-9 MHz). All examinations were performed by two experienced sonographers. Patients were examined during the late follicular phase of the menstrual cycle, because of the increased thickness and echogenicity of the endometrium enabling more accurate interpretation. Each ultrasound assessment started with detailed two-dimensional (2-D) demonstration of the placement, size, and morphological features of the uterus and adnexa, after which the uterus was placed in mid-sagittal view in a way that occupy at least 50% of the picture on the screen.

Initial 3-D static volume acquisition with high resolution and sweep angle of 120 degrees was done on 2-D US image. All volumes were immediately stored on removable hard disk cartridges and analyzed later by the same professional in order to avoid inter observer variations. All three perpendicular planes (sagittal, transverse, and coronal sections) were displayed following reload of the images. Reconstructed 3-D images in the coronal plan with visualized both fallopian tube ostia and internal cervical os were further studied to diagnose and differentiate major uterine anomalies. VCI technique that enables precise evaluation of the inner and outer uterine shape was used for the reconstruction. Virtual flattening of the curved line of the uterine cavity was achieved by OmniView method which provides use with better quantification of the uterine cavity length and its proportion.

Several measurements were taken from the 3-D picture of uterus: the length of the uterine cavity as a distance from the level of the internal cervical os to the fundus, distance between the two internal tubal ostia, fundal wall thickness, and thickness of fundal concavity in relation to interostial line, resulting in depth of fundal cavity indentation (Figure 1). Congenital uterine anomalies were classified in accordance to the modified ESHRE/ESGE consensus on the classification of female genital tract congenital anomalies with some additional criteria; In the group U1c (all minor deformities of the uterine cavity), the authors included the arcuate uterus whose fundal midline did not exceed 50% of the

Table 1. — Comparison of uterine cavity measurements from three-dimensional coronal view between infertile patients and group of unselected women.

(mm)	Infertile n=109)	Unselected (n=194)	p-value
Length of uterine cavity	30.38±5.37	33.31±8.44	0.0021*
Intertubal distance	31.34±5.33	32.49±5.45	0.2319
Fundal wall thickness	12.64±3.08	13.23±3.15	0.1143
Fundal cavity indentation	2.44±3.68	1.45±2.48	0.0132*

* $p < 0.06$

uterine wall thickness (important for the diagnosis of the septate uterus). Moreover, arcuate uteruses were further subclassified into two groups: one with midline indentation over 20% of the intratubal distance being chosen on the bases of two standard deviations that were measured in the group of unselected patients. Other group of uteruses with mild arcuate appearance (midline indentation from 10% to 20% of intratubal distance) were also analyzed but interpreted as anatomical variation instead of uterine anomaly. Other congenital uterine malformations were diagnosed and categorized in accordance with ESHRE/ESGE consensus.

A database file was set up using Excel to facilitate data entry and retrieval. Statistical analysis was performed using Minitab Statistical Package Statistical Software and SPSS (Version 18.0). Parametric dates were analysed by Student's *t*-test, while Pearson's χ^2 -test was used to compare relative proportions of various types of uterine anomalies between two groups.

Results

Two groups of patients did not differ by age and the number of miscarriages in medical history, but there was a difference in parity between the groups (data not shown). As expected, the number of women with previous deliveries was significantly higher in the group of unselected patients as compared to the group of infertile patients. The prevalence of uterine anomalies is shown in Figure 2. Overall the authors diagnosed Müllerian duct anomalies in 25 patients (8%). In the group of infertile patients, the number of assessed anomalies was higher (16; 14.4%) as compared to the unselected patients (9; 4.6%). Morphological characteristics of uterine anomalies were further compared between the groups. The most common anomalies in both groups were those from the Class U1 or dysmorphic uterus and partially septate uterus (U2a), while only one patient from each group was found to have complete bicorporeal uterus (Class U3b) and hemi-uterus (Class U4) as well. On the other hand, the diagnosis of complete septate uterus (Class U2b) and partial bicorporeal uterus (Class U3a) were made only in infertile patient group. Although the prevalence of uterine anomalies was increased in the patients with decrease fertility, there was no difference in the prevalence of uterus with mild arcuate appearance between the two groups.

Table 2. — Comparison of uterine cavity measurements from three-dimensional coronal view between nulliparous women from infertile and control groups.

(mm)	Infertile and nulliparous (n=82)	Nulliparous in unselected population (n=105)	p-value
Length of uterine cavity	29.43±5.23	31.8±6.5	0.0070*
Intertubal distance	30.67±5.33	30.19±5.26	0.5442
Fundal wall thickness	12.3±3.26	12.64±3.1	0.4839
Fundal cavity indentation	2.75±3.99	1.66±2.46	0.0341*

* $p < 0.06$

The results of uterine measurements are shown in Table 1. Measurements from seven patients with major uterine anomalies (from U2b to U4) were excluded from the study since in these cases the anatomy of uterus was very disturbed (Figure 3) that the values could not been compared to the minor anomalies (from U0 to U2a) or controls (Figure 4). In the group of infertile patients, the authors found decreased distance from internal os to the fundus and increased fundal indentation, as compared to the unselected patients. This difference was also visible in the case of nulliparous women from both groups (Table 2). On the other hand, the thickness of fundal myometrium and the distance between the two internal tubal ostia did not vary among patients.

Discussion

The results of this study confirmed the findings of other authors, that women who are referred for the investigation of infertility have a high prevalence of congenital uterine anomalies which is even more increased in a case of multiple miscarriages [2, 9]. The most common anomalies are arcuate and partially septate uterus that were both more common in group of infertile patients as compared to the group of unselected patients (Table 1). This is in accordance with other authors who found that surgical correction of these anomalies may be beneficial for the fertility rate. [10, 11] Further on, the measurements made in this study on the basis of coronal view showed that there is a spectrum of changes of the inner myometrium contour between normal toward arcuate and partially subseptate uterus that are not increased in women with infertility problems. It is well known that fundal arcuate indentation not exceeding 10% of interostial distance does not have impact on reproductive outcome [12], while the present results suggest that even more pronounced fundal arch does not have impact on fertility rate since it is often visualized on 3-D coronal view of multiparous women. The present authors' opinion is that the definition of arcuate anomaly as uterus with the internal midline myometrium depression of over

1 cm could be too restrictive [13] due to the individual variations of internal and external myometrium contour. To bypass these variations, the present authors chose the cut off value of 20% of fundal depression since it includes two standard variations of the mean value in this group of unselected patients. In this way the authors obtained objective method to differentiate normal from uterus with mild arcuate appearance. This anatomic variation is not increased in the group of infertile patients, showing that this categorization of the uterine cavity shape does not have impact on the reproduction outcome. On the other hand, surgical reconstruction of mild uterine anomalies, such as arcuate and partially septate uterus significantly improves the pregnancy rate [13] which shows the importance of correct differentiation of uterine anomalies from its anatomic variations.

3-D transvaginal US enables visualization of the uterus in the coronal plane, which could not be obtained on 2-D conventional scans. Since coronal plane allows the simultaneous visualization of both horns of the endometrium and the cervix at the same time, we could measure different distances in the uterus which could not be analysed by 2-D US. The present authors found that the infertile women have decreased length of uterine cavity and more pronounced depression of inner myometrium margin as compared to the unselected patient (Table 2). In addition, these two measurements were shown to be decreased in the nulliparous infertile patients as compared to the nulliparous women from the unselected group (Table 3). Although the difference in the length of the uterine cavity has been shown to vary according to parity [14], the present authors have not found published studies to confirm the difference in nulliparous infertile women, as compared to the nulliparous women from general population. It is not clear whether the decrease of the uterine cavity length and the more pronounced inner myometrium indentation are the results of increased prevalence of Müllerian duct anomalies or if these anatomical features could have independent effect on reproductive outcome.

In order to elucidate many problems regarding diagnosis and classification of female congenital malformations and their impact on reproduction, larger prospective study including patients of different ages and parity should be undertaken in the future work.

The present investigation confirmed that the analysis of coronal plane obtained by 3-D US represents a feasible and accurate technique for the detection and differentiation of congenital uterine malformations. The detection rate, sensitivity, and specificity of 3-D US could be compared to hysteroscopy and MRI [15], while its obvious advantages are non-invasive nature of the method and decreased costs. The potential of 3-D sonography as a relatively simple, non-invasive, and accessible method is even empowered with the introduction of Om-

niView and VCI technology. Although 3D-US has already been proposed as a reasonable choice in the assessment of the uterine cavity in patients with a suspected uterine anomaly seen on conventional 2D scan [8, 16], this method could also be used in the evaluation and screening of low risk patients, since some of the anomalies could be successfully treated even before the onset of reproductive problems.

References

- [1] Chan Y.Y., Jayaprakasan K., Zamora J., Thornton J.G., Raine-Fenning N., Coomarasamy A.: "The prevalence of congenital uterine anomalies in unselected and high-risk populations: a systematic review". *Hum. Reprod. Update*, 2011, 17, 761.
- [2] Saravelos S.H., Cocksedge K.A., Li T-C.: "Prevalence and diagnosis of congenital uterine anomalies in women with reproductive failure: a critical appraisal". *Hum. Reprod. Update*, 2008, 14, 415.
- [3] Epelman M., Dinan D., Gee M.S., Servaes S., Lee E.Y., Darge K.: "Müllerian duct and related anomalies in children and adolescents". *Magn. Reson. Imaging Clin. N. Am.*, 2013, 21, 773.
- [4] American Fertility Society: "The AFS classification of adnexal adhesions, distal tubal occlusion, tubal occlusion secondary to tubal ligation, tubal pregnancies, Müllerian anomalies and intrauterine adhesions". *Fertil. Steril.*, 1988, 49, 944.
- [5] Grimbizis G.F., Gordts S., Di Spiezio Sardo A., Brucker S., De Angelis C., Gergolet M., et al.: "The ESHRE/ESGE consensus on the classification of female genital tract congenital anomalies". *Hum. Reprod.*, 2013, 28, 2032.
- [6] Caliskan E., Ozkan S., Cakiroglu Y., Sarisoy H.T., Corakci A., Ozeren S.: "Diagnostic accuracy of real-time 3D sonography in the diagnosis of congenital Müllerian anomalies in high-risk patients with respect to the phase of the menstrual cycle". *J. Clin. Ultrasound*, 2010, 38, 123.
- [7] Imboden S., Müller M., Raio L., Mueller M.D., Tutschek B.: "Clinical significance of 3D ultrasound compared to MRI in uterine malformations". *Ultraschall Med.*, 2014, 35, 440.
- [8] Graupera B., Pascual M.A., Hereter L., Browne J.L., Úbeda B., Rodríguez I., Pedrero C.: "Accuracy of Three-Dimensional Ultrasound in the Diagnosis of Müllerian duct anomalies compared to magnetic resonance imaging using the ESHRE-ESGE Consensus on the Classification of Congenital Anomalies of the Female Genital Tract". *Ultrasound Obstet. Gynecol.*, 2015, 46, 616.
- [9] De Felice C., Porfiri L.M., Savelli S., Alfano G., Pace S., Mangano L., et al.: "Infertility in women: combined sonohysterography and hysterosalpingography in the evaluation of the uterine cavity". *Ultraschall. Med.*, 2009, 30, 52.
- [10] Gergolet M., Campo R., Verdenik I., Kenda Suster N., Gordts S., Gianaroli L.: "No clinical relevance of the height of fundal indentation in subseptate or arcuate uterus: a prospective study". *Reprod. Biomed. Online*, 2012, 24, 576.
- [11] Tomažević T., Ban-Franjež H., Virant-Klun I., Verdenik I., Požlep B., Vrtačnik-Bokal E.: "Septate, subseptate and arcuate uterus decrease pregnancy and live birth rates in IVF/ICSI". *Reprod. Biomed. Online*, 2010, 21, 700.
- [12] Lin P.C.: "Reproductive outcomes in women with uterine anomalies". *J. Womens Health (Larchmt.)*, 2004, 13, 33.
- [13] Abuzeid M.I., Imam M., Sakel K., Mitwally M.: "Reproductive outcome after hysteroscopic metroplasty in women with primary infertility". *Fertil. Steril.*, 2007, 88, 108.
- [14] Canteiro R., Bahamondes M.V., dos Santos Fernandes A., Espejo-Arce X., Marchi N.M., Bahamondes L.: "Length of the endometrial cavity as measured by uterine sounding and ultrasonography in women of different parities". *Contraception*, 2010, 8, 515.
- [15] Giacomucci E., Bellavia E., Sandri F., Farina A., Scagliarini G.: "Term delivery rate after hysteroscopic metroplasty in patients with

recurrent spontaneous abortion and T-shaped, arcuate and septate uterus". *Gynecol. Obstet. Invest.*, 2011, 71, 183.

- [16] Faivre E., Fernandez H., Deffieux X., Gervaise A., Frydman R., Levailant J.M.: "Accuracy of three-dimensional ultrasonography in differential diagnosis of septate and bicornuate uterus compared with office hysteroscopy and pelvic magnetic resonance imaging". *J. Minim. Invasive Gynecol.*, 2012, 1, 101.

Corresponding Author:

Z.M. PROTRKA, PHD

Faculty of Medical Science and Clinic of Gynecology
and Obstetrics, Clinical Center Kragujevac

30 Zmaj Jovina Street

Kragujevac (Serbia)

e-mail: protrka.zoran@gmail.com