

# Emergencies in Otorhinolaryngology

---

**Braut, Tamara; Velepič, Marko; Kujundžić, Milodar; Marijić, Blažen;  
Maržić, Diana; Oštarijaš, Eduard**

## **Educational content / Obrazovni sadržaj**

*Publication status / Verzija rada:* **Accepted version / Završna verzija rukopisa prihvaćena za objavljivanje (postprint)**

*Publication year / Godina izdavanja:* **2021**

*Permanent link / Trajna poveznica:* <https://um.nsk.hr/um:nbn:hr:184:932190>

*Rights / Prava:* [In copyright](#)/[Zaštićeno autorskim pravom.](#)

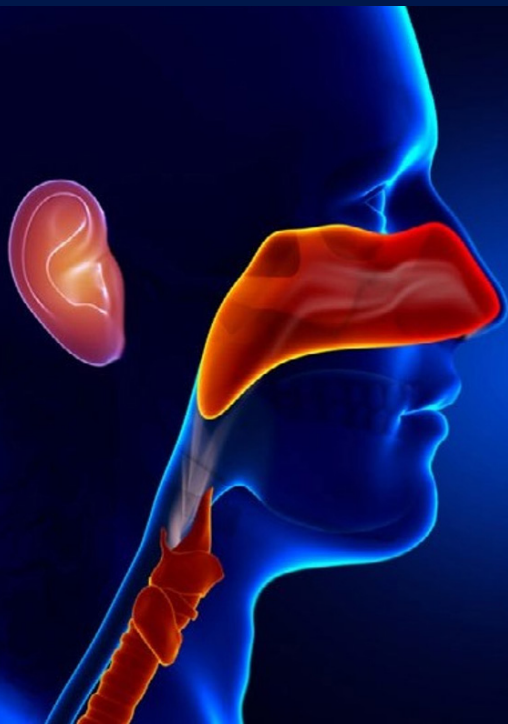*Download date / Datum preuzimanja:* **2024-11-04**



*Repository / Repozitorij:*

[Repository of the University of Rijeka, Faculty of Medicine - FMRI Repository](#)






Tamara Braut  
Marko Velepič  
Milodar Kujundžić  
Blažen Marijić  
Diana Maržić  
Eduard Oštarijaš

# Emergencies in Otorhinolaryngology

Textbook  
1<sup>st</sup> edition



Tamara Braut, Marko Velepič, Milodar Kujundžić,  
Blažen Marijić, Diana Maržić, Eduard Oštarijaš

## EMERGENCIES IN OTORHINOLARYNGOLOGY

*Udžbenici Sveučilišta u Rijeci*

*Manualia Universitatis studiorum Fluminensis*

### Publisher

University of Rijeka, Faculty of Medicine  
Department of Otorhinolaryngology

### Authors

Tamara Braut, MD, PhD, Associate Professor  
Marko Velepich, MD, PhD, Assistant Professor  
Milodar Kujundžić, MD, PhD, Assistant Professor  
Blažen Marijić, MD, Teaching Assistant  
Diana Maržić, MD, Teaching Assistant  
Eduard Oštarijaš, MD, PhD researcher

### Editor

Tamara Braut, MD, PhD, Associate Professor

### Reviewers

Srđan-Ante Anzić, MD, PhD  
Margita Belušić-Gobić, MD, PhD, Associate Professor

### English lecture and translation

Dunja Zoričić, MA in English and Croatian Language and Literature

### Graphic design

Sanja Jovanović, MA in Applied Arts, for the Center for Electronic Publishing (CEN)

Rijeka, 2021

UDK 616.21:616-083.98(075.8)


ISBN 978-953-8341-10-6 (PDF)

In compliance with the act issued by the Senate of the University of Rijeka (Class: 003-01/21-03/02, Registration number: 2170-57-01-21-98, on 30.03.2021.). This book is published as a part of the University of Rijeka edition. The University of Rijeka covers the cost of e-publishing performed by the Center for Electronic Publishing (CEN).

Tamara Braut  
Marko Velepich  
Milodar Kujundžić  
Blažen Marijić  
Diana Maržić  
Eduard Oštarijaš

# Emergencies in Otorhinolaryngology

Textbook, 1<sup>st</sup> edition



# Content

<b>Introduction.....</b>	<b>5</b>
<b>1. OTOTOLOGY.....</b>	<b>6</b>
1.1. Brief anatomical reminder .....	6
1.2. Otoscopy .....	7
1.2.1. Basic examination .....	7
1.2.2. Anatomical structures .....	7
1.2.3. Function evaluation .....	8
1.2.4. Laboratory tests.....	10
1.3. Otological symptomatology .....	10
1.3.1. Otagia .....	10
1.3.2. Otorrhea .....	12
1.3.3. Hypoacusis.....	13
1.3.4. Tinnitus .....	13
1.3.5. Vertigo .....	14
1.3.6. Facial paresis .....	14
1.3.7. Otorrhagia .....	15
1.4. Basics of therapy.....	15
1.5. Injuries.....	18
1.6. Foreign bodies .....	25
1.7. Inflammation.....	27
1.7.1. Outer ear .....	27
1.7.2. Middle ear.....	29
1.7.3. Inner ear .....	35
1.8. Emergencies in audiovestibulology.....	35
1.8.1. Isolated hearing loss .....	35
1.8.2. Isolated vestibular disorders.....	36
1.8.3. Combined audiovestibular disorders .....	37

<b>2. RHINOLOGY</b> .....	<b>39</b>
2.1. Brief anatomical and functional reminder.....	39
2.2. Examination of the nose and paranasal sinuses.....	41
2.2.1. Anatomical structures.....	41
2.2.2. Function evaluation.....	42
2.2.3. Laboratory and other interdisciplinary tests.....	42
2.3. Rhinological symptomatology.....	43
2.3.1. Epistaxis.....	43
2.3.2. Rhinorrhea.....	50
2.3.3. Sneezing.....	50
2.3.4. Pruritus.....	50
2.3.5. Nasal obstruction.....	51
2.3.6. Smell disorders.....	51
2.3.7. Allergic syndromes and headaches.....	51
2.3.8. Symptoms of surrounding organs.....	52
2.4. Basics of therapy.....	52
2.4.1. Topical therapy.....	53
2.4.2. Systemic therapy.....	55
2.5. Injuries.....	55
2.6. Foreign bodies.....	61
2.7. Inflammation and complications.....	62
2.7.1. The skin and vestibulum of the nose.....	62
2.7.2. True nasal cavity.....	63
2.7.3. Complications of sinusitis.....	65
 <b>3. OROPHARYNGOLARYNGEAL EMERGENCIES AND SELECTED CHAPTERS ON EMERGENCIES WITH OTHER ORGANS OF THE NECK REGION</b> .....	 <b>67</b>
3.1. Brief anatomical and functional reminder.....	67
3.2. Overview of the region.....	68
3.2.1. Anatomical structures.....	68

3.2.2. Function evaluation .....	69
3.2.3. Laboratory and additional tests .....	70
3.3. Symptomatology .....	70
3.3.1. Dyspnea .....	70
3.3.2. Dysphonia and aphonia.....	74
3.3.3. Painful syndromes.....	75
3.3.4. Hemoptysis and hemoptoe.....	76
3.3.5. Lymphadenopathy and other neck nodes .....	77
3.4. Basics of therapy.....	77
3.5. Hemorrhage .....	77
3.6. Injuries.....	78
3.6.1. Closed neck injuries .....	78
3.6.2. Open neck injuries.....	79
3.6.3. Other neck injuries .....	79
3.7. Foreign bodies .....	80
3.7.1. Oropharyngeal foreign bodies .....	80
3.7.2. Hypopharyngeal foreign bodies.....	81
3.7.3. Esophageal foreign bodies.....	81
3.7.4. Laryngotracheobronchial foreign bodies .....	82
3.7.5. Laryngeal foreign bodies .....	82
3.7.6. Tracheal foreign bodies .....	83
3.7.7. Bronchial foreign bodies.....	83
3.8. Inflammation and complications.....	84
<b>Conclusion .....</b>	<b>92</b>
<b>Bibliography.....</b>	<b>94</b>



## Introduction

One of the most common problems in everyday medical practice for family physicians and especially primary care pediatricians are diseases of the ear, nose, and throat, and accordingly their emergencies.

Emergency conditions are extremely dramatic for both the patient and the physician. Therefore, proper care, calmness, and resourcefulness of the physician treating the patient are of paramount importance.

The aim of this textbook is to familiarize future young physicians with basic symptomatology and the most common and most severe emergencies in otorhinolaryngology (ENT). It is important that the physician evaluates the severity of a particular emergency, triages it, and decides whether they can resolve a particular pathology alone or refer the patient to a specialist. Good cooperation between a primary care physician and ENT specialists is sometimes crucial for proper patient care.

By level of severity, ENT emergency conditions can be divided into life-threatening suffocations and bleeding and other non-life-threatening conditions that also require immediate evaluation and treatment.

According to localization, ENT emergency conditions can be classified into the area of the ear, nose, pharynx, larynx, and neck (and as such, they will be presented in the textbook). A good understanding of anatomy and pathophysiology is the key to a good diagnosis and proper medical treatment in general, as well as in otorhinolaryngology.

ENT regions contain vital structures such as the upper respiratory airways and neurovascular structures but also sensory organs (hearing, balance, smell, and taste), whose disruption can cause major handicaps in everyday life. There is also a close relation with surrounding important structures, especially the brain and the eye, which can be rapidly affected by inflammatory processes of this region.

A good understanding of basic symptomatology leads to a correct and prompt diagnosis and therapy, which can be crucial for preserving the function of the aforementioned organs and sometimes even saving lives.

# 1. Otology

## 1.1. Brief anatomical reminder

Anatomically, the ear is composed of the outer, middle, and inner ear. The outer and the middle ear are predominantly responsible for the transmission of sound signals. The inner ear is the most important part and contains a membranous labyrinth, i.e. it is a neurosensory organ with a dual function of hearing and balance. By that, the inner ear represents part of our body that is, although small in size, extremely significant because it contains these key senses.

**The outer ear** consists of the auricle and the ear canal, and its primary function is to collect and transmit sound signals. The auricle develops to its full size by the age of 6, so it is important to remember that any surgical correction of protruding ears should be performed after that age. The auricle and the ear canal are covered with skin that contains hair and sweat glands. Therefore, all skin diseases (furuncles and the like) are possible in that region. Ear canal skin is characterized by ceruminous glands. The product of these glands – earwax or cerumen – forms a protective layer that protects the ear canal skin and repels insects. This skin is adherent to the perichondrium, which explains the severe pain in inflammations of this region.

The eardrum is a membrane that separates the outer from the middle ear. As it is ovally shaped, changes on the eardrum are usually described by quadrants or clockwise numbers. Due to its slanted position in relation to the ear canal, when illuminated, a reflection of light described as a reflex (light artifact) can be seen in the lower front quadrant. If normal, it is evidence of adequate pressure in the tympanic cavity and good ventilation of the middle ear through the Eustachian tube. Its shortening is a sign of imbalance in that system, which is usually the first step toward inflammatory processes.

**The middle ear** consists of a set of temporal bone air spaces that communicate with the pharynx through the Eustachian tube. Its main function is to conduct and amplify the sound signal by transmitting the vibrations from the eardrum by the auditory ossicles that are incorporated in the tympanic cavity (malleus, incus, and stapes) to the inner ear.

It also includes mastoid cells (which can be more or less developed) and the Eustachian tube (with three important functions: equalizing atmospheric with middle ear pressure, drainage of the middle ear, and protection against infections entering the ear from the pharynx).

The membranous labyrinth of the **inner ear** (located inside the bony labyrinth) contains, as mentioned above, two important senses:

hearing (located in the cochlea) and balance (located in the vestibule and semicircular canals). These senses are transmitted by the vestibulocochlear nerve (n. vestibulocochlearis) to the auditory and balance centers in the brain.

## 1.2. Otoscopy

### 1.2.1. Basic examination

Each examination, including the otological one, begins with a good inspection and palpation as a part of the clinical examination and, if necessary, radiological evaluation of the integrity of anatomical structures and function evaluation of the region of interest.

When examining a region, two approaches should be considered:

- anatomical – integrity of structures (clinical examination and radiological evaluation)
- functional – defects in function (in the otological context of the vestibular system and hearing).

The examination is complemented by additional diagnostic methods (laboratory tests and additional multidisciplinary evaluation if necessary).

### 1.2.2. Anatomical structures

- a) **Clinical examination** begins with the inspection of the auricle, the integrity of its skin, the existence of hematomas, redness, and the like, as well as the retroauricular, preauricular, and infra-auricular regions. This is followed by an examination of the ear canal and the eardrum, which requires the use of an otoscope, ear speculum with the help of a headlight or otomicroscope.

As the ear canal is not a single-axis canal, the auricle should be gently pulled posterosuperiorly during the examination, thereby alleviating the angles between the lateral cartilaginous and medial bony part of the canal and achieving better visualization of the eardrum.

Before each examination, the ear should be washed if there are ceruminous deposits present. The most common aural toilet method used in outpatient work is rinsing the ear with a syringe. Hygiene with the help of an otomicroscope is definitely the best choice. If a physician is not experienced enough, the use of various medical forceps is not recommended for extraction of deposits and cerumen as that may lead to iatrogenic injuries of the ear canal and even rupture of the eardrum.

**b) Radiological examinations** enable assessment of the integrity of bony structures of the temporal bone. A basic radiological examination by Schuller and Stenvers enables assessment of mastoid pneumatization and fracture detection, but MSCT diagnostics is significantly more accurate (and especially indicated in head trauma). Except for MSCT diagnostics, additional radiological evaluation is sometimes performed in hospital conditions, e.g. MR in suspected neurinomas for a better insight into soft tissues, Doppler evaluation of vascular head and neck structures, and the like.

### 1.2.3. Function evaluation

In emergencies, the most important thing in basic **hearing** evaluation is to exclude sudden deafness, which should definitely be urgently referred to an ENT specialist.

Assessment of possible hearing loss is also important in the case of eardrum injuries. It should be emphasized that, depending on the rupture site and the quadrant, even a smaller rupture (as well as perforation) can cause severe hearing loss, depending on the relation to the auditory ossicular chain and the sound wave transmission.

#### **a) Hearing evaluation**

In order to exclude severe hearing loss in urgent hearing evaluation, hearing assessment can be performed by asking the patient (or the child's parent) to turn their back to the physician and drop, for example, a metal object on the ground to see if the child will respond (blink, turn toward the sound, and similar), i.e. to ask the adult patient if he can hear the sound. If they respond to the sound, we gradually reduce the sounds or the tone of the voice until the patient claims they no longer hear it, i.e. until the child no longer responds to the sound.

The patient's hearing is considered to be normal **if they understand a whisper at a distance of 6 meters from the examiner whom they are not looking at.**

#### **b) Acumetry**

Hearing assessment outside hospital services, in addition to the above-mentioned basic examinations, usually also includes **acumetric methods** with the tuning fork as the main indicator of whether hearing loss is conductive or perceptive.

**Remember:**

The Weber test is a simple and quick method of assessing types of hearing loss. A tuning fork is placed in the median plane at the patient's head and the patient is asked if they hear the sound equally on both sides or the sound is louder in one ear.

If the sound is heard symmetrically by the patient, they either have normal hearing or symmetrical hearing loss. If the sound is heard louder on the side they complained of hearing loss, it indicates conductive hearing loss. If the sound is heard louder on the side opposite to hearing loss, it indicates perceptive hearing loss.

In addition to the Weber test, the Rinne test is also usually performed. It involves placing a tuning fork on mastoid processes and then in front of the auricles. It is then monitored whether the patient hears the fork louder on the mastoid (bone conduction) or in front of the auricle (air conduction).

In the case of perceptive hearing loss or a healthy ear, air conduction of the sound is greater than bone conduction, whereas in conductive hearing loss it is contrariwise.

**c) Audiometry in hospital conditions**

Hearing assessment in hospital conditions is performed using additional tests. Pure-tone audiometry is the basis, followed by speech audiometry, tympanometry, and further subspecialist evaluation methods if necessary (evoked brain potentials and the like), for which consultation with additional literature is recommended.

**Remember:**

Hearing screening is important in:

- differential diagnosis and exclusion of sudden deafness
- severity assessment of an injury with eardrum ruptures, especially with hits or traumas sustained by another person (judicial expertise)

**d)** A quick neurological examination (walking with eyes closed, finger-nose test, nystagmus assessment, and Romberg test) is performed in balance assessment. Additional literature is advised for more information.

### 1.2.4. Laboratory tests

In addition to clinical examination, further tests are sometimes necessary in emergencies. **Laboratory blood tests** (DBC, ESR, CRP, GIB, Na<sup>+</sup>, K<sup>+</sup>, Cl<sup>-</sup>) are necessary in inflammatory conditions, whereas coagulation factors are necessary in the case of severe bleedings and traumas (especially preoperatively!).

## 1.3. Otological symptomatology

Basic symptoms of ear diseases are:

- ear pain (otalgia)
- discharge (serous, purulent, bloody) (otorrhea)
- impaired hearing (hypoacusis)
- dizziness (vertigo)
- ringing in the ear (tinnitus)
- feeling of fullness or congestion in the ear

Other symptoms of ear diseases include:

- bleeding from the ear canal (otorrhagia)
- facial nerve paresis/palsies

Based on the basic symptoms from the patient's medical history and clinical examination, the physician must weight upon the severity and urgency of particular ear pathology.

For example, classic symptoms of a common middle ear inflammation include a feeling of fullness or congestion in the ear, pain, impaired hearing, and discharge in the case of eardrum perforation. However, if these symptoms are also accompanied by vertigo, noise, and/or perceptive hearing loss, it should be suspected that the inflammation has spread from the middle ear to the inner ear. On the other hand, bleeding from the ear (otorrhagia) can be caused by a benign ear canal laceration but also by a very serious temporal bone fracture. Based on the listed basic symptoms and clinical picture, a good diagnostician and clinician will assess the severity of disease and possible complications and, accordingly, determine appropriate treatment.

### 1.3.1. Otagia

**Ear pain (otalgia)** can be caused by:

- a) otological pathology
- b) irradiation of pain from the surrounding regions.

## Otological pathology

- 1) *Acute infections, especially of the outer ear*, can cause intense pain and are often ranked on the pain scale by the patients as the strongest.
- 2) The pain in *middle ear inflammation* is also severe. It is caused by an increase in pressure inside the eardrum and an outward strain of the eardrum. In the case of eardrum perforation (and thus the equalization of the ear pressure with the atmospheric pressure), the pain significantly reduces or stops.
- 3) Unlike acute infections, *chronic infections* usually do not cause severe otalgia. Special attention is necessary with diabetic patients, whose chronic middle ear inflammation can get complicated and spread to surrounding organs and structures without severe pain due to diabetic polyneuropathy and consequent hypesthesia.
- 4) The *inner ear pathology* does not usually cause classic otalgia, but it is accompanied by a defect of the vestibular and/or auditory function.

## Irradiation of pain from the surrounding regions

- 1) *Pharyngeal otalgia* most commonly occurs in various pharyngeal inflammations and is also common in wound healing after tonsillectomy. However, tumors should always be excluded, especially in unilateral symptomatology. Therefore, evaluation and detailed examination of the surrounding regions (especially oropharyngoscopic and laryngoscopic examination, as well as examination of neck structures) are required. Thus, along with mild dysphagia, otalgia can occur as one of the first symptoms of a hypopharyngeal tumor. Irradiating otalgia also occurs with various neck swellings, irritation of the styloid process, and the like.
- 2) Patients often come with a referral diagnosis of otalgia with suspected otitis caused by the *dysfunction of the temporomandibular joint*. The pain can be very intense and can spread to the rest of the face and head. Therefore, each otalgia requires not only an otological examination but also a functional analysis of the temporomandibular joint. In differential diagnostics, pain when opening the mouth with masticatory movements (increased with digital compression on the articular capsule) is a helpful sign.
- 3) *Odontogenic pathology* (especially in molars) also often causes irradiation of ear pain and should be excluded in the differential diagnostics.

**Remember:**

In addition to otological examination to exclude the pathology of the ear, **especially in negative otoscopic findings**, each **otalgia** also requires a complete otorhinolaryngological examination of the surrounding regions (primarily of the pharynx and, if necessary, the larynx, esophagus, and neck), a dental examination (to exclude odontogenic pathology), and function evaluation of the temporomandibular joint. In the case of a negative finding, further testing is necessary (especially neurological) along with assessment of the vascular head and neck status, and, if necessary, internal medicine specialist examination to set a correct diagnosis.

### 1.3.2. Otorrhea

**Discharge from the ear (otorrhea)** can be purulent, serous, or bloody.

**Purulent secretion** is most commonly encountered in eardrum perforation in the case of middle ear inflammation, but it can also originate from the ear canal, which is why otoscopic examination is necessary to specify its origin.

**Serous secretion** is less common and usually detected in children with tubes inserted in the case of middle ear mucosal inflammation or milder outer ear inflammation.

**Bloody discharge** can usually be seen in hemorrhagic viral inflammation of the outer ear. Bloody discharge usually causes great fear in patients due to a popular belief that bleeding from the ear is life-threatening. The patient should be explained that this is not bleeding caused by head trauma, but a bloody discharge of viral origin caused by a blister rupture on the skin. The patient should not use cotton swabs, moisten the ear canal, or place any objects or herbal preparations in the ear. Therapy should include sterile antibiotic drops and, if necessary, peroral antibiotics.

**Remember:**

Otorrhea with abrupt reduction of pain in middle ear inflammation is a sign of eardrum perforation and passive drainage of purulent content.

The absence of otorrhea does not imply the absence of chronic middle ear inflammation or inner ear pathology!



On the other hand, in patients with marginal perforation (which is a sign of osteitic inflammation and/or cholesteatoma), otorrhea is not synonymous with good drainage. Despite the purulent discharge, complications may occur by the propagation of the inflammatory process through the bone into the surrounding organs.

Bloody discharge (otorrhea) should definitely be distinguished from pure blood from the ear canal (otorrhagia).

### 1.3.3. Hypoacusis

**Hypoacusis** indicates any type of hearing loss. Impaired hearing requires an otological examination. It can be caused by various etiological reasons. Although hypoacusis usually occurs as a part of inflammatory conditions (either purulent or serous middle ear inflammation or ventilation disturbances) its pathology can sometimes be very serious.

Testing is especially required in unilateral hearing loss, where the neurinoma of the vestibulocochlear nerve should be excluded. Sudden deafness should primarily be excluded in sudden, severe hearing loss. Hearing loss (hypoacusis) in cochlear damage is often accompanied by tinnitus.

In elderly people presbycusis occurs as a result of aging.

It is interesting to mention the so-called hyperacusis (noise intolerance) in the case of damage to the inner ear, sometimes misinterpreted by the patient as noise (typical patients' statements like "I can't hear speak louder" turn into "why are you shouting" when we raise the tone of our voice).

### 1.3.4. Tinnitus

**Tinnitus** indicates sounds perceived by the patient without an objective external auditory stimulus. Similar to epileptic seizures, people often experience tinnitus throughout their lives, and it is considered that this pathology affects 10 – 15% of the adult population. Tinnitus is often the cause of diagnostic and therapeutic dilemmas, which is why it is necessary to determine its origin, tonality, and intensity. Every tinnitus requires an otoscopic examination and a subsequent audiological evaluation (besides the cochlear origin, tinnitus can have different etiologies and it is necessary to exclude central causes, especially the tumor of the vestibulocochlear nerve and posterior cranial fossa). The cervical spine and the vascular status of the head and neck (due to frequent vascular etiology of tinnitus) should also be examined. These are usually milder disorders, but it is important to assess the patient's tolerance because certain tinnitus can be invalidating and require stronger treatment. Milder tinnitus is treated using a minimalist approach with placebo and the so-called behavioral therapy,

whereas severe disorders are treated with certain anticonvulsants, sometimes even vasodilators for 3 to 4 weeks, and if needed psychotherapy.

**Remember:**

Every tinnitus requires an otological examination and audiological testing because it can be a sign of the tumor of the vestibulocochlear nerve. The vascular status of the head and neck should also be examined.

### 1.3.5. Vertigo

**Dizziness (vertigo)** indicates the illusion of movement. It is often accompanied by balance disorders, but these are not synonyms! It is usually of vestibular origin. Patients most commonly report a feeling of rotation, especially with peripheral vestibular damage, often accompanied by nausea and vomiting. In milder cases, patients report instability and insecurity during walking. It is never accompanied by a loss of consciousness! Therefore, syncope excludes the diagnosis of vertigo and should definitely be evaluated by a neurologist and internal medicine specialist. Patients often misperceive various other symptoms (from dizziness to acrophobia) because psychosomatics can also cause symptoms similar to vertigo.

When testing for vertigo, it should primarily be differentiated whether it is peripheral or central. For more information on the differential diagnostics of vertigo, additional literature is advised.

**Remember:**

Not every languor indicates true vertigo. Antivertiginous therapy should not be prescribed in digestive, cardiac, and psychosomatic disorders!

Vertigo does not always imply a major rotation crisis. The illusion of movement definitely requires testing because, except benign disorders, it can also be a sign of a tumor of the posterior cranial fossa.

### 1.3.6. Facial paresis

**Facial paresis** of otological origin is always peripheral and should be distinguished from the centrally caused paresis. Peripheral facial paresis can occur in tumor processes within the petrous part of the temporal bone and parotid gland, as a part of otological complications (chronic otitis media), after temporal bone fractures (transverse and longitudinal), and in

neurological disorders. However, most often it is Bell's palsy, the etiology of which is still controversial (usually a viral infection underlies it).

### 1.3.7. Otorrhagia

**Bleeding from the ear (otorrhagia)** implies hemorrhage from the ear canal. It is usually identified in the population with serious and life-threatening head traumas, but it can also be caused by harmless injuries of the ear canal when cleaning the ear with a cotton swab or the like. It is important not to confuse bloody discharge (rupture of a viral hemorrhagic blister) with pure blood in the ear canal. Unlike the discharge that should be rinsed and cleaned, blood from the ear canal should never be cleaned without an otomicroscope.

**Remember:**

Never rinse the ear with water in case of clear otorrhagia!

A patient with otorrhagia the cause of which is unknown (medical history of ear canal lesion due to ear cleansing, insects, foreign bodies, and the like is negative) should definitely be referred to an ENT specialist.

## 1.4. Basics of therapy

Patients often resort to a systemic administration of antibiotics while neglecting the importance of topical therapy, which is the most important for most diseases in otology.

**Aural toilet.** It is best to clean the ear under a microscope. However, aural toilet is usually performed in outpatient care with a syringe (with or without an extension) and body temperature water (to avoid provoking vertiginous manifestations with hot or cold water). If the syringe is not available, the ear can be carefully cleaned with a swab. The swab should be made of a thin metal stick and a cotton tip (make sure that the cotton is properly coiled to prevent iatrogenic foreign bodies in the ear canal). It is preferable to use these swabs from commercial ones (which are usually wide and often cause additional cerumen impaction distally to the physiological narrowing of the ear canal).

**Remember:**

In outpatient care, it is preferable to rinse the ear using a syringe with body temperature water. It is useful to pull the auricle backward and upward, which widens the ear canal and enhances its toilet. If necessary, the patient could be asked to open the mouth slightly because a firm bite compresses the anterior ear canal's thin bone and therefore narrows it slightly, making the procedure less effective.

If we are dealing with inflammation and not cerumen, it is preferable to use 3% boric acid solution instead of cleaning it with tap water.

If medical forceps and tweezers are used for aural toilet, great caution is required due to the possibility of damaging the ear canal and eardrum by manipulation (iatrogenic rupture that classifies as a severe physical injury).

Patients should definitely be talked out of cleaning their ears with cotton swabs, which should only be used for auricular hygiene. They should also be told that this is how impacted cerumen usually appears.

**Ear drops (*otoguttae*).** Ear drops are prescribed for treatment of:

***Cerumen:*** drops with an emollient effect are used to soften the hardened earwax. There are several types of oil sprays on the market that serve this purpose.

Patients should be advised that in order to prevent the formation of ceruminous plugs, they should avoid using cotton swabs when cleaning the ear because that pushes the earwax and enhances the formation of hard obturating cerumen.

***Inflammation of the ear canal (otitis externa):*** antiseptics are used to balance pH and to facilitate aural toilet (e.g. a 3% boric acid solution), preparations like corticosteroid drugs (e.g. dexamethasone) for edema reduction, and topical antibiotics as an etiological therapy in the case of bacterial infections (e.g. tobramycin or ciprofloxacin). In fungal ear canal inflammation (*otomycosis*), topical antimycotic drugs (e.g. 1% clotrimazole or miconazole) are used instead of antibiotics (which are contraindicated because they enhance fungal growth). Hygiene with antiseptics that clean and enhance pH regulation and thus eradicate mycosis of the auditory canal (e.g. a 3% boric acid solution) is also very effective. Caution is definitely required when administering antibiotics, antimycotics, or antiseptics in the case of perforated

eardrums, considering that certain available preparations are ototoxic, especially in prolonged administration of these drugs. In the case of eardrum perforation, the patient should be referred to a specialist for otomicroscopical toilet and prescribing the most appropriate therapy.

**Acute and chronic middle ear inflammation (otitis media acuta et chronica):** administration of antibiotic otological drops makes sense in middle ear inflammation **only** in the case of eardrum perforation. Antibiotic drops are administered intranasally, preferably in a supine position with the patient's head tilted toward the diseased ear. The drops will not open the Eustachian tube, but they will improve breathing through the nose and cancel the effect of the Toynbee phenomenon (production of negative middle ear pressure during swallowing when the nose is obstructed).

**Topical dressing pad.** Outer ear inflammation can be treated very efficiently with a small gauze (0,5 – 1 cm wide, 4 – 5 cm long) soaked in a boric acid solution, smeared with an antibiotic ointment or even better with a Burow's solution (aqueous solution of aluminum acetate). The patient is instructed to keep the gauze moistened by dripping on it a boric acid solution or the like every 4 – 5 hours. The gauze has a double beneficial effect. On one hand, it has an antiedematous effect. On the other hand, drops dripped on it by capillary action penetrate deeper into the ear canal and have a better effect. An additional effect of the Burow's solution is the pH normalization of the ear canal (which hinders bacterial growth) and the astringent effect (it causes constriction of cracked skin and thus promotes healing and reduces skin soreness).

**Valsalva maneuver.** Good ventilation is very important for the health of the middle ear. It usually occurs naturally and spontaneously through swallowing (by contraction of the palate muscles), which opens the pharyngeal orifice of the Eustachian tube and equalizes middle ear with atmospheric pressure. However, spontaneous ventilation is impeded (or even disabled) if there is a greater difference in pressures, due to poor middle ear ventilation caused by the middle ear pathology, or due to a sudden increase in atmospheric pressure (when diving or flying by plane) as walls of the tube may collapse in these cases. In these situations, it is necessary to improve the patency of the auditory tube, and the simplest and best maneuver is the Valsalva maneuver. The procedure is very simple and each physician should be acquainted with it so they can advise it to their patients. It is performed by strongly exhaling through the nose with nostrils obstructed (by firmly holding them with fingers), which pushes the air from the nose through the tube, thus equalizing middle ear with atmospheric pressure. A commercially available nasal balloon can also be used, especially in children who sometimes do not know how to perform the Valsalva maneuver.

In addition to the Valsalva maneuver and the balloon, other techniques are also performed in healthcare settings.

**Paracentesis (myringotomy)** is a procedure used for eardrum opening to remove the secretion from the middle ear. It is performed in adults under local anesthesia and in children under general anesthesia. Although this procedure is very rare for acute processes (in the antibiotic era), it can be used to relieve pain in severe middle ear inflammation and extremely tense and painful red eardrum. It can also serve to collect and microbiologically analyze the secretion.

In chronic serous middle ear inflammation, due to problems usually associated with tubal dysfunction, in cases when the Valsalva maneuver and other noninvasive methods for middle ear ventilation are ineffective and conductive hearing loss persists, myringotomy is applied. It is performed in the anteroinferior quadrant of the eardrum with aspiration of the thick seromucous secretion from the tympanic cavity. Ventilation tubes can also, if needed, be placed after aspiration of the content. This is used to avoid permanent hypoacusis and adhesive processes of the middle ear. Additional literature should be consulted for more information.

Of course, serious conditions (e.g. severe inflammatory processes, sudden deafness, and the like) require both topical and systemic therapy (antibiotics, antiedematous drugs, corticosteroids – depending on the pathology) and sometimes even surgical interventions.

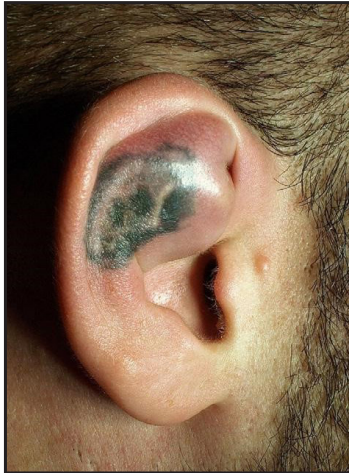## 1.5. Injuries

The most common injuries are **lacrocontusion injuries of the auricle** – from simple lacerations, smaller and larger wounds with or without tissue loss, to auricular avulsions. Smaller lacrocontusion injuries of the auricle should be surgically treated and the patient should be protected with antibiotics for about 10 days. Because of its anatomy and poor vascularization as well as close contact with the skin on both sides the auricular cartilage sometimes hinders the surgical treatment and postoperative wound healing. Reconstruction of the auricle can be very demanding and difficult, and in emergency interventions, the physician should try to preserve every vital tissue. Sutures should be placed in layers and the perichondrium should be sewn separately from the skin. In auricular injuries, a possible formation of the so-called othematoma requires special attention.

**Othematoma** is blood outflow in the subperichondrial space, between the cartilage and the auricular skin. The most common cause of othematoma is a stroke or a slap. Being that the cartilage does not have its own nutrition; it feeds on the capillarity of the adjacent skin. In the case of blood outflow between the cartilage and the skin during trauma, there is a risk of cartilage necrosis and subsequent deformation of the auricle.

Therefore, it is important to recognize the hematoma and treat it timely and adequately. Treatment of othematoma requires incision and drainage, followed by a compression bandage and antibiotic protection.

**Figure 1.** Othematoma



**Table 1.** Othematoma – symptomatology and treatment procedure

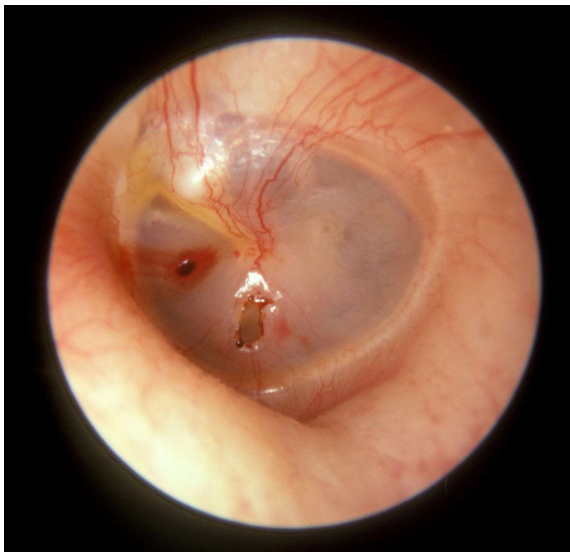
<b>OTHEMATOMA</b>	
<b>Appearance/symptoms</b>	<b>Procedure/therapy</b>
<ul style="list-style-type: none"> <li>• swollen and deformed auricle</li> <li>• consequence of trauma</li> <li>• blood/transudate accumulates in the subperichondrial space</li> <li>• <b>risk:</b> cartilage necrosis</li> </ul>	<ul style="list-style-type: none"> <li>◇ <b>refer to ENT</b></li> <li>• incision and drainage</li> <li>• compression bandage</li> <li>• antibiotics</li> </ul>

**Ear canal** injuries are most commonly caused by incautious cleaning of the ear canal with a cotton swab or by scratching the ear. Minor injuries heal spontaneously. However, more prominent injuries should be surgically treated and the ear canal should be protected with a sterile antibiotic tampon. The patient should be advised to avoid ear moistening and contact with water.

In thermal injuries (such as frostbites), the auricle should be warmed with a warm compression bandage, the patient should be protected with antibiotics, analgesics, and anticoagulants (depending on the extent of the injury). Burns and severe frostbites accompanied by necrosis require surgical treatment.

**Eardrum rupture** represents an interruption of the eardrum continuity caused by an outside force (a stroke, most often a slap, injury with various objects thrust into the ear canal, e.g. cotton swabs) or a difference in pressure when diving. Unlike rupture, perforation is a burst of the eardrum in severe middle ear inflammation (force from inside towards outside). Basic symptoms that cause the patient to visit their physician are severe pain, which can gradually decrease, a feeling of fullness in the ear, hearing loss and tinnitus, and air “whistling” from the injured ear. Otoscopically, irregular laceration of the eardrum is usually seen with marginal petechial hemorrhage. In addition to the otoscopic/otomicroscopical examination, evaluation should also include audiological diagnostics and assessment of hearing impairment, especially for ruptures caused on purpose by another person (known or unknown). This should be performed for further classification of the injury and forensic expertise. It is important to emphasize that hearing loss is affected by the size and position of the rupture on the eardrum (based upon its effect on the sound wave conduction).

**Figure 2.** Eardrum rupture



Prescribed therapy includes peroral antibiotics for 10 days and administration of nasal drops, sterile non-ototoxic antibiotic drugs, whereas other drops, washing and moistening of the ear are forbidden. Minor ruptures usually heal spontaneously, especially in younger people. Lacerated edges in large eardrum ruptures can be repositioned by otomicroscopy to facilitate healing, but if spontaneous wound closure does not occur, a subsequent tympanoplasty is required.



**Temporal bone fractures** usually cause great fear in the population. Their severity is based on otological complications and possible communication of cerebral and subarachnoid structures with the outside world, which can cause meningitis and other serious neurological sequelae. It should be noted that there is no parallel between the severity of the fracture and complications, i.e. severe fractures can have no consequences, whereas on the other hand, microfractures can cause otological and neurological sequelae even years after the trauma.

Any suspected temporal bone fracture requires a specialist evaluation (a multidisciplinary approach; otorhinolaryngological, audiological, radiological, and neurological diagnostics). Of course, neurosurgical evaluation is primary in emergencies, especially the exclusion of various hematomas (subdural, extradural, and the like) that require urgent surgical intervention.

After a neurological evaluation, a detailed otological evaluation is necessary as soon as the patient's condition allows it. Its purpose is:

- proper therapeutic measures
- prevention of infectious complications
- prevention of otological complications and consequences.

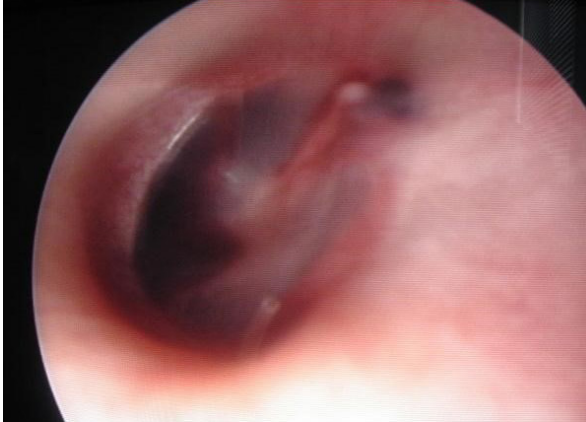During the evaluation, typical signs of otological damage should be looked for, such as otorrhagia, otoliquorrhea, hemotympanum or eardrum rupture, various degrees of peripheral facial nerve paresis, and the like.

**Otorrhagia** implies bleeding from the ear canal. It is usually a sign of severe temporal bone fracture and damage to the eardrum and middle ear, but it can also be caused only by a less serious lesion of the ear canal, which can be confirmed or excluded by an otoscopic/otomicroscopical examination. Treatment includes antibiotics, and if the bleeding is severe, sterile gauze is placed in the ear canal. Ear lavage, which can cause infection, is strictly forbidden.

**Otoliquorrhea** is not only a sign of temporal bone fracture but also of meningeal fistula. It can be stained with blood in the first days and later it becomes clearer, which confirms the diagnosis. If spontaneous wound closure does not occur, surgical intervention is necessary. In any case, antibiotic therapy is necessary for the prevention of meningitis. If the eardrum is not perforated, the cerebrospinal fluid can reach the epipharynx through the tube and leak into the nose (rhinoliqorrhea) or into the pharynx, which should not be overlooked during patient evaluation.

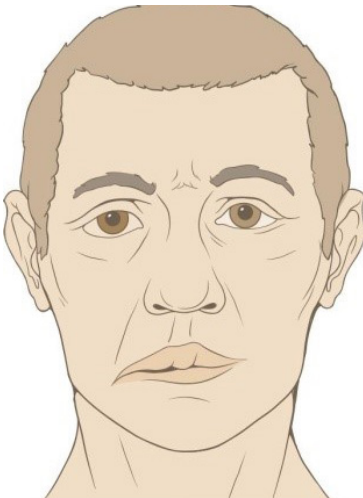**Hemotympanum** is an outflow of blood in the tympanic cavity that is manifested by a bluish-purple color of the eardrum during the otoscopic examination. Within the context of head trauma, it is usually a sign of temporal bone fracture and certainly requires a specialist evaluation.

**Figure 3.** Hemotympanum



**Facial paresis** is sometimes difficult to diagnose in a polytraumatized, swollen, and uncontactable patient, so its signs should be looked for. If immediate, facial paresis indicates nerve section or nerve contusion. Gradual facial paresis primarily indicates compression by hematoma or edema. Depending on the severity, evolution, time of occurrence, and neurological and audiological status, except corticosteroid therapy to reduce edema, facial paresis sometimes requires surgical exploration and decompression and, if necessary, reintegration of the neural thread course.

**Figure 4.** Facial paresis



An otoscopic examination is performed to analyze the lesions of the ear canal and possible ruptures of the eardrum or hemotympanum, which are usually indicators of a temporal bone fracture, with a note that eardrum rupture can also be caused by a blast injury without a bone fracture.

The hearing examination should be performed as soon as the patient's condition allows it. Total cophosis or deafness raise suspicion of labyrinthine fracture and the risk of meningitis, thus requiring antibiotic therapy. Conductive hearing loss can occur in hemotympanum, ossicular dislocation, and eardrum rupture. Except for antibiotic, in eardrum ruptures, especially the ones accompanied by otorrhagia, moistening of the ear, different ear drops, and manipulation of the ear canal should be strictly forbidden. If not recovered spontaneously, it requires subsequent surgical treatment and tympanoplasty. Perceptive hearing loss is a sign of labyrinthine commotion, it can occur in any cranial trauma with or without temporal bone fracture, and usually, if not recovered in the early posttraumatic period, it remains fixed. Hearing deterioration within several months after the trauma signals the possibility of perilymphatic fistula. Searching for vestibular signs upon the evaluation involves an examination of nystagmus (spontaneous nystagmus contralaterally from the affected ear raises suspicion of labyrinthine fracture) and vertigo. Vestibular signs can occur in labyrinthine commotion, cerebral trunk contusions but also cervical spine lesions. Urgent radiological diagnostics is necessary in the case of cerebrospinal fluid (CSF) leak and sudden facial paresis. In the case of other symptoms, depending on neurosurgical and otological findings, it can be performed subsequently.

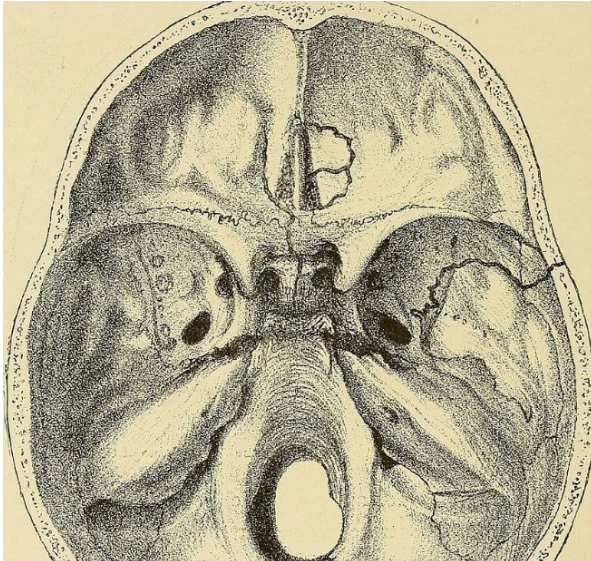
The two basic types of **temporal bone fractures** are longitudinal and transverse.

Longitudinal fractures are usually accompanied by bleeding from the ear canal (otorrhagia), and sometimes, in severe injuries and meningeal lesions, even with CSF leak. If the eardrum is not injured, hemotympanum occurs instead of otorrhagia. The patient reports conductive hearing loss (lateralization into the injured ear in the Weber test). Due to middle ear injuries, the facial nerve can be damaged on the way through the tympanic cavity, resulting in peripheral paresis (in approximately 20% of fractures).

Transverse fractures are often accompanied by hemotympanum without otorrhagia. Blood outflow through the tube may result in bleeding from the mouth. Due to the absence of the eardrum injury, the liquor in dural injury usually leaks into the nasal cavity and results in rhinoliqorrhoea. Therefore, the evaluation of patients with head trauma should include history-taking on whether clear fluid is leaking from their nose, which is a symptom that should not be overlooked.

Nausea, vomiting, vertigo, nystagmus, and perceptive hypoacusis occur due to labyrinthine damage (lateralization into the healthy ear in the Weber test). An early facial nerve paresis occurs in almost half of the cases.

**Figure 5.** Transverse temporal bone fracture



In temporal bone fractures, depending on the symptoms, surgical intervention is sometimes necessary along with antibiotic therapy and rest. Accordingly, immediate facial nerve paresis requires urgent surgical treatment, whereas treatment of gradual facial nerve paresis (which occurs after several days and suggests nerve compression due to edema in the bony canal) can commence with an antiedematous therapy. If the therapy is not effective, it also requires surgical treatment. Persistent liquorrhea also demands additional surgical treatment, as well as conductive hearing loss (tympanoplasty).

**Other otological traumas.** In addition to head traumas and acoustic traumas of the inner ear, otological injuries can also occur due to differences in pressures (e.g. when flying by plane or when diving). These are the so-called barotraumatic injuries. They can affect the middle ear (from serous otitis to eardrum rupture) or the inner ear (with tinnitus and vertiginous disorders). Inner ear barotrauma requires rest and administration of corticosteroids. As with other causes, it is important to emphasize to the patient with barotraumatic eardrum rupture to protect the ear from water and to prescribe antibiotic therapy. In the prevention of these traumas, it is important to educate divers about the importance of nasal and tubal patency and to familiarize them with the Valsalva maneuver.

Specifically, outside hydrostatic pressure increases during dives which affect the eardrum. Failure to equalize this pressure can result in ear barotrauma. Therefore, divers are advised to swallow during dives or perform the Valsalva maneuver, which helps to normalize the pressure in the tympanic cavity. Before flying by plane, except the aforementioned, it is advised to “suck” on a piece of candy or chew gum. Also, depending on the nasal obstruction, a nasal vasoconstrictor is used half an hour before the flight or before the dive. Diving out is less dangerous because it is easier to equalize a relatively higher pressure in the tympanic cavity by its passing through the tube into the epipharynx.

Other blast traumas and eardrum ruptures are usually the results of a stroke by direct force to the ear, especially with an open palm (slap) or ball. In addition to proper diagnosis and therapy, considering it is usually an injury (intentional or unintentional by a known or unknown person), it is important to obtain detailed anamnestic data during patient evaluation for potential subsequent forensic expertise.

Thermal injuries and usually large ruptures caused by glowing metal (most commonly in welders and the like) often cause inflammation and rarely heal spontaneously. Other than treatment by the same principles applied with other ruptures, they usually require surgical treatment (tympanoplasty).

Traumas caused by various manipulations or careless cleaning and scratching of the ear (cotton swabs, toothpicks, hairpins, matches, and the like) can also be severe and can lead to ear canal lacerations, eardrum ruptures, and even interruption of the auditory ossicular chain. In addition to otoscopy/otomicroscopy, they also require an audiological evaluation and, depending on the findings, antibiotic therapy and sometimes surgical treatment.

It is important to prevent these traumas by keeping thin and sharp objects (like the abovementioned) away from children. It is also important to emphasize that in cases foreign bodies are found during otoscopic examination in the ear canal, it is recommended to leave their extraction to a specialist due to the possibility of additional traumas during their manipulation (see next chapter).

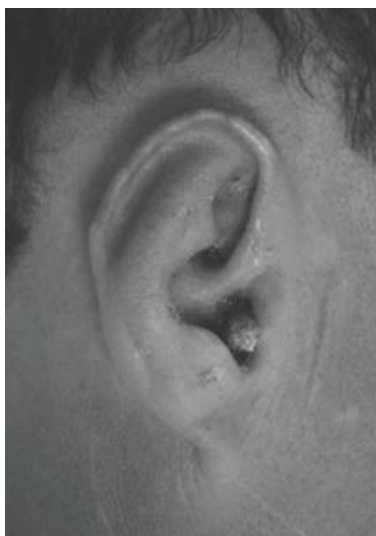## **1.6. Foreign bodies**

The basic etiological classification of foreign bodies in the ear canal is into inanimate (cotton wool, remainders of cotton swabs and toothpicks, toy parts, or the like) and animate bodies (flies, earwigs, ticks, butterflies, and the like).

Symptoms of a foreign body in the ear canal are a feeling of fullness, pain, and hypoacusis. If the foreign body is animate, the patient can feel unpleasant sensations like buzzing, humming, or vibration, which are usually upsetting. If the foreign body is not removed in time, a discharge appears along with an inflammatory reaction of the surrounding tissue, and sometimes even skin erosions.

The treatment of foreign bodies requires their extraction. Animate foreign bodies should first be benumbed (with an oily solution, alcohol, or ether instilled into the ear canal). Ticks are particularly dangerous as they should be removed entirely to prevent further complications. The removal of foreign bodies is usually performed by rinsing or ideally under an otomicroscope. Caution is required to avoid eardrum rupture and additional lesions due to careless manipulation.

**Figure 6.** Foreign body in the ear canal



**Table 2.** Foreign bodies in the ear canal – symptomatology and treatment procedure

<b>FOREIGN BODIES IN THE EAR CANAL</b>	
<b>Cause/symptoms</b>	<b>Procedure/therapy</b>
<ul style="list-style-type: none"> <li>• cotton swabs, insects, and other</li> <li>• discomfort, pain, obstruction, buzzing</li> <li>• complications (infections, skin erosion)</li> </ul>	<ul style="list-style-type: none"> <li>• rinsing/aspiration</li> <li>• extraction</li> <li>◇ <b>refer to ENT</b></li> </ul>

## 1.7. Inflammation

### 1.7.1. Outer ear

**Ear canal inflammation.** The most common emergencies, especially during summer, include (*diffuse*) *ear canal inflammations*, which are accompanied by severe pain (due to the close contact between the skin and the adjacent bone), discharge and flakes, and ear obstruction. Due to pain intensity, these inflammations require urgent analgesic treatment and proper topical therapy. Before the application of various warm dressing pads or ear drops, it is necessary to clean the ear canal properly (hygiene with a syringe or otomicroscope). If the eardrum cannot be visualized and the inflammation is severe and accompanied by fever, peroral antibiotic therapy is necessary along with the topical one. This inflammation is enhanced by moisture, various traumas (scratching and scraping of the ear canal), and improper topical therapy (e.g. various aggressive antiseptics, instilling inappropriate substances like houseleek, and the like). The basis of therapy is a proper topical (and systemic if necessary) therapy described previously.

If the symptoms during ear canal inflammation progress in the form of vertigo or severe hypoacusis, the propagation of inflammation toward the inner ear should be suspected and the patient should be referred to an ENT specialist to prevent complications (e.g. labyrinthitis).

**Complications and severe ear canal inflammation.** Special attention is always necessary with inflammations in diabetics, who can have a reduced pain sensation due to diabetic polyneuropathy with lesser pronounced symptomatology and often visit their physician with an already advanced stage of the disease. Therefore, diabetes should be excluded in the evaluation of a patient with prolonged otorrhea. One of the most severe forms of ear canal inflammation is the so-called malignant otitis externa, which is more common in diabetics and immunocompromised patients. During malignant otitis externa, the infection spreads to bony structures of the temporal bone, with the possibility of further propagation into the surrounding structures. This condition is known as osteomyelitis of the cranial base and can progress without being recognized. It is accompanied by cranial nerve defects, and fatalities are not infrequent. The most common cause is *Pseudomonas aeruginosa*, which is why therapy is based on the systemic application of antipseudomonal antibiotics for several months, and sometimes surgical intervention is required (debridement of necrotic parts).

**Other outer ear inflammations.** Except for the most common (diffuse) ear canal inflammation, localized inflammations can also occur in patients, and the most common ones are **furuncles** in the ear canal (the so-called *otitis externa circumscripta*). If antibiotic treatment (it is advised to cover

staphylococcus as the most common pathogen) is not efficient after 1 – 2 days, incision and evacuation of the purulent content should be performed.

***Impetigo*** is a superinfection caused by staphylococcus or streptococcus that occurs after intense scratching or cleaning of the ear, most commonly in children.

***Erysipelas*** is a more serious streptococcal infection with propagation of skin infection to the lymphatic system. It is manifested by local lymphadenopathy, fever, and general algic syndrome. It requires a timely antibiotic treatment to prevent sometimes rapid spread of the disease and possible complications.

A special form of outer ear inflammation is ***hemorrhagic otitis***, which is accompanied by the formation of hemorrhagic bullae. These are mostly viral inflammation (it can occur in flu), but antibiotics are often prescribed to prevent secondary bacterial infections. The patient should be familiarized with the importance of strict hygienic measures and to instill only sterile antibiotic drops in the ear canal. The patient should also be explained that bloody discharge may appear in the ear canal if the hemorrhagic bulla erupts (which usually causes the patient's distress).

**Auricular inflammation.** Complications from auricular injuries and infections also include inflammation of the perichondrium and cartilage structures (lat. perichondritis auriculae), which, if not treated timely and properly, can cause permanent deformities to the auricle due to cartilage decay (which does not have its own circulation and is fed by capillarity from the skin). Perichondritis should be considered in the case of positive medical history to trauma, previous surgical procedure, burns, and also after careless placement of earrings or acupuncture. In case auricular perichondritis is suspected, which is generally manifested by a painful, dark red, and swollen auricle, it is necessary to start broad-spectrum antibiotic therapy as soon as possible, most commonly third-generation fluoroquinolones or cephalosporins (to cover *Staphylococcus aureus* and *Pseudomonas aeruginosa* as the most common pathogens). Sometimes parenteral therapy is needed. If medical therapy is not efficient, surgical resection and debridement of necrotic cartilaginous parts are necessary to prevent the propagation of the infection.

**Obturing cerumen.** In addition to very common ear canal inflammations, patients seek medical attention, especially during summer, due to pain caused by the accumulation of cerumen (earwax). Cerumen has a protective function and is excreted by a special form of sebaceous glands found only in the ear canal (*gll. ceruminosae*). Cerumen expands in contact with water and if produced increasingly (which depends on individual predisposition), it can create pressure on the ear canal walls. Swimming in the sea or swimming pools during summer is the reason for more



frequent visits to the physician due to this symptomatology at this time of year. Therefore, the primary care physician should be able to properly and independently remove cerumen (see the chapter on aural toilet).

For the *purpose of prevention*, it should be explained to patients that using classic cotton swabs usually leads to the accumulation of cerumen and a mixture of dead epithelial cells behind the natural narrowing of the external auditory canal, and the formation of the so-called *obturating cerumen*. If the ceruminous plug is extremely hard and there is a risk of eardrum rupture during ear irrigation, it is not advisable to force hygiene (especially because the differential diagnosis may include the so-called epidermal plug – cholesteatoma of the ear canal, which sometimes affects bony structures as well). The patient is recommended to instill softening agents for 1 – 2 days (e.g. hydrogen peroxide, paraffin oils, or the like) and to perform aural toilet after the ceruminous plug is softened. If the hygiene is still impeded after that, the patient should be referred to a specialist for an otomicroscopical toilet.

**Remember:**

When cleaning cerumen, the following should be forbidden:

- using toothpicks, hairpins, and similar objects due to the risk of eardrum rupture and ear canal lesions
- various houseleeks, bubble baths, and the like due to the disturbance of the physiological flora and pH, which enhances infections.

### 1.7.2. Middle ear

**Acute middle ear inflammations** are more common in children than in adults, and are one of the most common reasons why concerned parents visit the physician.

The Eustachian tube is shorter in young children (13 mm, as opposed to 31 – 38 mm in adults) and more horizontally placed (10° in relation to the cranial base, as opposed to 45° in adults). It contains multiple goblet cells that produce a very thick viscous secretion, and the tubal isthmus is not yet formed and opens wide during contractions of the soft palate. Middle ear inflammation is especially common in children with enlarged epipharyngeal lymphatic tissue (pharyngeal and tubal tonsils known in the wider population as the “third tonsil”). It contributes to the propagation of the infection from the nose and epipharynx into the middle ear and impedes its ventilation. Along with immature immunity, it is the cause of more frequent middle ear inflammations in the pediatric population.

The most frequent symptom is pain. A young child expresses otalgia by holding or pulling their ear, by “nodding” their head, crying, and crankiness. Beside the local symptoms, there are also general symptoms of infection such as fever, lack of appetite, languor, insomnia, and sometimes even somnolence. The smaller the child, the more pronounced the general symptoms are.

It is this nonspecificity of symptoms that sometimes hinders diagnostics. This is why each febrile young child requires an otoscopic examination to exclude otitis as a cause of fever. In typical inflammation, the otoscopic finding shows a bulging eardrum as well as redness and hyperemia of the eardrum with reduced motility.

In 80% of cases, acute middle ear inflammation spontaneously regresses throughout 3 – 8 days, because in most cases it is a viral infection without the need for antibiotics. Therefore antibiotics should not be routinely prescribed. In bacterial infections, the type of antibiotic depends on the pathogen. The most common pathogens of acute middle ear inflammation in children are: *Streptococcus pneumoniae*, *Haemophilus influenzae*, and *Moraxella catarrhalis*. Others include group A streptococcus, *Staphylococcus aureus*, and gram-negative bacilli.

There are basic guidelines for the treatment of middle ear inflammation in children. Depending on the child’s age and the severity of the clinical picture, the following is recommended:

1. administration of analgesics and antipyretics (if the temperature is higher than 38 °C);
2. nasal toilet and nasal drops (vasoconstrictors for 5 days, topical antibiotics for up to 10 days);
3. if the child is younger than 6 months or has a serious disease, it is recommended to start antibiotic therapy immediately;
4. If the child is older than 6 months and has mild disease, close monitoring is necessary, but in the case of a serious disease, it is recommended to start antibiotic therapy immediately.

The increasing mitochondrial resistance of pneumococci to amoxicillin has led to changes in the initial approach, which is why in recent years amoxicillin is recommended in a double dose (80 – 90 mg/kg in 2 – 3 doses, up to a maximum of 1500 mg) for ear infections. Azithromycin and erythromycin are indicated for allergy to penicillin. In the case of severe inflammation, treatment can be initiated with second-line antibiotics according to guidelines (e.g. co-amoxiclav, cefpodoxime).

Middle ear inflammation **in adults** is accompanied by the same local symptoms as in children, although more commonly in a milder form and

with less pronounced general symptoms of the disease. Unlike acute inflammation, chronic middle ear inflammation is much more common in adults; especially with immunodeficiency and diabetes (additional literature is recommended for more details on various forms of chronic middle ear inflammation).

**Remember:**

Frequent middle ear inflammations in childhood require examination of the epipharynx and exclusion of the third tonsil (adenoid vegetations) as their cause. As generally in otorhinolaryngology, ipsilateral unilateral repeated inflammation requires greater caution! Frequent unilateral inflammations in adulthood with retracted eardrum and hypoacusis raise suspicion of dysfunction of the auditory tube potentially caused by a tumorous process of the epipharynx.

**Remember:**

Patients often treat middle ear inflammations incorrectly by administering prescribed drops in the ear canal, which is why it is necessary to explain that if the eardrum did not rupture, such administration of drops is ineffective and that these drops should be instilled in the ear canal only in the case of eardrum rupture or ear canal inflammation!

**Table 3.** Differences in topical therapy with outer ear otitis and middle ear otitis

<b>OTITIS MEDIA</b>	<b>OTITIS EXTERNA</b>
<p>Nasal drops: decongestant + topical antibiotic + rinsing and nasal toilet.</p> <p>Note: Apply ear drops only in the case of discharge (a sign of perforation)!</p>	<p>Ear drops: topical antibiotic and/or antiseptic.</p>

**Complications of acute and chronic middle ear inflammation:**

As stated above, the classic symptoms of a “common” ear inflammation include a feeling of fullness or congestion in the ear, pain, impaired hearing, and discharge in the case of eardrum perforation.

Based upon anatomy, a middle ear infection can spread towards the inner ear, mastoid bone, surrounding vascular structures, neck muscles, as well as intracranially.

Middle ear inflammations include the inflammation of all temporal bone air spaces. Besides tympanic cavity (and all auditory ossicles incorporated in it) and the eardrum, they also include mastoid cells and the Eustachian tube. Each inflammation in the tympanic cavity is accompanied by some degree of mucosal inflammation of mastoid cells, which are shown as a blur on radiological imaging. But if lysis of mastoid bony septa occurs, the term mastoiditis is used. It implies otitic process and the need for urgent surgical intervention.

Long-term, recurrent, and severe middle ear inflammation can lead to gradual damage to the auditory ossicular chain, as well as the eardrum.

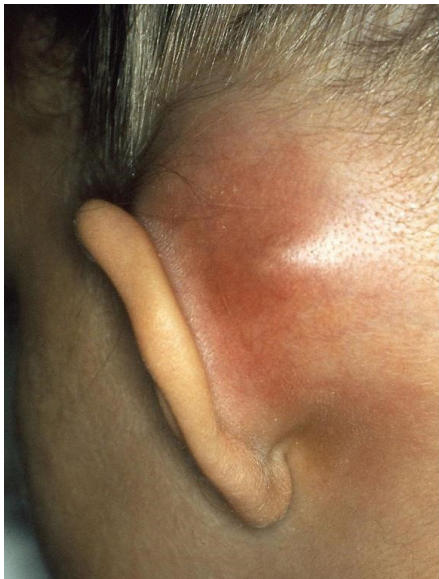**Table 4.** Complications of middle ear inflammation – symptomatology and treatment procedure

<b>COMPLICATIONS OF MIDDLE EAR INFLAMMATION</b>	
<b>Most common complications</b>	<b>Procedure/therapy</b>
<ul style="list-style-type: none"> <li>• medical history regarding ear inflammation – progression of symptoms/complications</li> <li>• mastoiditis (more often in children!) – retroauricular swelling/redness / lowering of the upper ear canal wall</li> <li>• intracranial complications (meningitis/ cerebral abscess) – occurrence of neurological symptoms</li> <li>• facial nerve paresis</li> </ul>	<ul style="list-style-type: none"> <li>◇ <b>urgently refer to ENT</b></li> <li>• antibiotics parenterally</li> <li>• MSCT diagnostics</li> <li>• surgical procedure</li> </ul>

**a) Mastoiditis** is a complication of the middle ear inflammation in the form of temporal bone osteitis. In their medical history, the patient usually reports an ear inflammation that lasts for several days and is accompanied by persistent fever and progression of otalgia. In classic mastoiditis, clinical examination reveals postauricular erythema and retroauricular pain, sometimes even protrusion of the auricle and otoscopically visible lowering of the upper ear canal wall. The diagnosis is confirmed by radiologically established osteitis and temporal bone lysis. Special attention should be given to diabetics with prolonged middle ear inflammation, who do not have a pronounced symptom of pain due to diabetic polyneuropathy. Particular attention should also be given to infants and young children, who often have a disorder of the general condition (like febrility of unknown etiology), and in whom nonspecific symptoms of other organs (such as digestive disorders) can occur as well, which can be misleading for the clinical picture. Therefore, any febrility in a child until the second year of life requires an otoscopical examination.

Treatment of mastoiditis, with confirmed osteitis, besides medical therapy requires surgical intervention. It is therefore important to recognize its signs and refer the patient to an ENT specialist.

**Figure 7.** Mastoiditis



**Table 5.** Differential diagnostics of the outer ear otitis and mastoiditis

<b><i>Otitis externa</i></b>	<b><i>Mastoiditis</i></b>
<ul style="list-style-type: none"> <li>• pre- and/or infra-auricular pain, sometimes even enlarged and painful pre- and/or infra-auricular lymph nodes</li> <li>• narrowed ear canal, irritated skin with discharge, flakes, and deposits</li> <li>• sudden pain in the ear, more often during summer, after exposure to water, wind and draft</li> <li>• a feeling of pressure and fullness in the ear, with progressive hearing loss</li> </ul>	<ul style="list-style-type: none"> <li>• retroauricular pain (sometimes even erythema and protrusion of the auricle) in the mastoid region</li> <li>• worsening of symptoms of the middle ear inflammation</li> <li>• confirmation by radiological imaging – lysis of mastoid bony septa</li> </ul>

**b) Labyrinthitis** is the spread of the inflammation from the middle to the inner ear. It is manifested by vertigo, insecurity during walking, nausea,

sometimes even vomiting, nystagmus to the healthy side (vestibular apparatus affected), and worsening of hypoacusis and tinnitus (auditory apparatus affected). Audiological evaluation and therapy are definitely necessary, sometimes neurological as well, to avoid permanent consequences and sometimes even deafness. Therefore, any middle ear inflammation with suspected labyrinthitis should be referred to a specialist evaluation.

**c) Intracranial complications** (meningitis, extradural and subdural abscesses, cerebral and cerebellar abscesses). Along with the middle ear inflammation, the appearance of neurological symptoms must raise suspicion of the intracranial spread of inflammation, which can lead to serious complications such as cerebral abscesses or meningitis. Therefore, neurological symptoms (during or after middle ear inflammation) require evaluation in specialized facilities. Therapy includes a multidisciplinary approach with an otorhinolaryngologist, neurologist, and, if necessary, neurosurgeon.

**d) Facial nerve paresis/palsies.** Signs of peripheral facial nerve **paresis** may appear in severe middle ear inflammations: the patient cannot close their eye or wrinkle their forehead (unlike central paresis where the forehead mimicking is preserved), the mimic of the affected side of the face is weakened and the lip corner is lowered. The symptoms usually regress with antibiotic and corticosteroid therapy. In the case of their persistence or chronic processes, the patient should be referred to a specialist facility for possible surgical treatment, i.e. exploration and decompression of the nerve.

**e) Other otogenic complications include neck abscesses, thrombophlebitis, and the like.** Any suspicion of the aforementioned complications certainly requires specialist evaluation and urgent treatment.

**f) Although not considered an emergency, complications of middle ear inflammation also include eardrum perforations that do not heal and ossicular chain defects, which should be surgically treated with different types of tympanoplasty (see additional literature for more information).** It is important to differentiate central from peripheral perforations. Central perforation includes an eardrum defect that does not reach the bony margin, as opposed to a peripheral perforation that reaches the margin of the eardrum and signifies an osteitic process, thus requiring greater caution and more aggressive therapy.

#### **Remember:**

When deciding on surgery, the following should be kept in mind:

- hearing recovery (it is possible to recover the conductive component of hearing loss)
- enabling normal activities and closing the defect to stop the exposure of the tympanic cavity to the external noxae.

Therefore, the procedure is always recommended in younger people, whereas in older people the decision is made depending on the comorbidities and the severity of defects and symptoms. The procedure is undoubtedly recommended in the case of osteitic processes due to possible complications.

Like malignant *otitis externa* is a special type of outer ear inflammation, there is also, due to possible complications, a special type of chronic middle ear inflammation called cholesteatoma (***otitis media cum cholesteatoma***), for which additional literature is advised.

### 1.7.3. Inner ear

Inner ear inflammation is discussed in the subchapter on emergencies in audiovestibulology.

## 1.8. Emergencies in audiovestibulology

### 1.8.1. Isolated hearing loss

**Sudden deafness** in otology implies sudden (within 3 days) perceptive hearing loss of 30 dB or more in three consecutive frequencies without apparent cause. It is usually a unilateral lesion, and although it can appear at any age, it predominantly affects younger adults. Perceptive hearing loss, and sometimes deafness, appears suddenly, in an otherwise healthy subject, usually in the morning when awakening. It can be accompanied by tinnitus, feeling of fullness in the ear, and sometimes even vertiginous disorders. This condition excludes conductive hearing loss and hearing losses that occur after traumas or other known causes like anticoagulant therapy, metabolic diseases, hematological diseases (leukemia and the like). The viral or vascular geneses of the aforementioned conditions are most often mentioned in literature, although there is sometimes a lack of concrete evidence. Vestibulocochlear nerve neurinoma nerve should definitely be excluded in the differential diagnostics of perceptive hearing loss. Clinical examination reveals a normal eardrum and ear canal. The tuning fork test is a rough indicator for an outpatient physician (Weber lateralizes to the healthy ear) before a detailed audiological evaluation, which is necessary for any sudden hearing loss. Laboratory evaluation is also necessary (differential blood count, exclusion of viral origin by evaluating viral antibodies and the like, coagulation factors...).

The majority of cases of sudden hearing loss would probably recover spontaneously even without therapy. However, the evolution of sudden deafness is unpredictable and can range from complete hearing restoration to more or less permanent hypoacusis. Being that this usually affects

younger adults in whom hearing impairment represents a significant handicap in everyday life, it is important, as with sudden blindness, to start the standard therapeutic protocols as soon as possible (preferably within 72 hours). Therapy includes corticosteroids and in equipped centers, hyperbaric chambers.

**Table 6.** Sudden deafness – symptomatology and treatment procedures

<b>SUDDEN DEAFNESS</b>	
<b>Symptoms</b>	<b>Procedure/therapy</b>
<ul style="list-style-type: none"> <li>• sudden perceptive hearing loss</li> <li>• vertigo and/or tinnitus ±</li> <li>• usually unilateral</li> <li>• <b>urgently consult physician! (72 h)</b></li> </ul>	<ul style="list-style-type: none"> <li>• otoscopy – normal finding</li> <li>• tuning fork test – Weber lateralizes to the healthy ear</li> <li>◊ <b>refer to ENT</b></li> <li>• audiological examination and laboratory findings</li> <li>• high doses of corticosteroids parenterally and later perorally</li> <li>• intratympanic administration of corticosteroids if parenteral administration is contraindicated due to comorbidities</li> <li>• hyperbaric chamber</li> </ul>

### 1.8.2. Isolated vestibular disorders

Sometimes severe vertigo is the reason for concerned patients to visit emergency rooms. The two most common etiologies leading to isolated vestibular disorders are benign paroxysmal positional vertigo (BPPV) and vestibular neuronitis.

**Benign paroxysmal positional vertigo (BPPV)** is also called cupulolithiasis of the vestibular system and is caused by the displacement of otoconia into semicircular (usually posterior) ducts. It is manifested by short and severe vertiginous disorders, provoked by a change in the body position in relation to gravity (from a supine to the sitting position or vice versa, by bending forward, and the like), and sudden changes in the position of the head, especially with the extension of the neck (e.g. reaching for objects on top shelves, the so-called “top-shelf syndrome”). Vertiginous disorders can be accompanied by nausea and vomiting.

In addition to typical medical history, the Dix-Hallpike maneuver is also used in the orientation examination (which, if positive, confirms the diagnosis of BPPV – additional literature is recommended for details). The basics of therapy are the so-called “repositioning” (liberatory) maneuvers, of



which the Epley maneuver is the most effective (see additional literature for other maneuvers like Semont and details about its performance). In case pharmacotherapy is used for relieving symptoms, vestibular suppressants and antiemetics (antihistamines, benzodiazepines, and anticholinergics) are used. These drugs should be used as briefly as possible, in the first several days with severe nausea and vomiting, and long-term administration is contraindicated due to their sedative effect and even possible delay in central compensation of the vestibular deficit.

**Vestibular neuronitis** (inflammation of the vestibular branch of the vestibulocochlear nerve) is characterized by sudden vertigo accompanied by spontaneous horizontal nystagmus to the healthy side (fast component) and the absence of tinnitus and hypoacusis. It sometimes occurs as part of respiratory infections and febrile conditions. It should not be confused with labyrinthitis, in which both the vestibular and auditory organs are affected, and hypoacusis and tinnitus are present as with Ménière syndrome and disease. The diagnostic basis is the caloric test, which confirms unilateral vestibular hyporeflexibility (additional literature is recommended for details).

First-line treatments are sedatives like benzodiazepines and central antiemetics like thiethylperazine. Antivertiginous medications like betahistine have a slow onset of action and therefore are redundant in the acute phase. The symptoms slowly subside over several days to several weeks by central compensation, but balance disorders persist in a certain number of patients, especially with certain movements as a sign of permanent vestibular damage. Physical therapy and rehabilitation are recommended in these cases. As with the treatment of BPPV, it is necessary to limit and cancel the use of antivertiginous and sedative drugs as soon as possible because they sometimes delay central compensation. Sometimes in acute phases, severe vomiting and dehydration may require hospital treatment due to parenteral administration of drugs and rehydration by intravenous therapy.

### 1.8.3. Combined audiovestibular disorders

The differential diagnostics of more common causes of vertigo includes **Ménière syndrome**, which, unlike BPPV and neuronitis, also involves associated symptoms of the affected auditory apparatus. The classic triad of symptoms includes recurrent vertiginous crises accompanied by tinnitus and hypoacusis. It certainly requires specialist audiological evaluation to which a patient with these disorders should be referred, especially when it appears for the first time. A considerably more serious cause of associated symptoms of hearing and balance impairment is the aforementioned **labyrinthitis**, which can result in permanent, more or less pronounced damage, and even severe hypoacusis and deafness. In addition to inflammatory causes, toxic and especially iatrogenic damage to the labyrinth are also possible.

**Caution!**

**Toxic damage** to the vestibular and auditory senses is sometimes a consequence of ototoxic drugs. Topical administration of such drugs requires special caution, especially in chronic ear inflammations with eardrum perforation!

Further diagnostics is necessary to exclude other causes of vertigo (especially tumor of the vestibulocochlear nerve, central causes, and the like). Additional literature is recommended for more details and other differential diagnoses of vertiginous symptomatology.

**Table 7.** Differential diagnosis of neuronitis and labyrinthitis

<b>Neuronitis</b>	<b>Labyrinthitis</b>
<ul style="list-style-type: none"><li>• severe vertigo</li><li>• nausea/vomiting</li><li>• spontaneous horizontal nystagmus to the healthy side (fast component)</li><li>• absence of hypoacusis</li><li>• absence of tinnitus</li></ul>	<ul style="list-style-type: none"><li>• vestibular apparatus affected</li><li>• vertigo, insecurity during walking</li><li>• nausea, sometimes even vomiting</li><li>• nystagmus to the healthy side (fast component)</li></ul> <p><b>auditory apparatus affected</b></p> <ul style="list-style-type: none"><li>• hypoacusis and tinnitus</li></ul>

**Remember:**

- Severe vertiginous disorders should be evaluated with a rapid orientation examination and, if the evaluation shows BPPV or vestibular neuronitis, symptomatic therapy can be initiated immediately to alleviate the patient's discomfort.
- Limit the symptomatic therapy to several days so that the central compensation is not delayed.
- It is subsequently recommended to refer the patient to a specialist for further evaluation.
- Any vertigo requires the exclusion of tumor processes of the vestibular pathways and centers!

## 2. Rhinology

### 2.1. Brief anatomical-functional reminder

There are numerous functions of the nose whose role in our health is often unrecognized, underestimated, and unknown to patients. The nasal cavity is the initial part of the respiratory tract. The respiratory function of the nose is directly related to its protective role and the sense of smell. As it passes through the nasal cavity, the inhaled air is cleansed of dust and microorganisms, moistened and warmed, thus preparing to enter the lower parts of the respiratory airway (larynx, trachea, bronchi, and lungs) but also through the oropharynx and hypopharynx. If the nose is clogged and we breathe through the throat, the unprepared cold air from the environment can induce pharyngeal and oral diseases (various types of throat pain), even caries and more frequent problems with the lower respiratory airway. Tears drain into the nasal cavity, which is also important for the healthy functioning of the eye. The air from epipharynx enters the middle ear through the Eustachian tube, and normal nasal breathing is essential for maintaining correct pressures in the middle ear. It also plays a role in phonation due to its resonating property.

Therefore, the nose is somewhat the central part of this anatomical region and nasal health is also important for the health of the sinuses, ear, throat, lungs, and even the eye.

The external nose is made of the nasal pyramid consisting of nasal bones and cartilage. The nasal valve is the boundary between the vestibulum (in which the skin is located and therefore all skin diseases are possible in this area – from furuncles to carcinoma) and the nasal cavity (which contains the mucosa with the respiratory epithelium – pseudostratified columnar ciliated epithelium). The mucosa has a leading role in the protective function of the nose. Good ciliary motility is extremely important because ciliary movement triggers the mucus and removes the inhaled particles, thus preventing their retention in the nose and consequently a possible inflammatory process.

The nasal cavity forms a unique unit with the paranasal sinuses, which together represent the pneumatic spaces of the viscerocranium. They can be more or less developed, and generally stronger pneumatization is a risk factor for inflammatory processes and possible complications during surgical procedures due to the possibility of deficiency and/or protrusion of blood vessels and nerves in the osseous walls of the sinuses. It should be emphasized that not all paranasal cavities develop simultaneously. In infants, we find the beginnings of the maxillary and ethmoid sinuses, which gradually develop during childhood. Their inflammation, due to close contact with the surrounding structures (especially the ethmoid sinus with the

ocular cavity), can lead to complications and should be recognized and treated in timely manner. The inflammation of the ethmoid sinus is one of the potentially most dangerous inflammations in children due to the possibility of propagation to the ocular structures. It is only later and more intensely after the age of 6 that the frontal and sphenoid sinuses develop. Therefore, it is unnecessary to do a sinus X-ray for a frontal headache in a young child who has no frontal sinuses developed yet. In these cases, the causes should be primarily sought in neurological problems.

Despite the classic anatomical classification into maxillary, ethmoid, frontal, and sphenoid sinuses, functional classification into anterior and posterior sinuses is more important, depending on their drainage pathways. Specifically, the anterior sinus group, which includes the maxillary and frontal sinuses and anterior ethmoid cells, is drained between the middle and inferior nasal turbinate, and patients typically report leakage of nasal secretion. On the other hand, the posterior sinus group, which includes posterior ethmoid cells (separated from anterior ethmoid cells by the basal lamella of the middle nasal turbinate) and the sphenoid sinus, drain into the epipharynx, and their basic symptomatology is the postnasal drip.

Its ability to provide a high degree of warming and moisturizing the air flowing through the nasal cavity is conditioned by the complex architectonics of the structure of the nasal meatus and paranasal sinuses, and the pronounced vascularization with numerous arteriovenous anastomoses, which makes the nose one of the most vascularized organs in the body (nasal vascular structures are described with more detail in the chapter on epistaxis).

The nasal cavity is richly innervated by adrenergic, cholinergic, and sensory nerves, which are responsible for numerous protective reflexes but also for the cascade reaction and symptoms of rhinitis.

Due to the anatomical connection among nasal veins through the ophthalmic vein and through the pterygoid plexus with the cavernous sinus, inflammatory processes may spread to these regions, which is of great clinical importance. Therefore, it is important to warn patients not to “squeeze” pimples and furuncles in the nasal region because of the possibility of propagation of inflammatory processes.

When air enters the olfactory zone, it stimulates sensory cells of the neuro-olfactory epithelium and the perception of smell. This is how the nose provides a very important (though often neglected) function of smell. Namely, odors protect us from harmful and dangerous substances in our environment (e.g. the smell of gas) and instinctively drive us away from unpleasant odors, which are often toxic.

Olfactory neural cells are characterized by the fact that the bipolar neuron produces dendrites, which exit the mucosal surface, while leading the

axon into the brain, thus representing a sort of “window into the brain” – a unique part of our body in which neural cells form communication between the central nervous system and the outside world. The olfactory bulb is connected to the limbic system, hypothalamus, and the autonomic nervous system. Odors, therefore, have a significant effect on our body and emotions.

**Remember: Anatomical specificities**

It is important to emphasize that inflammation of the sphenoid sinus can lead to serious complications due to its anatomical relationship with structures such as the internal carotid, cavernous sinus, optic nerve, and pituitary gland.

Young children breathe differently from adults and can not breathe through the mouth due to the length of the soft palate. Therefore, for example, bilateral choanal atresia is a neonatological emergency and is potentially life-threatening.

## 2.2. Examination of the nose and paranasal sinuses

During the examination of a rhinological patient, two approaches should be considered:

- anatomical – integrity of structures (clinical examination and radiological evaluation)
- functional – defects in function (rhinologically, assessment of nasal patency and smell).

This examination is supplemented by additional diagnostic methods (laboratory tests and, if necessary, additional multidisciplinary evaluation).

### 2.2.1. Anatomical structures

#### a) Clinical examination

Inspection of the external nose begins by checking the integrity of the skin and nasal pyramid, by paying attention not only to obvious laceration wounds but also to fractures, hematomas, and the like. This is followed by the examination of nasal cavities, and anterior rhinoscopy is usually performed outpatiently and should be mastered by every general physician. Before the exam, the patient must blow their nose properly and the examination is more effective if performed after instilling vasoconstrictive drops. It is important to exclude hematomas after traumas, if existing, to determine the origin of epistaxis, to notice various inflammations of the vestibulum, purulent secretions, foreign bodies, tumorous formations, and the like.

After rhinoscopy, palpation of the nasal pyramid and branch exits of the trigeminal nerve along with the direct percussion of the paranasal sinuses represent the basis of the outpatient examination of a rhinological patient.

Nasal endoscopy provides better visibility of nasal structures than classic anterior and posterior rhinoscopy and enables analysis of the ostiomeatal unit as well as of the epipharyngeal area. In addition, endoscopy also enables hygiene, irrigations, and aspirations along with the microbiological analysis of secretion. It is possible to take a bioptic material and perform small procedures such as capillary coagulation and the like.

Flexible endoscopes enable examination of the entire upper respiratory tract. Besides the nose and epipharynx, they also serve for visualization of pharyngolaryngeal structures.

## **b) Radiological examinations**

Radiological evaluation is important for any nose injury because it can exclude or confirm fractures for treatment purposes but also for potential subsequent forensic expertise.

A basic X-ray is used to observe fluid levels as a confirmation of acute sinusitis, but this method is often superfluous because therapy is usually given based on symptomatology, whereas suspected complications require more advanced imaging methods (such as MSCT). The classic X-ray is limited by very poor visualization of ethmoid and sphenoid sinuses, and the diagnostic accuracy of such a method in sinusitis varies between 30% and 80%.

### **2.2.2. Function evaluation**

Rough nasal patency can be evaluated by placing a mirror under the nostrils and observing its fogging as a confirmation of breathing through the nose. Rhinomanometry, which belongs to the specialist domain, provides significantly more accurate data on nasal patency.

Assessment of the sense of smell is not a part of the emergency evaluation, but it complements the basis of the rhinological examination. Additional literature is advised for details.

### **2.2.3. Laboratory and other interdisciplinary tests**

In addition to clinical exam, further tests are also required in emergencies, such as **laboratory blood tests** (DBC, ESR, CRP, GIB, Na<sup>+</sup>, K<sup>+</sup>, Cl<sup>-</sup>) in inflammatory conditions and coagulation factors in the case of severe bleedings and traumas, as well as preoperatively. Sometimes multidisciplinary evaluation is also required (neurosurgical, maxillofacial, and the like), especially in the case of severe head injuries.

## 2.3. Rhinological symptomatology

Diseases of the nose have the following basic symptoms:

- bleeding from the nose (epistaxis)
- runny nose (rhinorrhea)
- sneezing
- itchy nose (pruritus)
- “clogged” nose (nasal obstruction)
- impaired sense of smell (hyposmia)

Other symptomatology related to diseases of the nose includes:

- headache (but only 5% of headaches are of rhinological etiology!)
- symptoms of surrounding organs (cough, sore throat, and other symptoms of the lower respiratory airway and middle ear).

It should be emphasized that common allergic rhinitis or rhinosinusitis is usually accompanied by bilateral nasal discharge, whereas unilateral discharge requires more attention and evaluation, as well as any other asymmetry in the otorhinolaryngological region. For example, in differential diagnostics of unilateral purulent rhinorrhea in a child, a long-standing, unrecognized foreign body should be suspected, whereas tumorous formations and odontogenic sinusitis should be excluded in adults. In clear unilateral rhinorrhea, liquorrhea should always be ruled out and the patient should be asked about possible head traumas (the possibility of cerebrospinal fluid leak, not only in sinus trauma but also in temporal bone trauma through tubal communication).

Based on the clinical picture and basic symptoms, a good physician must assess the severity of a disease and its possible complications during the primary evaluation of a patient and, accordingly, determine the proper therapy.

### 2.3.1. Epistaxis

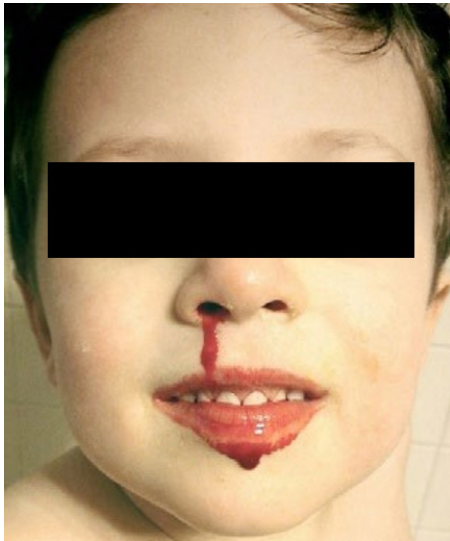The most dramatic and sometimes life-threatening emergency in rhinology is bleeding from the nose or epistaxis. The vascular structures of the nose are poor in contractile fibers, which is the reason bleeding can occur even with minor injuries. The nasal mucosa is richly vascularized through external and internal carotid arteries, with an extensive system of anastomoses.

Knowledge of anatomy and vascularization of the nose is important when stopping bleeding. For example, the external carotid artery supplies the nose through one of its branches, the sphenopalatine artery, which enters the nasal cavity through the sphenopalatine foramen behind the posterior

pole of the middle nasal turbinate (the site we seek for possible coagulation during severe epistaxis).

Branches of the internal carotid artery are anterior and posterior ethmoid arteries, which enter the nasal cavity through the ethmoid roof. In rhinosurgery, it is especially important to know the position of the anterior ethmoid artery, which can get damaged in various injuries, i.e. external traumas and iatrogenic procedures. Particularly dangerous is the retraction of the artery into the orbit and, consequently, a very serious hematoma of the eye. This hematoma can damage the patient's vision due to stretching of the optic nerve, which is why urgent intervention is required to avoid blindness.

**Figure 8.** Epistaxis in children

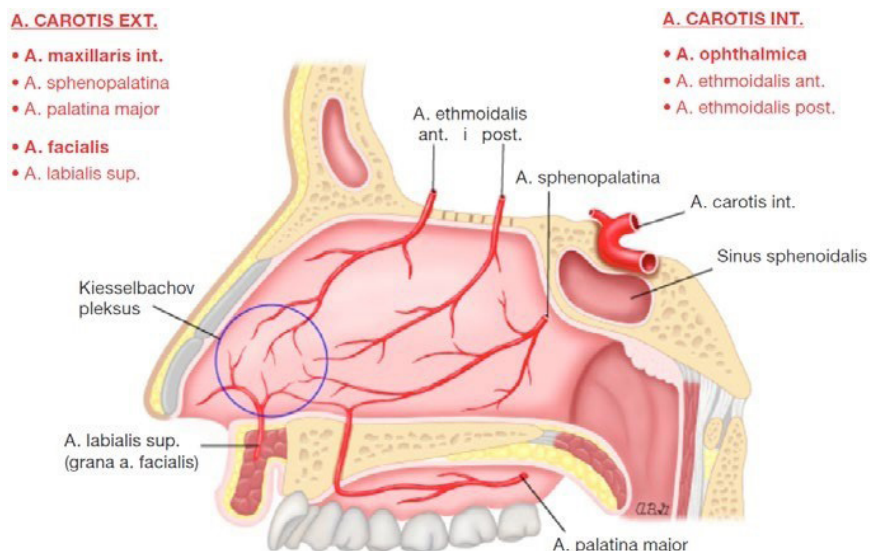


One of the first warning signs of vision impairment, except for hematoma and exophthalmos, is not recognizing the red color (the first visual field defect), so this should definitely be kept in mind. Remember: in any suspicion of optic nerve stretching, the physician should ask when taking patient's history, if they recognize the red color.

The most common bleedings in children and young people are the ones at the level of the arterial-venous capillary plexus of the anterior third of the nasal septum (the so-called Kiesselbach's locus). Kiesselbach's plexus represents the anastomosis of three arterial systems – anterior ethmoidal artery, sphenopalatine artery and facial artery. The bleeding site in elderly population is usually located in larger vascular structures of deeper parts of the nose.



**Figure 9.** Vascularization of the nose



Generally, epistaxis can be divided by the severity and presentation of the clinical picture into mild and severe. Mild epistaxis is characterized by less profuse bleedings, without consequences for the patient's general condition, and usually after nose blowing, anterior rhinoscopy reveals the bleeding site, which is most commonly located at the vascular site. Severe epistaxis is manifested by systemic signs and symptoms, including fear, pallor, tachycardia, and sweating. Although it is often caused by initial hypertension in particularly severe cases, signs of hypovolemic shock should be looked for. Sometimes the patient ostensibly calms down due to exhaustion, which does not mean their clinical condition is improved and is usually a prestage of shock.

In severe epistaxis, the basic treatment procedure includes:

- try to detect causes by taking patient's medical history properly
- assess the patient's general condition
- try to find the bleeding site (which is sometimes more difficult to determine with anterior rhinoscopy)
- stop the bleeding.

**It should be emphasized that it is always essential to stop the bleeding and that a thorough examination of causes and additional evaluation should only be done after primary care!**

Causes of epistaxis can be divided into systemic and local (table 8). There are two main systemic causes of epistaxis: hypertension and coagulation disorders. Local causes of epistaxis are most commonly various

inflammation of nasal mucosa, abuse of vasoconstrictors with consequent damage to the capillary plexus, injuries of the nasal mucosa, but also neoplasms that should definitely be excluded.

**Table 8.** The most common causes of epistaxis

<b>EPISTAXIS</b>	
<b>Most common systemic causes</b>	<b>Most common local causes</b>
hypertension coagulation disorders <ul style="list-style-type: none"> <li>• ask about alcohol and other hepatic diseases, use of anticoagulants, antiaggregants, nonsteroidal anti-inflammatory drugs, and the like</li> <li>• order laboratory tests for hepatic enzymes and coagulogram</li> </ul>	traumamucosal inflammation anatomical variations neoplasms abuse of vasoconstrictors other drugs and iatrogenic causes

Bleeding from the nostrils can be unilateral or bilateral, and the patient may also experience bleeding in the mouth. In history-taking, the patient should be asked about the duration and recurrence of bleeding episodes as well as possible episodes of vomiting blood in order to correctly assess the amount of blood lost.

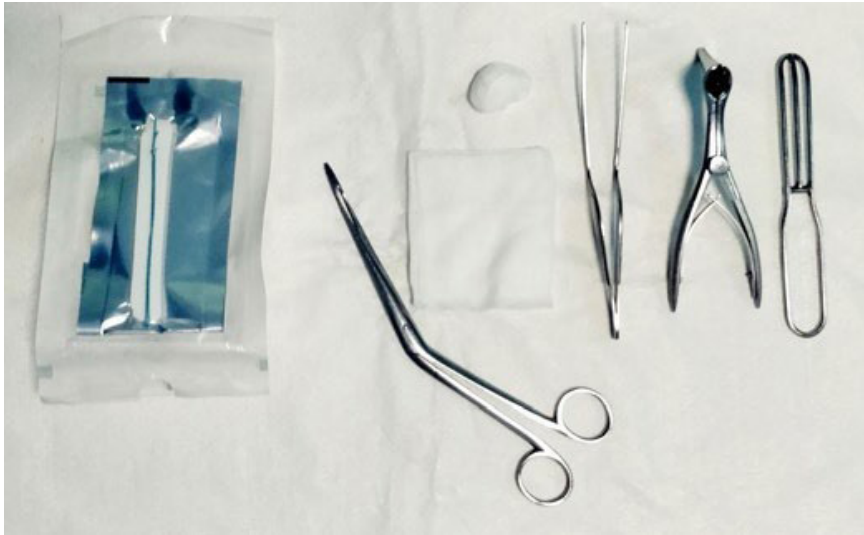Patients with epistaxis, as well as their escort, are usually very upset, so they should primarily be calmed down. Given that hypertension and coagulation disorders are the two most common causes of bleeding in elderly people, in whom bleedings are both more pronounced and dramatic, the first next step in evaluation is to measure blood pressure and, if necessary, lower it with sublingual administration of antihypertensives. This is followed by history-taking on coagulation disorders. The patient should be asked whether they use anticoagulants and antiaggregants (nowadays very commonly prescribed in cardiac patients whose incidence is steadily increasing) and nonsteroidal antirheumatics, which are often used for anti-inflammatory and antipyretic purposes and also lead to clotting disorders. Liver blood tests are recommended to exclude hepatic diseases.

Evaluation of recurrent epistaxis includes proper history-taking not only for potential causes (cardiovascular, hematological, hepatological, and iatrogenic) but also for risk factors (e.g. vascular stenosis, implanted stents, and the like), which can be exacerbated and potentially life-threatening in the context of epistaxis.

When providing first aid, the patient is placed in an upright sitting position with their head tilted forward, thus reducing blood dripping down to the

mouth and its swallowing and vomiting. It is necessary to firmly press the nasal wings to cause pressure on the anterior third of the nasal septum (compression of the Kiesselbach's capillary plexus for about 10 minutes, i.e. clotting time) and put a cold compress around the patient's neck to reduce blood flow to the head and nose. If the bleeding does not stop, the bleeding site is seeked.

**Figure 10.** Instruments for nasal packing



In case the anterior third of the nasal septum is bleeding, with visible dilation of the capillary plexus, it is possible to coagulate the capillaries (with solutions such as  $\text{AgNO}_3$  and the like or by electrocauterization), whereas bleedings from the deeper parts require tamponade, i.e. nasal packing (anterior and, if necessary, posterior). In order to achieve compression, the patient must blow their nose properly and remove any clots from the nose before the nasal packing. During the nasal packing, the patient's head is flexed with the chin on their chest, and the tampon is directed toward the epipharynx, following the bottom of the nasal cavity, never toward the cribriform plate and anterior cranial fossa (due to the possibility of dangerous lesions).

The bleeding usually stops after the anterior nasal packing; the patient is observed for about twenty minutes and then sent to home care. Before patient discharge, we check for blood in the sputum and use a spatula to check if fresh blood is still dripping from the epipharynx down the posterior wall of the pharynx.

If the primary care physician is unable to stop the bleeding, it is necessary to set up a venous access and give saline infusion before transporting the patient to a specialist facility to prevent hypovolemic shock.

The tampon is kept in the nose for 4–5 days (until enough mucus is formed around it for its gentle extraction). In addition to gauze tampons, nasal tamponade can also be performed with commercial tampons, such as *Mero-cel*, which are more expensive but easier to place and reduce the chance of developing an infection. *Surgicel*, *Gelfoam*, and the like are also used in the case of coagulopathies (see additional literature).

If the bleeding does not stop after the anterior tamponade, a posterior tamponade should be performed. For this purpose, balloon catheters can be used on the field, which should be a part of the physician's standard equipment for emergency medical care. The principle is to insert a deflated balloon catheter into the nasal cavity and fill the cuff after positioning the catheter into the epipharynx.

The posterior tamponade is usually in the domain of a specialist and implies the introduction of the tampon into the epipharynx.

If either that does not stop the bleeding, further evaluation or searching for bleeding sites are required. Endoscopic cauterization of bleeding sites is possible, for example, of the sphenopalatine artery (it is searched behind the posterior pole of the middle nasal turbinate), if necessary, septoplasty, or other surgical interventions (ligation of feeding arteries and the like).

### **First aid treatment for epistaxis**

- calm the patient down and lower their blood pressure if elevated
- press the nostrils for 10 minutes in an upright sitting position
- blow the nose and remove clots
- cauterization with  $\text{AgNO}_3$  and similar, or electrocauterization (in the case of bleeding at the level of the capillary plexus in the anterior third of the nasal septum)
- nasal tamponade/packing:
  - anterior (with, if necessary, topical decongestant and anesthetic)
  - posterior
- surgical procedure.

#### **Remember:**

Two primary causes of epistaxis are hypertension and blood clotting disorders.

Unilateral recurrent epistaxis in adults requires the exclusion of tumorous processes of the nose and paranasal sinuses!

If the bleeding can not be stopped, it is necessary to set up a venous access and infusion and refer the patient to a specialist facility.

Assessment of the severity of epistaxis on hemodynamics evaluates blood pressure, pulse, and hematocrit!

Epistaxis can be life-threatening!

**Remember:**

**Procedure for anterior nasal tamponade/packing with a gauze**

- It is important to clean the nose properly before the tamponade and remove any clots by blowing the nose.
- The patient is in a supine position with the chin leaned against their chest. If possible, an anesthetic with a vasoconstrictor are applied topically before the tamponade.
- Use medical forceps or nose tweezers to take a gauze approximately 2 – 5 mm wide. The gauze should be inserted as deeply as possible in the direction of the epipharynx and posterior parts of the nasal cavity; the gauze is inserted in layers.
- At the end of the tamponade, a cellulose pad is placed in front of the nostrils and fixed with a medical patch. The cellulose pad should be changed every few hours as needed. It should be emphasized that redness and the presence of blood on the cellulose pad do not indicate active bleeding. Stopping the bleeding is checked by inspection of the patient's sputum (pure saliva or bloody discharge mixed with saliva are a sign of decreased bleeding, whereas pure blood is a sign that epistaxis is not stopped successfully) and examination of the pharynx with a spatula (checking for postnasal blood dripping).

**Remember: Procedure for posterior nasal tamponade/packing**

- A catheter is inserted through the nasal cavity to the epipharynx and lowered through the pharynx into the oral cavity.
- After visualization, the catheter in the oral cavity is caught with an instrument and pulled out through the mouth.
- A compressed cellulose pad fixed with threads is attached to the catheter.
- The catheter is then extracted through the nose, allowing the cellulose pad to re-enter the epipharynx and, due to its size, remaining blocked behind the choanae, compressing the posterior bleeding.

- The threads extracted through the nose are tied in front of the nostrils.
- This is followed by the procedure for anterior nasal tamponade.
- Balloon catheter insertion is an option for posterior tamponade on the field.

### 2.3.2. Rhinorrhea

**Rhinorrhea** (runny nose) is most commonly bilateral (in inflammatory diseases), whereas a unilateral discharge must arouse suspicion of other etiologies. The discharge can be more or less thick (serous, mucous, mucopurulent, purulent secretion). There is not always a parallel between secretion and inflammation of sinuses, and sometimes milder inflammation (especially allergic ones) causes copious, profuse rhinorrhea, whereas the main symptom of infections of the posterior group of sinuses is the postnatal drip with a poorly pronounced symptom of a runny nose.

Unilateral purulent secretion in children is usually a consequence of a long-time unrecognized foreign body, whereas in adults, tumorous processes and odontogenic etiology (dental evaluation) should be excluded first.

Unilateral clear rhinorrhea certainly implies the exclusion of liquorrhea, which is not always related to sinus-level trauma and can also involve a temporal bone-level trauma! Spontaneous liquorrhea is also possible, with no anamnestic data on head trauma.

### 2.3.3. Sneezing

**Sneezing** represents a defensive reaction of the nasal mucosa to inhaled foreign particles (allergens or irritants), which is triggered to expel foreign bodies that irritate the mucosa. It can be considered the equivalent of coughing as a defense mechanism of the lower respiratory airways.

Allergic reactions are characterized by “bursts” of sneezing, with patients describing sneezing episodes of 10 to 15 sneezes in a row. Such medical history certainly requires further allergological evaluation.

### 2.3.4. Pruritus

**Itchy nose (pruritus)** usually has an allergic genesis and is treated with antihistamines as a part of the treatment of allergic rhinitis. Additional literature is recommended for details on diagnostics and treatment of allergic rhinitis.

### 2.3.5. Nasal obstruction

In differential diagnostics, **difficulty breathing through the nose (nasal obstruction)** can be caused by numerous diseases from allergies, chronic rhinosinusitis (with or without nasal polyposis), acute inflammation and infections, anatomical variations and deformities of the nasal septum, but sometimes also by tumorous processes.

#### **Remember:**

Any prolonged nasal obstruction, especially with the absence of inflammatory symptomatology, requires rhinological evaluation (anterior rhinoscopy, preferably endoscopy) and exclusion of tumor pathology!

### 2.3.6. Smell disorders

**Smell disorders** can range from anosmias and hyposmias to hyperosmias (most commonly associated with damage to the olfactory epithelium) and dysosmias (cacosmia, olfactory hallucinations, etc.), which are more commonly of central genesis and predominantly in the domain of mental disorders.

Smell disorder can occur with lesions of the olfactory epithelium obtained from head traumas. Any sudden posttraumatic loss of smell requires detailed otorhinolaryngological evaluation (as well as posttraumatic facial nerve paresis).

Smell loss (hyposmia) can be caused by edema in acute infectious or allergic inflammation, polypoid budding of the mucosa of the olfactory region, as a part of chronic rhinosinusitis. Although extremely rare, it can also be caused by tumorous processes, which is why it definitely requires rhinological and neurological evaluation. Sometimes after severe viral infections, hyposmia remains prolonged or even permanent, more or less pronounced. A negative finding of olfactory regions certainly requires neurological evaluation.

Unfortunately, damage to the neuro-olfactory epithelium with poor regenerative ability is often permanent, and the patient should be explained that sometimes after viral infections as well as after surgical treatment of nasal polyposis and other chronic rhinosinusitises, the sense of smell returns only in a smaller percentage of cases.

### 2.3.7. Algic syndromes and headaches

In addition to signs of inflammation of the nasal mucosa, rhinosinusitis (with typical symptoms of obstruction and impaired nasal breathing, increased secretion, sneezing, and impaired sense of smell) is also accompanied

by inflammation of the sinusoidal mucosa, which leads to the feeling of fullness in the head and sometimes cephalaea.

Sinuses are often considered to be the “culprits” for headache symptoms, but only 5% of cephalaeas have a rhinological genesis, which is why a multidisciplinary approach is definitely necessary during evaluation. Most commonly, these are vascular headaches and neuralgias and neurological evaluation is needed. Temporomandibular dysfunctions and odontogenic origin of headaches should also be ruled out. Of course, every headache also requires rhinological evaluation and exclusion of tumorous processes.

### 2.3.8. Symptoms of surrounding organs

Due to the influence of the nose on the health of the surrounding organs, patients often consult a physician with symptoms of the pharynx (erythema, burning sensation, dysphagia, clearing throat etc.), lower respiratory airways (cough, spasm, and the like), or ear (various tubal dysfunctions, more frequent middle ear inflammation). These anamnestic data indicate the importance to check nasal patency as a part of the evaluation. Finally, potential sinusogenic etiology should be excluded during the evaluation of meningitis (especially posttraumatic) and/or ophthalmological diseases of unknown etiology (e.g. optic neuritis, ocular motility disorders, and the like).

## 2.4. Basics of therapy

In rhinology, as in medicine, therapeutic procedures can be divided into etiological and symptomatic ones.

**Etiological treatment** implies, for example, administration of antibiotics for bacterial infections, whereas the only proper etiological therapy for allergies (which are very common in rhinology and represent one of the most common causes of patients visiting an otorhinolaryngologist) is specific immunotherapy (desensitization). Additional literature is advised for detailed allergological treatments.

In **symptomatic treatment** in rhinology, polypragmasia is a common problem as no drug covers all symptoms properly, which hinders treatment success. Therefore, for example, the most effective treatment for the symptom of nasal obstruction includes corticosteroid preparations because of their antiedematous and anti-inflammatory effect. However, their onset of action is slow, which is why vasoconstrictors (often abused by patients) are used for rapid onset for the symptoms of obstruction. Thus, a combination of vasoconstrictors and corticosteroids is often prescribed for treatment, e.g. oxymetazoline for 5 days with intranasal corticosteroid spray such as fluticasone or mometasone for 3 – 4 weeks.



Patients often do not understand the need for a combination of drugs, are not sure whether they should use it at the same time, and are often make mistakes in the order of application of topical treatments. Therefore, the success of therapy includes explaining to the patient what the prescribed drugs are for, how to use each drug, and for how long.

### 2.4.1. Topical therapy

- a) **Regular nasal lavages** are among basic topical treatments without which all additional therapy will not be effective. Patients usually neglect the significance of nasal lavage, not only in the treatment of rhinological diseases but also in their prevention and as a part of daily hygiene. There are various systems for the hygiene of nasal cavities, of which the most famous one is the neti pot for nasal irrigation. Isotonic preparations are suitable for daily hygiene while hypertonic solutions are useful for reducing edema of the nasal mucosa during inflammation.
- b) **Drops and sprays** are used along with nasal lavage. **Vasoconstrictors** (e.g. oxymetazoline, xylometazoline, naphazoline) are the most commonly used topical preparations, which are often abused by excessive use. Patients should be explained that these preparations should be used for a maximum of 1 week because constant vasoconstrictive action on blood vessels leads to the so-called *rebound phenomenon*. This implies swollen mucosa due to vasodilatation and vulnerable capillaries with even possible consequent epistaxis and rhinitis medicamentosa (in extreme cases of long-term use).

**Topical antibiotics.** With purulent nasal discharge, topical antibiotics are used along with nasal toilet and decongestants. As a rule, preparations are used that are not generally found in antibiotic preparations for systemic administration (e.g. tobramycin, polymyxin B, and the like), whereas penicillin antibiotics are avoided due to the possibility of sensitization occurring in a patient.

**Corticosteroid sprays** are often the topic of discussions and unnecessary fears among both patients and physicians! Namely, there are many misconceptions about their systemic side effects, which are not to be feared during intranasal administration due to the extremely low resorption into the systemic circulation. Numerous multicenter trials have been conducted on this topic and corticosteroid sprays have been approved according to European and world guidelines, not only within the basis of therapy for allergic rhinological diseases but also in the standard therapy for acute and chronic rhinosinusitis.

It is extremely important to explain to the patient how to apply nasal drops. Namely, most patients instill nasal drops without tilting their head back, in a sitting or standing position, with the substance sliding down the epipharynx into the pharynx and having no effect, with an additional discomfort of bitter taste in the mouth. Therefore, it is important to emphasize that the drops should be instilled with the head tilted back (preferably in a supine position, with the head hanging back over the edge of the bed). The patient should remain in this position for a few minutes in order to keep the active substance in the nose enabling its action on the nasal mucosa and surrounding sinuses.

If nasal drops are used for nasal tube patency and treatment of middle ear inflammation, it is additionally preferable to tilt the head toward the diseased ear.

The order of instillation of topical therapy with drops is also important.

Before instillation of drops, it is necessary to blow the nose properly, remove the nasal discharge, and preferably clean the nasal cavity (the patient should be explained that if they do not clean their nose, topically administered therapy will not work because it remains in the mucus and can not reach the mucosa).

This is followed by instillation of a decongestant (which reduces edema and enables a better effect of the next therapeutic preparation by opening the way to the sinuses), the effect of which should be waited a few minutes and then blow the nose properly again.

Only after that, if necessary, should a topical antibiotic be administered while remaining in a supine position for a few minutes in order for the antibiotic to be effective.

Regarding the use of nasal sprays, it is not necessary to lie down, but it is definitely necessary to blow the nose before using them.

It is advisable to shake the spray bottle before use and direct the pump not to the septum (which is a common mistake done by patients) but to the nasal wings so that as much of the active substance as possible can act on the lateral walls of the nasal cavity and reach the openings of the paranasal sinuses. The patient should then take a deep breath. This also avoids frequent lesions of the capillary plexus of the vascular site (in the anterior third of the septum) to which patients most commonly rest the pump and thus sometimes cause epistaxis.

- c) Nowadays, in the case of drug therapeutic failure, the treatment of sinuses is less frequently performed with sinus punctures, which are instead replaced with functional endoscopic procedures in the specialist domain.

- d) Among other topical treatments, repositioning procedures are described in the chapter on injuries, and ways to stop nasal bleeding are described in the chapter on epistaxis.

### 2.4.2. Systemic therapy

Severe rhinosinusitises require systemic administration of antibiotics and sometimes even corticosteroid preparations.

Other therapies include drugs used for particular diseases (such as antihistamines for allergic diathesis and the like), which should be further analyzed in additional literature.

## 2.5. Injuries

**Facial injuries** can be more or less severe, from superficial injuries to injuries of the soft tissue and adjacent organs, as well as skeletal injuries. They can be manifested by swellings, hematomas, contusions, deformities, lesions of the function of adjacent organs. Patients should be referred to a specialist facility for the treatment of severe injuries. Facial traumas usually occur in traffic accidents. During the evaluation of a polytraumatized patient, facial traumas can often be neglected due to neurological and surgical urgent interventions, especially in the case of deeper tissue injuries without clear superficial wounds. Bony injuries, if not initially properly treated, can result in aesthetical and functional disorders, and being they usually affect younger people, can permanently affect the quality of life. As with the evaluation of any trauma, the principles of emergency medicine (the ABC treatment principle: airway, breathing, circulation) are also applied with facial injuries. The first and basic rule is to open up the airways (which sometimes requires intubation and tracheotomy), followed by enabling circulation and stopping any bleeding (epistaxis, bleeding from wounds, and the like). The facial examination must always be complete and it is important to know how to identify fractures of the nose, upper and lower jaw, fractures of other facial bones (e.g. zygomatic bones). Lesions of the orbital floor and the so-called craniofacial dislocations according to Le Fort should be excluded. Specifically, types and sites of facial bone fractures and especially of the upper jaw depend on bone reinforcement, direction, and strength of the force. Therefore, characteristic fracture lines often occur at sites of force transfer. Suspicion of these injuries certainly requires specialist evaluation. In addition to palpation and analysis of hematomas, deformities, edemas, and the like, evaluation should also include an examination of facial movements (possible lesions of motor nerves) and sensibility (lesions of sensory nerves). It is important to exclude liquorrhea (compress pad test on the field: blood mixed with

liquor leaves a red dot with the surrounding clear aureole), palpate the orbital margins, nasal pyramid, zygomatic arch, mandibular margin, and assess mouth opening, lower jaw movements, and bite. It is necessary to thoroughly examine the oral cavity and search for possible lesions of the gingiva and mucosa.

Evaluation should also include a detailed ophthalmological examination as well as searching for possible diplopias, decline in visual acuity, narrowing of the visual field (“tunnel vision”), and the like. Radiological evaluation completes the diagnostics.

Caution is required with closed injuries, which can even be more severe than open ones.

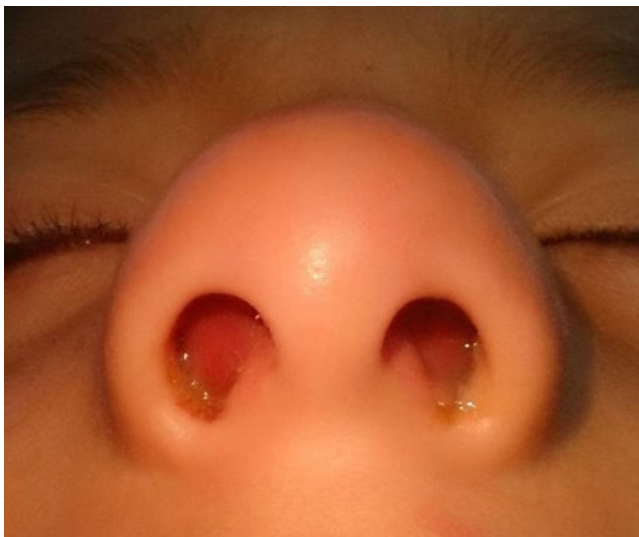In history-taking, attention should always be given to possible losses of consciousness and retrograde amnesia. An urgent surgical procedure is contraindicated with signs of commotion and disorders of consciousness, except in cases of vital indications, such as uncontrolled bleeding. When treating wounds, the primary evaluation must also be a definite one. Due to its rich vascularization, the face is very resistant to infections, which enables blood supply to wounds even several hours after the trauma (wounds can be sutured even 24 hours after the trauma). Therefore, in the case of emergencies on the field, it is sometimes better to thoroughly clean the wound, compress it and stop the bleeding if necessary, and refer to a specialist facility rather than suture it without detailed examination and adequate restoration of deeper musculoskeletal structures (clinical and radiological evaluation and restoration). After thorough cleaning and rinsing of the wound and removal of any particles of dirt and foreign bodies, sparing debridement is recommended to preserve the tissues (skin and mucosal, even poorly vascularized ones) as much as possible and obtain the best aesthetic results. The rules of plastic and reconstructive surgery are applied and, if possible, monofilament sutures are used with a careful adjustment of wound edges. In order to prevent scarring it is advisable to follow the so-called RCT (relaxed skin tension) facial lines. Sutures are made in layers, from deeper to superficial ones. After wound restoration, antibiotic protection is prescribed as well as tetanus vaccine or booster dose in the case of larger contaminated wounds, especially bite wounds.

**Nasal traumas.** Except by palpation and clinical examination, any suspicion of nasal bone fractures should be excluded or confirmed by radiological evaluation, not only to determine proper therapy but also for subsequent forensic expertise. Edema can hinder examination in the initial patient care, which is why appointment for medical control is advisable for the injured patient. An additional reason for medical control is the possibility of a subsequently formed septal hematoma.

**Septal hematoma** does not occur immediately and is usually not recorded during the primary patient evaluation because it gradually accumulates over several days after the trauma. The main symptoms include the progression of nasal obstruction, a feeling of pressure, and soreness.

Being that the nasal cartilage, like auricular cartilage, does not have its own nutrition and is fed by capillarity through the mucosa, any accumulation of blood between the perichondria and cartilage compromises its nutrition, which can cause necrosis and permanent deformation of the nasal septum, especially if it gets infected and abscess appears. It results in rhinolordosis (the so-called "saddle/boxer's nose"), which is often reconstructively very demanding. Therefore, each hematoma requires an incision, drainage, compression, and antibiotic treatment.

**Figure 11.** Septal hematoma



**Table 9.** Septal hematoma – symptomatology and treatment procedure

<b>SEPTAL HEMATOMA</b>	
<b>Causes/symptoms</b>	<b>Procedure/therapy</b>
<ul style="list-style-type: none"> <li>• several days after the trauma</li> <li>• fluctuating septal swelling/soreness and redness</li> <li>• difficulty breathing through the nose</li> <li>• complication – rhinolordosis</li> </ul>	<ul style="list-style-type: none"> <li>◇ <b>refer to ENT</b></li> <li>incision + drainage</li> <li>compression</li> <li>antibiotic</li> </ul>

**Remember:**

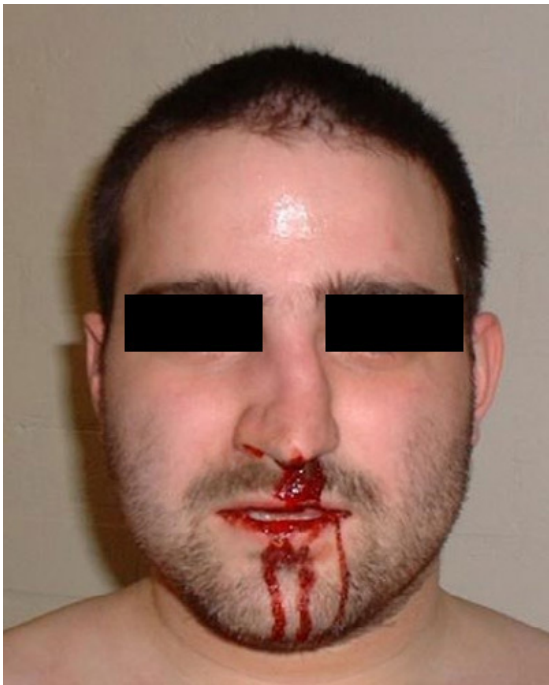Hematoma or septal abscess require:

- incision, drainage, compression, antibiotic therapy to prevent cartilage necrosis and consequent rhinolordosis.

**Fractures without displacement** are treated with topical vasoconstrictor and antibiotic drops. The patient should be advised to put cold compresses on the first day to reduce edema, and later to massage their nose to prevent swellings and subcutaneous hematomas as well as possible thickenings if a clot turns into fibrosis, with consequent deformities of the nasal pyramidal despite the absence of displaced fractures. Nasal fractures heal within 10 days. During this period, the patient should rest and avoid additional traumas.

**Fractures with displacement** can be caused by the lateral force but also by anteroposterior hits with depressions and impressions of fragments. Multifragmented fractures are also possible. Fractures with lateral displacement of nasal bones are usually more visible than impression fractures due to scoliosis of the nasal pyramid and visible displacement to the side.

**Figure 12.** Nasal bone fracture with a displaced nasal pyramid to the side



Displaced fractures should be repositioned with internal and external fixation. If not done properly, repositioning requires additional rhinoseptoplasty. Therefore, it is better to leave the procedure to a specialist (it can be performed up to 10 days after the trauma). Instrumental repositioning is performed under general anesthesia in the operating room. The exception are patients with minor bone displacements, who visit the specialist immediately after the trauma when manual repositioning is still possible and there is no tissue swelling or muscle spasms (within 1 – 2 hours after the injury).

All fractures require mandatory medical control after several days to exclude hematomas and abscesses.

**Septal and alar cartilage** injuries are also possible and definitely require specialist evaluation and restoration of the function and aesthetics of the nose.

**Nasal injuries in children** are less often accompanied by fractures due to the elasticity of structures and are more often the so-called greenstick fractures in which the periosteum remains uninjured. Therefore, subperiosteal hematomas are more common, which subsequently organize into fibrous tissue and can lead to aesthetic and functional consequences.

Upon each fall it is necessary to determine whether the injury occurred due to accidental wrong movement, hit, or the like or the person first lost consciousness and then subsequently got injured. Namely, if the patient loses consciousness prior to the injury, the restoration is followed by a detailed evaluation of causes of the loss of consciousness (neurological examination, control of blood pressure, blood sugar, and other laboratory parameters). Also, each head injury, even a minor forehead laceration or nasal contusion, does not exclude possible deeper injuries and commotions. The patient and their family should be warned that, if somnolence or worsening of consciousness occurs in the following days, they should contact their physician immediately.

In head traumas, it is also important to recognize possible subsequent consequences, such as delayed meningitis, rhinoliqorrhea, possible mucocele, and other ophthalmological, rhinological, and neurological complications.

**Remember:**

The septal hematoma is formed gradually and is not immediately visible, which is why each patient with a nasal trauma should have a medical control on the second or the third day after the injury.

Nasal fractures should be excluded or confirmed by radiological evaluation, not only to determine proper therapy but also for possible subsequent forensic expertise, especially with injuries caused by another person.

After first aid measures that include opening up the airways and stopping bleeding, naso-orbital and nasofrontal injuries certainly require not only specialist evaluation but also a multidisciplinary approach and treatment according to the principles of aesthetic and reconstructive surgery.

First aid definitely involves suppression or dealing with shock and evaluation according to the principles of emergency medicine (the ABC treatment principle: airway, breathing, circulation).

Minor superficial injuries can be deceiving and also require a thorough examination, evaluating and excluding deeper injuries of soft tissues and bones.

Each suspicion to rhinoliquorrhea (leakage of clear secretion from one nostril, especially when moving the head downward) or recurrent meningitis even several months after head trauma, require further detailed evaluation.

**Procedures for the evaluation of nasal trauma:**

- clinical examination (nasal pyramid, epistaxis)
- X-ray of nasal bones
- if there is no fracture: Heparin cream externally, nasal drops
- fracture without displacement : Heparin cream externally, nasal drops
- fracture with displacement: repositioning within 8 days, rhinoplasty in 6 months, if necessary.



medical control in two days due to possible formation of septal hematoma



## 2.6. Foreign bodies

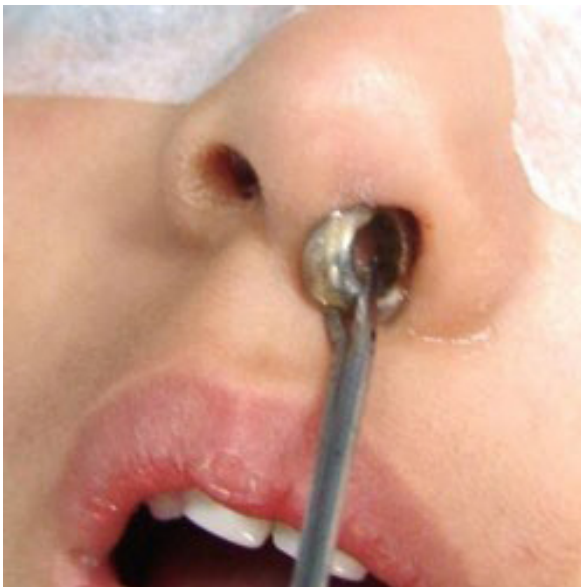Foreign bodies in the nose are more frequent in children, although they can be found in adults as well (usually in psychiatric patients or accidentally, when cleaning the nose).

Physicians often receive visits from parents whose children push various objects into the nose (little stones, various little balls, toy parts, etc.), usually when playing. Special attention is necessary with sharper objects, which can cause mucosal lacerations, but also with foreign bodies of vegetal origin (beans, corn, seeds, etc.), which can, by gradual swelling, additionally obstruct breathing and lead to inflammation of surrounding tissues.

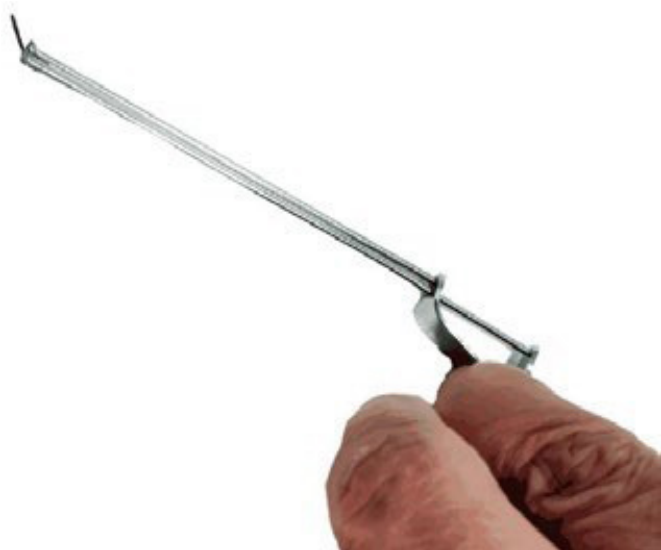A long-term foul-smelling discharge on one nostril (with ipsilateral difficulty breathing and sometimes bloody discharge) must arouse suspicion of an unrecognized foreign body that has been stuck in the nose for a long time.

If a foreign body in the nose is confirmed by rhinoscopy or endoscopy, it must be carefully removed with special instruments. Cooperation of the child and the parent is as important as the position of the child's head (head tilted forward) in order to prevent the foreign body from entering the deeper parts of the nasal cavity, and sometimes even aspiration. Special caution is necessary with round foreign bodies (beads and the like). If possible, the procedure is performed outpatiently, but if the child does not cooperate, hospitalization and surgery under general anesthesia are required.

**Figure 13.** Extracting a foreign body from the nose



**Figure 14.** Instrument for the extraction of a foreign body from the nose



**Table 10.** Foreign bodies in the nose – symptomatology and treatment procedures

<b>FOREIGN BODIES IN THE NOSE</b>	
<b>Cause/symptoms</b>	<b>Procedure/therapy</b>
<ul style="list-style-type: none"> <li>• little balls and toys, corn, beans, and the like</li> <li>• unilateral difficulty breathing and purulent secretion</li> <li>• complications: mucosal erosion, inflammation</li> </ul>	<ul style="list-style-type: none"> <li>◇ refer to ENT</li> <li>• extraction</li> <li>• antibiotic</li> </ul>

## 2.7. Inflammation and complications

### 2.7.1. The skin and vestibulum of the nose

A *furuncle* on the nasal skin or in the nasal vestibulum should be recognized and the patient should be warned not to squeeze it to prevent the retrograde propagation of bacterial infection from the nose to the brain through vascular anastomoses (by the ophthalmic and facial veins). Such spread is facilitated due to the absence of venous valves, which have a protective function in other regions, with the possibility of extremely dangerous cavernous sinus thrombosis. Therefore, furuncles of this region are more dangerous than, for example, furuncles of extremities or the trunk. They should be treated with broad-spectrum antibiotics, and it is important

to cover beta-hemolytic streptococcus and *Staphylococcus aureus* (e.g. first- and second-generation cephalosporins). The patient should come to a medical control within 48 hours in order to evaluate the success of antibiotic therapy. In addition to antibiotic therapy, it is sometimes necessary to perform incision and drainage of the furuncle. Any suspicion of initial signs of cavernous sinus thrombosis (neurological disorders, severe headache, febrility, ophthalmological symptoms, periorbital edema, and changes in the state of consciousness) requires urgent hospitalization for further evaluation and treatment!

Similar to the ear, ***impetigo*** is a superinfection by staphylococcus or streptococcus, which most commonly occurs after intensive scratching or cleansing of the nasal skin or nasal vestibulum. It is treated by cleansing the crusts, with moist compresses, nasal toilet, and topical antibiotic preparations. ***Erysipelas*** indicates a severe condition and spread of streptococcal infection into the lymphatic areas. It is accompanied by lymphadenopathy, general algic syndrome, and febrility. It requires prompt systemic antibiotic therapy to prevent the rapid spread of the disease and possible complications.

### 2.7.2. True nasal cavity

Although the introduction of this chapter does not exclusively cover the nose and paranasal sinuses, it is important to mention acute respiratory infections, which are the most common infections and a common cause of a "physician's visit".

Acute respiratory infection (ARI) is very common and occurs in adults on average 2 to 4 times annually), and even more frequently in children (5 to 8 times annually).

Depending on the affection of organs, the clinical picture can vary from:

- rhinitis/rhinosinusitis
- pharyngitis/tonsillopharyngitis
- rhinopharyngitis/rhinotonsillopharyngitis

However, it can also spread to surrounding organs in the form of:

- laryngitis / pharyngolaryngitis / rhinopharyngolaryngitis
- otitis
- and other.

The clinical picture depends on the virulence of the pathogen as well as the patient's immunity. Therefore, the same virus can cause mild rhinosinusitis in an adult or severe, even life-threatening laryngotracheobronchitis in a child with immature immunity.

**Acute respiratory infections are usually manifested by mild pain and sore throat, nasal discharge, obstruction, and sneezing.** The spread of the infection into the surrounding structures (sinuses, ear, etc.) causes a feeling of fullness of the ear and decreased hearing, and can lead to true middle ear inflammation with severe otalgia and painful tragus. The affection of sinuses leads to pressure and fullness in the head, sometimes even stronger headache. Basic symptoms include febrility, fatigue, and languor. Lowering and propagation of the disease toward the larynx and lower respiratory airways lead to hoarseness and cough. **The most common etiology is the viral one, which is why antibiotic therapy is not necessary.** It is important to **strengthen immunity** with symptomatic therapy, hydration, and rest. Being that this is a self-limited disease, most symptoms regress in 4 – 5 days and generally disappear within 10 days, but a dry irritating cough can persist for several weeks.

Also, exacerbations of allergic inflammation are often mistakenly treated with antibiotics and are not distinguished from infectious conditions.

**Acute rhinosinusitis (ARS).** Rhinitis is an inflammatory disease of the nasal mucosa and can have various etiologies. Its typical symptoms are obstruction and difficulty in nasal breathing, increased secretion, sneezing, sometimes even pruritus and impaired sense of smell, whereas the accompanying mucosal inflammation in the sinuses leads to the feeling of fullness in the head and sometimes even cephalgia. Treatment of the inflammatory process in the nose and proper nasal patency (which is the basis of therapy) leads to ventilation and restoration of inflammatory processes in the surrounding sinuses. If adequate nasal and sinus patency is not achieved, the processes slowly transition to chronicity, leading to various forms of chronic rhinosinusitis. Recurrent and chronic disorders are often underlain by allergic diathesis, reflux disease, immunity disorders, and other systemic diseases as well as treatments. Sometimes, various anatomical variations of nasal structures can be present, which can result in decreased sinus ventilation and lead to impaired mucociliary transport.

All this should be kept in mind during patient evaluation.

#### **Treatment of acute rhinosinusitis (ARS):**

- up to 10 days → symptomatic therapy (saline, lavage, intranasal corticosteroids)
  - decongestants are also possible (e.g. xylometazoline, oxymetazoline) but not longer than 7 days (development of medicamentous chronic rhinosinusitis)
- after 10 days or worsening after the fifth day → first-line antibiotic systemically according to national guidelines (e.g. amoxicillin)
- without improvement after the next 5 days → second-line antibiotic or hospitalization (e.g. co-amoxiclav, doxycycline)

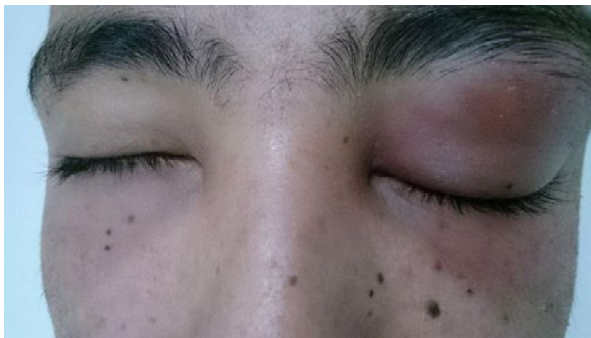In the case of suppurative rhinosinusitis accompanied by leukocytosis, it is definitely necessary to start antibiotic treatment on time to prevent complications, whereas special etiologies of sinusitis (e.g. odontogenic) require additional examinations and treatment. Additional literature is recommended for details on the treatment of various forms of rhinosinusitis.

### 2.7.3. Complications of sinusitis

Due to its specific position, by spreading to surrounding organs, sinus inflammation can cause serious complications, which should be recognized on time and treated properly.

**Orbital complications.** If sinus inflammation spreads toward the orbit through the thin bone of the lamina papyracea or through venous pathways, it can lead to mild or severe orbital complications and a series of clinical pictures, more or less dangerous for the patient's vision.

**Figure 15.** Orbital complication of sinusitis



**Preseptal cellulitis** is manifested by edema and redness of the upper eyelid, without impaired ocular motility or ptosis and without impaired vision. Treatment includes parenteral administration of antibiotics and antiedematous and vasoconstrictor therapy. It should be distinguished from the preseptal abscess, which requires surgical treatment and drainage. In addition to edema and eyelid redness, proptosis and chemosis of the conjunctiva also occur in orbital cellulitis. Visual impairment and diplopia can be present. Ophthalmological and otorhinolaryngological diagnostics and therapy are definitely required, as well as the exclusion of subperiosteal abscess, which requires urgent surgery. Treatment of cellulitis begins with high doses of antibiotics and antiedematous therapy, but in the case of diplopia and visual impairment, urgent surgical treatment is indicated in the form of ethmoidectomy and orbital decompression. In orbital abscess, the symptoms are similar to the previous complications, but ophthalmoplegia and proptosis are more frequent and more pronounced. Surgical treatment and a multidisciplinary approach of an ophthalmologist and otorhinolaryngologist are certainly required.

**Remember:**

Special caution is necessary with the pediatric population, in which the propagation of inflammation from the ethmoid sinus toward the eye can progress rapidly.

**Endocranial complications** of sinusitis are much less common than orbital ones. Endocranial complications include meningitis, epidural and subdural abscesses, cerebral abscesses, and very serious cavernous sinus thrombophlebitis, sometimes with a fatal outcome. Therefore, when neurological symptoms occur in sinusitis, the patient should be referred to specialist evaluation as soon as possible to exclude and possibly treat these complications, which usually require immediate opening and drainage of sinus foci with high doses of antibiotics. In addition to the removal of primary foci, a neurosurgical approach is sometimes also required (e.g. in frontal lobe abscess).

Therefore, if a patient with anamnestic data on sinusitis begins to manifest neurological symptoms, it is always important to exclude endocranial complications, which are sometimes even life-threatening, and not to delay diagnostics and treatment.

Osteomyelitis of the frontal bone and upper jaw belongs to other possible complications of sinusitis that certainly require specialist evaluation.

**Table 11.** Complications of rhinosinusitis – symptomatology and treatment procedures

<b>COMPLICATIONS OF RHINOSINUSITIS</b>	
<b>Symptoms</b>	<b>Procedure/therapy</b>
<ul style="list-style-type: none"><li>• progression of sinusitis symptoms (nasal discharge, congestion, febrility, headache) with the appearance of ocular or neurological symptoms</li><li>• orbital complications (cellulitis, abscess, etc.): swelling, eyelid closure; soreness, redness, bulb protrusion; impaired vision</li><li>• intracranial complications (meningitis, cerebral abscess, etc.): appearance of neurological symptoms</li></ul>	<p>◇ <b>urgently refer to ENT</b></p> <ul style="list-style-type: none"><li>• broad-spectrum antibiotic</li><li>• urgent MSCT</li><li>• consultation with an ophthalmologist neurosurgeon</li><li>• surgical procedure</li></ul>

### 3. Oropharyngolaryngeal emergencies and selected chapters on emergencies with other organs of the neck region

#### 3.1. Brief anatomical-functional reminder

**The oral cavity** (*cavitas oris*), much like the nasal cavity, is divided into the vestibulum and the true oral cavity, a detailed examination of which is the basis of any examination performed by a general physician. The oral cavity, in addition to the digestive function (chewing and food processing, production of saliva, and the beginning of digestion), also has a vocal function (resonation of voice and formation of consonants).

The pharynx is a musculomembranous organ representing the intersection of the respiratory and digestive tract. It is divided into three levels:

- **epipharynx** (nasopharynx) – with the respiratory function
- **oropharynx** – as an intersection of the aerodigestive tract
- **hypopharynx** – with a predominantly digestive role, but its pathology can have respiratory repercussions due to its close association with the larynx.

The pharynx contains the Waldeyer's lymphatic ring, which is crucial for the acquisition of immunity and consists of six tonsils:

- one pharyngeal (*tonsilla pharyngea*) and two tubal (*tonsilla tubaria*) located in the epipharynx (known in the population as the “third tonsil”)
- two palatine (*tonsilla palatina*) located in the tonsillar lodges (known in the population as “tonsils”)
- one lingual (*tonsilla lingualis*).

Inflammation of pharyngeal and tubal tonsils is most common in young children (up to 6 years of age), inflammation of palatine tonsils is more common in school children and young adults, whereas the elderly usually report problems with swallowing in hypertrophy of the lingual tonsil, which is more commonly found in tonsillectomized patients.

**The larynx** is a neck organ that belongs to the respiratory tract. In addition to the respiratory function, the larynx also has a very significant phonatory role, but also functions as a sphincter and protects the trachea and lower respiratory airways. It is divided into three levels:

- **supraglottic region**
- **glottic region**
- **subglottic region.**

Supraglottis is located at the intersection with the digestive tract. Its symptomatology is characterized by symptoms of respiration and deglutition (numerous dysphagic disorders). Due to their rich lymphatic irrigation and innervation, the initial symptoms of the aforementioned region can be manifested in the form of irradiation of pain to the surrounding organs, especially the neck (pain and lymphadenopathy) and the ear (otalgia with a negative otoscopic finding).

The *glottic region* is essential for phonation, and its main symptom is hoarseness, which can be a symptom of inflammation and benign changes, but any hoarseness lasting for more than 3 weeks raises suspicion of a tumorous process and requires detailed specialist evaluation. Fortunately, this region, which is also the most common site of carcinoma, has a more favorable prognosis due to poor lymphatic drainage and late metastasizing of tumorous processes, which are usually diagnosed at an early stage due to the obvious symptom of dysphonia. Of course, any severe affection of the glottic region also leads to dyspnea, in this case, the inspiratory stridor. Symptoms of the *subglottic region* are predominantly related to respiratory symptomatology, primarily inspiratory difficulties breathing.

The basic classification of the laryngeal musculature is into the respiratory and phonatory group of muscles. Within the anatomical features of this region, it is important to emphasize that only the cricoid cartilage has a complete ring, whereas the thyroid cartilage and tracheal rings consist of a combination of a cartilaginous and elastic-membranous part.

Additional literature is advised for details on anatomical and functional specificities of the oral cavity, pharynx, larynx, esophagus, trachea, and neck.

## 3.2. Overview of the region

When examining this region, as mentioned before, two approaches should be taken into account:

- anatomical – integrity of structures (clinical examination and radiological evaluation)
- functional – defects in function.

This examination is supplemented by additional diagnostic methods (laboratory tests and, if necessary, additional multidisciplinary evaluation).

### 3.2.1. Anatomical structures

#### a) Clinical examination

A good examination of the oropharyngolaryngeal region is necessary besides cases of symptomatology typical for the region in any general examination, any cervical lymphadenopathy, and any febrility of unknown cause



In addition to inspection of the vestibulum, teeth, and gingiva, it is also necessary to assess duct exits of salivary glands, pay attention to retro-molar regions (as possible sites of inflammatory and malignant processes), tongue motility, and examination of the hard and soft palate.

The examination can be performed by using a lamp (which must be a part of the basic medical equipment) or a medical headlight, the latter being recommended because the physician's hands are free, which increases the accuracy of the examination performed.

In addition to inspection, palpation of this region is also very important as it can detect some initial mucosal processes that are not visible to the naked eye but are palpable (e.g. initial tongue thickening, more accurate detection of pain site, and the like).

When using a spatula, it is necessary to press the front two-thirds of the tongue for better visibility of the pharynx. If the spatula is pushed too deep, it often causes pronounced reflexes of vomiting. If the spatula is placed too shallowly, it prevents a proper examination of tonsillar lodges.

For examination of the hypopharynx and larynx, a laryngeal mirror is used in general practice, whereas more accurate data is provided by a flexible nasolaryngoscope, which is a part of a specialist's equipment. It is important to examine properly the base of the tongue and the valleculas, epiglottis and other parts of the supraglottis, and pyriform sinuses (presence of foreign bodies, tumorous processes, hypersalivation, and the like). It is followed by a detailed examination of the glottic region, motility and appearance of vocal cords, the width of the glottic opening, and analysis of aryepiglottic folds, the irritation of which is one of the first symptoms of acid reflux. It is advisable to consult additional literature for further details on this topic.

#### **b) Radiological examinations**

Radiological evaluation in emergency conditions is primarily concerned with the evaluation of injuries and assessment of affection of surrounding structures as well as with the insight into the spread of the disease within the evaluation of complications of severe inflammatory conditions. It is also necessary for the evaluation of tumorous processes.

#### **3.2.2. Function evaluation**

The most important thing in emergency conditions is to exclude acute respiratory distress syndrome, to assess the status of the cardiovascular system, and, of course, the function of deglutition, mastication, and phonation.

### 3.2.3. Laboratory and additional tests

In addition to clinical examination, further tests are also required in emergencies, such as **laboratory blood tests** (DBC, ESR, CRP, GIB, Na<sup>+</sup>, K<sup>+</sup>, Cl<sup>-</sup>) for inflammatory conditions and coagulation factors in the case of severe bleedings and trauma, as well as preoperatively.

In addition to collecting swabs for acute tonsillopharyngitis, swabs are also collected for the evaluation of numerous other inflammatory conditions (exclusion of foci). Along with the analysis of AST-O antibodies, they are also a part of the preoperative evaluation when deciding on tonsillectomy. It is advisable to consult additional literature for more information.

## 3.3. Symptomatology

The main symptoms of diseases in this region are:

- dyspnea/stridor
- dysphonia
- sore throat / burning sensation / dry throat
- odynophagia
- dysphagia
- lymphadenopathy / other neck masses
- foreign body sensation in the throat.

Other symptoms include nonspecific neck pain with irradiation to the ears (otalgia) and surrounding organs, like coughing, snoring, hemoptysis, and hemoptoe etc.

### 3.3.1. Dyspnea

Dyspnea is the most severe and most dangerous symptom that causes a "physician's visit" in the case of injuries, edemas of allergic or inflammatory genesis, and progressive airway tumors. It is extremely important to recognize the type of dyspnea or stridor. Inspiratory stridor occurs when upper respiratory airways are obstructed.

The patient's expiration is impeded, whereas their inspiration is normal. In the case of disorders of the lower respiratory airways, the patient has expiratory stridor with prolonged and impeded expiration, whereas the inspiration is unobstructed. In the case of inspiratory stridor, the patient should be referred to an otorhinolaryngologist, whereas expiratory stridor requires pulmonary evaluation.

For example, a laryngectomized patient with a permanent tracheostomy and cannula having a normal inspiration and prolonged expiration, has no problem breathing through the cannula but obstructive disorders of the lower

respiratory airways and should be referred to a pulmonologist. This can be easily checked by the physician by placing the palm of his hand in front of the tracheostoma, with sensible patency of air flow through the stoma.

If the cannula is found to be impassable, it must be cleaned or replaced. If the inspiratory stridor persists, the airway should be cleansed by gentle instillation of saline and aspiration.

Dyspnea is more severe in young children because of their narrow airway and anatomical features of the laryngeal structures that are still developing (flabby epiglottis, rounder glottic inlet, elasticity and fragility of subglottic structures, small-sized subglottic spaces – the diameter of the subglottis is 6 mm). Therefore, the circumferential edema of the subglottic tissue in infants will narrow the lumen significantly more than the same edema in adults!

When evaluating dyspnea, it is important to recognize:

- **localization**

If the pharynx and supraglottis (epiglottitis and the like) are affected, the patient has respiratory stridor, deglutition disorders with saliva stagnation, they are often in a sitting position with their mouth open, and their head may be tilted to the healthy side. Their voice is often muffled and resembles a “frog voice”.

Typically, laryngeal stridor implies prolonged inspiration with modifications of voice and cough (similar to the “bark of a dog”) and is usually accompanied by bradypnea.

Normal voice is a characteristic of obstructed lower respiratory airways (as well as for tracheal dyspnea).

In tracheal dyspnea caused by foreign bodies, we encounter the so-called “tracheal ballotement” that can help determine localization. It is a result of the movement of a foreign body during breathing and its contact with the tracheal boundaries (a hit to the subglottis and bronchial bifurcation).

The cardiac cause of dyspnea is usually accompanied by tachypnea, whereas the bronchial cause of dyspnea is followed by expiratory bradypnea and prolonged expiration but with normal inspiration and voice.

- **degree and duration of dyspnea**

Dyspnea that lasts longer than an hour in a young child can lead to exhaustion and very serious asphyxia. Signs of asphyxia are pronounced pallor and/or cyanosis, tachycardia, sweating, and worsening of the general condition accompanied by a progressive disorder of the respiratory rhythm with pauses longer than 20 seconds. These signs indicate a life-threatening respiratory failure followed by circulatory collapse and require first-line emergency care with either intubation or tracheotomy.

When determining the cause of dyspnea in children, information about the child's age helps as well as their anamnestic data. In children younger than 6 months, anatomical malformations (laryngomalacia and/or tracheomalacia due to immature cartilage structures, laryngeal membranes, and the like), angiofibromas, and the like should be primarily suspected. In children older than 6 months, the most common cause of inspiratory dyspnea is acute laryngitis, which is divided into stridulous and edematous.

The most common causes of laryngeal dyspnea in adulthood are progressed laryngeal tumors (newly diagnosed or progressive, previously identified tumors) and injuries of the aforementioned region.

Dyspnea is also possible due to caustic ingestions or extremely hot beverages, which requires corticosteroid therapy, but also due to insect bites and allergic edema, which usually require, in addition to corticosteroids and antihistamines, immediate parenteral administration of adrenaline.

Bilateral vocal cord palsy is also a possible cause of inspiratory stridor.

**Remember:**

In the case of severe dyspnea, especially with suspected inflammatory cause, parenteral corticosteroid therapy should be administered as a part of first-line emergency care.

Sweating, pallor, and cyanosis indicate worsening of acute respiratory distress syndrome and are a warning sign!

A patient who is sitting and "grasping" for air should never be forced to lie down because that may worsen dyspnea. If there is a risk of asphyxia, it is necessary to be ready to perform coniotomy on the field or tracheotomy in hospital conditions!

Any laryngeal or pharyngeal dyspnea can suddenly worsen, especially in young children and cardiopulmonary patients!

Sedatives should never be prescribed for inspiratory stridor due to potential additional respiratory depression!

It is always important to open up the airway. Depending on the degree of urgency, localization, and cause of suffocation, antiedematous therapy is necessary along with endotracheal intubation and, if necessary, coniotomy on the field and tracheotomy in hospital conditions.

**Tracheotomy** is a procedure that opens up the airway in the case of inspiratory stridor if the obstruction is located above the intended opening. However, this procedure is not helpful with lower obstructions.

Emergency tracheotomy is usually performed under local anesthesia. A venous access is previously set up and anti-edematous therapy with corticosteroids is administered to reduce edema and facilitate the procedure. The patient is usually upset, which can hinder cooperation. The patient should remain in a sitting position until the procedure is performed because lying down usually worsens dyspnea. The procedure is performed in an operating room under sterile conditions. The patient is in a supine position, with placement of a sheet or a compress under the thoracic part of the back to achieve better access to laryngotracheal structures obtained by deflection of the neck.

Tracheotomy is performed by making an incision on the neck in the median line, with laryngeal prominence (*pomum Adami*) serving as an orientation under which the cricoid cartilage and, lower, the tracheal rings are palpated. By strictly following the median line, lesions of the surrounding neurovascular structures (dangerous carotid triangle, *trigonum caroticum*, with vital vessels and nerves of the neck) are avoided.

Depending on the anatomical relationships and pathology, the opening on the trachea can be made below the isthmus (lower tracheotomy), above the isthmus (upper tracheotomy), but it is usually performed through the isthmus at the level of the second tracheal cartilage. Cricoid cartilage should be preserved as it is the only upper airway structure with full cartilaginous armor, which is important for maintaining the airway lumen. Tracheal rings consist of anterior cartilaginous parts shaped like a horseshoe (2/3 of the ring) and a posterior elastic-membranous part (1/3 of the ring), and because of that lack the strength of the cricoid cartilage. On the other hand, lower tracheotomies can damage the thoracic organs and cardiovascular structures. Preparation is performed in layers. In order to access the trachea, it is necessary to, along with other neck structures located at the level of the second tracheal ring (skin, subcutaneous tissue, muscles, etc.), identify and ligate the thyroid isthmus. Before opening the trachea, it is important to achieve proper hemostasis in order to prevent aspiration of blood and to coagulate the isthmus as well as bleeding sites and/or ligate larger vascular structures.

Besides surgical or classic tracheotomy, percutaneous tracheotomy performed with special instruments in intensive care units is an option.

Unlike emergency or urgent tracheotomy, planned or preventive tracheotomy is advised for all cases with impaired inspiration that are expected to aggravate without intervention (tumorous processes, prolonged intubation and the like).

The opening made by tracheotomy is called the tracheostomy. Tracheostomy can be **temporary** if normalization of breathing through the upper airways is expected or permanent (for example, in progressed tumors that

require total laryngectomy). A tracheal cannula is placed in the tracheostomy for respiration. There are different types of cannulas, depending on the indications: metal, silicone, plastic, with or without the cuff, etc. The cannula should be distinguished from the voice prosthesis (which is set up to enable speech after laryngectomy), located on the posterior tracheal wall, in the so-called tracheoesophageal fistula.

**Coniotomy** is performed in the case of threatening suffocation with inspiratory stridor if it is estimated that there is no time to perform tracheotomy.

Coniotomy is performed by opening the cricothyroid ligament (*ligamentum conicum*), which is located between the thyroid and cricoid cartilage. The incision is preferably made with a sharp instrument available (scalpel, knife, etc.), and a structure with a lumen (ballpoint pen, straw, etc.) is placed in the opening.

After coniotomy is performed and the life is saved, the patient should be referred to a facility where subsequent tracheotomy will be performed.

### 3.3.2. Dysphonia and aphonia

The term **dysphonia** implies voice disorders. Although these disorders most commonly have a *laryngeal origin*, *supralaryngeal causes* are also possible, such as rhinolalia (caused by disorders of the resonant cavities). Among supralaryngeal dysphonias, it is important in an emergency to recognize abscesses and other tumorous processes of the pharynx, which are usually accompanied by a “duck-like” sound.

*Laryngeal dysphonia* can be caused by organic or functional disorders, and its evaluation belongs to the domain of a phoniatrician or ENT specialist. In addition to the laryngeal examination, basic anamnestic and clinical data also help with setting a diagnosis. It is important to remember that the voice is rough and hoarse in chronic cases, especially in organic, exophytic neoplasms (benign and malignant tumors, hypertrophic laryngitis, chronic laryngitis), whereas acute laryngitis usually leads to a muffled voice and sometimes aphonia. Unilateral or partial paresis and palsies of vocal cords usually lead to bitonal dysphonia and should also be recognized as a part of the differential diagnostics, whereas bilateral palsies of vocal cords leads to a very serious inspiratory stridor.

Additional literature is recommended for details on other dysphonic problems (especially functional ones).

**Aphonia** signifies the cessation of voice emission and can be caused by the immobilization of vocal cords in the respiration position. In differential diagnostics, it helps to observe whether the cough is inaudible, unlike psychogenic aphonia in which the patient’s cough is normal and clear.

### 3.3.3. Painful syndromes

Besides various sore throats in inflammatory processes of the oral cavity and pharynx, painful syndromes are possible in dental pathology, in various temporomandibular dysfunctions, vascular algic syndromes due to, for example, compromised cervical circulation, inflammations of lymph nodes (not only of the neck but also of the posterior pharyngeal wall). Neuralgic pain can be caused by, for example, more developed styloid process, and many other causes of nerve irritations.

Sore throats can often be treated with symptomatic therapy, whereas antibiotics should be reserved for suspected or proven bacterial diseases according to current guidelines.

**Dysphagia** indicates difficulty swallowing, whereas **odynophagia** implies painful swallowing. These two symptoms can occur simultaneously or separately. Dysphagia is often more severe than odynophagia and can be associated with cough and dyspnea. They can be caused by inflammatory processes and infections, but dysphagic problems also often have psychogenic causes. A special form of fear of swallowing is called phagophobia. Odynophagia and dysphagia should not be confused with pharyngeal paresthesias (in the form of “feeling a lump in the throat” and similar). Each time patients present with dysphagia they should be asked if they have more difficulties swallowing liquids or solids. Dysphagia of liquid foods indicates neurological problems of deglutition, whereas difficulty swallowing solid foods certainly raises suspicion of various inflammatory or tumorous processes (either benign or malignant). Dysphagia and odynophagia can be of oropharyngeal or esophageal origin. In addition to infections (i.e. obvious inflammations of the oral cavity, tonsillopharyngitis, laryngitis, sialadenitis, and the like), common causes also include acid reflux and other digestive diseases such as dyspepsia, gastritis, esophagitis, peptic ulcers, but also numerous systemic, immunological disorders, as well as alcohol consumption, extremely hot or cold beverages, and smoking. In addition to taking detailed anamnestic data on dysphagia and odynophagia, the differential diagnostics must also include data collection on possible weight loss as a potential sign of malignancy.

In emergencies, it is important to assess the level of dehydration in a patient (e.g. mucosal dryness, tongue coating, and the like). The basic treatment includes compensation of lost fluid and exclusion of various abscesses that require immediate surgical intervention. Further procedures depend on a more detailed specialist evaluation.

In addition to odynophagia and dysphagia, **pharyngeal paraesthesias** are also common and can become an emergency. They can occur as pain during deglutition of saliva, globus sensation (“lump”) in the pharynx,

subjective foreign body sensation, and constant throat clearing. Patients often consult a physician due to these problems. A thorough examination is certainly required before any declaration of psychogenic causes of the aforementioned problems, which, in addition to the local examination, involve additional evaluation (e.g. hypochromic anemia and hormonal imbalances often cause mucosal dryness, odynodysphagic problems, and sometimes a feeling of “lump” in the throat). Sometimes these are true painful tics caused by pharyngeal contractions, which are typically milder in the morning after a night’s rest and disappear at mealtime during physiological contractions of the pharyngeal musculature, whereas they worsen in stressful situations and unconscious spasms of the aforementioned muscles (e.g. in unpurposeful deglutition).

**Remember:**

The symptomatology of the pharynx is closely related and often overlapping with rhinosinusogenic and esophagogastric problems (discharge of secretion from the sinuses, acid reflux, and the like).

Pharyngeal discomfort and throat clearing can be caused by muscle spasms and psychogenic causes, which lead to musculature spasms and slowly turn into psychoorganic disorders. However, it is certainly necessary to exclude organic causes, especially tumorous genesis of pain before making such diagnoses.

The psychogenic background of these problems is characterized by the fact that the symptoms usually regress during mealtime, whereas they worsen in these cases with organic causes.

### 3.3.4. Hemoptysis and hemoptoe

Bloody sputum, in addition to the pharynx and larynx, can also originate from nasal cavities, other parts of the digestive tract, and lower respiratory airways, and certainly requires multidisciplinary evaluation. Typically, if the sputum contains clear blood during coughing, special attention should be paid to lower respiratory airways and detailed pulmonary evaluation is necessary. If there are anamnestic data on bloody discharge from the nose, a thorough endoscopic examination is required, especially of posterior parts of the nose and epipharynx, to exclude possible tumorous processes. Oropharyngeal examination often reveals gingival lesions (especially in periodontitis and the like) and small venous varicosities at the base of the tongue (especially in elderly people), but only after detailed evaluation and exclusion of other etiologies of bleeding can it be said with certainty that they are the cause of bloody sputum. Certainly, laboratory tests should be performed as a part of the evaluation to exclude internal



diseases, coagulation disorders, hematological diseases (thrombocytopenia, pancytopenia, myeloproliferative diseases), and the like, which often affect the buccopharyngeal mucosa.

### 3.3.5. Lymphadenopathy and other neck nodes

The main rule in an emergency is to distinguish whether a neck mass is an inflammatory or a tumorous process. In addition to lymph nodes, inflammation can also affect lateral and midline neck cysts, which should not be forgotten, as well as large salivary glands. The inflammatory process is characterized by the classic five symptoms and signs: *tumor, rubor, calor, dolor, et functio laesa*. It is important to recognize an abscess formation that requires surgical treatment, whereas other inflammatory conditions are treated with systemic antibiotic therapy.

## 3.4. Basics of therapy

Management of bleeding and airway opening in an emergency (coniotomy, tracheotomy) are explained in the chapters on hemorrhage and dyspnea.

## 3.5. Hemorrhage

After suffocation, the most serious symptom of the pharyngolaryngeal region is bleedisputumng. In addition to injuries, bleeding can also occur after tonsillectomy and/or adenoidectomy.

Bleeding upon tonsillectomy can be divided into early (within 24 hours) and late (within 10 days after the procedure), and can be mild, strong, or severe.

Therefore, it is especially important to monitor the patient immediately after the procedure, especially if the patient is a small child who is not always able to signalize bleeding (they sometimes swallow blood without visible bleeding from the mouth). Patients are monitored by checking their sputum regularly every two to three hours usually for 24 hours postoperatively. If the sputum is hemorrhagic, it is necessary to examine the patient oropharyngoscopically, determine the bleeding site, remove possible clots, and clean the tonsillar lodges with a tampon soaked in a solution of hydrogen peroxide. If the bleeding does not stop, the tonsillectomy site is revised and blood vessel ligation is performed. The danger of bleeding is also present in the next 10 days during the wound healing process.

Therefore, when discharging the patient from the hospital, it is necessary to familiarize them (or their parents) with the symptoms of potential bleeding and emphasize that they should contact a physician in the case of bloody sputum. Rest and soft food diet are recommended for preventive purposes for the next 7 days.

If the physician on the field is unable to stop the bleeding, the way to the hospital is longer and the bleeding is more intense, a venous access and volume compensation are set up prior to transportation to prevent hypovolemic shock.

### 3.6. Injuries

Due to vital anatomical structures (neurovascular bundles, thyroid, larynx, trachea, esophagus), neck injuries are very dangerous but fortunately rare (only 2% of injuries). Therefore, any neck injury requires urgent and detailed evaluation and treatment according to the principles of emergency medicine (ABCD: *airway, breathing, circulation, disability*).

Neck injuries are divided into closed and opened ones.

#### 3.6.1. Closed neck injuries

Closed neck injuries are especially encountered in martial arts, traffic accidents, but also in intentional and unintentional suffocation attempts (strangulation, hanging, etc.), as well as other intentional and unintentional injuries, which is why they are often the subject of forensic expertise. Therefore, in addition to proper diagnostics and therapy, the physician must also conduct detailed documentation of events and procedures during the first appointment. With closed injuries on the skin, it is possible to see scratches, hematomas, or strangulation furrows, whereas deeper hematomas and edemas may compromise aerodigestive tracts and neurovascular structures of the neck. The clinical picture is prevailed by neck soreness and difficulty swallowing, which is accompanied by hoarseness and sometimes even inspiratory stridor when the larynx is affected. The respiratory airway is at risk in laryngeal injuries, but also in injuries of the lingual bone, trachea, and the like. With palpatory examination it is possible to find edema, sometimes even emphysema of the neck, but external examination should be performed along with a detailed oropharyngolaryngeal examination. In addition to proper clinical examination, the evaluation also requires radiological diagnostics for forensic purposes as well as exclusion of internal injuries. The primary rule in therapy is to open up the airway (antiedematous therapy, intubation if necessary, tracheotomy or coniotomy in the case of emergency – points A and B of emergency patient care). Formation of pulsating hematomas, absence of carotid arterial pulse, and the like are possible in blood vessel injuries, which certainly require neck exploration and proper hemostasis. First aid implies setting up a venous access and volume compensation along with, depending on the clinical picture, medicamentous therapy (points C and D of emergency patient care, i.e. ensuring circulation and administration of drugs). Neurological defects, fractures of the laryngeal and tracheal cartilage, esophageal

lesions, as well as other injuries of deeper structures, certainly require evaluation by competent specialists and tissue restoration according to surgical principles in specialist facilities.

### 3.6.2. Opened neck injuries

Opened neck injuries are most often encountered in traffic accidents and accidents at work or home (handling tools like saws, grinders, etc.). Sometimes bite wounds are also visible. As with closed injuries, open injuries also require a prompt assessment of the severity of the condition (especially proper assessment of lesions of vital neck structures) as well as adequate intervention and tissue restoration. The clinical picture depends on the extent of the injury and the structures affected. Dyspnea can be more or less pronounced, and if the laryngeal structures are affected, hoarseness is present. Crepitation and swelling of the neck are signs of subcutaneous emphysema and indicate a penetrating airway injury, sometimes with the presence of frothy blood at the site of injury. The first and basic rule is to open up the airway (intubation, coniotomy, tracheotomy). Bleeding can range from minimal to profuse, and any bleeding requires hemostasis. Special caution is required with penetrating injuries by foreign bodies, whose extraction on the field is not recommended, due to possible additional lesions of vascular structures and provocation of heavier bleeding, as well as lesions of adjacent structures during their manipulation. It is also important to recognize possible pulsating hematomas, as well as hypovolemic shock that may occur with severe bleedings. First aid in stopping the bleeding consists of compression, setting up a venous access, and emergency transport to a specialized facility. The therapeutic principles of restoration are the same as for closed injuries. After a more detailed neck exploration and toilet, as well as the removal of possible foreign bodies and impurities, wounds are treated according to the principles of plastic and reconstructive surgery. Deep or perforating wounds are sutured in layers from the depth toward the skin. Restoration within 6 to 12 hours is recommended, with antibiotic protection and tetanus vaccine or booster dose. In the case of delayed restorations and contaminated wounds (e.g. bites), wound debridement is required before suturing, and in some cases, only positional sutures are placed with adequate drainage.

### 3.6.3. Other neck injuries

**Thermal laryngeal injuries** by inhalation should definitely be referred to a specialist and the degree of airway damage should be examined in detail, followed by appropriate treatment.

**Corrosive esophageal injuries** are the result of ingested acids or bases. Ingestion of caustic substances most commonly occurs by accident

(more often in children) or intentionally (in a suicide attempt or in emotionally unstable persons). The passage of corrosive substances can damage the oral cavity, pharynx, esophagus, stomach, and/or the larynx. In the case of accidental ingestion of caustics, the patient tries to spit out the swallowed content using their defense mechanism, which sometimes leads to additional lesions. Localization and intensity of lesions depend on the type, amount and concentration, and the onset of action of the caustic agent. Injuries of the upper parts of the digestive tract can be divided into superficial and deep. Superficial injuries are manifested by edemas, erosions, and ulcerations, whereas necrosis and penetration into the surrounding structures are possible with deep injuries, which can lead to mediastinitis, peritonitis, and the like. Inducing vomiting and neutralization are usually contraindicated due to the risk of additional injuries and perforation. Depending on the symptoms and the degree of injury, therapy includes gastric aspiration (to reduce caustic resorption), endoscopic evaluation, analgesics, antibiotics, and drugs that reduce hydrochloric acid production. Most specialist facilities use corticosteroid therapy (reduction of edemas and delayed stenoses), sometimes with parenteral nutrition and measures to maintain airway patency if necessary.

Endoscopy, corticosteroid therapy, as well as views on indications for emergency surgical intervention are still, although mostly recognized, topics of discussion and differences of opinion among experts.

## 3.7. Foreign bodies

### 3.7.1. Oropharyngeal foreign bodies

Foreign bodies found in the oropharyngeal region are usually formed due to food remains (fish bones and the like) most often in the tonsils, especially if they are hypertrophic, or at the base of the tongue (lingual tonsils) and vallecula.

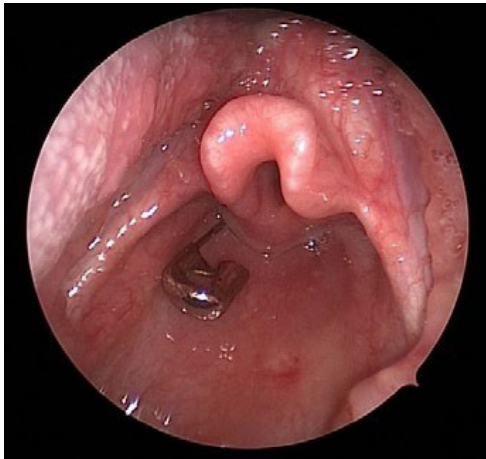
The main symptoms are pain and mild dysphagia. The patient usually locates the site of pain accurately and reports a stabbing sensation. Sometimes a foreign body, especially if the patient reports to the physician a day or two after the meal, can not be found (e.g. small bones that sink into the mucosa). Often only erosions and minor injuries caused by the passage of a swallowed foreign body can be noticed. The patient should be calmed down, explained that digestive enzymes in the mouth will decompose any foreign body residues, and protect them with antibiotics. If visible, the foreign body is extirpated with special medical forceps. Foreign bodies in the tonsils are usually not a problem and can be removed by a family physician, whereas foreign bodies on the base of the tongue are more difficult to reach and usually require specialist evaluation. In the case of a strong

urge to vomit and if the patient does not cooperate, it is necessary to wait 4 hours from the meal, and remove the foreign body under local anesthesia.

### 3.7.2. Hypopharyngeal foreign bodies

Foreign bodies in the hypopharynx are usually located in the pyriform sinuses, and in addition to the obvious foreign body, a closed or saliva-filled pyriform sinus also raises suspicion. The symptoms are similar to foreign bodies in the oropharynx, with more pronounced dysphagia, whereas the patient is less able to locate the exact site of pain. Therapy includes extirpation, usually performed by a specialist.

**Figure 16.** Foreign body in the hypopharynx



### 3.7.3. Esophageal foreign bodies

Foreign bodies in the esophagus are usually stuck at sites of physiological narrowing, but pathological strictures (due to tumorous processes, consequences of trauma or corrosion, or pressure of surrounding structures) should be excluded in the case of repeated episodes and detailed evaluation should be performed. Sometimes, instead of a foreign body, only the injured mucosa can be seen, although the patient reports a scratching sensation and the presence of a foreign body. The symptoms range from mild scratching to more or less difficulty swallowing. With severe obstructions, patients have an urge to vomit and/or vomit, and there is a lot of saliva in their mouth that they are unable to swallow. When the foreign body causes complete obstruction we can find saliva even in the oral cavity as a sign of impaired deglutition. One way to check if the patient can swallow is by giving him a glass of water (with large boluses inability to even drink water is noted). It is important to distinguish whether the food contains

bones, which can lead to esophageal perforation and mediastinitis. This requires urgent endoscopic evaluation and extraction, which is also necessary for sharp objects, coins, and in other cases of any obstruction that causes significant symptoms. In the case of milder symptoms, it is possible to relax the esophagus enough with antispasmodics and to stimulate a spontaneous passage. The use of various “softeners” such as milk and the like (which patients often resort to before visiting their physician) is not recommended. Foreign bodies are removed with special instruments, most often by endoscopic extraction.

#### 3.7.4. Laryngotracheobronchial foreign bodies

Foreign body aspiration is most common in children from 6 months to 5 years with the highest incidence in the second year of life. The diagnosis is based on the clinical picture of the so-called “penetration syndrome”.

A typical penetration syndrome is described as:

- sudden suffocation with cyanosis, explosive cough, and episodes of brief apnea
- occurring during the day in otherwise “healthy” person (usually a child)
- spontaneous resolution and asymptomatic phase, followed by a phase of pulmonary complications (in the form of bronchitis, atelectasis and “unilateral pneumonia”, bronchiectasis, and sometimes even severe complications such as pneumothorax, mediastinal emphysema, and the like).

The diagnosis is complemented by radiological and endoscopic evaluations, which are indicated even if there is a reasonable suspicion of a foreign body despite the absence of obvious symptoms.

#### 3.7.5. Laryngeal foreign bodies

Foreign bodies in the larynx are extremely rare. When they occur, due to the peculiarity of its shape, they are usually trapped at the level of the glottis or subglottis. If fatal asphyxia does not occur and if the foreign body allows partial ventilation, it is presented with laryngeal dyspnea, with episodes of spasm and a muffled voice. Symptoms usually appear suddenly, from entire health (for example, in an afebrile child during play), which helps in the differential diagnostics of laryngitis and requires urgent endoscopy. Peculiar cases of inhaled foreign bodies have been recorded such as blades of grass, pine needles etc. during mowing or walking in nature “stabbed” into the vocal cords or subglottic tissue. They are presented with intermittent seizures of pronounced laryngeal dyspnea and respiratory distress, cough, and periods of normal breathing after spasm.

**Remember:**

In cases of alternans of intermittent seizures of laryngeal dyspnea and cough with periods of normal breathing between spasms visualization of laryngeal structures and tracheal opening is necessary in order to exclude a laryngeal foreign body.

### 3.7.6. Tracheal foreign bodies

Foreign bodies in the trachea are life-threatening and represent a first-line emergency. These are foreign bodies that are large enough to pass through the subglottis, but too large to enter one of the main bronchi. A typical sign of a foreign body in the trachea is the so-called “ballotement”, i.e. respiratory disorders in the form of intermittent seizures of laryngeal dyspnea in alternation with expiratory dyspnea, caused by a change in the position of a foreign body due to a reflex attempt of expulsion (movement of the foreign body between the subglottis and bronchial bifurcation). The greatest danger of this localization is the entrapment of a foreign body in the subglottic region due to a cough attack, which can lead to a rapid worsening of dyspnea, even asphyxia.

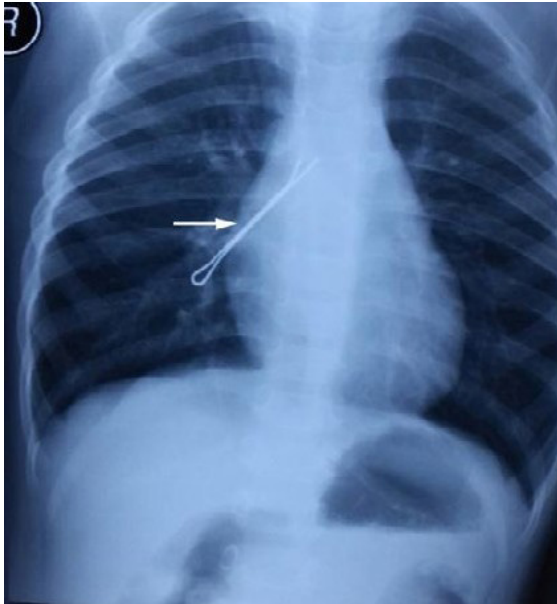### 3.7.7. Bronchial foreign bodies

Foreign bodies in the bronchi are the most common of all laryngotracheo-bronchial foreign bodies and are more frequently located in the right bronchus because of its more vertical position. It is accompanied by expiratory dyspnea with usually auscultatory attenuated breathing under the affected bronchus, but sometimes the symptoms are less pronounced, which hinders the diagnosis, especially in foreign bodies that are not radiologically visible. The radiological evaluation may show a foreign body if it is radiopaque (visible), it may show atelectasis or pulmonary emphysema below the affected bronchus, but it may also be normal and does not exclude a foreign body. Therefore, any penetration syndrome and suspected laryngotracheobronchial foreign body, as well as nonspecific laryngotracheal and unilateral bronchopulmonary symptoms, require further evaluation. A flexible endoscope is sufficient for diagnostic purposes, whereas rigid endoscopy is required for the extraction of a confirmed foreign body. Special attention is required for vegetative foreign bodies due to the gradual accumulation of fluid and swelling, which can turn a partial obstruction into a complete one, rapidly worsen dyspnea and compromise respiration. After extraction, they usually require antibiotic and corticosteroid treatment due to the often adjacent inflammatory process (especially if the extraction is performed with a delay).

It should be emphasized that even a nasal foreign body poses a risk of secondary inhalation.

In prevention, it is important to avoid giving peanuts and similar seeds to children under the age of 4, to control playing with small balls, beads, etc., and to keep small objects out of their reach.

**Figure 17.** Foreign body in the bronchus (X-ray)



### 3.8. Inflammation and complications

Inflammatory processes of the pharyngolaryngeal region are usually more common and more serious in children.

Of all the urgent inflammatory conditions which are the most common reason why anxious parents bring their child to the physician, **laryngitis** should definitely be emphasized. It can be divided into stridulous and edematous laryngitis.

**Spastic or stridulous laryngitis** is characterized by paroxysmal spasms that can be very impressive, with a severe cough accompanied by apnea, and sometimes even cyanosis of a few seconds, and a hoarse voice. The child is in a forced sitting position, “gaspings for air”. There is no dyspnea or chest retraction between episodes of spasm. There is no temperature because it is not an infection, and the blood count is normal. The evolution of this laryngitis is usually benign. Antiedematous therapy and antispasmodics are administered, whereas antibiotics are redundant and ineffective.



**Edematous laryngitis** is divided according to localization into subglottic (the most common cause of dyspnea in preschool children) and supraglottic (epiglottitis).

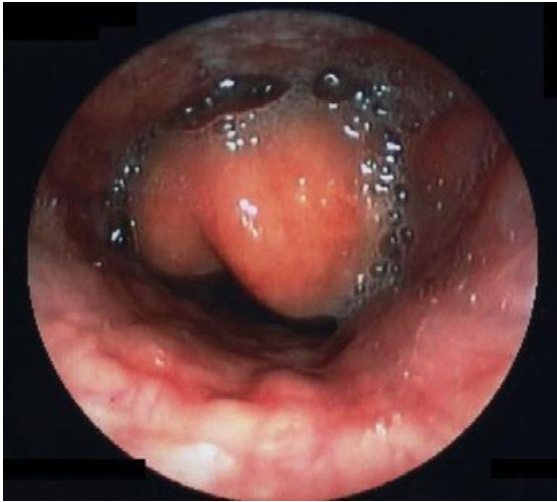**Subglottic laryngitis** implies thickening of the subglottic structures and most often occurs as a result of viral inflammation with an allergic predisposition. It usually occurs before dawn, which facilitates the differential diagnostics toward the foreign body that should be suspected if dyspnea occurs during the day, usually during play, in an otherwise healthy child. As with stridulous laryngitis, subglottic laryngitis is manifested by shortness of breath with inspiratory stridor and a hoarse voice. The child is "gasping for air" and coughing. There is no neutrophilia in the blood count because it is not a bacterial inflammation. Clinical examination reveals a calm, nonirritated epiglottis, with visible edema and "pad-like" swelling of sublaryngeal soft tissues.

Antibiotic therapy is ineffective and unnecessary. Antiedematous therapy is administered with parenteral corticosteroid preparations and adrenaline inhalation. Nowadays, the need for tracheotomy is extremely rare. The symptoms of both spastic and subglottic edematous laryngitis are most dramatic at dawn or early in the morning when the airways are physiologically narrowest due to the cortisol cycle. For first aid, concerned parents (who sometimes call an ambulance) should be told to calm the child down and place them next to an open window or on a balcony (fresh air helps relieve dyspnea). The child can also be seated in the bathroom next to running cold water. The air in the room in which the child sleeps should be moistened (put a wet sheet or towel over the child's bed or place a pan of water on the radiator), as inhalations are also helpful in relieving the symptoms of the child. Allergological evaluation is subsequently required.

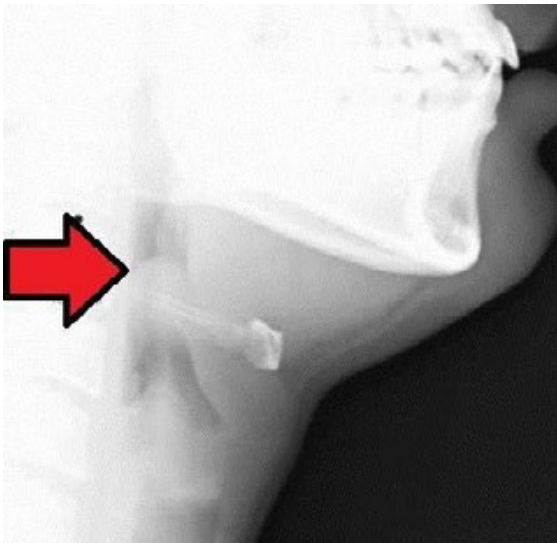
**Epiglottitis** is an inflammation of the epiglottis, most commonly caused by the bacterium *Haemophilus influenzae*. It is rarer but more severe than subglottic laryngitis. It most commonly occurs around the third year of life and is more frequent in boys. The leading symptoms are severe dysphagia, which sometimes leads to saliva stagnation in the oral cavity, high fever, sore throat, and inspiratory stridor, which upsets parents the most. Sometimes cyanosis and chest retraction also occur. The voice is muffled but not hoarse as in subglottic laryngitis, whereas the cough sounds normal. The child is pale, in a forced sitting position (the supine position should be avoided as it worsens dyspnea). The basis of diagnostics includes a deeper oropharyngoscopic examination with a spatula pressed against the base of the tongue, which provokes elevation of the epiglottis in smaller children. A red, swollen, and thickened epiglottis (microabscesses) is a characteristic of epiglottitis. In older children and adults, the examination is performed with a laryngeal mirror, indirect laryngoscopy, or flexible endoscope. The blood count shows leukocytosis and neutrophil-

ia in favor of bacterial inflammation. The basis of therapy includes high doses of broad-spectrum antibiotics (most often third-generation cephalosporins) and antiedematous therapy. The child should be hospitalized and observed, possibly even intubated in case the symptoms worsen, whereas the need for tracheotomy in the antibiotic era is fortunately extremely rare.

**Figure 18.** Endoscopic presentation of epiglottitis



**Figure 19.** Radiological image of epiglottitis (X-ray)



**Table 12.** Epiglottitis – symptomatology and treatment procedure

<b>EPIGLOTTITIS</b>	
<b>Symptoms/cause</b>	<b>Procedure/therapy</b>
<ul style="list-style-type: none"> <li>• sore throat, difficulty swallowing, hypersalivation, high fever</li> <li>• inspiratory stridor</li> <li>• forced sitting position of the child with their mouth open</li> <li>• Haemophilus influenzae bacterium</li> </ul>	<ul style="list-style-type: none"> <li>◇ <b>refer to ENT</b></li> <li>• laboratory findings – leukocytosis</li> <li>• antibiotics and corticosteroids parenterally</li> <li>• intubation or even tracheotomy if necessary</li> </ul>

**Laryngitis** in adulthood is less common and is accompanied by the same but usually milder symptoms than in children due to wider airways, which makes it less dangerous.

Other dangerous inflammations accompanied by febrility, dyspnea, and poor general condition, such as diffuse laryngotracheobronchitis, which usually occurs in young children, need to be identified in time and definitely treated in specialized facilities. The clinical picture is dominated by signs of severe infection with high fever, shivering, and asthenia. The initial laryngeal dyspnea soon turns into a mixed inspiratory-expiratory one, and with the progression of the disease, there are auscultatory signs of lung affection. Apart from antiedematous and antibiotic therapy, lavages of the tracheobronchial tree are also applied, which sometimes require, in addition to intubation, tracheotomy that facilitates airway clearance.

**Mucosal edemas of the pharyngolaryngeal region** usually occur due to an allergic reaction to, for example, foods rich in histamine (e.g. blue fish, red wine), insect bites (wasps, bees), and the like. They can be more or less dangerous, depending on the region affected by the swelling. For example, uvular swelling will cause an unpleasant sensation of a foreign body, with a possible urge to vomit and, if more pronounced, difficulty swallowing.

On the other hand, swelling of the tongue (e.g. in bee stings) can lead to partial or complete airway obstruction and may require antiedematous and antiallergic therapy (corticosteroids and antihistamines) and, if necessary, intubation.

**Tonsillopharyngitis** is a common cause of patients coming to emergency rooms. It is important to distinguish whether the inflammation is viral or bacterial in order to determine proper therapy and avoid the unnecessary administration of antibiotics in viral infections. The assessment is based on Centor criteria.

**Table 13.** Centor criteria

<b>Clinical finding</b>	<b>Score</b>
Tonsillar exudate	1
Fever > 38 °C	1
Absence of cough and catarrhal symptoms	1
Cervical lymphadenopathy	1

The clinical presentation of viral infections is most commonly predominated by catarrhal symptoms, i.e. both the pharynx and other adjacent mucosas are affected (conjunctiva; nasal mucosa; and sometimes even the ear), whereas palatine tonsils in bacterial tonsillitis are irritated the most and the reaction of adjacent mucosas is much weaker.

It should be emphasized that sometimes only the differential blood count can safely allow differentiation of streptococcal angina from infectious mononucleosis syndrome and other viral infections that can also manifest with white deposits on the tonsils and even pseudomembranes.

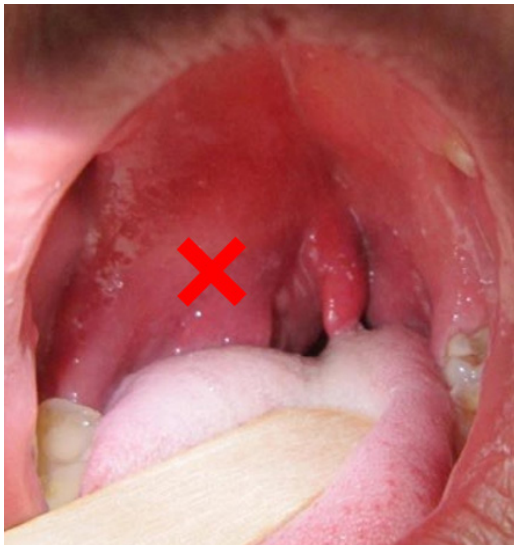
Therapy includes rest, proper hydration, humidification, gargling, and oral hygiene, as well as symptomatic therapy with analgesics and antipyretics (for febrility over 38 °C). Caution is necessary with children and adolescents, in whom the use of acetylsalicylic acid should be limited due to the potential development of dangerous Reye's syndrome (for details see additional literature). Antibiotics are administered in the case of a proven bacterial infection or severe clinical picture according to the sum of Centor criteria.

**Table 14.** Treatment of tonsillopharyngitis

<b>Sum of Cento criteria</b>	<b>Approach</b>
≤ 1	<ul style="list-style-type: none"> <li>• symptomatic treatment</li> <li>• introduction of antibiotic therapy is not recommended</li> <li>• patient monitoring</li> </ul>
≥ 2	<ul style="list-style-type: none"> <li>• prove streptococcal infection by pharyngeal swab and bacteriological culture or rapid strep test → then administer antibiotics (penicillins; in the case of allergy → macrolides)</li> <li>• administration of antibiotics is recommended immediately in suspicion of peritonsillar abscess or severe clinical picture</li> </ul>

**Peritonsillitis and peritonsillar abscess.** Peritonsillitis is an inflammation of the peritonsillar tissue that results from the propagation of tonsillitis. The main symptoms are worsening of the clinical picture, difficulty swallowing, trismus, and irradiation of pain towards the ear. Bad breath and saliva stagnation in the oral cavity occur with severe swallowing difficulties. It is usually accompanied by angular lymphadenitis and febrility. Oropharyngoscopically, redness is visible with peritonsillar tissue edema, usually unilateral, without a proper abscess formed. When a peritonsillar abscess is formed, swelling and redness are more pronounced, the anterior palatal arch is protruded toward the median line, and the uvula is displaced to the opposite side.

**Figure 20.** Peritonsillar abscess (right-sided). Incision site marked (red X)



The blood count in peritonsillitis and peritonsillar abscess shows leukocytosis with increased sedimentation (unlike allergic edemas in which the blood count is normal). In addition to symptomatic therapy (analgesics, hydration, and the like), the treatment also includes high doses of antibiotics, whereas incision and drainage are performed in the case of abscess formation. The incision is performed at the site of the strongest protrusion of the anterior palatal arch, usually in the middle of the imaginary line between the uvula and the posterior molar, with dilatation over the next several days.

**Inflammations of salivary glands.** Acute suppurative sialadenitis most commonly occurs due to hyposecretion and ductal obstruction (sialolithiasis). The most common causative agent is *Staphylococcus aureus*,

followed by viridans streptococci, *Haemophilus influenzae*, and various anaerobic bacteria. The clinical picture is characterized by a sudden onset with hard glandular edema accompanied by soreness, sometimes even skin redness, and febrility and odynophagia in severe infections. The diagnosis is primarily set clinically, whereas parotitis may be accompanied by elevated serum amylase. It is crucial to examine the gland and the excretory duct properly. The appearance of a purulent discharge at the excretory duct opening during the massage of the gland confirms the diagnosis and does not require further diagnostic evaluation. Therapy is based on hydration, sialogogues (substances that stimulate salivation such as citrus and acidic foods), cold compresses, massage of the gland, proper oral hygiene, and systemic administration of antibiotics (co-amoxiclav, cephalexin, and the like are recommended). In the case of abscess formation, surgical incision and drainage are also required. Additional diagnostic imaging is necessary in cases of recurrence and in suspicion of complications or sialolithiasis. Recurrent and chronic sialadenitis are more common in immunocompromised patients, patients with autoimmune diseases (e.g. Sjögren's syndrome), and patients after chemoradiotherapy.

**Inflammations of the submandibular and submental space** are most often caused by the propagation of the inflammation of salivary glands or odontogenic processes. In addition to the symptoms typical for inflammations in this region, such as difficulty swallowing and febrility, these inflammations are also manifested by elevation of the floor of the oral cavity and elevation of the tongue, which can lead to airway obstruction in severe swellings. A special type of inflammation of the floor of the oral cavity is the so-called "Ludwig's angina", which is characterized by hard swelling and redness of the submental region. It can also compromise the airway due to tongue retroposition with progressive onset of inspiratory dyspnea. Therapy involves high doses of broad-spectrum antibiotics (effective on anaerobic bacteria as well) with incisions and abscess drainage. In the era of antibiotics, the need for intubation and tracheotomy is extremely rare, but should not be ruled out. Therefore, observation is required in specialist facilities.

**Abscesses of deep neck spaces.** Propagation of inflammation from the peritonsillar tissue, odontogenic inflammations, and inflammations of salivary glands, severe inflammations of the pharyngolaryngeal region, traumas, foreign bodies, and sometimes even iatrogenic interventions can all lead to the formation of parapharyngeal abscess. Being that vital neurovascular structures are located in this space, inflammations of this region can lead to severe and sometimes life-threatening complications, most often in immunocompromised patients. If the inflammation affects the anterior segment, the symptoms are more pronounced.

Patients have severe dysphagia, painful and swollen neck, high febrility, and poor general condition. In more pronounced abscesses, the patient's head and neck are tilted to the side of the abscess, and a protrusion of the lateroposterior pharyngeal wall toward the medial line can be seen at the oropharyngoscopic examination. Unlike the anterior segment, the posterior part of the parapharyngeal space (which contains neurovascular structures and is more dangerous) usually has less pronounced symptoms and is more difficult to diagnose. The trismus is usually poorly pronounced and discrete, and only later does dislocation of the posterior pharyngeal wall occur. Any suspicion of an abscess in the aforementioned region requires hospital treatment, with high doses of antibiotics, surgical incision, drainage, and sometimes even opening the airways.

**The retropharyngeal space** is most often affected in children up to the age of 5, after which involution of lymph nodes in this region occurs and inflammations are less frequent. The clinical picture of a child with inflammation of the retropharyngeal space is characterized by torticollis, lymphadenitis, neck pain, and poor general condition. Difficulty swallowing occurs, whereas larger abscesses can even compromise breathing. Hospitalization and observation are required, along with the drainage of the abscess after previously opening up the airways (intubation, tracheotomy if necessary).

From the previously described deep neck spaces, the infection can also propagate to the so-called "dangerous space", and the process can further spread to the mediastinum. **Mediastinitis** is still a very serious and life-threatening condition, and any suspicion of the propagation of inflammations from these regions, with worsening of the patient's general condition, requires detailed diagnostic evaluation and timely treatment.

## Conclusion

Otorhinolaryngological problems are common in everyday practice as well as their emergencies. Given that these are functionally and aesthetically important parts of our body, it is important that the primary care physician correctly recognizes the pathology, assesses its severity, and acts appropriately.

In addition to vital structures such as upper respiratory airways and neurovascular structures of the head and neck, whose integrity violation is vitally threatening and represents a first-line emergency, other symptomatology of this region can, if not treated properly and in time, also have severe consequences and sometimes even be life-threatening.

Head and neck injuries, in addition to functional, sometimes also have severe aesthetic as well as emotional consequences.

Due to their anatomical specificity and close relationship with the surrounding important structures and organs, inflammatory processes in otorhinolaryngology can also have consequences on their function. Therefore, they represent an additional danger and require faster intervention than similar processes in another region. Thus, for example, a nasal furuncle is more dangerous than a furuncle of the leg, middle ear inflammation can spread to cerebral structures, sinusogenic processes can impair vision, processes in deep neck spaces can spread to the mediastinum, and so forth.

It should be emphasized that the symmetry of certain structures is important in otorhinolaryngology and that any asymmetric finding, such as unilateral purulent secretion (possible foreign body or tumor symptom) or especially clear nasal secretion (possibility of liquorrhea), pronounced asymmetry of the tonsils (abscess, tumor), asymmetric tongue motility to one side (possible first sign of compression by a tumorous process of the XII cranial nerve) and the like, requires a search for the cause and detailed evaluation, and should not be neglected.

Special caution is necessary with young children in whom, due to the peculiarities of anatomical structures (small airways, more horizontally placed tube, immaturity of cartilages, and the like), inflammatory or allergic processes can progress rapidly, and sometimes timely intervention is crucial.

Apart from the anatomy, the pediatric population is more sensitive due to the immaturity of the immune system, and this risk group includes all other immunodeficiencies and hematological diseases.

Caution is also necessary with diabetics in whom, due to frequent polyneuropathy, the classic symptoms are sometimes minimal and the pain is



significantly lower. Sometimes the severity of the inflammatory process is underestimated, which delays the patient's visit to the physician; with occasionally already present propagation into the surrounding vital structures.

It is important to emphasize that sensory organs (hearing, balance, smell, and taste) are located in this region and that disorders of these senses require detailed evaluation and adequate and timely treatment. Thus, for example, hearing loss, if it occurs suddenly and if treated incorrectly, can remain permanent, and being that it usually affects younger people, it can significantly affect their future lives. Loss of balance is very constraining. Although the sense of smell is not necessary for daily functioning, its loss significantly impairs the quality of life, as well as the absence of taste.

Therefore, patient evaluation and assessment of what is urgent in otorhinolaryngology should not ignore such symptomatology, and not only injuries, suffocations, and bleedings should be considered emergencies. On the other hand, purulent angina does not require urgent otorhinolaryngological evaluation, but it is often encountered in subspecialist otorhinolaryngological emergency rooms. If signs of tonsillopharyngitis persist, the patient should be referred to an infectologist, and only if abscessing occurs does it require evaluation by an otorhinolaryngologist and urgent surgical intervention.

Finally, although some symptoms, such as hearing loss, may not always seem serious to us, it does not mean they are less urgent and important because they can result in permanent damage to the senses and organ lesions. The quality of life should be sought in the experience of the world around us: to find beauty in small things like the smell of roses, delicious food, the sound of good music, and the like. Therefore, in addition to resolving obvious emergencies, we should not neglect other symptoms and ailments that also require proper evaluation and urgency level assessment in order to achieve and maintain a patient's psychophysical balance and health.

In conclusion, knowledge of anatomy and pathophysiology along with proper history-taking and clinical examination are the foundations of good diagnostics, appropriate therapy, and the essence of being a good physician.

## Bibliography

1. Bumber, Ž., Katić, V., Nikšić-Ivančić, M., Pegan, B., Petrić, V., Šprem, N. et al. (2004). *Otorinolaringologija*. Medicinska biblioteka, Naklada Ljevak, Zagreb.
2. Chabolle, F., Garabedian, E.N. (1994). *Décision en ORL*. Vigot, Paris.
3. Legent, F., Fleury, P., Narci, P., Beauvillain, C. (1996). *ORL: Pathologie cervico-faciale*. Masson, Paris.
4. Sauvage, J.P. (2016). *Guide d'ORL: Clinique et thérapeutique*. Elsevier Masson, Paris.
5. Stevenson, N., Corbridge, R. (2010). *Oxford handbook of ENT and head and neck surgery*. Oxford University Press, Oxford.
6. Swibel Rosenthal, L.H., Patadia, M.O., Stankiewicz, J.A. (2016). *Otolaryngology: a color handbook*. CRC Press, Boca Raton, FL.
7. Tran Ba Huy, P. (1996). *O.R.L.* Universités francophones, Ellipses, Paris.

## List of figures with sources and corresponding licenses

Figure 1.	Klaus, D.P. (2012). <a href="https://commons.wikimedia.org/wiki/File:Hematoma_ear.jpg">https://commons.wikimedia.org/wiki/File:Hematoma_ear.jpg</a> . (CC BY 3.0 DE)
Figure 2.	Hawke, M. (2012). <a href="https://commons.wikimedia.org/wiki/File:Traumatic_Perforation_of_the_Tympanic_Membrane.jpg">https://commons.wikimedia.org/wiki/File:Traumatic_Perforation_of_the_Tympanic_Membrane.jpg</a> . (CC BY 4.0)
Figure 3.	From: Fidan, V., Ozcan, K., Karaca, F. (2011). <i>Bilateral hemotympanum as a result of spontaneous epistaxis</i> . Int J Emerg Med. 2011; 4:3. <a href="https://www.ncbi.nlm.nih.gov/pmc/articles/PMC3051890/">https://www.ncbi.nlm.nih.gov/pmc/articles/PMC3051890/</a> . (CC BY 2.0)
Figure 4.	Modified from: Lynch, P.J. (2006). <a href="https://commons.wikimedia.org/wiki/File:Bells_palsy_diagram.svg">https://commons.wikimedia.org/wiki/File:Bells_palsy_diagram.svg</a> . (CC BY 2.5)
Figure 5.	From: Herrick, C.B. (1899). <i>Railway surgery: a handbook on the management of injuries</i> . New York: W. Wood & Co. Downloaded from: <a href="https://www.flickr.com/photos/126377022@N07/14759134172">https://www.flickr.com/photos/126377022@N07/14759134172</a> . (a public good)
Figure 6.	From: Ribeiro, F.A.Q. (2008). <i>Foreign body in the Eustachian tube: case presentation and technique used for removal</i> . Revista Brasileira de Otorrinolaringologia, 74(1), 137–142. <a href="https://dx.doi.org/10.1590/S0034-72992008000100022">https://dx.doi.org/10.1590/S0034-72992008000100022</a> . (CC BY-NC 4.0)

Figure 7.	Welleschik, B. (2006). <a href="https://commons.wikimedia.org/wiki/File:-Mastoiditis1.jpg">https://commons.wikimedia.org/wiki/File:-Mastoiditis1.jpg</a> . (CC BY-SA 3.0)
Figure 8.	Ragessos (2013). <a href="https://commons.wikimedia.org/wiki/File:Young_child_with_nosebleed,_smiling_cropped.jpg">https://commons.wikimedia.org/wiki/File:Young_child_with_nosebleed,_smiling_cropped.jpg</a> (CC BY-SA4.0)
Figure 9.	Bode, J., Byrne, E. (2016). TXA In epistaxis [NUEM Blog. Expert Commentary By Vertovec A]. Downloaded from: <a href="http://www.nuemblog.com/blog/txa-epistaxis">http://www.nuemblog.com/blog/txa-epistaxis</a> . (CC BY-NC 4.0)
Figure 10.	Oštarijaš, E. (2018). <i>Instrumentarij za tamponadu nosa</i> . (CC BY 4.0)
Figure 11.	Afrodriquezg (2014). <a href="https://commons.wikimedia.org/wiki/File:Nasal_Septal_Hematoma.jpg">https://commons.wikimedia.org/wiki/File:Nasal_Septal_Hematoma.jpg</a> . (CC BY-SA 4.0)
Figure 12.	Rls (2005). <a href="https://commons.wikimedia.org/wiki/File:BrokenNose.jpg">https://commons.wikimedia.org/wiki/File:BrokenNose.jpg</a> . (CC BY-SA 3.0)
Figure 13.	Downloaded from: <a href="https://momwithastethoscope.wordpress.com/">https://momwithastethoscope.wordpress.com/</a> (12.4.2018.)
Figure 14.	Oštarijaš, E. (2018). <i>Instrument za ekstrakciju stranog tijela iz nosa</i> . (CC BY 4.0)
Figure 15.	Afrodriquezg (2014). <a href="https://commons.wikimedia.org/wiki/File:Celulitis_Periorbitaria_(Preseptal).JPG">https://commons.wikimedia.org/wiki/File:Celulitis_Periorbitaria_(Preseptal).JPG</a> . (CC BY-SA 3.0)
Figure 16.	From: Yung, A., Saadat, H., Grischkan, J., Tobias, J. (2015). <i>Perioperative care of an infant with an open safety pin in the hypopharynx</i> . Journal Of Medical Cases, 6(4), 146–149. <a href="http://www.journalmc.org/index.php/JMC/article/view/2017/1471">http://www.journalmc.org/index.php/JMC/article/view/2017/1471</a> . (CC BY-NC 4.0)
Figure 17.	From: Wang, Z. et al. (2015). <i>Tracheobronchial foreign bodies in children – a retrospective study of 2,000 cases in Northwestern China</i> . Therapeutics and Clinical Risk Management, 1291. doi:10.2147/tcrm.s86595. (CC BY-NC 3.0)
Figure 18.	Fujisawa, T. (2013). <a href="https://commons.wikimedia.org/wiki/File:Epiglottitis_endoscopy.jpg">https://commons.wikimedia.org/wiki/File:Epiglottitis_endoscopy.jpg</a> . (CC BY-SA 3.0)
Figure 19.	Med Chaos (2011). <a href="https://en.wikipedia.org/wiki/File:Epiglottitis.jpg">https://en.wikipedia.org/wiki/File:Epiglottitis.jpg</a> . (CC0 1.0)
Figure 20.	Modified from: Heilman, J. (2011). <a href="https://commons.wikimedia.org/wiki/File:PeritonsilarAbscess.jpg">https://commons.wikimedia.org/wiki/File:PeritonsilarAbscess.jpg</a> . (CC BY-SA 3.0)

ISBN 978-953-8341-10-6 (PDF)