

# Tip of the iceberg: Immunohistochemical markers reveal malignant transformation underneath a vocal polyp surface

---

**Braut, Tamara; Krstulja, Mira; Marijić, Blažen; Maržić, Diana; Kujundžić, Milodar; Zamolo, Gordana; Vučinić, Damir; Oštarijaš, Eduard**

*Source / Izvornik:* **Medicina Fluminensis, 2021, 57, 171 - 176**

**Journal article, Published version**

**Rad u časopisu, Objavljena verzija rada (izdavačev PDF)**

[https://doi.org/10.21860/medflum2021\\_371640](https://doi.org/10.21860/medflum2021_371640)

*Permanent link / Trajna poveznica:* <https://um.nsk.hr/um:nbn:hr:184:660259>

*Rights / Prava:* [Attribution 4.0 International](#)/[Imenovanje 4.0 međunarodna](#)

*Download date / Datum preuzimanja:* **2024-08-25**



*Repository / Repozitorij:*

[Repository of the University of Rijeka, Faculty of Medicine - FMRI Repository](#)



# Tip of the iceberg: Immunohistochemical markers reveal malignant transformation underneath a vocal polyp surface

## Vrh ledene sante: Maligna transformacija ispod površine glasnica otkrivena imunohistokemijskim markerima

Tamara Braut<sup>1</sup>, Mira Krstulja<sup>2</sup>, Blažen Marijić<sup>1</sup>, Diana Maržić<sup>1</sup>, Milodar Kujundžić<sup>1</sup>, Gordana Zamolo<sup>2</sup>, Damir Vučinić<sup>3</sup>, Eduard Oštarijaš<sup>4\*</sup>

**Abstract.** Novel molecular techniques including markers of laryngeal carcinogenesis could improve the difficult diagnosis of a wide array of laryngeal polypoid changes. The case reported herein shows that not every clinically diagnosed vocal fold polyp is a benign lesion as mostly considered in the literature. Further assessment including carcinogenesis markers detected a nest of micro-invasive squamous cell carcinoma. Therefore, we recommend biopsy backed up with immunohistochemical analysis whenever there is a suspicious polypoid formation in order to exclude or confirm a malignant transformation because of the possibility of multi-focal growth in the active laryngeal epithelium.

**Key words:** epithelial atypia; immunohistochemistry; laryngeal polyps; molecular markers; squamous cell carcinoma

**Sažetak.** Nove molekularne tehnike, uključujući markere laringealne karcinogeneze, mogu pridonijeti diferencijalnoj dijagnozi širokog spektra polipoidnih promjena grkljana. Prikazujemo slučaj koji ukazuje na to da nije svaka klinički dijagnosticirana polipoidna lezija glasnica benigna kao što se obično navodi u literaturi jer smo daljnjom imunohistokemijskom obradom otkrili žarište mikroinvazivnog planocelularnog karcinoma. Stoga kod svake polipoidne tvorbe grkljana preporučujemo biopsiju popraćenu imunohistokemijskom analizom markera kako bi se potvrdila ili isključila maligna transformacija zbog poznate sklonosti multifokalnom rastu u aktivnom epitelu grkljana.

**Ključne riječi:** epitelna atipija; imunohistokemija; molekularni markeri; planocelularni karcinom; polip grkljana

<sup>1</sup>University of Rijeka, Faculty of Medicine, Department of Otorhinolaryngology, Rijeka, Croatia

<sup>2</sup>University of Rijeka, Faculty of Medicine, Department of General Pathology and Pathological Anatomy, Rijeka, Croatia

<sup>3</sup>Clinic for Radiotherapy and Oncology, Clinical Hospital Centre of Rijeka, Rijeka, Croatia

<sup>4</sup>Institute for Translational Medicine, Medical School, University of Pécs, Pécs, Hungary

**\*Corresponding author:**

Eduard Oštarijaš, M.D.  
University of Pécs, Medical School,  
Institute for Translational Medicine,  
Szigeti út 12., 7624 Pécs, Hungary  
E-mail: eduard.ostarijas@gmail.com

<http://hrcak.srce.hr/medicina>

## INTRODUCTION

Differential diagnosis of dysphonia and prolonged hoarseness is one of the most difficult ones in an otorhinolaryngologist's daily practice. It often causes dilemmas in the protocol, diagnostics, treatment, and follow-up because of its broad array of laryngeal pathologies. These can range from a variety of inflammatory conditions, vocal fold lesions (both benign and malignant), and finally functional and neurologic disorders.

Not every clinically diagnosed vocal fold polyp is a benign lesion as mostly considered in literature. We present the case of a micro-invasive squamous cell carcinoma discovered in a clinically diagnosed polypoid formation.

A number of noxae frequently cause chronic vocal fold irritation (smoking, drinking, gastroesophageal reflux, vocal abuse, etc.)<sup>1-5</sup>. The following regenerative and healing processes sometimes lead to excessive stromal growth. Besides causing stromal expansion, constant irritation also affects the overlying epithelium, inducing changes spanning from simple hyperplasia to different degrees of structural alterations and possible atypia. Similar noxae are reported as one of the major causes of laryngeal benign, precancerous, and cancerous lesions. These data imply that there are common risk factors for all degrees of malignancy and that caution in evaluation is needed.

Macroscopically, stromal expansions are seen as vocal fold polypoid changes and are mostly considered in the literature as benign growths of vocal cords<sup>6-8</sup>.

There are disparate definitions in literature considering vocal cord polyps. Regarding their histology, some authors<sup>9-11</sup> do not differentiate them from nodules, while others<sup>6-8</sup> do. The majority of authors agree that polyps represent swelling of lamina propria with inflammation and enlargement of vascular spaces, with an absence of strong epithelial alteration<sup>3</sup>. In literature, many different classifications of histopathological types of polyps are found<sup>6,11</sup>. Previous research was

mainly focused on stromal changes (examining laminin, type IV collagen, basal membrane, etc.)<sup>3,6,12,13</sup>, while an investigation of squamous cell carcinoma (SCC) markers in the overlying epithelium is lacking.

We ask ourselves what a polypoid formation represents, and who diagnoses a patient with a polyp diagnosis. How reliable is the clinical diagnosis of a polyp without further histopathological analysis? Do all polypoid changes need a biopsy to confirm the diagnosis and to exclude a malignant transformation?

The aim of this mini-review was to answer these questions and to describe the case of micro-invasive squamous cell carcinoma discovered in a clinically diagnosed polypoid formation.

Additionally, we present the case of a micro-invasive squamous cell carcinoma discovered in a clinically diagnosed polypoid formation, in which immunohistochemical methods using known squamous cell carcinoma (SCC) markers, as well as introducing a novel marker IMP3, for which interest in carcinogenesis of other malignancies is escalating, contributed to confirmation of diagnosis.

## CASE REPORT

A 58-year-old man presented to our otorhinolaryngology ambulatory practice in March 2017 complaining of voice hoarseness and heartburn. In his archives, diabetes, polyneuropathy, hypertension, and hyperlipoproteinaemia were noted, but no previous otorhinolaryngological workup was performed. Flexible nasolaryngoscopy discovered a polypoid formation in the anterior third of the left vocal cord and erythema of arytenoid regions. The working diagnoses were laryngeal polyp and posterior laryngitis, and ablation of the vocal cord by microlaryngoscopy (MLS) was performed.

The intraoperative macroscopic appearance was described as a fibro-vascular polyp occupying the anterior two-thirds of the left vocal cord (2.0×0.5×0.2 cm in size). Histopathological examination revealed ulcerations, parakeratosis, focal hypergranulosis and squamous metaplasia of the respiratory epithelium, and discovered a suspected focus of in-situ squamous cell carcinoma ac-

According to the latest classifications<sup>2,14</sup>, following which the patient underwent another, extended procedure. On further histopathological assessment, microscopically, in the anterior part of the polypoid lesion, the multi-layer squamous epithelium displayed a lack of maturation and polarity. A strong inflammatory reaction of the underlining stroma was noticed, in which a small area of an initial invasion of atypical epithelium sized 2 mm was detected. The posterior parts of the vocal cord showed only inflammatory changes with mild dysplasia.

Further, immunohistochemical (IHC) analysis of five molecular markers of laryngeal carcinogenesis (p53, cyclin D1, Ki-67, epidermal growth factor receptor (EGFR), and insulin-like growth factor mRNA-binding protein 3 (IMP3)), was performed according to the protocol described beforehand<sup>2</sup>. The results of p53 (Fig. 1), as well as cyclin D1 and Ki-67 immunostaining, showed a clear nuclear reaction and pattern typical for dysplastic lesions with a clear increase of positive cells in the squamous carcinoma nest. This was especially well followed for EGFR staining (Fig. 2). We also report IMP3 immunostaining that showed positivity in single cells or a small group of cells in the carcinoma nest (Fig. 3).

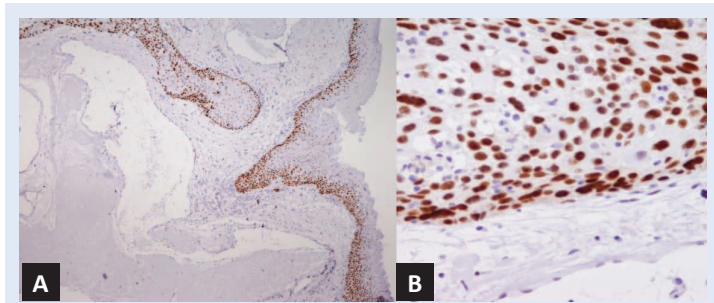
The final pathological report following detailed histopathological analysis supported by immunohistochemical methods confirmed the diagnosis of multi-focal atypia with a nest of micro-invasive squamous cell carcinoma.

Based upon the pathological finding, a complete standard workup for SCC (including ultrasonic and radiological assessment, as well as interdisciplinary consultations) found no regional nor distant metastases, therefore the final diagnosis with T1N0M0<sup>15</sup>.

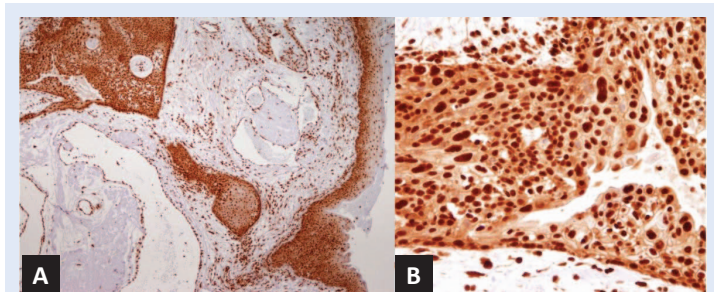
On the last head-and-neck oncological check-up, 18 months after surgery the patient was free of disease with no recurrence.

## DISCUSSION

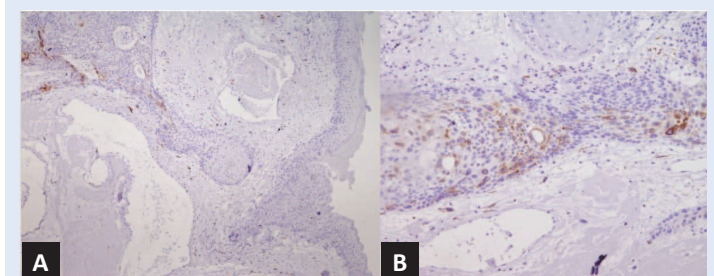
Polypoid changes of vocal folds still represent an object of debate regarding classification, follow-up, and treatment due to a lack of acknowledged consensus on both optimal nomenclature and treatment.



**Figure 1.** Biopsy specimen representing a fibrovascular polyp with a high-grade dysplastic epithelium and a squamous cell carcinoma nest formation. A. Immunohistochemical staining with p53 showing nuclear positivity in basal and suprabasal cells in the dysplastic region (magnification 40×). B. A detail of the carcinoma nest formation with much stronger p53 immunostaining noticed in malignant squamous epithelium (magnification 200×).



**Figure 2.** A. EGFR displaying positivity throughout the epithelial thickness in the dysplastic region of the fibrovascular polyp (magnification 40×). B. Increased EGFR immunoreactivity is present in squamous carcinoma cells (magnification 200×).



**Figure 3.** A. IMP3 immunostaining of the polyp's dysplastic epithelium displaying a negative reaction in the region without malignant transformation (magnification 40×). B. A detail of malignant epithelium with focal positive IMP3 staining in some cells or small groups of cells (magnification 200×).

The pathomorphological diagnosis of polyps sometimes differs from that of the clinician. In these stromal growths, the epithelium should not present atypical changes, and, if such changes are present, they are usually mild.

Although IHC analysis is usually used for precancerous lesions, we report a case of a polypoid le-

sion in which IHC analysis contributed to early detection and confirmation of a squamous cell carcinoma nest, improving the pathologist's final report.

This paper presents a patient that came to the otorhinolaryngological department because of hoarseness and had a clinically typical polypoid change in the anterior third of the left vocal cord. The patient had a history of diabetes, multiple other medical problems, and was reluctant to undergo biopsy. After persuasion and explanation

Careful assessment of each patient is needed while taking into account all medical history and risk factors. We recommend biopsy backed up with immunohistochemical analysis whenever there is a suspicious polypoid formation. Such approach is advised in order to confirm or exclude malignant transformation in fibrovascular polyps.

that the voice will not reconstitute without reduction of the polypoid mass by microlaryngoscopy and that conservative treatment was unadvised in his case, the patient accepted to be submitted to operative treatment. The histopathological examination discovered troublesome epithelium with multi-focal high-grade atypia in the anterior third of the vocal cord and confirmed a small area sized 2 mm with squamous cell carcinoma invasion into the stromal tissue. The pathologist expanded the analysis with immunohistochemical analysis of SCC markers, usually performed on pre- and cancerous lesions, and not routinely used for polyps. Besides the most commonly analysed markers of squamous cell carcinogenesis, including Ki-67, p53, cyclin D1, and EGFR, a novel marker recently increasingly investigated in carcinogenesis IMP3, was examined. There are only a few available data on this oncofetal protein in head and neck oncology<sup>16,17</sup> and scarce research on laryngeal tissue, which gave us incitement for its inclusion in this investigation.

These markers are currently applied at our otorhinolaryngology clinic and pathological department as part of previous and ongoing projects, as well as research on laryngeal carcinogenesis, which gave us novel interesting data<sup>2,18-20</sup>

on molecular markers and incitement for further research and studies that are currently undertaken.

The immunohistochemical analysis of p53, cyclin D1, and Ki-67 and EGFR supported the diagnosis of initial squamous cell carcinoma in the atypical epithelium of the anterior third of the left vocal cord displaying stronger staining patterns. This was especially well followed for EGFR staining, proving once more EGFR to be one of the most reliable markers of laryngeal carcinogenesis. We are also reporting staining patterns about IMP3 in laryngeal polypoid tissue in which we recorded IMP3-positive cells within the squamous cell carcinoma nest, while we did not observe IMP3 expression in the benign epithelium adjacent to the carcinoma. These findings indicate the possible use of this marker in the assessment of laryngeal tissue atypia and further research is commendable. In the posterior part of the vocal cord, although atypical changes were present, no criteria for carcinoma were met. This confirms that atypia can be multi-focal in vocal folds, and these multi-focal changes require additional caution in evaluation and are the most demanding for the clinician, as well as the pathologist, in the decision-making and the follow-up processes.

This case shows that polyps cannot be lightly treated as benign lesions and that conservative treatment is not advised for fibromatous polyps; only biopsy and histopathological analysis sometimes supported by IHC analysis can exclude a malignant transformation. It also highlights that IHC analysis should nowadays gradually be introduced in order to improve routine histopathological evaluation, at least for multi-focal atypia and problematic cases, not only in precancerous but also in suspicious polypoid changes of vocal cords.

Nowadays, there is still disagreement in classification among specialists, but also a divergence in the treatment of polypoid lesions, with a broad spectrum ranging from:

- a) strictly conservative treatment based upon observation and/or voice therapy and/or anti-reflux medication<sup>3,21-26</sup> which, in our opinion, is risky, needs careful selection, and can be reserved only for small edematous polyps

with short-lasting medical history; we want to point out that check-ups are in such cases mandatory

- b) steroid injections promoted by some authors<sup>27,28</sup>, while others are more cautious concluding that it may delay, but not substitute surgery<sup>29</sup>, and we agree with the latter
- c) subepithelial resection, conserving the epithelial tissue<sup>30</sup>, which in our opinion has the pitfall of lacking histopathological confirmation that excludes an epithelial malignant transformation
- d) endoscopic laser treatment of vocal cords, especially in angiomatous polyps<sup>30-32</sup>, due to its photocoagulative properties on vascular structures, with the same pitfall mentioned above
- e) surgery using flexible laryngostroboscopy<sup>33,34</sup> as well as the standard, traditional laryngeal microsurgery<sup>35</sup>.

Unlike some authors<sup>36</sup> who reserve surgery for larger polyps, others<sup>37</sup> are cautious in prescribing conservative treatment for angiomatous polyps and consider surgery as the gold standard that we agree with. In our opinion, conservative treatment and observation, especially in elderly male patients with a medical history positive for chronic laryngeal irritation and burdened with risk factors (e.g. smoking, abuse of alcohol, gastro-oesophageal reflux disease, vocal abuse, etc.), is unadvised and we advocate surgical treatment and histopathological exclusion of a malignant transformation. Conservative treatment should be reserved only for small, edematous, short-lasting polyps that must be closely followed and re-evaluated. Undoubtedly, successful treatment of polyps, after surgery by a skilled surgeon, is assured also by avoidance of noxae, additional conservative treatment depending on aetiology (e.g. anti-reflux therapy<sup>23</sup>), and, if needed, an adequate speech therapy<sup>38</sup>.

We consider surgery to be the safest and most reliable treatment option for fibrovascular polypoid formations. Further studies are needed to establish criteria for the most effective treatment of polypoid lesions, and we believe that the IHC analysis will help in differential diagnoses of problematic cases.

This case is an example that sometimes a vocal fold formation clinically presented as benign polyp can be deceiving, and only further histopathological and immunohistochemical “plunge” under the surface and detailed analysis of the epithelium reveals the true nature of the lesion we are dealing with.

## CONCLUSIONS

We still lack criteria for follow-up and treatment in a wide range of laryngeal polypoid changes.

Unlike some authors that promote conservative treatment, we strongly advise at least probatory biopsy, especially in elderly male patients with medical history positive for chronic laryngeal irritation (smoking, drinking, gastro-oesophageal reflux, vocal abuse, etc.).

Although laryngeal polyps are mostly considered as benign lesions, we present a case of a laryngeal polypoid formation with multi-focal atypia in its overlying epithelium in which we discovered a nest of micro-invasive squamous cell carcinoma confirmed by histopathological and supported by immunohistochemical analysis.

While IHC analysis of SCC molecular markers is applied in laryngeal precancerous lesions, no such markers are routinely analysed in laryngeal polyps, in which only stromal markers have been widely examined.

We think that in difficult cases with multi-focal atypia, immunohistochemistry could improve histopathological analysis and should slowly be introduced into diagnostic protocols of polypoid tissue, especially when high-grade atypia is discovered. We also found interesting staining patterns of IMP3, indicating the possible use of this marker in the assessment of laryngeal tissue atypia and the need for its further investigation.

**Conflicts of interest:** Authors declare no conflicts of interest.

## REFERENCES

1. Levendoski EE, Leydon C, Thibeault SL. Vocal fold epithelial barrier in health and injury: a research review. *J Speech Lang Hear Res* 2014;57:1679–1691.
2. Braut T, Krstulja M, Marijic B, Marzic D, Kujundzic M, Brumini G, et al. Immunohistochemical analysis of vocal cord polyps applying markers of squamous cell carcinogenesis. *Pathol Res Pract* 2019;215:144–150.

3. Vasconcelos D, Gomes AOC, Araujo CMT. Vocal Fold Polyps: Literature Review. *Int Arch Otorhinolaryngol* 2019; 23:116–124.
4. Wang L, Tan JJ, Wu T, Zhang R, Wu JN, Zeng FF, et al. Association between Laryngeal Pepsin Levels and the Presence of Vocal Fold Polyps. *Otolaryngol Head Neck Surg* 2017;156:144–151.
5. Effat KG, Milad M. A comparative histopathological study of vocal fold polyps in smokers versus non-smokers. *J Laryngol Otol* 2015;129:484–488.
6. Martins RH, Defaveri J, Domingues MA, de Albuquerque e Silva R. Vocal polyps: clinical, morphological, and immunohistochemical aspects. *J Voice* 2011;25:98–106.
7. Nunes RB, Behlau M, Nunes MB, Paulino JG. Clinical diagnosis and histological analysis of vocal nodules and polyps. *Braz J Otorhinolaryngol* 2013;79:434–440.
8. Cielo C, Finger L, Rosa J, Brancalioni A. Organic and functional lesions: nodules, polyps and reinke's edema. *Rev CEFAC* 2011;13:735–748.
9. Marcotullio D, Magliulo G, Pietruni S, Suriano M. Exudative laryngeal diseases of Reinke's space: a clinicohistopathological framing. *J Otolaryngol* 2002;31:376–380.
10. Wallis L, Jackson-Menaldi C, Holland W, Giraldo A. Vocal fold nodule vs. vocal fold polyp: answer from surgical pathologist and voice pathologist point of view. *J Voice* 2004;18:125–129.
11. Cipriani NA, Martin DE, Corey JP, Portugal L, Caballero N, Lester R, et al. The clinicopathologic spectrum of benign mass lesions of the vocal fold due to vocal abuse. *Int J Surg Pathol* 2011;19:583–587.
12. Johns MM. Update on the etiology, diagnosis, and treatment of vocal fold nodules, polyps, and cysts. *Curr Opin Otolaryngol Head Neck Surg* 2003;11:456–461.
13. Martins RH, Defaveri J, Custodio Domingues MA, de Albuquerque ESR, Fabro A. Vocal fold nodules: morphological and immunohistochemical investigations. *J Voice* 2010;24:531–539.
14. El-Naggar AK, Chan JKC, Grandis JR, Takata T, Slootweg PJ. WHO Classification of Head and Neck Tumours. World Health Organization; 2017.
15. Edge SB, American Joint Committee on Cancer. AJCC cancer staging manual. Part II: Head and Neck. New York: Springer; 2010. pp. xiv, 648 p.
16. Li S, Cha J, Kim J, Kim KY, Kim HJ, Nam W, et al. Insulin-like growth factor II mRNA-binding protein 3: a novel prognostic biomarker for oral squamous cell carcinoma. *Head Neck* 2011;33:368–374.
17. Lu D, Vohra P, Chu PG, Woda B, Rock KL, Jiang Z. An oncofetal protein IMP3: a new molecular marker for the detection of esophageal adenocarcinoma and high-grade dysplasia. *Am J Surg Pathol* 2009; 33:521–525.
18. Braut T, Krstulja M, Kujundzic M, Manestar D, Hadzisejdic I, Jonjic N, et al. Epidermal growth factor receptor protein expression and gene amplification in normal, hyperplastic, and cancerous glottic tissue: immunohistochemical and fluorescent in situ hybridization study on tissue microarrays. *Croat Med J* 2009;50:370–379.
19. Braut T, Krstulja M, Rukavina KM, Jonjic N, Kujundzic M, Manestar ID, et al. Cytoplasmic EGFR staining and gene amplification in glottic cancer: a better indicator of EGFR-driven signaling? *Appl Immunohistochem Mol Morphol* 2014;22:674–680.
20. Braut T, Kujundzic M, Vukelic J, Manestar D, Krstulja M, Starcevic R, et al. Gene Amplification of Epidermal Growth Factor Receptor in Atypical Glottic Hyperplasia. *Coll Antropol* 2012;36:87–91.
21. Klein AM, Lehmann M, Hapner ER, Johns MM, 3rd. Spontaneous resolution of hemorrhagic polyps of the true vocal fold. *J Voice* 2009;23:132–135.
22. Cohen SM, Garrett CG. Utility of voice therapy in the management of vocal fold polyps and cysts. *Otolaryngol Head Neck Surg* 2007;136:742–746.
23. Jeong WJ, Lee SJ, Lee WY, Chang H, Ahn SH. Conservative management for vocal fold polyps. *JAMA Otolaryngol Head Neck Surg* 2014;140:448–452.
24. Srirompotong S, Saeseow P, Vatanasapt P. Small vocal cord polyps: completely resolved with conservative treatment. *Southeast Asian J Trop Med Public Health* 2004;35:169–171.
25. Gokcan KM, Dursun G. Vascular lesions of the vocal fold. *Eur Arch Otorhinolaryngol* 2009;266:527–533.
26. Lin L, Sun N, Yang Q, Zhang Y, Shen J, Shi L, et al. Effect of voice training in the voice rehabilitation of patients with vocal cord polyps after surgery. *Exp Ther Med* 2014; 7:877–880.
27. Hsu YB, Lan MC, Chang SY. Percutaneous corticosteroid injection for vocal fold polyp. *Arch Otolaryngol Head Neck Surg* 2009;135:776–780.
28. Wang CT, Liao LJ, Cheng PW, Lo WC, Lai MS. Intralesional steroid injection for benign vocal fold disorders: a systematic review and meta-analysis. *Laryngoscope* 2013; 123:197–203.
29. Wang CT, Lai MS, Hsiao TY. Comprehensive Outcome Researches of Intralesional Steroid Injection on Benign Vocal Fold Lesions. *J Voice* 2015;29:578–587.
30. Mizuta M, Hiwatashi N, Kobayashi T, Kaneko M, Tateya I, Hirano S. Comparison of vocal outcomes after angiolytic laser surgery and microflap surgery for vocal polyps. *Auris Nasus Larynx* 2015;42:453–457.
31. Ivey CM, Woo P, Altman KW, Shapshay SM. Office pulsed dye laser treatment for benign laryngeal vascular polyps: a preliminary study. *Ann Otol Rhinol Laryngol* 2008;117:353–358.
32. Mallur PS, Tajudeen BA, Aaronson N, Branski RC, Amin MR. Quantification of benign lesion regression as a function of 532-nm pulsed potassium titanyl phosphate laser parameter selection. *Laryngoscope* 2011;121:590–595.
33. Lan MC, Hsu YB, Chang SY, Huang JL, Tai SK, Chien CH, et al. Office-based treatment of vocal fold polyp with flexible laryngosvideostroboscopic surgery. *J Otolaryngol Head Neck Surg* 2010;39:90–95.
34. Vegas A, Cobeta I, Mico A, Rivera T. Pedunculated polyp removal by means of larynx fiberendoscopic surgery. *Eur Arch Otorhinolaryngol* 2010;267:1255–1260.
35. Sulica L. Microlaryngoscopy and endolaryngeal microsurgery. In: Fried M, Ferlito A, editors. *The Larynx*. San Diego, CA, US: Plural Publishing Inc; 2009. pp. 227–244.
36. Garrett CG, Francis DO. Is surgery necessary for all vocal fold polyps? *Laryngoscope* 2014;124:363–364.
37. Adrian J, Rodríguez-Parra M. Evaluation of voice therapy for dysphonia in adults: Follow-up of group effects and individual variability. *Rev Logop Fon Audiol* 2015;35:17–29.
38. Cecatto S, Costa K, Garcia R, Haddad L, Angelico Junior F, PB R. Vocal cord polyps: clinical and surgical aspects. *Rev Bras Otorrinolaringol* 2002;68:534–538.