

# Primary bronchomalacia successfully treated with bronchopexy

---

**Banac, Srđan; Ivančić, Aldo; Šegulja, Silvije; Šaina, Giordano; Čače, Neven**

*Source / Izvornik:* **Paediatrica Croatica, 2012, 56, 253 - 255**

**Journal article, Published version**

**Rad u časopisu, Objavljena verzija rada (izdavačev PDF)**

*Permanent link / Trajna poveznica:* <https://um.nsk.hr/um:nbn:hr:184:404566>

*Rights / Prava:* [Attribution-NonCommercial-NoDerivatives 4.0 International/Imenovanje-Nekomercijalno-Bez prerada 4.0 međunarodna](#)

*Download date / Datum preuzimanja:* **2024-09-18**



*Repository / Repozitorij:*

[Repository of the University of Rijeka, Faculty of Medicine - FMRI Repository](#)



## PRIMARY BRONCHOMALACIA SUCCESSFULLY TREATED WITH BRONCHOPEXY

SRĐAN BANAC<sup>1</sup>, ALDO IVANČIĆ<sup>2</sup>, SILVIJE ŠEGULJA<sup>3</sup>, GIORDANO ŠAINA<sup>4</sup>, NEVEN ČAČE<sup>1</sup>, VOJKO ROŽMANIĆ<sup>5</sup>

*A case of a two-year-old girl with primary bronchomalacia of the left mainstem bronchus is described. The girl did not present with a history of persistent or recurrent respiratory symptoms. Instead, thorough physical examination performed due to an acute upper airway infection and coincidental discovery of unilateral lung hyperinflation on chest radiography had started a sequence of diagnostic procedures. Definitive diagnosis was made by bronchoscopy. There was complete loss of bronchial lumen during expiration. The girl underwent bronchopexy, which entails surgical suspension of the affected bronchial wall to ligamentum arteriosum. Bronchopexy proved to be effective therapeutic approach in the reported case. The suspending effect of bronchopexy is expected to last long enough to allow the affected bronchus to grow and reach the size at which malacic segment will no longer produce problems.*

Descriptors: BRONCHOMALACIA; CHILD, PRESCHOOL; BRONCHI; RADIOGRAPHY, THORACIC; BRONCHOSCOPY

### INTRODUCTION

Although primary malacias of central airways are not common conditions, they seem to be more prevalent than generally thought. Combined birth prevalence of tracheomalacia and bronchomalacia is estimated to be at least one in 2100 with a male predominance (1). Bronchomalacia usually accompanies tracheomalacia, but it may occur as an isolated condition. It is presented in early infancy with noisy breathing, persistent wheezing, dyspnea, hyperinflation and recurrent pulmonary infections (2). Definitive diagnosis is made by bronchoscopic examination (3).

Therapeutic approaches include chest physiotherapy and application of continuous positive airway pressure. A range of surgical procedures, including bronchopexy, are performed in more severe cases (4).

This is a report of a girl who was detected to have primary bronchomalacia of the left mainstem bronchus. She was successfully treated with bronchopexy.

### CASE REPORT

It was a common situation in a pediatrician office. A two-year-old girl had a six-day history of high fever, runny nose and cough. Besides obvious signs of an upper airway infection, on physical examination auscultation revealed diminished breath sounds over her left lung. Blood tests showed acute phase reactants to be high (C-reactive protein, CRP 163 mg/L). Chest radiography was ordered for the first time in her life. Surprisingly, it did not confirm the expected presence of left-sided pneumonia. Significant hyperinflation of the whole left lung was noticed instead (Figure 1A). The girl was otherwise healthy. She did not suffer from recurrent pneumonias or chronic respira-

tory symptoms including dyspnea, wheezing and cough. Her growth and development were normal.

The girl was admitted to the hospital and she was treated for more than a week. In spite of successfully coped respiratory infection, repeated chest radiographies, including comparative inspiratory and expiratory views, showed that emphysema of the left lung persisted. Therefore, bronchoscopy was performed and severe malacia of the left main bronchus was noticed. There was complete loss of airway lumen during expiration (Figure 2A). Malacic segment seemed to be quite long. It was followed with increased mucus and inflammation of the left-sided bronchial tree. There were neither signs of tracheomalacia nor of foreign body. Bronchial branching was normal.

Computed chest tomography examination showed that it was going for the primary bronchomalacia as there were identified no structures to press against the bronchial wall. The presence of some flat atelectasias of the left lower lobe was documented.

At that point, it was decided that surgical approach would be an optimal therapeutic option. The girl underwent bron-

<sup>1</sup> Department of Pediatrics, Clinical Hospital Center Rijeka, Istarska 43, Rijeka, Croatia

<sup>2</sup> Department of Surgery, Clinical Hospital Center Rijeka, Tome Strižića 3, Rijeka, Croatia

<sup>3</sup> Department of Pediatrics, Thalassotherapia Crikvenica, Gajevo šetalište 21, Crikvenica, Croatia

<sup>4</sup> Department of Pediatric Radiology, Clinical Hospital Center Rijeka, Istarska 43, Rijeka, Croatia

<sup>5</sup> Department of Pediatrics, School of medicine, University of Rijeka, Braće Brachetta 22, Rijeka, Croatia

#### Correspondence to:

Srđan Banac, MD, PhD., Department of Pediatrics, Clinical Hospital Center Rijeka, Istarska 43, 51000 Rijeka, Croatia, e-mail: srdjan.banac@medri.hr

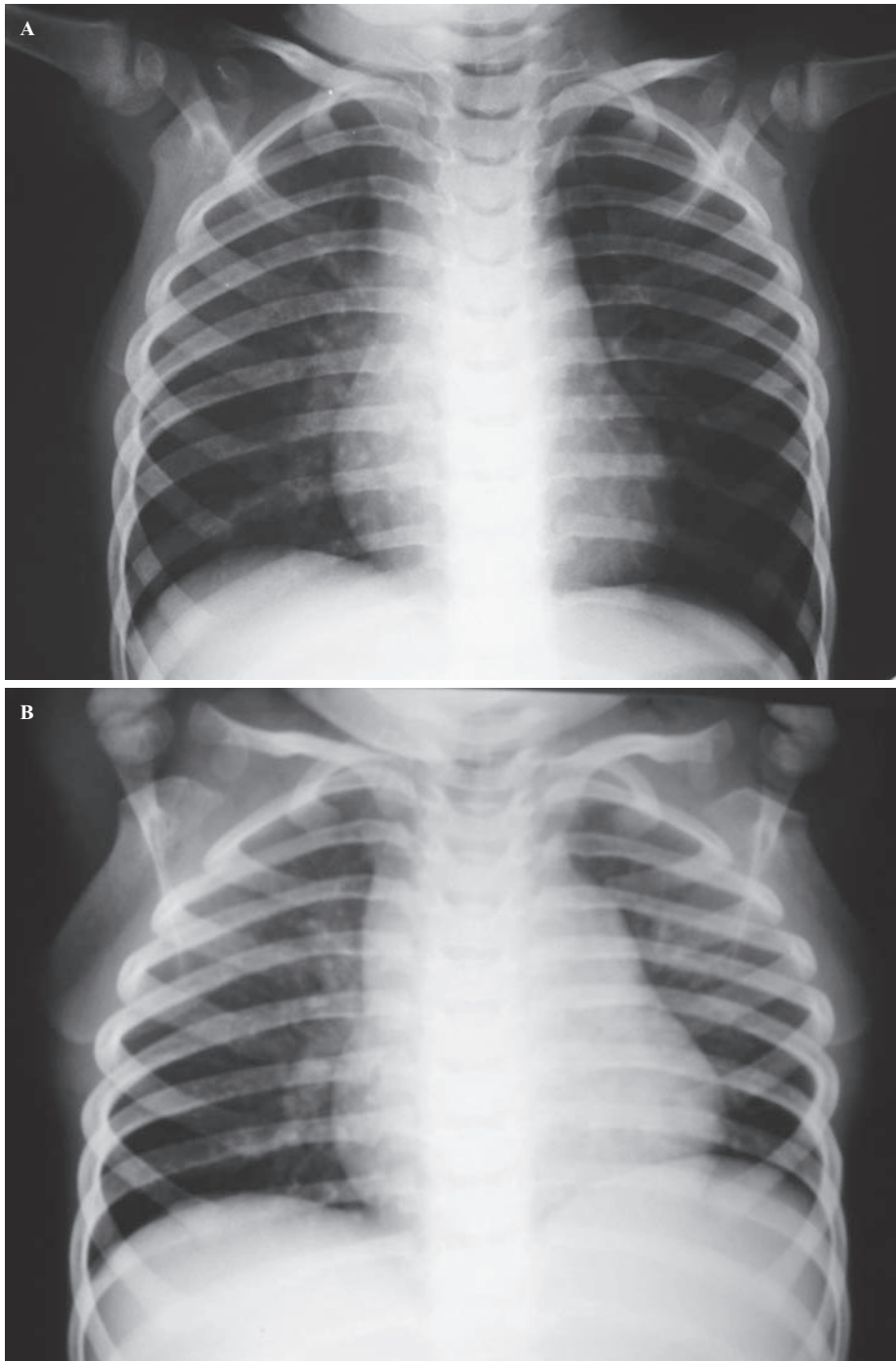


Figure 1. Chest radiographies in the two-year-old girl: (A) hyperinflation of the whole left lung at admission to the hospital; and (B) there were no signs of hyperinflation six months following bronchopexy. Hypoplasia of the left lung with elevation of the ipsilateral hemidiaphragm was noticed.

chopexy. The affected and collapsed bronchial wall was suspended superiorly to the ligamentum arteriosum using sutures. There were no complications in the early postoperative period. The intervention provided a very good suspending effect, which was confirmed several days following the surgery by an improved bronchoscopic appearance of the left main bronchus (Figure 2B). A mild hypoplastic

aspect of the left-sided bronchial tree was also noticed (Figure 2C). Radiographic follow-up showed no more signs of lung hyperinflation (Figure 1B).

#### DISCUSSION

In this case report there are a few particularities of primary isolated bronchomalacia, considering the type of malacia,

its clinical presentation and therapeutic approach.

Primary tracheo- and bronchomalacia refer to congenital intrinsic softness and collapsibility of the airway wall. Bronchomalacia is less frequent than tracheomalacia. It is usually seen to be combined with tracheomalacia and the term tracheo-bronchomalacia is employed (5). Isolated bronchomalacia is a rare condition, especially its primary form like the one reported in this case. Secondary bronchomalacia is more common. It usually occurs in children as a result of extrinsic compression from an enlarged vessel, a vascular ring or bronchogenic cyst (6).

Primary bronchomalacia is more likely to be clinically present in the first six months of the child's life (7). Symptoms may vary from recurrent or persistent "asthma-like" symptoms and lower airway infections to exercise intolerance, severe dyspnea and respiratory insufficiency (8). However, in a small proportion of patients, congenital lung abnormalities may go unrecognized through infancy and early childhood (2). Thorough physical examination and coincidental discovery of unilateral lung hyperinflation on chest radiography rather than disease history had started a sequence of further diagnostic procedures and led to the diagnosis in the reported case.

Unilateral lung hyperinflation on chest radiography should include Swyer-James-McLeod syndrome as a differential diagnosis. It occurs as a result of obliterative bronchiolitis, where the affected lung is hyperlucent but smaller compared with the normal lung (9). In contrast, the affected lung in the reported case was hyperlucent and larger than the unaffected lung due to a ball-valve mechanism in the malacic left mainstem bronchus. However, chest radiographies that followed bronchopexy suggested that the left lung assumed normal density, but it was actually smaller than the right lung. Probably, the primary congenital malacia of the left mainstem bronchus had interfered with normal lung development and had led to pulmonary hypoplasia.

Many children with simple bronchomalacia without external compression or associated anomalies can be managed conservatively because their symptoms resolve and airway function gradually improves with increasing age (10). Continuous positive airway pressure and chest physiotherapy together with prevention

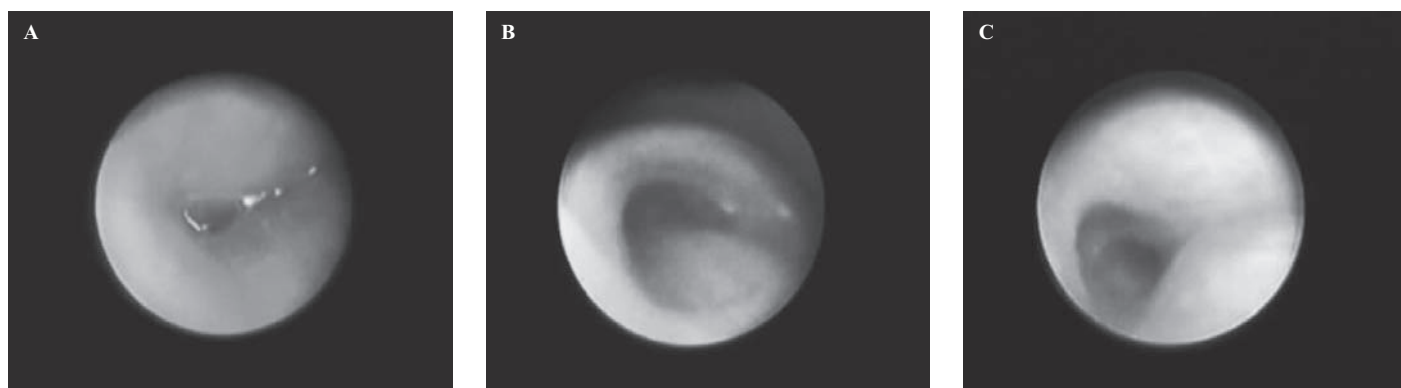


Figure 2. Bronchoscopic views of the left mainstem bronchus: (A) malacic and collapsed orifice before bronchopexy; (B) suspending effect of bronchopexy and hypoplastic appearance of the bronchus, and (C) of secondary carina.

and treatment of lower airway infections are preferred therapeutic options in such cases. In severe cases, including patients with unilateral lung hyperinflation, more active treatment might be considered. There are still no clear guidelines as to which surgical procedure to be performed in severe cases of bronchomalacia. In comparison to classical surgical resection of the affected bronchial segment, bronchopexy seems to be a rational, not too aggressive, surgical treatment in cases of severe primary and even secondary bronchomalacia (4). By analogy to aortopexy, which is much more frequently described and performed in cases of severe tracheomalacia, bronchopexy entails surgical suspension of the affected bronchus *via* sutures to the nearby tissue (11). In case of the left mainstem bronchus, its wall is usually suspended superiorly to the ligamentum arteriosum (12). The right side of the thorax does not offer the surgeon such a good anatomic point of support to attain an effective suspension of the airway wall. Fortunately, bronchomalacia is more common on the left than on the right side (1).

Bronchoscopic insertion of an endobronchial stent is also a possible therapeutic option in severe cases of localized bronchomalacia. There are currently two main types of stents available, silicone tubes and self-expanding metal stents that may be placed to ensure airway lumen in children. Although bronchial stenting seems to be a less invasive method than bronchopexy, actually it is rarely used because stents have to be replaced periodi-

cally in children according to their growth, and because of the high risk of substantial complications (13). Metal stents are associated with development of granulation tissue, and they can become embedded in the airway mucosa. Their removal is hazardous with the possibility of lethal outcome. On the other hand, silicone tubes cause mucus retention and plugging, and they are more prone to migration. Thus, stenting is a second-line therapy for bronchomalacia in children and should be restricted to highly selected cases where all other therapeutic options have failed (14).

In conclusion, bronchopexy proved to be a rational and effective therapeutic approach in the reported case of primary isolated malacia of the left mainstem bronchus. We believe that the suspending effect will last long enough to allow the affected bronchus to grow and reach the size at which malacic segment will no longer produce problems. Finally, this report reminds us that patients should always be thoroughly physically examined, and that conventional chest radiography still remains the gold standard for initial diagnostic imaging of pediatric chest.

Autori izjavljaju da nisu bili u sukobu interesa.  
Authors declare no conflict of interest.

#### REFERENCES

- Boogaard R, Huijsmans SH, Pijnenburg MWH, Tiddens HAWM, de Jongste JC, Merkus PJFM. Tracheomalacia and bronchomalacia in children: incidence and patient characteristics. *Chest*. 2005;128:3391-7.
- Laberge JM, Puligandla P. Congenital malformations of the lungs and airways. In: Taussig LM, Lan-

- dau LI, eds. *Pediatric respiratory medicine*. 2<sup>nd</sup> ed. Philadelphia: Mosby; 2008:907-41.
- Pohunek P, Boogaard R, Merkus P. Congenital and acquired abnormalities of the lower airways. In: Priftis KN, Anthracopoulos MB, Eber E, Koumbourlis AC, Wood RE, eds. *Paediatric Bronchoscopy*. 2<sup>nd</sup> ed. Basel: Karger; 2010:130-40.
- Ahel V, Banac S, Rožmanić V, Vukas D, Dreščik I, Ahel V. Aortopexy and bronchopexy for the management of severe tracheomalacia and bronchomalacia. *Pediatr Int*. 2003;45:104-6.
- Carden KA, Boiselle PM, Waltz DA, Ernst A. Tracheomalacia and tracheobronchomalacia in children and adults: an in-depth review. *Chest*. 2005;127:984-1005.
- Ahel V, Palčevski G, Dreščik I, Vukas D, Zubović I, Rožmanić V. Unilateral pulmonary emphysema with secondary bronchomalacia caused by bronchogenic cyst in an infant. *Pediatr Pulmonol*. 1994;18:58-60.
- Finder JD. Primary bronchomalacia in infants and children. *J Pediatr*. 1997;130:59-66.
- Abel RM, Bush A, Chitty LS, Harcourt J, Nicholson AG. Congenital lung disease. In: Chernick V, Boat TF, Wilmott RW, Bush A, eds. *Kendig's disorders of the respiratory tract in children*. 7<sup>th</sup> ed. Philadelphia: Saunders; 2006:280-316.
- Bhandari A. Congenital malformations of the lung and the airway. In: Panitch HB, ed. *Pediatric Pulmonology*. 1<sup>st</sup> ed. Philadelphia: Mosby; 2005:35-59.
- Eber E. Congenital lung abnormalities. *Eur Respir Mon*. 2010;47:263-7.
- Kosloske AM. Left mainstem bronchopexy for severe bronchomalacia. *J Pediatr Surg*. 1991;26:260-2.
- Ahel V, Severinski S, Vukas D, Rožmanić V. Primary bronchomalacia and patent ductus arteriosus. *Tex Heart Inst J*. 1999;26:215-8.
- Wood RE, Daines C. Bronchoscopy and bronchoalveolar lavage in pediatric patients. In: Chernick V, Boat TF, Wilmott RW, Bush A, eds. *Kendig's disorders of the respiratory tract in children*. 7<sup>th</sup> ed. Philadelphia: Saunders; 2006:94-109.
- Donato L, Tran TMH, Mihailidou E. Interventional bronchoscopy. In: Priftis KN, Anthracopoulos MB, Eber E, Koumbourlis AC, Wood RE, eds. *Paediatric Bronchoscopy*. 1<sup>st</sup> ed. Basel: Karger; 2010:64-74.

## S a ž e t a k

### PRIMARNA BRONHOMALACIJA USPJEŠNO LIJEČENA BRONHOPEKSIJOM

*S. Banac, A. Ivančić, S. Šegulja, G. Šaina, N. Čače, V. Rožmanić*

*Opisan je slučaj dvogodišnje djevojčice s primarnom bronhomalacijom lijevog glavnog bronha, koja se nije prezentirala anamnestičkim podacima o tvrdokornim i ponavljajućim respiratornim simptomima. Fizikalni pregled i daljnji dijagnostički postupak obavljen zbog akutne infekcije gornjih dišnih putova, rezultirao je neočekivanim nalazom jednostrane hiperinflacije lijevog pluća na radiogramu prsnih organa. Konačna dijagnoza postavljena je bronhoskopijom koja je pokazala potpuni gubitak lumena lijevog glavnog bronha. Djevojčica je podvrgnuta bronhopeksiji kod koje se stijenka zahvaćenog bronha nategne i kirurški prišije za ligamentum arteriosum. Bronhopeksija se pokazala učinkovitim terapijskim pristupom u opisanom slučaju. Očekuje se da će natežući učinak bronhopeksije trajati dovoljno dugo i omogućiti pogodnom bronhu da svojim rastom dosegne veličinu kod koje razmekšani segment više neće uzrokovati probleme.*

Deskriptori: BRONHOMALACIJA; DIJETE, PREDŠKOLSKO; BRONHI; RADIOGRAFIJA, TORAKS; BRONHOSKOPIJA

*Primljeno/Received: 9. 11. 2011.*

*Prihvaćeno/Accepted: 16. 12. 2011.*