

# Study of the healing process after transplantation of pasteurized bone grafts in rabbits

---

**Zoričić, Sanja; Bobinac, Dragica; Lah, Boris; Marić, Ivana; Cvijanović, Olga; Bajek, Snježana; Golubović, Vesna; Mihelić, Radovan**

*Source / Izvornik:* **Acta medica Okayama, 2002, 56**

**Journal article, Published version**

**Rad u časopisu, Objavljena verzija rada (izdavačev PDF)**

*Permanent link / Trajna poveznica:* <https://um.nsk.hr/um:nbn:hr:184:643913>

*Rights / Prava:* [Attribution-NonCommercial-NoDerivatives 4.0 International/Imenovanje-Nekomercijalno-Bez prerada 4.0 međunarodna](#)

*Download date / Datum preuzimanja:* **2025-01-23**



*Repository / Repozitorij:*

[Repository of the University of Rijeka, Faculty of Medicine - FMRI Repository](#)



# *Acta Medica Okayama*

---

*Volume 56, Issue 3*

2002

*Article 1*

JUNE 2002

---

## Study of the healing process after transplantation of pasteurized bone grafts in rabbits.

Sanja Zoricic\*

Dragica Bobinac<sup>†</sup>

Boris Lah<sup>‡</sup>

Ivana Maric\*\*

Olga Cvijanovic<sup>††</sup>

Snjezana Bajak<sup>‡‡</sup>

Vesna Golubovic<sup>§</sup>

Radovan Mihelic<sup>¶</sup>

\*University of Rijeka,

<sup>†</sup>University of Rijeka,

<sup>‡</sup>University of Rijeka,

\*\*University of Rijeka,

<sup>††</sup>University of Rijeka,

<sup>‡‡</sup>University of Rijeka,

<sup>§</sup>University of Rijeka,

<sup>¶</sup>University of Rijeka,

# Study of the healing process after transplantation of pasteurized bone grafts in rabbits.\*

Sanja Zoricic, Dragica Bobinac, Boris Lah, Ivana Maric, Olga Cvijanovic, Snjezana Bajak, Vesna Golubovic, and Radovan Mihelic

## Abstract

Different bone allografts (pasteurized, autoclaved, and frozen) were compared based on their osteoinductive properties. Our primary purpose was to examine the biologic qualities of pasteurized allografts, as pasteurization inactivates most viruses transmitted by transplantation. Frozen, pasteurized, and autoclaved allografts were packed into a standard defect of rabbit ulna. The animals were sacrificed at 2 and 4 weeks after surgery. The parts of bones with experimental defects were explored en bloc, and a roentgenogram was carried out. Ulna bone samples were then embedded in methyl-methacrylate. Roentgenograms showed that after 2 weeks, calluses were well-formed, but irregular in shape in all 3 types of allografts. After 4 weeks, the calluses were regular in shape in all but the autoclaved grafts. After 2 weeks, the healing processes had begun in the frozen and pasteurized grafts, with the reaching approximately the same stage, while in the autoclaved grafts these processes were not seen and the bone particles were surrounded by connective tissue without any changes. After 4 weeks, osteoinductive processes were very strong, with the first signs of complete bone remodeling at the bone edges of the defect in pasteurized and frozen allografts. The osteoinductive values of these 2 types were very high and similar. Autoclaved allografts, on the other hand, had very low osteoinductive values, as they were still at the very beginning of the healing process. Histomorphometric analysis revealed a significant difference in both newly formed osteoid thickness and osteoblast number per microm of bone surface in all experimental groups ( $P < 0.005$ ). Values of osteoid thickness and osteoblast number were significantly higher in both frozen and pasteurized grafts when compared with the autoclaved ones ( $P < 0.005$ ). Osteogenic properties of pasteurized bone allografts were preserved, and the allografts have been gradually replaced with newly formed bone. As such, pasteurized bone grafts from a bone bank have approximately the same biologic validity as frozen grafts, while autoclaved grafts impair bone healing.

**KEYWORDS:** bone allograft, pasteurization, healing, rabbits

---

\*PMID: 12108582 [PubMed - indexed for MEDLINE]

Copyright (C) OKAYAMA UNIVERSITY MEDICAL SCHOOL

Original Article

## Study of the Healing Process after Transplantation of Pasteurized Bone Grafts in Rabbits

Sanja Zoricic<sup>a</sup>, Dragica Bobinac<sup>a\*</sup>, Boris Lah<sup>b</sup>, Ivana Maric<sup>a</sup>,  
Olga Cvijanovic<sup>a</sup>, Snjezana Bajek<sup>a</sup>, Vesna Golubovic<sup>c</sup>, and Radovan Mihelic<sup>b</sup>

<sup>a</sup>Department of Anatomy, School of Medicine, <sup>b</sup>Clinical Orthopedic Hospital, and  
<sup>c</sup>Department of Anesthesiology, School of Medicine, University of Rijeka,  
B. Branchetta 20, 51000 Rijeka, Croatia

Different bone allografts (pasteurized, autoclaved, and frozen) were compared based on their osteoinductive properties. Our primary purpose was to examine the biologic qualities of pasteurized allografts, as pasteurization inactivates most viruses transmitted by transplantation. Frozen, pasteurized, and autoclaved allografts were packed into a standard defect of rabbit ulna. The animals were sacrificed at 2 and 4 weeks after surgery. The parts of bones with experimental defects were explored *en bloc*, and a roentgenogram was carried out. Ulna bone samples were then embedded in methyl-methacrylate. Roentgenograms showed that after 2 weeks, calluses were well-formed, but irregular in shape in all 3 types of allografts. After 4 weeks, the calluses were regular in shape in all but the autoclaved grafts. After 2 weeks, the healing processes had begun in the frozen and pasteurized grafts, with the reaching approximately the same stage, while in the autoclaved grafts these processes were not seen and the bone particles were surrounded by connective tissue without any changes. After 4 weeks, osteoinductive processes were very strong, with the first signs of complete bone remodeling at the bone edges of the defect in pasteurized and frozen allografts. The osteoinductive values of these 2 types were very high and similar. Autoclaved allografts, on the other hand, had very low osteoinductive values, as they were still at the very beginning of the healing process. Histomorphometric analysis revealed a significant difference in both newly formed osteoid thickness and osteoblast number per  $\mu\text{m}$  of bone surface in all experimental groups ( $P < 0.005$ ). Values of osteoid thickness and osteoblast number were significantly higher in both frozen and pasteurized grafts when compared with the autoclaved ones ( $P < 0.005$ ). Osteogenic properties of pasteurized bone allografts were preserved, and the allografts have been gradually replaced with newly formed bone. As such, pasteurized bone grafts from a bone bank have approximately the same biologic validity as frozen grafts, while autoclaved grafts impair bone healing.

**Key words:** bone allograft, pasteurization, healing, rabbits

Received July 3, 2001; accepted December 17, 2001.

\*Corresponding author. Phone: +385-51-651-143; Fax: +385-51-651-143  
E-mail: Dragica.Bobinac@medri.hr (D. Bobinac)

**B**one transplantation surgery has become integral to orthopedic and traumatology. Although autologous bone grafts are the most favorable for bone transplantation purpose ("golden standard") [1, 2, 3], their resource capacity is limited. Consequently, trans-

plantation of deep-frozen allogeneous bone has become prevalent in clinical practice [1]. This procedure has several complication risks, including transplant rejection-host versus graft reaction, instability, and infection.

After the appearance of HIV and other retroviral infections, transmission risks have become one of the most important problems in deep-frozen allogeneous bone transplantation surgery [4, 5]. Since the time when the first case of HIV transmission by an allogeneous bone was reported, the number of bone allograft transplantations has decreased [6].

In the meantime, certain medical associations [7] have introduced new medical guidelines in order to reduce the risk of HIV transmission [8]. In addition, numerous experiments have been carried out with the intent of developing an adequate procedure for virus inactivation without compromising graft biological values [9]. Nevertheless, there are still serious problems in bone banking [1, 10].

Previous studies have shown that HIV and other retroviruses are not sensitive to low temperatures and therefore cannot be inactivated by freezing [5, 11]. Numerous studies have described the effects and efficacy of various methods and procedures directed at HIV disinfection such as the use of chemical agents, gamma and delta irradiation, and thermal energy [12, 13]. Although these methods have been successful in virus inactivation, they have been inapplicable to allogeneous bone graft transplantations, as they severely alter the physical properties and osteogenic potential of the bone allograft [14].

Moreover, all growth factors (TGF $\beta$ , BMPs, IGFs *etc.*) of the bone matrix responsible for osteogenic properties are inactivated at 80 °C [15]. As such, autoclaved bone allografts have been considered to be inappropriate for bone transplant surgery due to the associated loss of physical and biological properties [16]. Manifestly, allograft disinfection from viruses should be performed by heating at lower temperatures, as it is done with blood derivatives (50–60 °C) [17].

It has recently been shown that heating at 50–68 °C inactivates HIV. Spire *et al.* [11] have shown that after 30 min of incubation in a waterbath, viral sample inactivation is 0%, 40%, 63%, and 100% at 37 °C, 42 °C, 48 °C, and 56 °C, respectively. They have also observed that HIV reverse transcriptase activity reaches zero after 20 min of incubation at 56 °C [18]. This important finding inspired us to elucidate the osteogenic properties

of previously pasteurized bone graft (56 °C for 20 min) with regard to its use in bone transplantation. Therefore, our aim in the present study was to establish the efficacy of pasteurized bone allografts in the healing process for bone defects in rabbits. Autoclaved and frozen allografts were used as control allografts of known biological validity. Due to its good osteogenic potential, the rabbit is the best experimental animal for such a study. Moreover, the surgical procedure performed on the rabbit's ulna is simple and reasonably reproducible, as the skeletal dimensions are appropriate. The present results suggest that the temperature applied, quite sufficient to disinfect the bone allograft of HIV, does not interfere with the osteogenic properties of a pasteurized bone graft.

## Materials and Methods

**Animals.** Fully grown male rabbits, weight 3–4 kg, were housed in standard cages at controlled temperature (25 °C) with free access to water and standard pellet food (MK Moslavka, Kutina, Croatia). Sixty animals were divided into 3 test groups according to the kinds of variously prepared allografts. Ten animals in each test group were sacrificed after 2 weeks and 4 weeks, respectively. Five more animals were used as bone donors for preparing bone tissue implants. The animal experiment was carried out in accordance with Medical School Policies and Guidelines for the Care and Use of Laboratory Animals. All efforts were made to minimize animal suffering.

**Bone allografts.** The femora, tibia, and coxae were isolated from bone donor animals under aseptic conditions. The periosteum and articular cartilage were carefully removed from the bone surface. Thereafter, the bones were cut up into small fragments with Luer's rongeur (particles ca. 1 mm<sup>3</sup>). Such fragmented bones were kept sterile and frozen in the bone bank at –70 °C for 6 weeks.

**Preparation of experimental allografts.** Frozen allogeneous bone grafts: corticocancellous bone grafts from the bone bank were thawed in saline solution at room temperature immediately prior to their use.

Pasteurized allogeneous bone grafts: corticocancellous bone grafts from the bone bank stored in sterile test tubes were thawed at 56 °C for 20 min in a waterbath.

Autoclaved allogeneous bone grafts: corticocancellous bone grafts from the bone bank, stored in sterile test tubes were sterilized at 120 °C for 20 min.

**Surgery.** Rabbits were anesthetized with intravenous injection of Midazolam (0.25 mg/kg) and Fantanyl (0.005 mg/kg) via the marginal ear vein. The middle part of the ulna's shaft was exposed extraperiosteally under tourniquet ischemia and aseptic conditions. The periosteum was incised circumferentially and removed. Thereafter, a bone defect was created that was as close to the same length as possible as the diameter of the bone shaft at this point (approximately 4 mm). A dental drill was used for this purpose to avoid thermal damage to the bone ends that can be caused by a saw. The bone defect was completely filled with previously prepared bone allograft taken from the bone bank. The soft tissues were restored, and skin was carefully sutured. One of us (B.L.) performed all the surgical procedures in this study, achieving what was considered to be a uniform technique. After surgery, animals received penicillin (750,000 IU intramuscularly). No internal or external fixation was used, since the weight-bearing load is not transmitted through the ulna in rabbits. No sign of infection or locomotion disturbance was observed during the experimental period.

At the end of the experimental period, the animals were sacrificed by an overdose of the pentobarbital. A segment of the ulna containing the experimental graft was excised *en bloc*, including portions of normal ulna proximal and distal to the graft along with a generous investment of soft tissue.

Roentgenograms were made of all animals 2 days after surgery to confirm graft placement. After the animals were sacrificed, roentgenograms were obtained again to check the appearance of the bone defect healing. However, the roentgenograms proved to be of little value in assessing of the effectiveness of the various types of grafts and were therefore not used in the final evaluation.

**Tissue preparation.** Tissue specimens were fixed in 4% paraformaldehyde, dehydrated in ethanol, cleared in xylene, and embedded undecalcified in methyl methacrylate. Serial tissue slices, 7  $\mu\text{m}$  thick, were cut parallel to the bone axis, with a Leica RM 2155 microtome equipped with a tungsten carbide knife and placed onto silanated glass slides (Silane-Prep slides, Sigma Chemical Co., St. Louis, MO, USA), dried at 37 °C in a thermostat and stained with hematoxyline - eosine and toluidine blue.

**Methods of evaluation.** Tissue morphology and cellular mechanisms of the healing process induced by implantation of different allografts were analyzed. During the course of this study, it became apparent that there

were 5 key histological features in the healing process that must be considered and included in an evaluation of the experiment: the appearance of the allograft particles, the restoration of continuity between bone edges, the callus, the bone edges, and the quality of newly formed bone. Even though histology clearly revealed differences in tissue reaction after different allograft transplantation, it was not possible to compare the status of different specimens on the basis of descriptive histology. Therefore, a kind of semiquantitative system was applied with numerical rates for each of the key morphological structures listed above. A similar method of numerical evaluation was described by Heiple [3], but as his experiment differed from ours, we modified the parameters included in the evaluation. In order to obtain objective analysis, the evaluation was carried out by 2 independent observers (S.Z., D.B.). The maximum quality of the bone healing process was evaluated by a score of 13. The arbitrary scale used in our numerical evaluation was:

1. the appearance of the allograft: particles of allograft are intact (0), new cellular activity on the surface of bone particles (1), allograft is fully incorporated (2).
2. restoration of continuity between bone edges: no (0), yes (1).
3. callus: no callus (0), fibrous callus (1), chondral callus (2), bone callus (3).
4. bone edges: necrotic (0), resorbed (1), new bone apposition (2).
5. quality of new bone: initial apposition of new bone on the transplant surface (1), single nodules of woven bone (2), trabeculas of woven bone (3), bridging trabeculas (4), lamellar bone trabeculas (5).

Histomorphometric analysis was obtained by an image analyzer (Sform, VAMS, Zagreb, Croatia) using the Olympus BX 50 microscope (Olympus Optical Co. Ltd., Tokyo, Japan). Osteoid thickness was measured (O. Th. ( $\mu\text{m}$ )), on the surface of the bone graft particles and on newly formed bone. Osteoid was identified in toluidin blue stained tissue sections as a pale blue layer overlying the newly formed bone or graft particles, and covered with a layer of cuboidal osteoblasts on its surface. The thickness of the osteoid was measured at 4 equally distant points and expressed as its mean value [19].

Osteoblast number was expressed as the ratio of osteoblast number (Nb Ob) per bone surface (Tb. Pm. ( $\mu\text{m}$ )) [19]. Osteoblasts were identified as cuboidal blue-stained cells with a basal nucleus.

Measurements were taken on 5 randomly chosen



power fields along the entire tissue section, including 6 section per specimen. All histomorphometric data are given as mean values  $\pm$  standard error of the mean. Statistic analysis was performed using the Student's *t*-test for impaired data (Statistica for windows) and *P* values  $<$  0.05 were considered statistically significant.

## Results

**Radiographic findings.** The appearance of the implanted graft at 2 days after surgery is shown in Fig. 1A. Two weeks after surgery, all 3 types of allografts showed an irregularly shaped callus on radiographic examination (data not shown). Four weeks after surgery, most pasteurized and frozen types of grafts had a regularly shaped callus, while the callus of autoclaved grafts was still irregularly shaped (Fig. 1B, 1C, 1D).

**Histological analysis after 2 weeks** Allograft particles were identified by their irregular shape, sharp and irregular edges, irregularly oriented lamellas, and empty osteocyte lacunas (Fig. 2A, 2B, 2C).

Frozen and pasteurized allograft bone particles were surrounded by dense connective tissue with cell infiltrate, blood vessels, and blood cells (Fig. 2B, 2A). Accumulated osteoblasts were seen on the surface of the graft particles. Scattered newly formed bone with pali-

sades of osteoblasts with underlying osteoid was found within a bone defect. The cortical bone showed the initial endosteal and periosteal reaction with cellular accumulation. Osteoblastic activity of the host bone was also found on the edges of the bone defect (Fig. 2D, 2E).

In contrast, osteoblasts were rarely found on the surfaces of bone particles in the autoclaved allografts. The bone particles seemed to be preserved, and some had even been resorbed (Fig. 2C). No resting lining cells were found on the surface of graft particles. The bone edges were clear with no sign of cell activity (Fig. 2F). Only a weak endosteal and periosteal cellular reaction could be seen around the host cortical bone.

**Histological analysis after 4 weeks.** In pasteurized and frozen allografts, most of the particles were resorbed and substituted with newly formed bone by the process of remodeling. Newly formed trabeculas of woven bone or even lamellar bone had bridged over opposite edges of the bone defect (Fig. 3D, 3E). The remaining allograft particles were incorporated into the newly formed bone tissue. A very strong periosteal and endosteal reaction with bone remodeling could be seen in the host cortical bone. The callus of cartilaginous tissue with peripheral ossification was well-developed. Large amounts of osteoid and numerous osteoblasts were placed on the surfaces of remaining particles and newly formed

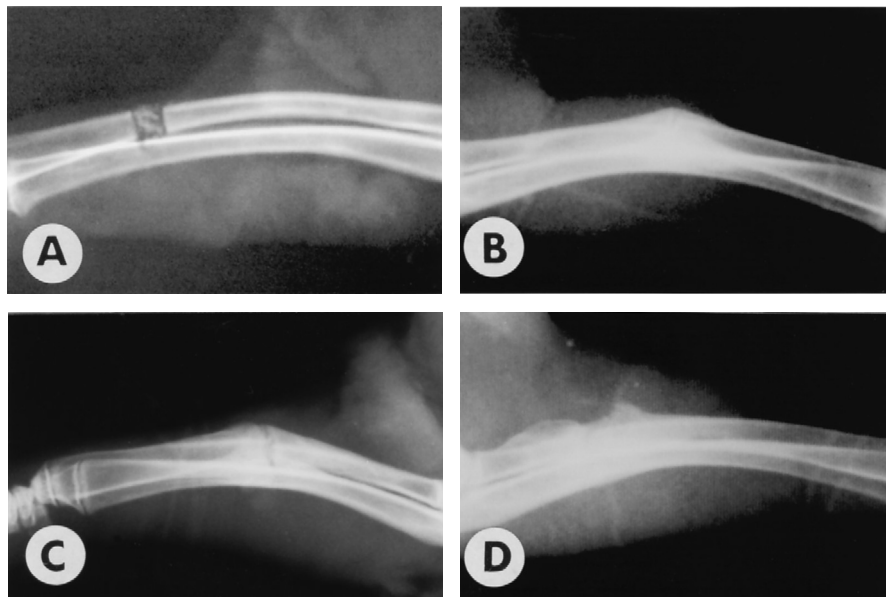
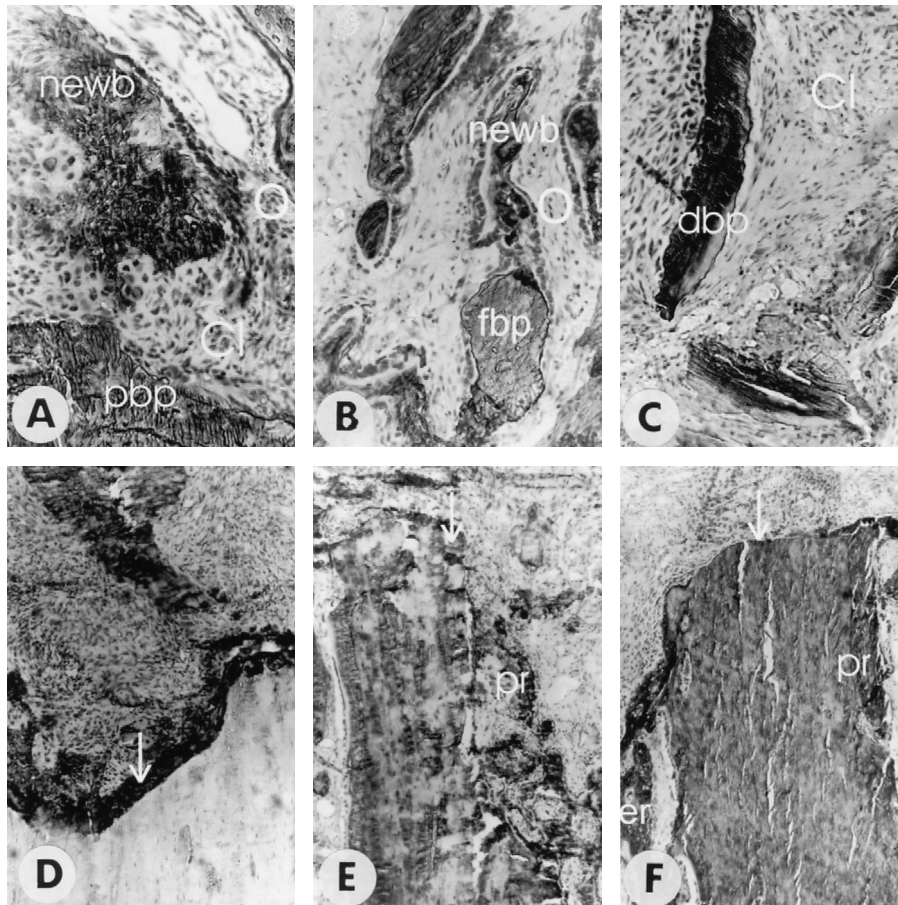


Fig. 1 Roentgenograms show the appearance of the bone allografts at 2 days after surgery (A), then pasteurized (B), frozen (C) and autoclaved (D) grafts at 4 weeks after implantation.



**Fig. 2** The results of tissue and cellular events during the healing process induced by 3 types of bone allografts at 2 weeks after transplantation (toluidin blue,  $200\times$ ). Strong cellular infiltration (Cl) around pasteurized bone allograft particles (pbp), numerous osteoblasts (O) forming new bone (newb) (A); cellular infiltration (Cl) around the frozen bone allograft particles (fbp), numerous osteoblasts (O) forming new woven bone (newb) (B); cellular infiltration (Cl) around the autoclaved bone allograft particles (abp) (C); pasteurized allograft-the host bone edge ( $\downarrow$ ) shows stronger cellular activity with the beginning of remodeling (D); frozen allograft-cellular activity on the host bone edge ( $\downarrow$ ) with the beginning of remodeling, strong periosteal reaction (pr) (E); autoclaved allograft-the edge of the host bone ( $\downarrow$ ) shows no visible changes, weak periosteal (pr) and endosteal reactions (er) (F).

bone trabeculas (Fig. 3A, 3B).

In autoclaved bone grafts, most of the particles remained unchanged (Fig. 3C). Here and there, formation of new bone with adjacent osteoblasts could be seen. On some parts of the bone edge a new bone apposition could be seen, but the connection with the newly formed regenerative bone in the defect had not yet been established (Fig. 3F).

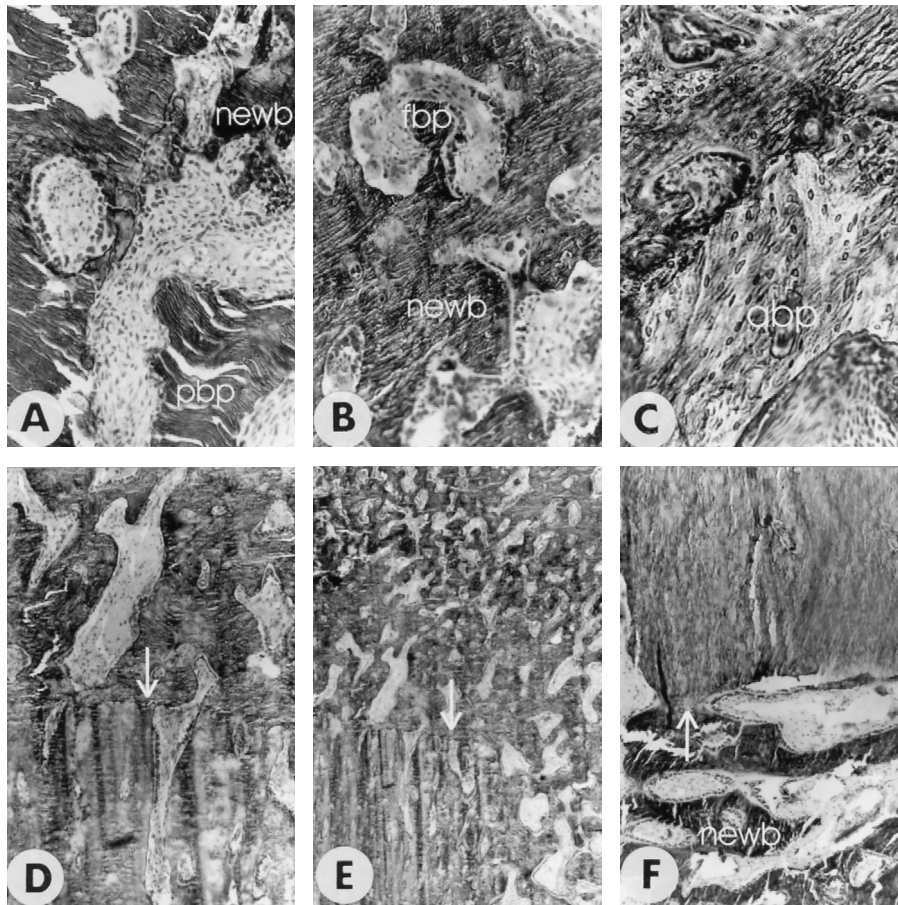
**Numerical evaluation.** Numerical evaluation of the morphological structures involved in the bone healing process showed almost the same numerical values for pasteurized and frozen bone allografts at 2 weeks and 4 weeks after transplantation. In contrast, the numerical

values for autoclaved bone allografts were markedly lower in both experimental periods (Table 1).

**Results of histomorphometry.** The mean osteoid thickness (O.Th) in frozen ( $4.45 \pm 0.06 \mu\text{m}$ ) and pasteurized ( $3.51 \pm 0.06 \mu\text{m}$ ) grafts differed significantly from that in autoclaved grafts ( $1.28 \pm 0.04 \mu\text{m}$ ) ( $P < 0.005$ ).

Correspondingly, there was a significant difference in the osteoblast number per  $\mu\text{m}$  in frozen ( $0.16 \pm 0.016$ ) and pasteurized ( $0.19 \pm 0.002$ ) grafts when compared with autoclaved grafts ( $0.075 \pm 0.001$ ) ( $P < 0.005$ ).





**Fig. 3** The tissue and cellular events during the healing process induced by 3 types of bone allografts at 4 weeks after transplantation (toluidin blue, 200 $\times$ ). Pasteurized allograft-particles residues (pbp), new bone (newb) (A); frozen allograft-particles (fop) are almost completely resorbed, newly formed woven bone (newb) (B); autoclaved allograft-bone particles are still unresorbed (abp) (C); pasteurized allograft-advanced remodeling on the host bone edge ( $\downarrow$ ), continuity with newly formed bone (newb) in defect (D); frozen allograft-advanced remodeling on the host bone edge ( $\downarrow$ ), continuity with newly formed woven bone (newb) in defect (E); autoclaved allograft-the beginning of remodeling on the bone edge ( $\downarrow$ ), without continuity with newly formed bone (newb) in defect (F).

**Table 1** The results of numerical rating of the healing process induced by implantation of differentially prepared bone allografts

Type of allograft	2 weeks after transplantation	4 weeks after transplantation
Autoclaved allografts	4.4 $\pm$ 0.241	7.2 $\pm$ 8.04
Frozen allografts	8.4 $\pm$ 0.67*	12.4 $\pm$ 0.78*
Pasteurized allografts	7.2 $\pm$ 0.34*	11.3 $\pm$ 0.92*

The assessment was performed by 2 independent observers. The results are expressed as mean  $\pm$  standard error of the mean (\*statistically significant difference vs. autoclaved allografts,  $P < 0.005$ , Student's  $t$ -test).

## Discussion

Because there is a high risk of HIV and other viral transmission through bone allograft transplantation [6, 7, 8, 10], it is necessary to develop an adequate procedure that can achieve viral inactivation, but does not compromise the biological osteoinductive properties of bone allografts [2, 16]. It has been shown that pasteurization (56 °C for 20 min) successfully eliminates HIV [17] and, importantly, that the thermal energy of pasteurization does not affect the activity of the growth factors in the bone matrix responsible for osteoinduction [16]. In accordance with these results, our study has demonstrated that transplantation of pasteurized bone allografts induces the same rate of bone formation within the bone defect as frozen allografts. Because frozen bone allografts perform satisfactory in bone transplantation surgery [13] we can conclude that pasteurized bone allografts may be used for the same purpose. At the same time, pasteurization does prevent viral transmission, which is crucial to today's transplantation surgeries. This study is the first report of the efficacy of pasteurized bone allografts in inducing bone formation in experimental bone defects in rabbits.

During histological analysis, it became apparent that there are certain histological features and structures within bone defects that must be considered and included in evaluating the success of bone allografts, as they strongly reflect the intensity of the bone-induction process within the site of allograft transplantation. The first histological structure of interest was the particles of the transplanted allografts. It was found that the majority of particles in the pasteurized allografts, as with the frozen allografts, had been almost completely resorbed and incorporated within 4 weeks of transplantation, while most of the autoclaved bone particles were still intact and unresorbed. These results suggest that pasteurized bone allograft particles act rapidly in the bone-induction process, as do frozen ones. In these allografts, incorporation of particles was found to be connected with new bone formation, which was the second structure of interest. Newly formed bone was found in different stages of development. Most of this newly formed bone was woven bone, according to the classification of bone tissue, and rarely lamellar bone tissue. In the case of autoclaved bone allografts, however, newly formed woven bone was observed only rarely. Within 4 weeks, newly formed bone tissue induced by pasteurized and frozen allografts had even

bridged over some parts of the bone defect. The newly formed bone tissue established continuity with host-bone edges, and in these cases the bone-induction processes were more pronounced.

In addition, histology revealed new endosteal, periosteal, and perivascular bone formation in both pasteurized and frozen bone grafts, with minor morphologic differences after 2 weeks and stronger reactions after 4 weeks.

Even though histology clearly revealed differences in tissue reaction after transplantation of the different allografts, it was not possible to compare the status of different specimens on the basis of descriptive histology. To establish the differences between bone inductions induced by different types of allograft transplantation with more accuracy, a proposed semiquantitative system was applied with numerical rates for each of the key morphological structures described above. Heiple has described a similar method of numerical evaluation [3], but as his experiment differed from ours, we modified the parameters included in the evaluation and designed a new original scale system.

The numerical rating scale used for quantification of histological structures important to the bone-induction process, designed expressly for this study. The proposed scale system proved to be useful and revealed the superiority of the frozen allografts in bone induction. The numerical value of pasteurized allografts did not differ significantly from those of the frozen allografts, confirming again that pasteurized bone allografts do not lose their osteoinductive properties.

Histomorphometric parameters - osteoid thickness and osteoblast number did not differ significantly between frozen and pasteurized groups but were significantly higher in relation to the autoclaved group. The higher osteoblast numbers in these 2 groups clearly indicates that transplantation of these allografts induces higher cellular infiltration and osteoblast differentiation [19]. These findings once more indicate that pasteurized allografts have the same osteoinductive properties as frozen bone.

These 3 methods of evaluation (histology, the numerical rating system, and histomorphometry) all gave the same results regarding pasteurized and frozen bone, leading to the conclusion that pasteurization of bone allografts does not alter the biological validity and that transplantation of pasteurized allografts induces satisfactory new bone formation.

The results regarding the efficacy of the different types

of bone allografts and their differences were also confirmed by a radiological method. However, as this method provides only a general perspective regarding the bone defect healing process, we did not use it for further evaluation, nor did Heiple in his study [3].

A certain activation of bone cells leading to a bone-healing response was also revealed in the autoclaved group. The significantly fewer active osteoblasts that were revealed in the autoclaved bone graft, however, was probably due to osteoconductive properties, as we know that high temperatures (80 °C) inactivate growth factors and that there is thus no further stimulation of osteogenesis [15]. The above only confirm why autoclaved bone grafts have been abandoned in bone transplantation surgery [1, 3].

Because the value for autoclaved and frozen bone allografts in transplantation surgery are known, we used these allografts as controls for estimation of the efficacy of pasteurized bone grafts.

In that respect, we can conclude that heat pretreatment at 56 °C for 20 min does not alter the biological qualities of pasteurized bone allografts. Since it is known that pasteurization prevents HIV transmission [11, 17], we suggest that such pretreated bone allografts from a bone bank could be safely and successfully used for bone transplantation.

**Acknowledgments.** This study was performed under a project funded by the Croatian Ministry of Science and Technology.

## References

- Solomon L: Bone grafts. *J Bone Joint Surg Br* (1991) **73**, 706-707.
- Friedlaender GE: Bone allografts: The biological consequences of immunological events. *J Bone Joint Surg Am* (1991) **73**, 1119-1122.
- Heiple KG, Chase SW and Herndon CH: A comparative study of the healing process following different types of bone transplantation. *J Bone Joint Surg Am* (1963) **45**, 1593-1616.
- Nemzek JA, Arnoczky SP and Swenson CL: Retroviral transmission by the transplantation of connective-tissue allografts. An experimental study. *J Bone Joint Surg Am* (1994) **76**, 1036-1041.
- Nemzek JA, Arnoczky SP and Swenson CL: Retroviral transmission in bone allotransplantation. The effects of tissue processing. *Clin Orthop* (1996) **324**, 275-282.
- Simonds RJ, Holmberg SD, Hurwitz RL, Coleman TR, Bottenfield S, Conley LJ, Kohlenberg SH, Castro KG, Dahan BA, Schable CA, Rayfield MA and Rogers MF: Transmission of human immunodeficiency virus type I from a seronegative organ and tissue donor. *N Engl J Med* (1992) **326**, 726-732.
- Schratt HE, Regel G, Lobenhoffer P and Tscherne H: Organisation of a bone and tissue bank. Consequences for organization of bone and tissue banks after HIV and hepatitis C infections. *Unfallchirurg* (1996) **99**, 880-888.
- Bettin D, Dethloff M, Polster J, Steinbeck J and Fiedler R: HIV-screening in bone transplantation. *Unfallchirurg* (1993) **96**, 636-640.
- Knaepler H, von Garrel T, Seipp HM and Ascherl R: Experimental studies of thermal disinfection and sterilization of allogeneic bone transplants and their effects on biological viability. *Unfallchirurg* (1992) **95**, 477-484.
- Norman-Taylor FH and Villar RN: Bone allograft: A cause for concern? *J Bone Joint Surg Br* (1997) **79**, 178-180.
- Spire B, Dormont D, Barre-Sinoussi F, Montagnier L and Chermann JC: Inactivation of lymphadenopathy-associated virus by heat, gamma rays, and ultraviolet light. *Lancet* (1985) **1**, 188-189.
- Tomford WW: Transmission of disease through transplantation of musculoskeletal allografts. *J Bone Joint Surg Am* (1995) **77**, 1742-1754.
- Tomford WW, Ploetz JE and Mankin HJ: Bone allografts of femoral heads: Procurement and storage. *J Bone Joint Surg Am* (1986) **68**, 534-537.
- Aspenberg P, Johnsson E and Thorngren K-G: Dose-dependent reduction of bone inductive properties by ethylene oxide. *J Bone Joint Surg Br* (1990) **72**, 1036-1037.
- Knaepler H, Koch F and Bugany H: Studies on HIV inactivation in allogeneic bone transplants using chemical disinfection and radioactive irradiation. *Unfallchirurg* (1992) **18**, 1-6.
- Stevenson S and Horowitz M: The response to bone allografts. *J Bone Joint Surg Am* (1992) **74**, 939-950.
- Uemura Y, Yang YHJ, Heldebrant CM, Takechi K and Yokoyama K: Inactivation and elimination of viruses during preparation of human intravenous immunoglobulin. *Vox Sang* (1994) **67**, 246-254.
- Spire B, Barre-Sinoussi F, Montagnier L and Chermann JC: Inactivation of lymphadenopathy associated virus by chemical disinfectants. *Lancet* (1984) **2**, 899-901.
- Parfitt AM: Bone histomorphometry: Standardization of nomenclature, symbols and units. Summary of proposed system. *Bone Miner* (1988) **4**, 1-5.