

Kidney Complications Due to Hematopoietic Stem Cell Transplantation-A Disorder of an Increasing Incidence?

Orlić, Lidija; Mikolašević, Ivana; Pavletić-Peršić, Martina; Jelić, Ita; Raspor-Flajšman, Sanja; Rački, Sanjin

Source / Izvornik: **BANTAO Journal, 2014, 12, 90 - 96**

Journal article, Published version

Rad u časopisu, Objavljena verzija rada (izdavačev PDF)

<https://doi.org/10.2478/bj-2014-0018>

Permanent link / Trajna poveznica: <https://um.nsk.hr/um:nbn:hr:184:275561>

Rights / Prava: [Attribution-NonCommercial-NoDerivatives 4.0 International/Imenovanje-Nekomercijalno-Bez prerada 4.0 međunarodna](#)

Download date / Datum preuzimanja: **2024-09-19**



Repository / Repozitorij:

[Repository of the University of Rijeka, Faculty of Medicine - FMRI Repository](#)



*Review***Kidney Complications Due to Hematopoietic Stem Cell Transplantation-A Disorder of an Increasing Incidence?**Lidija Orlic¹, Ivana Mikolasevic¹, Martina Pavletic-Persic¹, Ita Jelic¹, Sanja Raspor-Flajsman² and Sanjin Racki¹¹Department of Nephrology, Dialysis and Kidney Transplantation, ²Pediatric Clinic "Kantrida", University Hospital Center Rijeka, Rijeka, Croatia**Abstract**

Hematopoietic stem cell transplantation (HSCT) is becoming an increasingly popular treatment considering that it is the only curative option for many malignant and non-malignant diseases. Many patients treated in this way have been followed for two or three decades post-transplant and are presumed to be cured. But, on the other hand, a great proportion of these patients are experiencing long-term side effects after HSCT, including non-malignant organ or tissue dysfunction, changes in quality of life, infections and secondary malignancy. Renal complications caused by HSCT are high and are associated with the development of both acute and chronic kidney failure. So, considering the increasing numbers of HSCT survivors many years after the transplantation, chronic kidney disease due to HSCT is becoming a growing problem and represents a new population of patients who are presented to nephrologists. The three most common forms of chronic kidney disease related to HSCT are: chronic calcineurin nephrotoxicity, glomerular disease after HSCT and HSCT associated thrombotic microangiopathy.

Key words: hematopoietic stem cell transplantation, acute kidney failure, chronic kidney failure

Case presentation

In January 2013 a 21-year-old man was admitted to the Department of Nephrology after experiencing pedal and facial edema for the last 14 days. His medical history began in 2007 when he was diagnosed with acute lymphoblastic leukemia (ALL). He underwent chemotherapy according to the ALL-IC-BFM 2002. After an apparent remission, three years later he presented with isolated medullary relapse. He received treatment with the ALL-REZ BFM protocol that led to cytomorphological remission. The patient underwent myeloablative allogeneic

peripheral stem cell transplantation with his HLA-identical sister as the donor. The conditioning regimen consisted of cyclophosphamide and 12-Gy total-body irradiation. The patient received cyclosporine and methotrexate for graft-versus-host disease (GVHD) prophylaxis. He responded well and continued further ambulatory monitoring by a hematologist. There was no sign of residual ALL on follow-up.

Results of his physical examination showed periorbital and pretibial edema. Renal function was normal; with a serum creatinine level of 80 $\mu\text{mol/L}$. He had proteinuria with protein of 9 g/24h. The kidney ultrasound was normal. He underwent a percutaneous renal biopsy that showed membranous nephropathy. Further hematological investigation showed no signs of ALL relapse.

Introduction

Hematopoietic stem cell transplantation (HSCT) is becoming an increasingly popular treatment considering that it is the only curative option for many malignant and non-malignant diseases [1]. In general, HSCT consists of three steps. In the first phase, patients are given preconditioning regimen which consists of total-body irradiation and/or chemotherapy. The decision whether to perform myeloablative or nonmyeloablative conditioning regimen depends on the patient age, comorbid states, the underlying disease and the disease stage. Myeloablative regimens may be associated with high morbidity during the cytopenic period, and for this reason this approach is reserved for younger patients without co-morbid conditions. In the second step, the patient receives an infusion consisting of bone marrow, peripheral-blood, or umbilical cord progenitor cells which are derived from either a donor (and then we are talking about allogeneic HSCT) or the patients themselves (autologous HSCT). In the third step immunosuppressive medications are used in order to decrease the risk of graft-versus-host disease (GVHD). These are usually methotrexate or the calcineurin inhibitors

(CNIs) cyclosporine or tacrolimus. Using the mentioned approach many patients have now been followed for two or three decades post-transplant and are presumed to be cured [1,2]. On the other hand, a great proportion of these patients are experiencing long-term side effects after HSCT, including non-malignant organ or tissue dysfunction, changes in quality of life, infections and secondary malignancy [3]. Rates of renal complications caused by HSCT have been reported as high as 92% and are associated with the development of both acute and chronic kidney failure [4]. The risk factors for kidney injury following HSCT vary depending on the types of regimens that are used in patients undergoing HSCT. Namely, a high-dose conditioning regimen is used in both myeloablative allogeneic and autologous HSCT and frequently in combination with high dose radiotherapy. Furthermore, myeloablative allogeneic HSCT also requires the use of immunosuppressive therapy post-transplant, most of the time with calcineurin inhibitors and this is not necessary in autologous HSCT [2,5]. Recently, a newly developed form of HSCT, a non-myeloablative or reduced-intensity conditioning (RIC) allogeneic HSCT is being used in older patients or in those with co-morbid medical conditions. With this procedure patients receive a lower dose of chemoradiotherapy, but post-transplant immunosuppression therapy is also required. The intensity of the conditioning regimen, especially the use of full-dose myeloablative total body irradiation (TBI) is more likely to cause late complications after allo-HSCT. On the other hand, it has been well-established that the use of RIC can reduce short-term acute toxicity, but it has also been well-documented that the probability of chronic graft-host-versus disease (cGHVD) is not reduced after implementation of this regimen, namely because this approach is used in older patients and in more advanced disease stages [1,6-8]. These observations are supported by the study of Al Hazzouri, as well [9]). In the aforementioned analysis the authors have investigated the appearance of chronic kidney disease (CKD) in patients that have received RIC versus myeloablative regimens, and they observed that there were no significant differences in terms of renal complications between two patients' groups. According to this observation and considering the increasing incidence of HSCT related nephropathy, the aim of this review is to provide an update on the recent knowledge in the approach to patients with suspected HSCT nephropathy.

Acute kidney injury (AKI) after HSCT

The incidence of AKI in the days and weeks following myeloablative regimens varies from 30% to 90%. It is significantly higher in patients receiving an allogeneic HSCT, and approximately 33% of these patients require renal replacement therapy (RRT) (10). Mortality is 2 to 7 times higher in patients experiencing AKI compared

to those without AKI, and when those patients require RRT, the mortality rates may eventually rise to more than 80%, mainly due to association with coexistent injury of multiple organs [11,12]. Also, the important risk factor that may be driving the sustained rates of AKI is patients' age at the time of transplantation, which is steadily increasing. The fastest growing group of patients who undergo HSCT includes patients over the age of 60. It has already been well-established that age is a risk factor for AKI. Acute kidney injury following HSCT is related to prerenal (such as fluid depletion, sepsis, drugs...), intrinsic renal (acute tubular necrosis due to ischemia, nephrotoxic drugs, acute interstitial nephritis, infection-associated kidney injury and vascular disorders) and postrenal (intratubular or extratubular obstruction) causes [2]. During the first month after HSCT the main predisposing factors for development of AKI are: sepsis, nephrotoxic drugs, obstruction, tumor lysis syndrome, hepatorenal syndrome from veno-occlusive disease, acute thrombocytopenic purpura or hemolytic uremic syndrome (TTP/HUS), acute graft-host-versus disease (aGHVD) and cytomegalovirus (CMV) reactivation. Venous-occlusive disease (VOD) usually develops within 30 days after HSCT with the incidence of approximately 10% for allogeneic HSCT, and with lower incidence rate for autologous HSCT. VOD is also known as sinusoidal obstruction syndrome, and is a conditioning-related toxicity usually associated with regimens including cyclophosphamide, busulfan, and/or total body irradiation. Clinically, it is characterized by an acute onset of jaundice, ascites and painful hepatomegaly followed by azotemia, low urine sodium excretion and with bland urine. The severity of the disease varies. In mild to moderate cause hepatic injury is self-limited, but this condition can progress to multi-organ failure (MOF) [2,11,13]. Tumor lysis syndrome is characterized by hyperkalemia, hyperuricemia, hyperphosphatemia, and hypocalcemia. Acute graft-host-versus disease (aGHVD) is the most frequent complication following allogeneic HSCT and it usually occurs within the time frame of two weeks up to three months after transplantation and aGHVD causes renal injury that ranges from prerenal azotemia to thrombotic thrombocytopenic purpura-like microangiopathy [2]. TTP-like microangiopathy has a poor response to treatment with apheresis and is accompanied by a mortality rate up to 60%. When approaching a patient with AKI following HSCT, it's important to differentiate the cause of renal failure. According to this, management of AKI ranges from adequate use of fluids, antibiotics, avoidance of nephrotoxic agents, use of dialysis, etc. Treatment of hepatorenal syndrome due to veno-occlusive disease in these cases is mainly supportive [13]. Treatment of TTP/HUS because of the applied specific therapy primarily involves avoidance of the aforementioned medications. Management of

other types of TTP/HUS demands implementation of plasma exchanges and/or eculizumab [2]. There is no convincing data to support the efficiency of plasma exchange in patients who develop thrombotic microangiopathy after HSCT. This is in contrast to the well-known beneficial effect seen in most other forms of TTP-HUS. This might be partially explained by the fact that TTP-HUS following HSCT occurs due to direct injury to the kidney from nephrotoxic drugs and/or radiation. Treatment of tumor lysis syndrome consists of identifying those patients that are at risk, careful laboratory monitoring and the use of prophylactic therapy (hydration, urine alkalinization and use of xanthine oxidase inhibitors). Acute renal failure due to tumor lysis syndrome often requires some dialysis treatment (hemodialysis and/or hemofiltration) [14-16].

Chronic kidney disease (CKD) after HSCT

Within six months of transplantation some of the patients who undergo HSCT develop chronic kidney disease (CKD). The incidence of CKD related to HSCT varies worldwide and depends on the used diagnostic criteria, definition of CKD, duration of follow-up, and the type of HSCT. When we include all these factors the incidence of CKD related to HSCT ranges from 15% to as high as 60%. The growth in non-myeloablative protocols may actually increase the incidence of CKD in patients undergoing HSCT despite its milder conditioning regimen, because of older patients' age and increased baseline co-morbidities in this population of patients [2,17-18]. Independent risk factors for development of CKD include AKI in the first 100 days, previous autologous HSCT, CNI use, and chronic GVHD [2].

The three most common forms of CKD related to HSCT are: chronic CNI nephrotoxicity, glomerular disease after HSCT (chronic GVHD-associated glomerulonephritis), and HSCT associated thrombotic microangiopathy (TA-TMA) [2].

Chronic CNI nephrotoxicity

Calcineurin inhibitors, mainly cyclosporine and tacrolimus, can cause renal injury similar to that seen in other settings, such as solid organ transplantation. These are used to prevent GVHD in the period of several months after allogeneic HSCT. This approach is associated with a 25% incidence of moderate to severe aGVHD. According to these observations, patients who require prolonged therapy for GVHD will receive these medications for a longer period of time and are at great risk of developing side-effects, mainly nephrotoxicity. The main pathohistological findings are non-specific and include obliterative arteriopathy, afferent arteriolar hyalinosis, and patchy interstitial fibrosis [2,19-20].

HSCT associated thrombotic microangiopathy (TA-TMA)

Transplant-associated thrombotic microangiopathy (TA-TMA) is a severe complication of HSCT, and usually occurs within 6 to 12 months after transplantation. The kidney is the most commonly affected organ, but in some cases it may present as a systemic condition, with high mortality rate, while in milder cases there is an increased risk of a resulting chronic kidney disease [2,21-23]. Published studies have shown discrepant results in the incidence rates of TA-TMA, ranging from 0.5% to 76% which is mainly due to diagnostic uncertainty, and limited prospective data. According to the most large, retrospective studies, the incidence rate of TA-TMA is about 10-25%, which more likely represents the true burden of the disease [2,24].

The pathogenesis of thrombotic microangiopathy after HSCT is still poorly understood but it is believed that the most important setting in the pathogenesis of TA-TMA is the endothelial injury in the context of HSCT. Namely, it is believed that during the first six months after transplantation various etiological factors cause endothelium injury, which leads to endothelial inflammation. Furthermore, dysregulation of interaction between platelets and damaged endothelium results in thrombosis and fibrin deposition in the microcirculation, which in turn causes end-organ damage [2]. The most important risk factors for development of TA-TMA are: irradiation and chemotherapy, mainly the use of cyclophosphamide, busulfan, cisplatin and carmustine [24,25]. Radiotherapy is performed as a total-body irradiation or radio-immunotherapy or both treatments are implemented. TA-TMA is more common after allogeneic HSCT, but it can develop in patients who undergo autologous transplantation. Both myeloablative and reduced intensity conditioning regimens are risk factors for developing TA-TMA. Recent investigations have failed to produce a statistical difference in the prevalence of TA-TMA between reduced intensity and myeloablative conditioning regimens. Furthermore, it is known that partial renal shielding during total body irradiation may reduce the risk of TA-TMA development [2,25-27].

It is also believed that several other conditions may contribute to the development of TA-TMA, such as: scleroderma, pregnancy-related kidney disease, malignancy, numerous medications and infections (most commonly *Aspergillus*, cytomegalovirus, and adenovirus). It remains unclear if other potential infections (parvovirus B19, human herpes virus-6, and BK virus infection) play a role in the development of TA-TMA even though there has been a great interest in their role. It is important to emphasize that TA-TMA can occur in the presence or absence of GVHD, and with or without a triggering infection [28-30].

However, considering the complexity of the HSCT population, it's doubtful that a single etiological factor is responsible for the development of TA-TMA in all affected patients and it is more likely that TA-TMA is a consequence of several etiological factors that lead to endothelial injury of the kidney and other organs in the setting of HSCT. This hypothesis is supported by the fact that classic thrombotic microangiopathies have been successfully linked to a single etiology, such as Shiga toxin in diarrhea-positive HUS. According to these observations, TA-TMA was first thought to be TTP but as TA-TMA did not respond as well to plasma exchange as TTP did, this condition was distinct from "classic" TTP/HUS [5]. This might be partially explained by the fact that TTP-HUS following HSCT occurs because of direct injury to the kidney from nephrotoxic drugs and/or radiation. Furthermore, it is believed that deficiency of the ADAMTS-13 protease, present in classic TTP, is not involved in the pathogenesis of thrombotic microangiopathy following HSCT [2,23,24].

The pathohistological features of TA-TMA in the kidney are non-specific and include thickened capillary walls, fragmented erythrocytes, occluded vascular lumens, and endothelial separation accompanied by swelling, fibrin deposition, and necrosis [2,33]. As mentioned above, in contrast to patients with "classic" TTP, patients with TA-TMA have rarely been reported to have systemic thromboses, although recent case reports have presented the involvement of other organs, namely the lungs [32] and the gastrointestinal tract [33].

Characteristic clinical features include slowly rising plasma creatinine, hypertension, and disproportionate anemia, but some patients are experiencing a more fulminant presentation. It is important to say that hypertension is more likely due to CNI-nephrotoxicity. Proteinuria, usually in the absence of persistent hypoalbuminemia, is an important sign of renal involvement in TA-TMA. Also, urinalysis shows variable hematuria, depending on the extent of kidney involvement. In some patients, chronic TA-TMA presents as a low-grade microangiopathic hemolysis with the usual laboratory findings such as intermittent or persistent elevation in plasma lactate-dehydrogenase level, low serum haptoglobin level, anemia, thrombocytopenia, and presence of schistocytes in the peripheral blood [2,16,23,24]. Furthermore, in patients with kidney-limited TMA, the characteristic laboratory findings are missing, and hence a kidney biopsy is necessary in these patients [2].

Treatment of TA-TMA includes medical management and withdrawal of promoting medications, mainly CNIs and cisplatin. However, medical approach includes the use of antihypertensive drugs, use of recombinant erythropoietin, red blood cell transfusions, and plasma exchange. Preclinical studies indicate a beneficial effect of the angiotensin converting enzyme inhibitors (ACEI) in the treatment of HSCT-related TMA. Although the use of ACEI has not been utilized in patients with TA-

TMA, it seems reasonable to believe that patients with persistent proteinuria after HSCT could benefit from this therapy. Further prospective studies are needed to confirm their beneficial effect [2,15,16].

The effectiveness of plasma exchange in the treatment of TA-TMA is unclear, and according to most studies patients who have undergone this treatment had poor response and high mortality rate [34].

According to some studies, the use of new drugs, such as daclizumab, rituximab, defibrotide, and eicosapentaenoic acid could be useful in the treatment of HSCT-related TMA [2,35-37].

Another therapeutic approach to patients with ESRD due to HSCT is kidney transplantation. In the last decade numerous cases of successful kidney transplantation in these patients have been published [2].

In the absence of controlled trials that evaluate additional treatment modalities in patients with HSCT-related TMA, for now, discontinuation of offending agents may be the most promising therapeutic option compared to other treatment modalities.

Glomerular disease after HSCT

Nephrotic syndrome (NS) is a well-documented but rare complication after HSCT. It is mainly related to membranous nephropathy and occurs in about 75% of all cases of HSCT-associated NS [38,39]. It is less frequently related to minimal change disease, focal segmental glomerulonephrosis, diffuse proliferative glomerulonephritis or IgA nephropathy. Post-HSCT NS is characterized with immune-complex deposits, and mainly represents the consequence of GVHD. Namely, most patients with HSCT-related NS have other manifestations of cGVHD at the time of diagnosis. According to some authors this condition could represent the renal manifestation of cGVHD. This hypothesis is supported by the fact that NS usually occurs late in the course of transplantation when the patient is off immunosuppressive therapy [2,4,39-42].

It is also important to say that in adult subjects NS may represent the manifestation of different malignancy states, and the appearance of NS is an absolute indication for renal biopsy. It is necessary to exclude a clinical relapse of primary disease in HSCT patients, as well [4]. Treatment of HSCT-related NS is controversial, and in the absence of randomized controlled trials, the current therapeutic options mostly include use of cyclosporine (CSA) and corticosteroids (CS). In the majority of studies patients were treated with a high-dose steroid therapy (starting dose was 1 mg/kg, and the duration of treatment ranged from 2 months to a year) in order to reduce NS. Furthermore, in most cases the use of an additional immunosuppressive drug was necessary. Cyclosporine was the most commonly used additional drug. The duration of treatment with CSA varies from 6 to 12 months. Other immunosuppressive drugs that are repor-

ted in the setting of HSCT-related NS were mycophenolate, azathioprine, and cyclophosphamide. TNF blockers have showed a limited success, but there are promising results with the use of anti-CD 20 antibody, such as rituximab. According to these observations, the current approach in the treatment of HSTC-related NS should include the use of CSA and CS in order to control the acute manifestations of cGVHD. This is necessary as a prerequisite to the remission of NS [39-42].

Approaching the patients with HSCT-related chronic kidney disease

Patient's history important notes include the type of HSCT, the used conditioning regimen and the use of nephrotoxic drugs, mainly CNIs. General treatment should be recommended for any CKD patient. In a patient with a TA- TMA due to HSCT the hypertension control is necessary in order to reduce endothelial damage. Further-

more, patients with persistent proteinuria after HSCT could benefit from the use of ACEI. Hyperkalemia may be more common in HSCT patients than in patients with other forms of CKD. Diuretics are often needed. Considering the toxicity of CNIs, it is worthwhile to minimize their dosage or to replace them with other agents, such as m-TOR inhibitors, sirolimus or everolimus. According to some investigations, GVHD prophylaxis with sirolimus and mycophenolate mofetil has been found to be promising alternative therapy to CNIs [2,4]. A subset of patients progress to ESRD, and overall patients who undergo hemodialysis have worse survival rates than patients with ESRD due to other etiological factors. Renal transplantation is treatment option in some patients, especially in those who receive a renal-allograft from the same donor as their original HSCT, considering the fact that this approach may obviate the need for antirejection therapy because of the immunotolerance of the allograft [5,4,33].

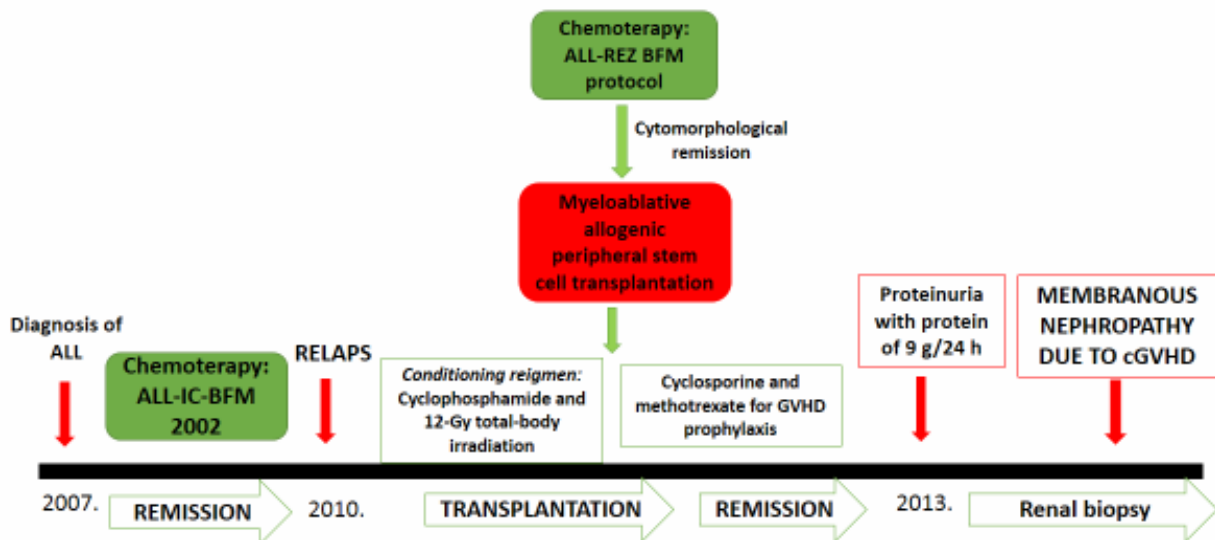


Fig. 1. Schematic view of the disease course in our patient

* acute lymphoblastic leukemia (ALL); graft-versus-host disease (GVHD); chronic graft-versus-host disease (cGVHD)

Case review

In line with the findings of kidney biopsy, nephrotic syndrome associated with membranous nephropathy was diagnosed, probably due to cGVHD. The treatment of the patient started with an oral dose of ramipril 1.25 mg per day. This led to an improvement of hypertension and proteinuria. The patient was discharged from our Department and referred to the Hematological Department because of the need for further immunosuppressive therapy in order to control cGVHD (Figure 1).

Conclusions

Hematopoietic stem cell transplantation offers a curative treatment for many malignant and non-malignant di-

sorders. A wide spectrum of renal involvement can be observed in these patients. Considering the increasing number of HSCT survivors many years after transplantation, especially older patients with co-morbidities, long-term complications such as CKD and ESRD represent a growing problem. Renal biopsies are often needed to identify the underlying cause of renal failure in HSCT patients. According to this, once the underlying pathology is known, an appropriate therapeutic approach can be used in order to prevent progression to ESRD. There is a need for further research in this field in order to better define the natural history and clinical features of HSCT-related kidney injury and the treatment of this relatively new entity.

Conflict of interest statement. None declared.

References

1. Mohty B, Mohty M. Long-term complications and side effects after allogeneic hematopoietic stem cell transplantation: an update. *Blood Cancer J* 2011; 1:e16; doi:10.1038/bcj.2011.14; published online 29 April 2011.
2. Singh N, McNeely J, Parikh S, *et al.* Kidney complications of hematopoietic stem cell transplantation. *Am J Kidney Dis* 2013; 61: 809-821.
3. Martin PJ, Counts Jr GW, Appelbaum FR, *et al.* Life expectancy in patients surviving more than 5 years after hematopoietic cell transplantation. *J Clin Oncol* 2010; 28: 1011-1016.
4. Panduranga SR. Nephrotic syndrome in patients with peripheral blood stem cell transplant. *Am J Kidney Dis* 2005; 45: 780-785.
5. Cohen EP. Renal failure after bone-marrow transplantation. *Lancet* 2001; 357: 6.
6. Mohty M, Bay JO, Faucher C, *et al.* Graft-versus-host disease following allogeneic transplantation from HLA-identical sibling with antithymocyte globulin-based reduced-intensity preparative regimen. *Blood* 2003; 102: 470-476.
7. Mohty M, Kuentz M, Michallet M, *et al.* Chronic graft-versus-host disease after allogeneic blood stem cell transplantation: long-term results of a randomized study. *Blood* 2002; 100: 3128-3134.
8. Mohty M, Bilger K, Jourdan E, *et al.* Higher doses of CD34+ peripheral blood stem cells are associated with increased mortality from chronic graft-versus-host disease after allogeneic HLA-identical sibling transplantation. *Leukemia* 2003; 17: 869-875.
9. Al-Hazzouri A, Cao Q, Burns LJ, *et al.* Similar risks for chronic kidney disease in long-term survivors of myeloablative and reduced-intensity allogeneic hematopoietic cell transplantation. *Biol Blood Marrow Transplant* 2008; 14: 658-663.
10. Matthew JE, Uptal DP. Hematopoietic Stem-Cell Transplantation. *NEJM* 2006; 355: 10.
11. Helal I, Byzun A, Rerolle JP, *et al.* Acute renal failure following hematopoietic cell transplantation: incidence, outcome and risk factors. *Saudi J Kidney Dis Transpl* 2011; 22: 437-443.
12. Zager RA. Acute renal failure in the setting of bone marrow transplantation. *Kidney Int* 1994; 46: 1443.
13. Coppell JA, Richardson PG, Soiffer R, *et al.* Hepatic veno-occlusive disease following stem cell transplantation: incidence, clinical course and outcome. *Biol Blood Marrow Transplant* 2009; 15: 157-168.
14. Coiffier B, Altman A, Pui CH, *et al.* Guidelines for the management of pediatric and adult tumor lysis syndrome: an evidence-based review. *J Clin Oncol* 2008; 26: 2767-2778.
15. Kersting S, Koomans HA, Hene RJ, Verdonck LF. Acute renal failure after allogeneic myeloablative stem cell transplantation: retrospective analysis of incidence, risk factors and survival. *Bone Marrow Transplant* 2007; 39(6): 359-365.
16. Parikh CR, McSweeney P, Schrier RW. Acute renal failure independently predicts mortality after myeloablative allogeneic hematopoietic cell transplant. *Kidney Int* 2005; 67(5): 1999-2005.
17. Hingorani S. Chronic kidney disease in long-term survivors of hematopoietic cell transplantation: epidemiology, pathogenesis, and treatment. *J Am Soc Nephrol* 2006; 17: 1995.
18. Hingorani S, Guthrie KA, Schoch G, *et al.* Chronic kidney disease in long-term survivors of hematopoietic cell transplant. *Bone Marrow Transplant* 2007; 39: 223-229.
19. Cohen EP, Lawton CA, Moulder JE, *et al.* Clinical course of late-onset bone marrow transplant nephropathy. *Nephron* 1993; 64: 626-635.
20. Stewart BL, Storer B, Storek J, *et al.* Duration of immunosuppressive treatment for chronic graft-versus-host disease. *Blood* 2004; 104: 3501-3506.
21. George JN, Li X, McMinn JR, *et al.* Thrombotic thrombocytopenic purpura-hemolytic uremic syndrome following allogeneic HPC transplantation: a diagnostic dilemma. *Transfusion* 2004; 44: 294-304.
22. Cruz DN, Perazella MA, Mahnensmith RL. Bone marrow transplant nephropathy: a case report and review of the literature. *J Am Soc Nephrol* 1997; 8: 166.
23. Changsirikulchai S, Myerson D, Guthrie KA, *et al.* Renal thrombotic microangiopathy after hematopoietic cell transplant: role of GVHD in pathogenesis. *Clin J Am Soc Nephrol* 2009; 4(2): 345-353.
24. Siami K, Kiarash K, Swisher KK, *et al.* Thrombotic Microangiopathy after Allogeneic Hematopoietic Stem Cell Transplantation: An Autopsy Study. *Transplantation* 2008; 85: 22-28.
25. Kojouri K, George JN. Thrombotic microangiopathy following allogeneic hematopoietic stem cell transplantation. *Curr Opin Oncol* 2007; 19(2): 148-154.
26. Nakamae H, Yamane T, Hasegawa T, *et al.* Risk factor analysis for thrombotic microangiopathy after reduced-intensity or myeloablative allogeneic hematopoietic stem cell transplantation. *Am J Hematol* 2006; 81(7): 525-531.
27. George JN, Li X, McMinn JR, *et al.* Thrombotic thrombocytopenic purpura-hemolytic uremic syndrome following allogeneic HPC transplantation: a diagnostic dilemma. *Transfusion* 2004; 44(2): 294-304.
28. Uderzo C, Bonanomi S, Busca A, *et al.* Risk factors and severe outcome in thrombotic microangiopathy after allogeneic hematopoietic stem cell transplantation. *Transplantation* 2006; 82(5): 638-644.
29. Eremina V, Jefferson JA, Kowalewska J, *et al.* VEGF inhibition and renal thrombotic microangiopathy. *N Engl J Med* 2008; 358(11): 1129-1136.
30. Takatsuka H, Takemoto Y, Yamada S, *et al.* Complications after bone marrow transplantation are manifestations of systemic inflammatory response syndrome. *Bone Marrow Transplant* 2000; 26(4): 419-426.
31. Batts ED, Lazarus HM. Diagnosis and treatment of transplantation-associated thrombotic microangiopathy: real progress or are we still waiting? *Bone Marrow Transplant* 2007; 40(8): 709-719.
32. Perkowska-Ptasinska A, Sulikowska-Rowinska A, Pazik J, *et al.* Thrombotic nephropathy and pulmonary hypertension following autologous bone marrow transplantation in a patient with acute lymphoblastic leukemia: case report. *Transplant Proc* 2006; 38(1): 295-296.
33. Hewamana S, Austen B, Murray J, *et al.* Intestinal perforation secondary to haematopoietic stem cell transplant associated thrombotic microangiopathy. *Eur J Haematol* 2009; 83(3): 277.
34. Ho VT, Cutler C, Carter S, *et al.* Blood and marrow transplant clinical trials network toxicity committee consensus summary: thrombotic microangiopathy after hematopoietic stem cell transplantation. *Biol Blood Marrow Transplant* 2005; 11(8): 571-575.
35. Marr H, McDonald EJ, Merriman E, *et al.* Successful treatment of transplant-associated microangiopathy with rituximab. *N Z Med J* 2009; 122(1292): 72-74.
36. Carella AM, D'Arena G, Greco MM, *et al.* Rituximab for allo-SCT-associated thrombotic thrombocytopenic purpura. *Bone Marrow Transplant* 2008; 41(12): 1063-1065.
37. Au WY, Ma ES, Lee TL, *et al.* Successful treatment of thrombotic microangiopathy after haematopoietic stem cell transplantation with rituximab. *Br J Haematol* 2007; 137(5): 475-478.

38. Lin J, Markowitz GS, Nicolaides M, *et al.* Membranous glomerulopathy associated with graft-versus-host disease following allogeneic stem cell transplantation. Report of 2 cases and review of the literature. *Am J Nephrol* 2001; 21: 351-356.
39. Chang A, Hingorani S, Kowalewska J, *et al.* Spectrum of renal pathology in hematopoietic cell transplantation: a series of 20 patients and review of the literature. *Clin J Am Soc Nephrol* 2007; 2: 1014-1023.
40. Terrier B, Delmas Y, Hummel A, *et al.* Post-allogeneic haematopoietic stem cell transplantation membranous nephropathy: clinical presentation, outcome and pathogenic aspects. *Nephrol Dial Transplant* 2007; 22: 1369-1376.
41. Romagnani P, Lazzeri E, Mazzinghi B, *et al.* Nephrotic syndrome and renal failure after allogeneic stem cell transplantation: novel molecular diagnostic tools for a challenging differential diagnosis. *Am J Kidney Dis* 2005; 46: 550-556.
42. Cohen EP, Drobyski WR, Moulder JE. Significant increase in end-stage renal disease after hematopoietic stem cell transplantation. *Bone Marrow Transplant* 2007; 39: 571-572.