

# Celiac disease associated with autoimmune hepatitis and autoimmune hyperthyroidism

---

Milić, Sandra; Mikolašević, Ivana; Mijandrušić-Sinčić, Brankica; Bulić, Zlatko; Giljača, Vanja; Štimac, Davor

Source / Izvornik: **Medicinski Glasnik, 2013, 10, 408 - 410**

**Journal article, Published version**

**Rad u časopisu, Objavljena verzija rada (izdavačev PDF)**

Permanent link / Trajna poveznica: <https://um.nsk.hr/um:nbn:hr:184:082019>

Rights / Prava: [Attribution-NonCommercial-NoDerivatives 4.0 International/Imenovanje-Nekomercijalno-Bez prerada 4.0 međunarodna](#)

Download date / Datum preuzimanja: **2025-02-19**



Repository / Repozitorij:

[Repository of the University of Rijeka, Faculty of Medicine - FMRI Repository](#)



bolesti. U oba slučaja, isključeni su drugi mogući uzroci akutnog pankreatitisa. Budući da je AP čest poremećaj, a konzumacija marihuane raširena po cijelom svijetu, nužno je u svih bolesnika s nejasnom etiologijom AP-a razmišljati i o ovom, ne tako rijetkom uzroku AP-a.

**Ključne riječi:** česta bolest, tetrahidrokanabinoila (THC), etiologija.

## CASE REPORT

### Celiac disease associated with autoimmune hepatitis and autoimmune hyperthyroidism

**Sandra Milić, Ivana Mikolašević, Brankica Mijandrušić-Sinčić, Zlatko Bulić, Vanja Giljača, Davor Štimac**

Division of Gastroenterology, Department of Internal Medicine, University Hospital Rijeka, Rijeka, Croatia

**Corresponding author:** Ivana Mikolašević; Division of Gastroenterology, Department of Internal Medicine; University Hospital Rijeka, Krešimirova 42, Rijeka, Croatia;

Phone: +385 51 658 122; fax: +385 51 658 191;

Email: ivana.mikolasevic@yahoo.com

**Original submission:** 20 October 2012; **Revised submission:** 17 January 2013; **Accepted:** 18 January 2013.

Med Glas (Zenica) 2013; 10(2):408-410

## ABSTRACT

Although celiac disease (CD) may occur in patients with other immune-mediated disorders, its coexistence with multiple autoimmune diseases is not frequently described. We report the case of a 23-year-old woman referred to our centre because of jaundice and diarrhoea, who was diagnosed with CD in childhood. She complied with a gluten-free diet until puberty. Laboratory tests and liver biopsy were performed to establish the diagnosis of autoimmune hepatitis. Her thyroid-specific peroxides levels and thyroid gland function tests were altered as well, indicating the presence of an autoimmune disorder of the thyroid gland. Immunosuppressive treatment led to normalization of transaminases levels and bilirubin. In conclusion, other autoimmune diseases should be ruled out in patients with CD.

**Key words:** multiple autoimmune diseases, gluten-free, diet

## INTRODUCTION

Celiac disease (CD) is a chronic, multifactorial, auto-immune disorder of the small intestine (1). The disease develops in genetically-predetermined individuals because of persistent intolerance of gluten (1,2). Patients with CD may present to specialists other than gastroenterologists with diverse clinical manifestations (1-3). Here we report a case of a 23-year-old patient with previously diagnosed CD, with multiple autoimmune diseases.

## CASE REPORT

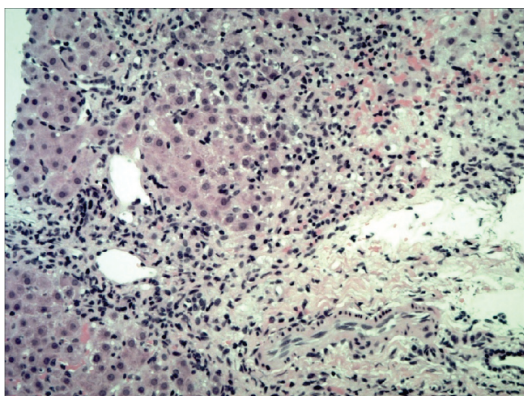
In August 2010, a 23-year-old woman was admitted to our department after experiencing diarrhoea, jaundice and weight loss that had occurred during the past 14 days. Her medical history began in 1990, when she was diagnosed with CD. She complied with a gluten-free diet (GFD) until puberty. She reported that her father was also diagnosed with CD.

Our patient gave birth six months prior to admission. Results of her physical examination identified a heart rate of 120 beats/min, jaundice, an enlarged thyroid gland, and hepatomegaly. The laboratory evaluation showed a serum Hb of 113 g/L (normal 119–157 g/L), iron 39 µmol/L (normal 8–30 µmol/L), ferritin 459 µg/L (normal 10–120 µg/L), MCV 75.4 fL (normal 83–97 fL), reticulocytes 138 x 10<sup>9</sup>/L (normal 22–97 x 10<sup>9</sup>/L). Serum AST and ALT levels were 924 U/L (normal 8–30 U/L) and 1181 U/L (normal 10–36 U/L), respectively, with an ALP level of 168 U/L (normal 64–153 U/L) and bilirubin level of 311 µmol/L (normal 3–20 µmol/L), with non-significant unconjugated hyperbilirubinaemia. Prothrombin time (PT) was 60% (normal >70%). Serum albumin, gamma globulins, and gamma glutamyl transferase (gGT) were within normal limits. Coombs direct and indirect tests were both negative. Screening evaluations for viral, autoimmune, and metabolic etiologies for chronic liver disease were unremarkable, except for an elevated anti-nuclear antibody (ANA). Anti-tTG antibodies were elevated to 226 RU/ml (normal < 20 RU/ml). Abdominal ultrasound showed hepatosplenomegaly, whereas there were no signs of biliary obstruction.

Because of the suggestive laboratory data, a diagnosis of autoimmune hepatitis (AIH) was

considered, and a liver biopsy was performed. Histological findings were compatible with AIH (Figure 1) which, together with positive ANA antibodies, suggested type I autoimmune hepatitis. Furthermore, high titers of serum TPO antibodies were presented with high values of thyroid hormones, and a diagnosis of autoimmune thyroid disease (ATD) with hyperthyroidism was assumed. The patient was advised to follow GFD and was started on an immunosuppressive treatment (an initial dose of prednisone 30 mg) with tiamazol. The patient responded well and her transaminases and bilirubin levels returned to normal, as well as thyroid gland function tests and anti-tTG antibody titers. Continued further ambulatory monitoring by a gastroenterologist and an endocrinologist was advised.

Gastroenterologists are familiar with the association between CD and immune and non-immune diseases (1,2). However, many diseases outside of the digestive system are also linked with CD, and patients with CD have about a ten-fold greater risk of other autoimmune diseases than the general population (1-3). When both autoimmune diseases and CD occur, CD is usually silent; as a result, the autoimmune disorder is frequently diagnosed first (1). Our patient was first diagnosed with CD, presenting with typical CD features, whereas both autoimmune disorders occurred nineteen years later. It is not known whether the treatment of CD reduces the likelihood of developing autoimmune disorders,



**Figure 1.** Pathohistological findings of liver biopsy. The lobular architecture of the liver is compromised. Streaks of connective tissue are visible, which deform the liver parenchyma in several places. Predominantly lymphocytic inflammatory infiltrate is visible in the relatively wide connective tissue streaks, but plasma cells are also present, the finding that suggests autoimmune hepatitis (Milić S, 2010)

or if it changes the natural history of the disease (1,2). Vljamaa et al (2) showed that a GFD does not reduce the risk of autoimmune diseases and has a negligible impact on the outcome of these diseases, whereas Ventura et al (3) showed that autoimmune diseases are more common in CD patients without GFD than in the control group (14% vs. 2.8%), and the risk increases with the duration of gluten exposure. Several CD-associated disorders might improve on GFD such as neurological, cardiac, and renal diseases, whereas the effect of GFD on the course of autoimmune liver disorders (AILD) requires further investigation (4,5). Furthermore, only few studies have investigated the role of GFD on the course of AILD. Some studies reported that with diet compliance, AILD may regress or go into remission, whereas some studies do not support such a hypothesis (6). In our case, it is doubtful whether non-compliance with GFD contributed to the development of autoimmune diseases of the liver and thyroid. Forty percent of patients with CD have reactive hepatitis with mild disturbance of liver function characterized by raised hepatic transaminase enzymes, with normal GGT and serum bilirubin levels (5-9). This condition is usually marked as “coeliac hepatitis” (1,9). This is explained by an increased permeability of the intestinal wall and increased availability of different antigens, toxins, and inflammatory mediators in the portal circulation (5-9). Pathological changes are mild and non-specific, and patients generally have no symptoms of liver damage or have nonspecific symptoms like fatigue and malaise (4,5). Transaminase levels usually return to normal in 95% of cases within 12 months after GFD (6-9). But, it is necessary to exclude other causes of liver damage, such as AILD in patients with persistently elevated transaminases who comply with GFD (4-9).

In our case report, we describe the association between CD and autoimmune hepatitis (AIH) type I. In patients with CD, the prevalence of AIH is approximately 4%, and is most frequently AIH type II (4,5). When both diseases are present, AIH is more often diagnosed first and CD is usually latent (4-9). The clinical impact of GFD on the outcome of AIH remains to be elucidated (6,10). People with CD also have an increased risk of developing autoimmune thyroid disease

(ATD) (1,5). According to the available literature, 2% to 7.8 % of CD patients may develop some form of ATD (1,5). This association is primarily explained by a common genetic predisposition (1,5). In our patient, symptoms of hyperthyroidism (weight loss and tachycardia) were present, with elevated levels of FT3 and FT4, decreased levels of TSH, and high titers of thyroglobulin antibodies. We started therapy with tiamazol and beta adrenergic receptor blocker, with further outpatient monitoring by an endocrinologist.

Both autoimmune disorders developed in our patient after non-compliance with GFD. It is doubtful whether our patient's non-compliance with GFD contributed to the development of autoimmune diseases of the liver and thyroid. We would like to stress the necessity of an interdisciplinary approach to patients with CD as well as many other conditions.

#### FUNDING

No specific funding was received for this study.

#### TRANSPARENCY DECLARATIONS

Competing interests: none to declare.

#### REFERENCES

1. Tack GJ, Verbeek WHM, Schreurs MWJ, Mulder CJJ. The spectrum of celiac disease: epidemiology, clinical aspects and treatment. *Lancet* 2010; 7:204-13.
2. Viljamaa M, Kaukinen K, Huhtala H, Kyrönpalo S, Rasmussen M, Collin P. Coeliac disease, autoimmune disease and gluten exposure. *Scand J Gastroenterol* 2005; 40:437-43.
3. Ventura A, Neri E, Ughi C, Leopaldi A, Citta A, Not T. Gluten-dependent diabetes-related and thyroid-related autoantibodies in patients with celiac disease. *J Pediatr* 2000; 137:263-5.
4. Mirzaagha F, Azali SH, Islami F, Zamani F, Khalilipour E, Khatibian M, Malekzadeh R. Coeliac disease in autoimmune liver disease: A cross – sectional study and a systematic review. *Digest Liver Dis* 2010; 42:620-3.
5. Vallejo MDC, Camarero JG, Menchén L, Díaz AP, Iacono OL. Liver damage and celiac disease. *Rev Esp Enferm Dig (Madrid)* 2007; 90:648-52.
6. Sedlack RE, Smyrk TC, Czaja AJ, Talwalkar JA. Celiac disease – associated autoimmune cholangitis. *AJG* 2002; 97:3196-8.
7. Duggan JM, Duggan AE. Systematic review: the liver in celiac disease. *Aliment Pharmacol Ther* 2005; 21:515-8.
8. Biecker E, Stieger M, Zimmermann A, Reichen J. Autoimmune hepatitis, cryoglobulinaemia and untreated celiac disease: a case report. *Eur J Gastroenterol Hepatol* 2003; 15:423-7.
9. Tovoli F, Giorgio DR, Caio G, Grasso V, Frisoni C, Serra M, et al. Autoimmune hepatitis and celiac disease: case report showing an entero-hepatic link. *Case Rep Gastroenterol* 2010; 4:469-75.
10. Tapia-Rubio A, Murray JA. The liver in celiac disease. *Hepatology* 2007; 46:1650-8.

### Udruženost celijakije s autoimunim hepatitisom i autoimunom bolesti štitnjače

Sandra Milić, Ivana Mikolašević, Brankica Mijandrušić-Sinčić, Zlatko Bulić, Vanja Giljača, Davor Štimac

Zavod za gastroenterologiju, Klinika za internu medicinu, Klinički bolnički centar Rijeka, Rijeka, Hrvatska

#### SAŽETAK

Iako celijakija ili glutenska enteropatija može biti udružena s drugim imunološkim bolestima, udruženost celijakije s više autoimunih bolesti nije česta. U ovom radu prikazujemo slučaj 23-godišnje bolesnice, liječene u našem Centru zbog ikterusa i proljeva, a kojoj je dijagnoza celijakije postavljena još u djetinjstvu. Do početka puberteta pacijentica se pridržavala bezglutenske dijeta. Tijekom boravka u našem Centru, učinjenom dijagnostičkom obradom (laboratorijski pokazatelji i patohistološki nalaz biopsata jetre), dokazan je autoimuni hepatitis. Nadalje, funkcionalni testovi štitnjače, kao i pozitivan nalaz antitijela na tkivnu peroksidazu, ukazivali su na autoimunu bolest štitnjače. Primjenom imunosupresivne terapije došlo je do normalizacije vrijednosti aminotransferaza, kao i regresije ikterusa. Slijedom navedenog, u bolesnika s celijakijom nužno je razmišljati i o drugim imunološkim bolestima.

**Ključne riječi:** imunološke bolesti, bezglutenska, dijeta