

# Arthroscopic Removal of Metal Foreign Bodies from the Knee Joint after Explosive War Injuries

---

Gulan, Gordan; Jurdana, Hari; Legović, Dalen; Šantić, Veljko; Šestan, Branko; Ravlić-Gulan, Jagoda; Rapan, Saša; Jovanović, Savo

Source / Izvornik: *Collegium antropologicum*, 2009, 33, 907 - 909

Journal article, Published version

Rad u časopisu, Objavljena verzija rada (izdavačev PDF)

Permanent link / Trajna poveznica: <https://um.nsk.hr/um:nbn:hr:184:943069>

Rights / Prava: [In copyright](#)/[Zaštićeno autorskim pravom](#).

Download date / Datum preuzimanja: **2025-03-20**



Repository / Repozitorij:

[Repository of the University of Rijeka, Faculty of Medicine - FMRI Repository](#)



# Arthroscopic Removal of Metal Foreign Bodies from the Knee Joint after Explosive War Injuries

Gordan Gulan<sup>1</sup>, Hari Jurdana<sup>1</sup>, Dalen Legović<sup>1</sup>, Veljko Šantić<sup>1</sup>, Branko Šestan<sup>1</sup>, Jagoda Ravlić-Gulan<sup>3</sup>, Saša Rapan<sup>2</sup> and Savo Jovanović<sup>2</sup>

<sup>1</sup> Clinic for Orthopaedic Surgery »Lovran«, School of Medicine, University of Rijeka, Rijeka, Croatia

<sup>2</sup> Department of Orthopaedic Surgery, School of Medicine, University of Osijek, Osijek, Croatia

<sup>3</sup> Department of Physiology and Immunology, School of Medicine, University of Rijeka, Rijeka, Croatia

## ABSTRACT

*The results of arthroscopic removal of metallic fragments from knee joint due to explosive war injuries are presented. In period from 1991–1995 during war in Croatia we have operated 25 knee joints. Indications for arthroscopy were based on radiographic and clinical findings. The foreign bodies in the joint were found in 19 patients while additional 6 had foreign bodies in the periarticular soft tissues. Arthroscopies were performed on average one month after wounding. The foreign bodies were placed in different parts of the joint with no prediction sites. In 8 knees foreign bodies were freely mobile, and in 11 were anchored to different intraarticular structures. There were no complications during early postoperative period as well as in follow up period.*

**Key words:** arthroscopy, knee, explosive injuries, foreign body, retrieval

## Introduction

Arthroscopy of the knee is well established method in diagnosis and treatment of the knee disorders in every day orthopedics practice. Loose bodies found in the knee's joint cavity are usually of cartilaginous and osseous origin. Foreign bodies are very uncommon. The experiences and the results of arthroscopic retrieval of foreign bodies are described only in few articles covered by arthroscopy. Commonly they described removal of bullets as a result of civilian gunshot wounds<sup>1</sup>. The role of arthroscopy in wartime has been demonstrated by Buckley et al.<sup>2</sup> and Hirsh et al.<sup>3</sup> as support of the troops. No treatment of explosive injuries was described by them. In this article we described our experiences and results in arthroscopically retrieval of metallic fragments from knee joint as a result of explosive war injuries in period from 1991–1995.

## Patients and Methods

Arthroscopic operation was performed in 25 patients, 23 males and 2 females, injured in the period between 1991–1995. The average age was 31 year (19–56). Explosive fragments caused all injuries. None of these were bullets. We analyzed only the patients with small en-

trance trauma. The patients suffered from acute or chronic disease were excluded. The time from the injury to the operation varied from 7 days to 5 months in patients who suffered from other injuries which need prior observation and treatment. Indications for arthroscopy were based on clinical and radiographic findings of foreign body. The radiographic findings consist of anterior-posterior, lateral view and the axial view of patella. In same cases the notch and oblique view was also used. Arthroscopy was performed in standard manner under spinal anesthesia, using of tourniquet, and anterolateral and anteromedial approach. The knee was filled with liquid media using of arthropump. Patients with clinical and/or arthroscopically verified synovitis and effusion had a biopsy and aspiration of synovial fluid for standard synovial fluid biochemistry. All patients had ESR and complete blood count (white blood count, differential white cell count, red blood count, hematocrit, hemoglobin, MCV, MCHC, MCH, platelet count).

All patients received tetanus antitoxin. All of them received three doses of 2 g of ceftriaxon. One dose was 1 hour prior the surgery and other two in period of 8 hour after surgery.

At the end of the operation the knees was additionally washed with 2l of liquid. Drainage was applied for 24 to 48 hours postoperatively.

## Results

In 19 (76%) of 25 operated patients explosive fragments were found in the joint cavity (fig 1). In 8 patients (32%) the metallic fragments were freely mobile while in 11 patients (44%) were anchored in the bone, cartilage, synovial membrane or between cruciate ligaments (fig 2). In 3 patients (12%) we found 2 fragments. Intra-articular damages were present in 15 patients (60%). They varied from few millimeters superficial damage of articular cartilage to extended lesion of cartilage and subchondral bone with hemarthros. We did not observe injury of cruciates ligaments despite of one patient with anchored fragment within it. In one patient X-rays showed the metal fragment in subchondral bone. At operation the cartilage above this area was intact but soft and bloated.

The removed fragments had irregular shapes and the larger diameter varied from 4 to 28 millimeters. In 6 patients (24%) with positive radiographic findings we could not find foreign bodies in the joint cavity, but synovitis was present.

Biopsy analysis of synovial tissue shows infiltration of inflammatory cells, capillary proliferation, deposition of fibrin, and vili proliferation. Hemosiderin was seen in the cytoplasm of the synovial cells in patients with hemarthros, but no crystals or particles deposition was noted.

Synovial fluid analysis reveals normal concentration of electrolytes with no abnormal protein or cells.

In follow up period which consisted from 6 months to 4 years all control blood test was in normal range in all patients. Four patients complained at intermittent knee pain with effusion. X-rays in all this cases showed subchondral sclerosis.

Despite of contaminated foreign body in the joint we did not observed any knee infection.

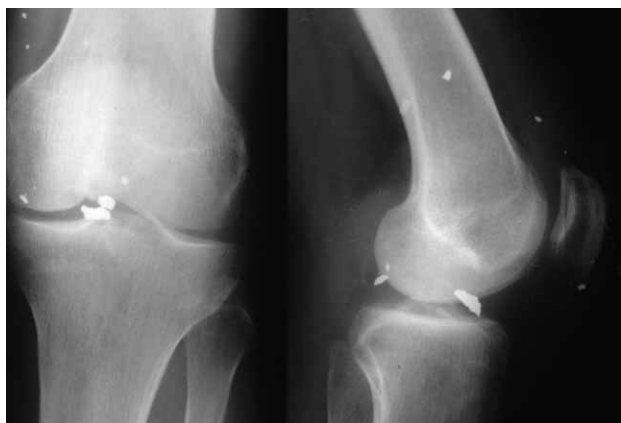

Fig 1. a) Anteroposterior and b) lateral radiographs of the knee joint with anchored metallic foreign body in the bone.

## Discussion

Metallic fragments have to be removed from the joint cavity because of possible mechanical damages of intra-articular structures especially cartilage. Especially in a case of loose body of irregular shape with sharp edge as it in explosive ordnance. The majority of patients suffered of vary degree of cartilage damage caused by friction between metal fragment and articular surface. Patient with anchored fragments had greater cartilage lesion which necessitated debridement in comparison with patients with mobile fragments who had diffuse scratches at articular cartilage surface, but they did not require debridement. The second reason for removing metallic fragments is to avoid synovitis or arthropathy or even systemic intoxication caused by lead.

In our group of patients the synovitis was present, but synovial fluid analysis reveal no crystal or other kind of deposition suggesting that synovitis was secondary mechanical irritation by explosive ordnance. This was confirmed with synovial tissue, synovial fluid and blood analysis which were in normal range. Most of patients had small metallic fragments in subsynovium and in periarticular soft tissue. There were not removed despite of their number. In follow up period we did not notice that these remaining pieces of metal bodies caused any pain or tenderness. These findings could be explained by rapid encapsulation of the fragments by fibrous tissue. In 6 patients with positive X-rays we could not find foreign bodies in the joint cavity. During war time we did not have available other imaging methods to confirm the exact placement of metallic bodies. We declare them as falls positive X-rays. It is important to point out that no one of them complained at the knee in follow up period.

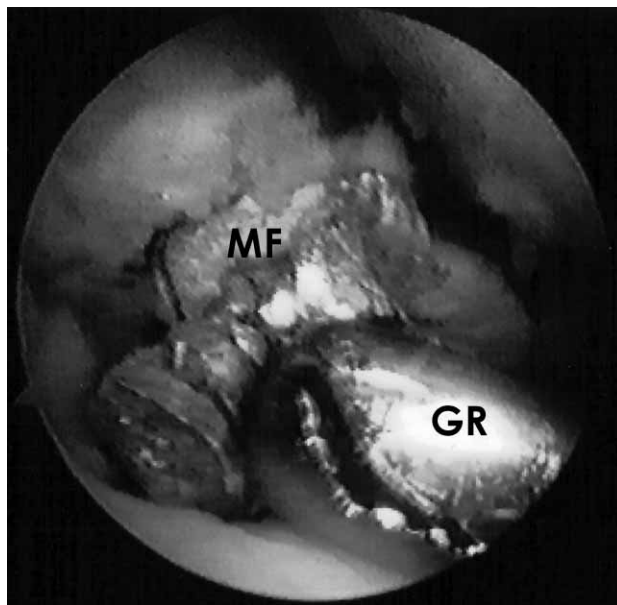


Fig. 2. Arthroscopically view of metallic fragment inside the knee joint. MF – metallic fragment. GR – grasper.

In case of fragments located deeper in subchondral bone, usually, only small part peek from joint surface hiding the major part of the fragment and the extent of the lesion as it is in iceberg phenomenon. Te attention should be paid during mobilization and extraction of such fragment because the enlargement of the lesion should be avoided. It is necessarily to to debrid the edges of remain-

ing crater as well as side and bottom of the crater to remove possible residual pieces.

In conclusion we point out that arthroscopy is useful method for removal the metallic loose bodies from the knee joints as results of explosive injuries are very demanding operation requiring an experienced arthroscopist.

## REFERENCES

1. WHITE RR, *J Traum*, 27 (1987) 445. — 2. BUCKLEY SL, ALEXANDER A, JONES M, CULP RW, SMALLMAN T, *Arthroscopy*, 8 (1992) 359. — 3. HIRSCH E, HRUTKAY JM, *Arthroscopy*, 10 (1994) 431. — 4. SCLAFANI SJA, VULETIN JC, TWERSKY J *Radiology*, 156 (1985) 299.

— SWITZ DM, ELMORSHIDY ME, DEYERLE WM, *Arch Intern Med*, 136 (1976) 939.

G. Gulan

*Clinic for Orthopaedic Surgery »Lovran«, M. Tita, 51415 Lovran, Croatia*  
e-mail: gordang@medri.hr

## ARTROSKOPSKO UKLJANJANJE METALNIH STRANIH TIJELA IZ KOLJENA NAKON EKSPLOZIVNIH RATNIH OZLJEDA

### SAŽETAK

U ovom radu izneseni su rezultati artroskopskog uklanjanja metalnih fragmenta iz zglobo koljena nastali kao posljedica ratnih ranjavanja. U razdoblju od 1991. do 1995. godine tijekom rata u Hrvatskoj, u našoj ustanovi operirano je 25 koljena zbog gore navedenog razloga. Indikacija za artroskopiju postavljena je na osnovu radiološkog i kliničkog nalaza. Metalni fragmenti nađeni su intraartikularno u 19 koljena, dok su u 6 koljena metalni dijelovi bili smešteni periartikularno u mekim tkivima. Artroskopija je učinjena prosječno mjesec dana po ranjavanju. U 8 koljena strana tijela bila su slobodna, dok je su u 11 koljena bila usidrena u različitim dijelovima intraartikularnih struktura, te nije nađeno niti jedno predilekcijsko mjesto. Tijekom poslijeoperacijskog praćenja nismo zabilježili niti jednu komplikaciju.