

Malignancy Risk in Patient with Neurofibromatosis and Autosomal Dominant Polycystic Kidney Disease

Flego, Veljko; Radojčić Badovinac, Anđelka; Pleše, Vika; Kapović, Miljenko; Beg-Zec, Zlata; Zaputović, Luka

Source / Izvornik: **Croatian medical journal, 2003, 44, 485 - 488**

Journal article, Published version

Rad u časopisu, Objavljena verzija rada (izdavačev PDF)

Permanent link / Trajna poveznica: <https://um.nsk.hr/um:nbn:hr:184:421725>

Rights / Prava: [In copyright](#)/[Zaštićeno autorskim pravom.](#)

Download date / Datum preuzimanja: **2024-12-27**



Repository / Repozitorij:

[Repository of the University of Rijeka, Faculty of Medicine - FMRI Repository](#)



Malignancy Risk in Patient with Neurofibromatosis and Autosomal Dominant Polycystic Kidney Disease

Veljko Flego, Anđelka Radojčić Badovinac¹, Vika Pleše², Miljenko Kapović¹, Zlata Beg-Zec, Luka Zaputović³

Department of Pulmology, Rijeka University Hospital Center; ¹Department of Biology, Rijeka University School of Medicine, Rijeka; ²Delnice Health Center, Delnice; ³Department of Internal Medicine, Rijeka University Hospital Center, Rijeka, Croatia

Cancer appearance in some inherited diseases depends on the interactions with other genes. Lung cancer is rare in neurofibromatosis and has not been reported in Caucasian population. In this paper, we present the case of lung adenocarcinoma in a patient with neurofibromatosis, pseudoarthrosis of tibia, and autosomal dominant polycystic kidney disease. Cytogenetic analysis of the pleural effusion showed chaotic cleavage and constitutional inversion of chromosome 9, transmitted from the mother. Family investigation revealed two autosomal dominant diseases, neurofibromatosis and polycystic kidney disease in the same family. These findings suggest that the second autosomal dominant disease in the family and inversion of chromosome 9 contributed to the severity of neurofibromatosis and patient's risk to malignancies.

Key words: adenocarcinoma; chromosomes, human, pair 9; inversion (genetics); lung neoplasms; neurofibromatosis; polycystic kidney diseases; pseudoarthrosis; tibia

Neurofibromatosis 1, or Morbus von Recklinghausen, is a relatively common autosomal dominant disease, which affects approximately one in 3,500 newborns (1). It is mostly a progressive disease, but with variable expression. The consistent clinical features of neurofibromatosis 1 are neurofibromas, café au lait spots, and Lisch nodules or pigmented iris hamartomas. Except these defining features, there are many other characteristics of this disease (2). Malignant tumors are more common in patients with neurofibromatosis than in population at large. The mean age of patients with neurofibromatosis 1 at diagnosis of malignancy is 38 years, compared with a mean age of 65 of the general population in the United States (2). Common malignancies in neurofibromatosis 1 patients are neurofibrosarcoma, optic glioma, malignant schwannoma, Wilms' tumor, rhabdomyosarcoma, astrocytoma, neuroblastoma, pheochromocytoma, leiomyosarcoma, and some types of leukemia (3). The development of epithelial malignancies, such as thyroid carcinoma, lung cancer, carcinoma of the Vater's ampulla, breast, bladder, or colon cancer is rare (4-6). Neurofibromatosis (NF) 1 gene is widely expressed in many tissues, and at particularly high level in the central and peripheral nervous system (7). It is assumed that the product of NF 1 gene, neurofibromin, acts as a tumor suppressor by

inhibiting the activity of ras oncogene (8). Besides germline mutations in NF 1 gene, other mutations can also occur in somatic cells and contribute to the development of sporadic tumors, including tumors without association with NF 1 (9-11).

Autosomal dominant polycystic kidney disease has a prevalence of about 1:1,000 (12) and may occur at any time in life. It is characterized by cystic formation of the kidney and, to a lesser extent, of the liver, spleen, pancreas, lungs, uterus, and several other organs, as well as of the testis and epididymis (13-15). Other gastrointestinal, cerebrovascular, and cardiovascular abnormalities are often found in patients with autosomal dominant polycystic kidney disease. In the majority of affected families, autosomal dominant polycystic kidney disease is linked to PKD 1 gene on chromosome 16p (16). PKD 1 mutations define a classical form of the disease, also known as autosomal dominant polycystic kidney disease 1. Here we present a patient with neurofibromatosis combined with lung adenocarcinoma and pseudoarthrosis of the tibia.

Case Report

A 50-year-old white male was admitted to the Department of Pulmology for a chest pain on the right

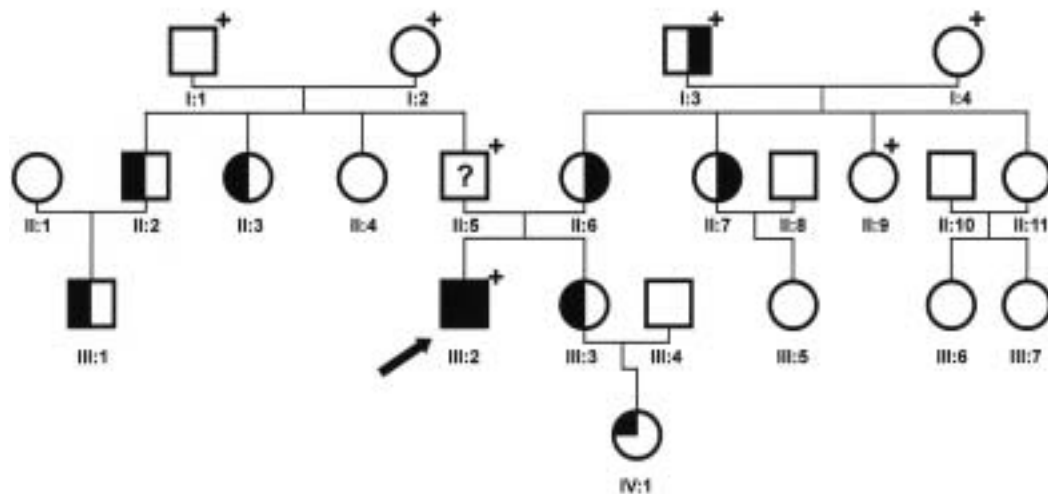


Figure 1. Pedigree of the family with neurofibromatosis (NF) 1. Arrow indicates the proband; open square – unaffected male; open circle – unaffected female; closed square – male affected by NF1 and polycystic kidney disease (PKD); closed circle – female affected by NF1 and PKD; open-closed square – male affected by NF1; open-closed circle – female affected by NF1; square with a question mark – possibly affected male; circle with a question mark – possibly affected female; open circle with a closed triangle – female with polycystic ovaries; closed-open square – male affected with PKD; closed-open circle – female affected with PKD; open square with a cross – deceased male; open circle with a cross – deceased female.

side, cough, dyspnea, fever, and weight loss. His past medical history included congenital deformation of the right foot. Skin macular pigmentation and neurofibromas, first observed at the age of 13, increased in number and size. His mother, aunt, and grandfather from the mother's side, had similar skin changes, but smaller and fewer. His uncle underwent a surgical treatment for kidney polycystosis, whereas his sister has kidney cysts and her daughter a polycystic ovary (Fig. 1). Proband's mother and her daughter a polycystic ovary (Fig. 1). Proband's mother and aunt, both with neurofibromatosis, had surgically treated myoma and stomach carcinoma, respectively. At physical examination, the patient showed multiple neurofibromas and café au lait spots (Fig. 2) covering the whole body, particularly the trunk. The right tibia was 8 cm shorter than the left one, with hypotrophic musculature, and the right ankle was deformed, with 0 degrees of flexion and 15 degrees of extension.

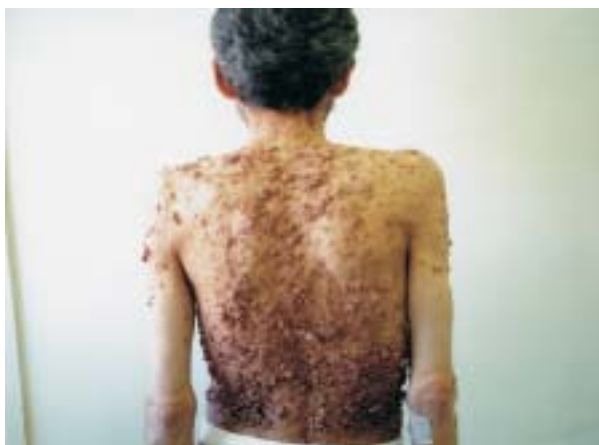

Figure 2. Patient with neurofibromatosis. The entire trunk is covered with cutaneous tumors.

The chest radiograph revealed massive pleural effusion, totally shaded right lung. Computed tomography (CT) scan of the chest revealed a large mass, 8.2 cm in diameter, in the right upper lobe, with central necrosis, liquidopneumothorax, and limited effusion on the same side, multiple nodular right pleural infiltrates specific for the pleural metastases, and an abnormal enlargement of the lymph nodes in the right supraclavicular and left axial region.

Pleural fluid had characteristics of an exudate and contained adenocarcinoma cells, as revealed on cytological examination. Malignant cells were not found on the cytological examination of bronchoscopic specimens, but the biopsy of the tumor by transthoracic ultrasound-guided needle showed malignant adenocarcinoma cells. CT scan of the brain revealed a tumor with level of density consistent to the metastases and necrosis at the right frontoparietal region. Therefore, the stage of the lung adenocarcinoma was specified as T4N3M1.

Abdominal ultrasound of the right kidney revealed a focal mass 8.5 x 5.6 cm and a cyst of 4.6 cm in diameter. Excretory urography confirmed a tumor. Unfortunately, the patient refused renal biopsy and the exact origin of the tumor could not be confirmed. Radiography of the right ankle showed aplasia of the distal part of the fibula, inclined and deformed tibia, and demineralized bones of the foot. Orthopedic diagnosis was congenital hypoplasia of the right fibula and congenital pseudoarthrosis of the right tibia. Histopathological examination of the skin nodule biopsy confirmed neurofibroma.

Karyotype analyses were performed on lymphocyte cultures from the patient and his mother. Pleural effusion cells of the patient were cultured for 10 days. Metaphase chromosomes were GTG-banded (17). Cytogenetic findings of the long-term cultivated pleural effusion cells showed chaotic cleavage. The most

common chromosome modal number in tumor cell population was $4n\pm$. Unbalanced forms of various translocations involving long arms of chromosomes 1, 3, and 10, marker, dicentric, and ring chromosomes, were seen in each metaphase spread, although there were a few mitoses with normal number of chromosomes but pericentric inversion transmitted from the mother – 46,XY,inv(9)(p11q13). Due to great karyotypic heterogeneity within the pleural effusion cells, a composite karyotype had to be created: $92\pm,XXYY,inv(9)(p11q13)c,+1,+3,+7,+dic(1;?),+3mar,-9,-17$ [cp17].

A palliative radiotherapy of the lung cancer was performed. Patient died two months later, at the age of 50.

Discussion

We presented a patient with Recklinghausen's disease who had lung adenocarcinoma and pseudoarthrosis, both very rare diseases in neurofibromatosis. He also had polycystic kidney disease and inversion of the chromosome 9 heterochromatin region. The coexistence of two autosomal dominant diseases, found in his family, is also extremely rare.

NF 1 gene spans over 350 kb of genomic DNA in the chromosomal region 17q11.2 (near centromere) and is widely expressed in a variety of human tissues. As mutations of the NF 1 gene have been detected in tumors, the presumption is that NF 1 belongs to the family of tumor suppressor genes (11,18). The translocated chromosomes have chromosome 17 break-points at the exact location where the NF 1 gene has been mapped (1). Neurofibromatosis is one of the most common human mutations, with average incidence of approximately 4/100,000 gametes (1,19). About half of all cases are considered to be the result of a new mutation. One of the most common human genetic diseases is autosomal dominant polycystic kidney disease 1 (12). From that aspect, it is not strange to find both diseases in one family.

Both sexes in Recklinghausen's disease are affected with equal frequency, with 50% recurrence risk, pronouncedly variable expression, virtually 100% penetrance, and 25-30% risk for moderate or severe disease, similar to polycystic kidney disease. The severity of the Recklinghausen's disease is unpredictable. No relation was found between the severity and age of onset, status of the affected parent, birth order, parental age, or environmental factors (1).

Lung cancer appears rarely in Recklinghausen's disease. There have been only 14 cases of neurofibromatosis associated with lung cancer, and only in the Japanese population (4,20,21). Adenocarcinoma was observed in about 73% of these cases (20). Many authors examined if genetic abnormality in neurofibromatosis increases a patient's risk of malignancies. Loss of heterozygosity (LOH) was detected on chromosome arm 17p in a patient with small cell lung carcinoma, but it is still unknown whether a mutation of the NF 1 gene on 17q was involved in the development of small cell lung carcinoma (21). The cases of Recklinghausen's disease and lung cancer derived from wall of emphysematous bulla have also been de-

scribed (19). In our patient's family, the neurofibromatosis was connected with several malignancies: stomach carcinoma (aunt, II:7; Fig. 1), lung adenocarcinoma, and possible kidney carcinoma (proband, III:2; Fig. 1). NF 1 protein regulates the level of biologically active ras-GAP (11). Ras activity is associated with the regulation of cell growth and differentiation including control of cytoskeletal organization and formation of cell-cell junction (8), possibly causing multiple tumor changes.

Pseudoarthrosis appears in 0.5-3% of the patients with neurofibromatosis, and about 50% of all cases of congenital pseudoarthrosis are due to neurofibromatosis (22). The tibia and the radius are the most common sites (23). The exact origin of pseudoarthrosis is unclear. Male patients have this complication more frequently than female ones. Moreover, this feature is more common if the gene is transmitted from the mother (22), as in our patient.

The inversion of the chromosome 9 is considered a normal heteromorphism, with familial inheritance. It is the result of fragile region involving repeated α , β , and satellite III DNA sequences (24), which gives rise to a variety of heteromorphisms whose clinical significance remains obscure. Although heterochromatin has been regarded as meaningless filler in the genome, its rearrangement can alter certain surrounding genes (25). 9p21 LOH has been detected in 70% of the early stages of lung cancer (26). The interaction of the remaining allele occurs through such processes as mutation or hypermethylation in cell clones in which exists an initial mutation. The inversion of hypermethylated heterochromatin near 9p21 loci is a highly possible mechanism for LOH and an additional factor contributing to malignancy in our patient. No clonal chromosomal aberration was found in cytogenetic analysis of the patient's pleural effusion cells, although the aberrations of chromosomes 9 and 3 are found. These chromosomes have been demonstrated as LOH sites in malignant lesion (27). Cysts of the testis, epididymis, and seminal vesicles in patients with autosomal dominant polycystic kidney disease have been reported (14,15), but polycystic ovaries in patients with polycystic kidney disease have not been described so far, and only further genetic testing will prove if proband's niece (IV:2; Fig. 1) has PKD 1 gene mutation transmitted from her mother.

In addition to lung adenocarcinoma and pseudoarthrosis, our patient with neurofibromatosis 1 also had polycystic kidney disease, a second autosomal dominant disease, and an inversion of chromosome 9 heterochromatin, which may have contributed to the severity of neurofibromatosis and development of multiple malignancies.

References

- 1 Viskochil D, White R, Cawthon R. The neurofibromatosis type 1 gene. *Annu Rev Neurosci* 1993;16: 183-205.
- 2 McGaughan JM, Harris DI, Donnai D, Teare D, MacLeod R, Westerbeek R, et al. A clinical study of type

- 1 neurofibromatosis in northwest England. *J Med Genet* 1999;36:197-203.
- 3 Fuyuno G, Kobayashi R, Iga R, Horio H, Nomori H, Kodera K, et al. A case of Von Recklinghausen's disease associated with a hemothorax due to a rapidly growing malignant schwannoma [in Japanese]. *Nihon Kyobu Shikkan Gakkai Zasshi* 1995;33:682-5.
- 4 Fukuoka K, Katada H, Kohnoike Y, Narita N, Ioka S. A case of Von Recklinghausen's disease associated with large cell carcinoma of the lung [in Japanese]. *Nihon Kyobu Shikkan Gakkai Zasshi* 1993;31:88-93.
- 5 Gomes H, Lebre R, Fonseca J, Borralho P, Duarte R. Adenocarcinoma of the Vater's ampulla associated with Von Recklinghausen's neurofibromatosis [in Spanish]. *Acta Med Port* 1997;10:832-6.
- 6 Nakamura M, Tangoku A, Kusanagi H, Oka M, Suzuki T. Breast cancer associated with Recklinghausen's disease: report of a case. *Nippon Geka Hokan* 1998;67:3-9.
- 7 Li C, Cheng Y, Gutmann DA, Mangoura D. Differential localization of the neurofibromatosis 1 (NF 1) gene product, neurofibromin, with the F-actin or microtubule cytoskeleton during differentiation of telencephalic neurons. *Brain Res Dev Brain Res* 2001;130:231-48.
- 8 Yla-Outinen H, Koivunen J, Nissinen M, Bjorkstrand AS, Paloniemi M, Korkiamaki T, et al. NF1 tumor suppressor mRNA is targeted to the cell-cell contact zone in Ca (2+)-induced keratinocyte differentiation. *Lab Invest* 2002;82:353-61.
- 9 Li Y, Bollag G, Clark R, Stevens J, Conroy L, Fults D, et al. Somatic mutations in the neurofibromatosis 1 gene in human tumours. *Cell* 1992;69:275-81.
- 10 Shen MH, Harper PS, Upadhyaya M. Molecular genetics of neurofibromatosis type 1 (NF1). *J Med Genet* 1996;33:2-17.
- 11 Hsueh YP, Roberts AM, Volta M, Sheng M, Roberts RG. Bipartite interaction between neurofibromatosis type 1 protein (neurofibromin) and syndecan transmembrane heparan sulfate proteoglycans. *J Neurosci* 2001;21:3764-70.
- 12 Coto E, Sanz de Castro S, Aguado S, Alvarez J, Arias M, Menéndez MJ, et al. DNA microsatellite analysis of families with autosomal dominant polycystic kidney disease types 1 and 2: evaluation of clinical heterogeneity between both forms of the disease. *J Med Genet* 1995;32:442-5.
- 13 Constantinou-Deltas CD, Papageorgiou E, Boteva K, Christodoulou K, Breuning MH, Peter DJ, et al. Genetic heterogeneity in adult dominant polycystic kidney disease in Cypriot families. *Hum Genet* 1995;95:416-23.
- 14 van der Linden E, Bartelink AK, Ike BW, van Leeuwen B. Polycystic kidney disease and infertility. *Fertil Steril* 1995;64:202-3.
- 15 Orhan I, Onur R, Ergin E, Koksall IT, Kadioglu A. Infertility treatment in autosomal dominant polycystic kidney disease (ADPKD) – a case report. *Andrologia* 2000;32:91-3.
- 16 Jeffery S, Sagar-Malik AK, Morgan S, Eastwood JB, Patton M. Genetic analysis of 20 families with autosomal dominant adult polycystic kidney disease from South West Thames Region. *Clin Genet* 1995;47:290-4.
- 17 Moorhead PS, Nowell PC, Mellman WJ, Battips DM, Hugerford DA. Chromosome preparation of leukocyte cultured from human peripheral blood. *Exper Cell Res* 1960;20:613-6.
- 18 Lothe RA, Saeter G, Danielsen HE, Stenwig AE, Hoyheim B, O'Connell P, et al. Genetic alteration in a malignant schwannoma from a patient with neurofibromatosis (NF1). *Pathol Res Pract* 1993;189:465-74.
- 19 Shimizu Y, Tsuchiya S, Watanabe S, Saitoh R. von Recklinghausen's disease with lung cancer derived from the wall of emphysematous bullae. *Intern Med* 1994;33:167-71.
- 20 Itoi K, Yanagihara K, Okubo K, Kuwabara M. A case of lung cancer in a patient with von Recklinghausen's disease [in Japanese]. *Nihon Kyobu Shikkan Gakkai Zasshi* 1992;30:317-21.
- 21 Shimizu E, Shinohara T, Mori N, Yokota J, Tani K, Izumi K, et al. Loss of heterozygosity on chromosome arm 17p in small cell lung carcinomas, but not in neurofibromas, in a patient with von Recklinghausen neurofibromatosis. *Cancer* 1993;71:725-8.
- 22 Riccardi VM. Von Recklinghausen neurofibromatosis. *N Engl J Med* 1981;305:1617-27.
- 23 Boero S, Catagni M, Donzelli O, Facchini R, Frediani PV. Congenital pseudoarthrosis of the tibia associated with neurofibromatosis-1: treatment with Ilizarov's device. *J Pediatr Orthop* 1997;17:675-84.
- 24 Ramesh KH, Verma RS. Breakpoints in alpha, beta, and satellite III DNA sequences of chromosome 9 result in a variety of pericentric inversions. *J Med Genet* 1996;33:395-8.
- 25 Macera MJ, Verma RS, Conte RA, Bialer MG, Klein VR. Mechanisms of the origin of an extra G-positive band within the secondary constriction region of human chromosome 9. *Cytogenet Cell Genet* 1995;69:235-9.
- 26 Kishimoto Y, Sugio K, Hung JY, Virmani AK, McIntire DD, Minna JD, et al. Allele-specific loss in chromosome 9p loci in preneoplastic lesions accompanying non-small-cell lung cancers. *J Natl Cancer Inst* 1995;87:1224-9.
- 27 Kohno H, Hiroshima K, Toyozaki T, Fujisawa T, Ohwada H. p53 mutation and allelic loss of chromosome 3p,9p of preneoplastic lesions in patients with non-small cell lung carcinoma. *Cancer* 1999;85:341-7.

Received: April 11, 2002

Accepted: May 14, 2003

Correspondence to:

Anđelka Radojčić Badovinac

Department of Biology

Rijeka University School of Medicine

Braće Branchetta 20

51000 Rijeka, Croatia

andjelr@mamed.medri.hr